

# HUMAN ANATOMY

*M. Prives*

*N. Lysenkov*

*V. Bushkovich*

I

# HUMAN ANATOMY

# HUMAN

М. Г. ПРИВЕС,  
Н. К. ЛЫСЕНКОВ,  
В. И. БУШКОВИЧ

АНАТОМИЯ ЧЕЛОВЕКА

ИЗДАТЕЛЬСТВО  
«МЕДИЦИНА»  
МОСКВА

M. PRIVES,  
N. LYSEKOV,  
V. BUSHKOVICH

# ANATOMY

VOLUME I  
THE WEIGHT-BEARING AND  
LOCOMOTOR SYSTEM  
THE SCIENCE OF THE VISCERA  
THE SCIENCE OF THE  
ORGANS OF INTERNAL  
SECRETION

*Translated from the Russian by  
Ludmila Aksenova, M. D.*



MIR  
PUBLISHERS  
MOSCOW

First published 1985  
Second printing 1986  
Third printing 1989

*На английском языке*

*Printed in the Union of Soviet Socialist Republics*

ISBN 5-03-000773-2

ISBN 5-03-000772-5

© Издательство «Медицина», Москва, 1974,  
с изменениями

© English translation, Mir Publishers, 1985

# CONTENTS

PREFACE	12
INTRODUCTION	13
THE SCIENCE OF HUMAN ANATOMY	13
METHODS OF ANATOMICAL STUDY	18
GENERAL PART	
BRIEF HISTORY OF ANATOMY	19
The Beginning of Anatomical Science at the Time of the Ancient Greeks	19
The Alexandrian Period	21
Ancient Rome	22
Anatomy in the Age of Feudalism (5th-17th Centuries)	23
The Renaissance	25
The Discovery of the Circulation of the Blood	29
Anatomy in the Age of Capitalism	31
The Cell Theory	32
The Evolutionary Idea as Applied to Man	33
Anatomy in Russia before the Great October Socialist Revolution	35
The Idea of Nervism in Application to Anatomy	40
Anatomy in the USSR	45
THE STRUCTURE OF THE HUMAN BODY	
The Organism	51
The Organism and Its Components	51
Tissues	52
Organs	54
Systems of Organs and Apparatus	55
The Integrity of the Organism	58
The Relationship of the Organism as a Single Whole to the Elements Composing It	59
The Organism and the Environment	59
THE PLACE OF MAN IN NATURE	
F. Engels' Labour Theory on the Origin of Man	63
The Main Stages in the Individual Development of the Human Organism (Ontogenesis)	66
The Initial Development of the Human Organism	66
The Auxiliary Extraembryonic Organs and the Connection of the Embryo with the Maternal Organism	75
The Extrauterine Developmental Period of the Organism	76
THE FORM, SIZE AND SEX OF THE HUMAN BODY	
Constitution	81
Norm and Anomalies	83

ANATOMICAL TERMINOLOGY	84
THE SUPPORTING (WEIGHT-BEARING) AND LOCOMOTOR SYSTEM	87
INTRODUCTION	87
THE PASSIVE PART OF THE SUPPORTING (WEIGHT-BEARING) AND LOCOMOTOR SYSTEM (OSTEOARTHROSYNDESMOLOGY THE SCIENCE OF THE BONES AND THEIR ARTICULATIONS)	89
General Osteology, Osteologia	89
Bone as an Organ	90
The Development of Bone	95
Bone Classification	100
X-ray Examination of Bone Structure and Development	102
The Dependence of Bone Development on Internal and External Factors	105
The Skeletal Structure of Various Occupational Groups (X-ray Picture)	108
The Skeletal Structure of Athletes Engaged in Various Sports	111
Anatomy as the Study of Dynamic Changes in Bone System	112
The Relationship of Social and Biological Factors in Bone Development	113
General Information on Bone Articulations (General Syndesmology)	115
Contiguous Articulations (Synarthroses)	116
Types of Syndesmoses	117
Types of Synchondroses	117
Transitional Articulations, Half-joints, Hemiarthroses	118
Interrupted Articulations, Joints, Diarthroses	118
Joint Biomechanics	120
Regular Features of Ligament Arrangement	122
Classification and General Characteristics of Joints	122
Uniaxial Joints	123
Biaxial Joints	125
Multiaxial Joints	126
Coordination of Joints	127
The Skeleton of the Trunk	128
The Vertebral Column	131
Individual Types of Vertebrae	133
Joints Between the Vertebrae	142
Joints Between the Vertebral Bodies	143
Joints Between the Vertebral Arches	144
Joints Between the Sacrum and Coccyx	145
The Union of the Vertebral Column with the Skull	146
The Vertebral Column as a Whole	147
The Thoracic Cage	149
The Sternum	150
The Ribs	150
Joints of the Ribs	152
The Thoracic Cage as a Whole	154
The Skeleton of the Head	156
The Bones of the Cerebral Cranium	163
The Occipital Bone	163
The Sphenoid Bone	165
The Temporal Bone	169

The Parietal Bone	175
The Frontal Bone	175
The Ethmoid Bone	177
The Bones of the Visceral Cranium	179
The Upper Jaw Bone	179
The Palatine Bone	182
The Inferior Nasal Concha	183
The Nasal Bone	183
The Lacrimal Bone	183
The Vomer	184
The Zygomatic Bone	185
The Lower Jaw Bone	185
The Hyoid Bone	189
Articulations of the Skull Bones	190
The Temporomandibular Joint	191
The Skull as a Whole	193
Age Features of the Skull	203
Sex Differences of the Skull	205
Craniaology and Criticism of the Racist "Theory"	205
The Skeleton of the Limbs	207
The Skeleton of the Upper Limb	213
The Shoulder Girdle	213
The Clavicle	213
The Scapula	214
The Joints of the Shoulder Girdle	215
The Skeleton of the Free Upper Limb and Its Adaptation to Labour	217
<i>The Humerus</i>	217
<i>The Shoulder Joint</i>	218
Bones of the Forearm	221
<i>The Ulna</i>	221
<i>The Radius</i>	221
<i>The Elbow Joint</i>	224
<i>Articulations Between the Forearm Bones</i>	227
The Bones of the Hand	227
<i>The Carpus</i>	227
<i>The Metacarpus</i>	229
<i>Bones of the Fingers</i>	229
<i>Joints of the Hand Bones</i>	232
The Skeleton of the Lower Limb	238
The Pelvic Girdle	238
The Ilium	238
The Pubis	239
The Ischium	239
Joints of the Pelvic Bones	240
The Pelvis as a Whole	243
The Skeleton of the Free Lower Limb and Its Adaptation to Walking Erect	247
<i>The Femur</i>	247
<i>The Patella</i>	248
<i>The Hip Joint</i>	249
The Skeleton of the Leg	252
<i>The Tibia</i>	253
<i>The Fibula</i>	254
<i>The Knee Joint</i>	256
<i>Joints Between the Leg Bones</i>	280
The Bones of the Foot	261
<i>The Tarsus</i>	261
<i>The Metatarsus</i>	263
<i>The Bones of the Toes</i>	264
<i>Joints of the Bones of the Foot</i>	265



THE ACTIVE LOCOMOTOR APPARATUS. MYOLOGY	272
General Information	272
Muscle Development	272
The Muscle as an Organ	277
The Work of Muscles (Elements of Biomechanics)	278
Regularities in Distribution of the Muscles	282
Classification of Muscles	283
The Auxiliary Apparatus of Muscles	284
The Soft Framework of the Human Body	285
The Effect of Environmental Factors on the Musculature	287
Special Myology	287
Muscles of the Back	287
Superficial Muscles of the Back	290
Deep Muscles of the Back	292
Autochthonous Muscles of the Back	292
Deep Muscles of the Back of Ventral Origin	295
Fasciae of the Back	295
Ventral Muscles of the Back	296
Muscles of the Chest	297
Chest Muscles Related to the Upper Limbs	297
Autochthonous Muscles of the Chest	298
The Thoracoabdominal Diaphragm	299
Fasciae of the Chest	301
Muscles of the Abdomen	302
The Lateral Muscles	302
The Anterior Muscles	305
The Posterior Muscles	308
The Inguinal Canal	309
Muscles of the Neck	312
Superficial Muscles—Derivatives of the Visceral Arches	313
The Middle Muscles, or Muscles of the Hyoid Bone	314
<i>Muscles Located Above the Hyoid Bone—Derivatives of the Visceral Arches</i>	314
<i>Muscles Located Below the Hyoid Bone—Derivatives of the Anterior Longitudinal Trunk Muscle</i>	316
The Deep Muscles	316
<i>Lateral Muscles Attached to the Ribs, the Scalene Muscles</i>	316
<i>Prevertebral Muscles</i>	318
Topography of the Neck	318
Fasciae of the Neck	320
Muscles of the Head	323
Muscles of Mastication	323
Muscles of Facial Expression	324
Muscles of the Scalp	326
Muscles Surrounding the Eyes	328
Muscles Around the Mouth	328
Muscles Surrounding the Nose	331
Fasciae of the Head	331
Muscles of the Upper Limb	331
Muscles of the Region of the Shoulder Joint	332
A. The Dorsal Group	332
B. The Ventral Group	335
Muscles of the Upper Arm	335
Anterior Muscles of the Upper Arm	336
Posterior Muscles of the Upper Arm	336
Muscles of the Forearm	337
The Anterior Group	337
The Posterior Group	341

<i>The Radial Group of the Superficial Layer</i>	342
<i>The Ulnar Group of the Superficial Layer</i>	344
<i>The Ulnar Group of the Deep Layer</i>	345
Muscles of the Hand	346
The Thenar Muscles	346
The Hypothenar Muscles	348
Muscles of the Hollow of the Hand	348
Fasciae of the Upper Limb and the Tendon Sheaths	350
Topography of the Upper Limb	352
Muscles of the Lower Limb	355
Muscles of the Hip Region	355
The Anterior Group	357
The Posterior Group	358
Muscles of the Thigh	360
The Anterior Group	360
The Posterior Group	362
The Medial Group	364
Muscles of the Leg	365
The Anterior Group	365
The Lateral Group	366
The Posterior Group	367
Muscles of the Foot	369
The Dorsal Muscles	370
The Plantar Muscles	370
Fasciae of the Lower Limb and Tendon Sheaths	373
Topography of the Lower Limb	377
Canals Transmitting the Vessels and Nerves	377
The Femoral Canal	379
The Most Important Specific Features of the Structure of the Motor System in Man Distinguishing Him from Animals	380
Survey of Muscles Accomplishing Movement of the Body Segments	381
Movements of the Spine	381
The Atlantoccipital Joint	382
The Shoulder Girdle	382
The Shoulder Joint	382
The Elbow Joint	383
The Joints of the Hand	383
The Joints of the Fingers	383
The Hip Joint	383
The Knee Joint	384
Movements of the Foot	384
The Joints of the Toes	384
Electromyographic Information on the Action of Muscles	384

## THE SCIENCE OF THE VISCERA (SPLANCHNOLOGY)

387

### GENERAL INFORMATION THE DIGESTIVE SYSTEM (SYSTEMA DIGESTORIUM)

387

390

Derivatives of the Foregut	391
The Cavity of the Mouth	391
The Palate	392

The Teeth	396
The Tongue	409
Glands of the Oral Cavity	414
The Pharynx	417
The Oesophagus	421
The Abdominal Cavity	426
The Stomach	428
Derivatives of the Midgut	438
The Small Intestine	438
Derivatives of the Hindgut	447
The Large Intestine	447
Regular Features of the Intestinal Structure	459
The Large Glands of the Digestive System	460
The Liver	460
The Pancreas	470
The Peritoneum	471
Main Stages of the Development of the Digestive System and the Peritoneum and Their Developmental Anomalies	480
The Foregut	483
The Midgut	485
The Hindgut	485

## THE RESPIRATORY SYSTEM (SYSTEMA RESPIRATORIUM)

	488
The Cavity of the Nose	489
The Larynx	492
Cartilages of the Larynx	493
Ligaments and Joints of the Larynx	495
Muscles of the Larynx	496
The Cavity of the Larynx	500
The Trachea	502
The Bronchi	503
The Lungs	506
Structure of the Lungs	507
The Segmental Structure of the Lungs	513
The Pleural Sacs and the Mediastinum	516
The Boundaries of the Pleural Sacs and Lungs	520
Development of the Respiratory Organs	523

## THE UROGENITAL SYSTEM

The Urinary Organs	
The Kidney	536
The Renal Pelvis, Calyces, and Ureter	540
The Urinary Bladder	543
The Female Urethra	543
The Genital Organs	544
The Male Genital Organs	544
The Testes	546
Ductus Deferens	547
The Seminal Vesicles	547
The Spermatic Cord and Coats of the Testis	551
The Penis	554
The Male Urethra	557
The Bulbourethral Glands	557
The Prostate	557

The Female Genital Organs	559
The Ovary	560
The Uterine Tube	562
The Epoophoron and the Paroophoron	563
The Uterus	563
The Vagina	569
Pudendum Femininum	570
Development of the Urogenital Organs	572
The Perineum	576
Muscles of the Perineum	576
Fasciae of the Perineum	581

## THE SCIENCE OF THE ORGANS OF INTERNAL SECRETION 583

### THE ENDOCRINE GLANDS (GLANDULAE ENDOCRINAE) 583

The Branchiogenic Group	586
The Thyroid Gland	586
The Parathyroid Glands	588
The Thymus	589
The Neurogenic Group	589
Hypophysis Cerebri	589
The Pineal Body	591
The Adrenal System Group	592
The Suprarenal Gland	592
The Chromaffin Bodies	594
The Mesodermal Glands	596
Endocrine Organs of the Sex Glands	596
Entodermal Glands of the Intestinal Tube	597
Insular Part of the Pancreas	597
Name Index	598
Subject Index	599

## PREFACE

The textbook on human anatomy by M. G. Prives, N. K. Lysenkov, and V. I. Bushkovich under the general editorship of Prof. M. G. Prives, reflects the latest research on anatomical science and offers a number of advantages over other textbooks. *Human Anatomy*, based on the advanced philosophy of dialectical materialism, offers a progressive view of descriptive, evolutionary, functional, and practical anatomy. The textbook approaches the human organism both analytically, according to organs and systems, and synthetically, as a discrete unit with close ties to the environment, especially to society. The book also contains a discussion of the influence of social factors, including the influence of extreme social conditions, on the structure of the human organism and includes a section on new trends in anatomical science currently under investigation by Prives and other Soviet scientists. These include the study of sports anatomy and the study of variants in the anatomy of individuals engaged in different professions. The textbook also contains information on the study of X-ray anatomy, the anatomy of the living human being. This branch of study first began to develop in the Soviet Union in part as the result of work by M. G. Prives. Finally, the textbook is valuable both for its traditional view of anatomy as the science of the human body structure and for its presentation of anatomy as the science of the natural laws regulating the structure and development of the human organism in relation to the environment. Anatomy is thus seen not as the stagnant subject of university courses but as a progressive science with important prospects. This approach gives the textbook *Human Anatomy* a great advantage over other anatomical handbooks for medical students.

The textbook has been published four times in Russian and four times in Spanish for use in Latin America. The Russian version received special mention in national competition with other Soviet medical textbooks. This publication of an English translation should be of interest and use to medical students and doctors.

A. V. Borisov  
CHAIRMAN, DEPARTMENT OF ANATOMY,  
Leningrad Medical Institute  
of Sanitary Hygiene

# INTRODUCTION

## THE SCIENCE OF HUMAN ANATOMY

The science of human anatomy is the study of the form and structure of the human body (and the organs and systems which form it) and the regularities of the development of this structure in relation to its functions and external environment. At the base of this science in the Soviet Union lies the advanced philosophy of dialectical materialism.

The study of anatomy previously dealt with a single problem: how the body is built. Descriptive anatomy, so called because it was restricted to a description of the body's structures, studied the body's form without regard to its function and made no attempt to disclose the laws governing its development. The approach taken by descriptive anatomy was thus metaphysical.<sup>1</sup>

Any science, however, undergoes two phases during its development: a descriptive phase during which facts are accumulated and described and a synthetic phase in which the accumulated facts are generalized and systematized and recurring patterns disclosed. The science of modern anatomy, therefore, seeks not only to describe but to generalize the facts, to uncover the regularities governing the structure and development of the human body and to regulate that structure, its organs, and its systems.

The object of the old descriptive anatomy was description of the structure of the body. In modern anatomy, however, description is a means rather than an end, one of the methods used in studying the human body structure. This method gives modern anatomy its descriptive aspect. Modern anatomy, however, attempts to explain not only *how* the organism is formed, but *why* it is so formed. To answer this second question, it is necessary to investigate both internal and external relationships of the organism.

According to dialectics (in contrast to metaphysics), everything in nature is interrelated, just as the living human organism is an integral system. For this reason, anatomy studies the organism not simply as the sum of its parts independent of the environment but as a discrete unit subject to and in unity with external conditions of existence. Dialectics, as opposed to metaphysics, further teaches that everything in nature changes and develops. Similarly, the human organism is not an unalterable entity cast in a single, unvariable shape but changes continuously from the time of birth to the

<sup>1</sup> In philosophy, metaphysics is a non-scientific approach to natural and social phenomena, which considers such phenomena unalterable and isolated from each other. As such, metaphysics is a method directly opposed to dialectics, which examines all phenomena in the light of their development, alteration, and interrelationships.

moment of death. The human species, in addition, is the product of prolonged evolution and displays features resembling those of the lower animal forms. Anatomy, therefore, studies not only the structure of the modern adult human being, but investigates the human organism in its historical development. With this in mind, the following three points should be considered.

1. The development of the human genus in relation to the evolutionary process of the lower life forms. This study is called *phylogenesis* (Gk *phylon* genus, *genesis* development) and uses the data of *comparative anatomy*, which compares the structures of various animals and man. In addition to comparative anatomy, which is a descriptive science, phylogenesis takes into account the principles of evolutionary morphology. Evolutionary morphology studies the dynamic forces of evolution and the structural changes an organism undergoes in its adaptation to given conditions in the environment (A. N. Severtsev).

2. The formation and development of the human being in relation to the development of society. The study of *anthropogenesis* (Gk *anthropos* human being), which uses the findings of both comparative anatomy and evolutionary morphology, is based primarily on the data of *anthropology*, the scientific study of mankind in its development. A branch of anthropology known as anatomical anthropology studies the structure of the human body not in relation to a hypothetical "average" human being but in relation to a given group of people who may vary according to constitution, occupation, and way of life. Anthropology studies man's evolution and physical make-up taking into account the historical development of the specific social group to which he belongs. In addition, anthropology is concerned with specific structural features of the human body as they relate to anthropogenesis and the leading role of labour in this process.

3. The process of the development of the individual organism throughout life. *Ontogenesis* (Gk *onthos* being) is concerned with uterine, embryonal (*embryogenesis*) processes, and extrauterine, postembryonal or postnatal (L *post* after, *natus* birth) processes. The data of *embryology* (Gk *embryo* to grow) and *age anatomy* are used in the study of ontogenesis. The last period of ontogenesis, ageing, is the subject of *gerontology*, the study of the ageing process (Gk *geron*, *gerontos* old man). Individual and sexual differences in the shape, structure, and position of the body and its organs as well as the topographic relationships of the organs are also taken into account.

As a result, the study of anatomy treats the human organism as a single entity, subject to definite patterns of development which have been influenced by various internal and external conditions throughout the evolutionary process. This approach to the structure of the human organism gives anatomy its *evolutionary aspect*.

Dialectical materialism also teaches that form and content or form and function are unified and each is determined by the other. An organism contains no structure that is not engaged in some function, and there are no functions that cannot be associated with some structure. 'The whole of organic nature is one continuous proof of the identity or inseparability of form

and content'<sup>1</sup> (function—*M.P.*). Each organ is to a great degree the product of the work in which it is engaged. The study of anatomy thus has a *functional aspect* since the structure of the organism and its separate parts and organs are considered inseparable from the function each body part performs.

The study of human anatomy is conducted not simply in and of itself. It is rather based on the principle of the unity of theory and practice and has an *applied aspect* which serves both medical science and physical culture.

The descriptive, evolutionary, and functional aspects of the study of anatomy are different features of a single science. The most important feature of the Soviet study of anatomy is its *effectiveness*, its attempt not to contemplate and describe the structure of the body passively (as advocated by Feuerbach's contemplative materialism) but to discover the natural laws governing the structure and development of the organism and to master these laws and thus influence the human organism in the direction necessary for the favourable and harmonious development of man.

L. Feuerbach argued that it is sufficient to observe nature, to contemplate it passively without interfering with it. Criticizing Feuerbach in "Theses on Feuerbach" Marx wrote: "The philosophers have only *interpreted* the world in various ways; the point is to *change* it."<sup>2</sup>

Science, according to Marx, must therefore serve three purposes: description, explanation, and direction.

Anatomy, as a science, accumulates and describes facts. Its evolutionary and functional aspects provide the possibility for explaining these facts and for determining the regular features of the human body structure. With a practical orientation, the science of anatomy may master and, in turn, direct and control these features. Anatomy may thus solve the problems of description, explanation and direction, and is consequently a science with considerable prospects.

In view of the vast material involved and the difficulty of studying the organism as a single entity, it is at first examined according to systems. The approach of *systematic anatomy* is to divide the organism artificially into parts using the analytical method. In the living organism, however, the separate parts and components of the body's structure (its systems, organs, tissues and so on) are not isolated but related in origin and development, and each helps shape and form the others.

To understand the organism as an entity, therefore, the synthetic method must also be applied. Anatomical knowledge is synthesized throughout the anatomy course by disclosing the connection between form and function and by studying the structure as its development is influenced by external and internal factors. At the end of the course, the body's systems are studied together, as they exist in the living organism. Attention is focused on the relationship of each system to every other and especially to the nervous sys-

<sup>1</sup> F. Engels. *Dialectics of Nature*. Foreign Languages Publishing House, Moscow, 1954, p. 401.

<sup>2</sup> K. Marx and F. Engels. *The German Ideology*. Progress Publishers, Moscow, 1964, p. 647.



tem, which unites the organism into a single entity (see the chapter "Synthesis of Anatomical Data").

Besides systematic anatomy there is *topographic* or *regional anatomy* which studies the spatial relationships of the organs in the different body regions. Since topographic anatomy has direct, practical significance for clinical work, particularly in surgical practice, it is also called *surgical anatomy*. Some authors separate from topographic anatomy an aggregate of information concerning the external relief of the body and its regions under the term "*relief anatomy*".

*Sport anatomy* studies the structure of the organism of individuals engaged in sports and the effect produced on the body's structure by various sports. Taught at institutes of physical culture, sport anatomy contributes to the improvement of the training of athletes. Sport anatomy is a branch of anatomical anthropology, which is concerned with the study of the anatomy of people with differing traits (race, constitution, habitat, and so forth).

Special attention is focused at institutes of physical culture on the functional anatomy of the supportive and motor apparatus. This branch of anatomy studies not only the structure of the apparatus but its dynamics, and is therefore called *dynamic anatomy*. Applied anatomy for artists and sculptors studies only the external form and proportions of the body and is known as *plastic anatomy*.

Anatomy that studies the normal healthy organism is called *normal anatomy*, as distinct from *pathological*, or *morbid anatomy*, which is concerned with the study of the sick organism and the morbid changes in its organs.

The types of anatomy indicated above differ in their approach to the study of the human body, which may be conducted on a cadaver or on a living person. Study of the *anatomy of the living human being* is especially necessary for the physician. The successes of this branch of anatomy are linked with advances in X-ray methods of examination which allow physicians to view almost all the organs and systems of the living human organism and constitute an integral part of that branch of modern anatomy designated as *X-ray anatomy*.

All these branches of anatomical science are different aspects of a *single human anatomy*.

The relationships existing in a single organism can be understood only by comparing the anatomical data with the data of other, *related disciplines*.

Man is the high point in the development of living matter. To understand the human structure, therefore, it is necessary to use the data of biology, the science of the laws of the origin and development of living matter. Just as man is a part of nature, anatomy, the science studying man's structure, is part of biology. Man, however, is an animal who produces tools. This classical definition voiced by B. Franklin and accepted by K. Marx reflects two aspects of man's nature: biological ("man is an animal..."), indicating man's relationship to the animal world, and social ("... producing tools"), emphasizing his social nature. The great importance of social conditions in man's development must consequently be borne in mind. The study of

human anatomy, therefore, exceeds the realms of biology and merges with the social sciences.

**The unity of form and function in the structure of the organism.** The organism and its components—organs, tissues, and cells—are different types of matter.

Dialectical materialism teaches that matter exists by movement and continuous change in space and time. From this point of view, form characterizes the arrangement of moving matter in space, that is the organization of the morphological substrate, whereas function is the process of its change in time. Because space and time, as properties of moving matter, are inseparable, form and function are interconnected and unified.

In this way the structure of living matter is a combination of the morphological substrate (or matter) and the dynamics of its changes (or movement). The structure of living matter, thus, comprises not only the form but the function, not only the morphological but the functional peculiarities of the organism.

To understand the structure of the organism in light of the *connection between form and function*, anatomy uses the data of *physiology*, the science of the organism's vital functions. Biology is usually separated into two branches: morphology, the study of form, and physiology, the study of function. Such separation is conditional, however, because "morphological and physiological phenomena, form and function, mutually determine one another."<sup>1</sup> Anatomy and physiology study one and the same object, the structure of living matter, but from different standpoints: anatomy from the standpoint of the form and organization of living matter and physiology from that of function, the processes taking place in the living matter. Thus anatomy and physiology, the alpha and omega of medical knowledge, are closely related disciplines. As A. P. Valter, a Russian anatomist and physiologist of the 19th century justly noted, "anatomy in union with physiology is the tsarina of medicine".

Since the external shape of organs cannot be separated from their internal structure, anatomy is also related closely to *histology*, the science of tissues, particularly to the branch of histology known as *microscopic anatomy*. Macroscopic, or gross, anatomy (Gk *markos* large, *skopein* to watch) and microscopic (Gk *mikros* small) anatomy are in essence a single science divided into two branches according to examination technique. Because of the specific character of the examination methods (microscope), the vast amount of material to be examined, and the specific patterns governing the development of tissues, cells, and extracellular substance, however, *histology* (Gk *histos* tissue) and *cytology*, the science of the cell (Gk *kytos* cell), are considered independent branches of science.

With the invention of the electron microscope, it became possible to examine submicroscopic structures and even molecules of living matter, which are also the objects of study in chemistry. A new science, *cytochemistry*,

<sup>1</sup> F. Engels. *Dialectics of Nature*. Foreign Languages Publishing House, Moscow, 1954, p. 401.

was born at the junction of cytology and chemistry. As a result the structure of the human organism is now studied at different levels:

1. At the level of systems and organs: (a) with the naked eye—macroscopic, or gross, anatomy; (b) with a magnifying glass—micro-macroscopic anatomy; (c) with a microscope—microscopic anatomy.

2. At the level of tissues (histology): (a) with a magnifying glass; (b) with a microscope.

3. At the cellular level (cytology): (a) with a light microscope; (b) with an electron microscope.

4. At the molecular level: (a) with an electron microscope and by means of cyto-histochemical reactions.

Thus, anatomy and histology are currently divided according to level and technique of examination.

Anatomy, histology, cytology, and embryology constitute the general science of the form, structure, and development of the organism, which is called *morphology* (Gk *morphe* form, shape).

## METHODS OF ANATOMICAL STUDY

There are two principal methods of anatomical study.

1. Examination of a cadaver by opening the body cavities and dissecting the organs and tissues with surgical instruments. The science of anatomy derives its name from this procedure of dissecting the whole cadaver into parts (Gk *anatome* to dissect). Tubular systems (vessels, ducts, and so forth) are injected with various media (injection method) and then exposed to X-rays, clarification, or corrosion. Nerves are treated by elective staining.

2. Examination of a living human being. Every physician begins examination of a patient with this procedure, which includes palpation, percussion, auscultation, various measurements of the body (anthropometry), and endoscopy examination of the hollow organs through the natural body orifices (Gk *endon* within).

X-rays provide the best possibilities for studying "living anatomy". They open, as it were, the internal organs of a living human being without a knife and without pain and make it possible to observe the structure of the organs of a single individual throughout the course of his life (X-ray anatomy). X-rays are used for making X-ray photographs (radiography) and for visualization on a special screen (radioscopy).

The newest methods of X-ray examination are as follows:

1. Electroradiography produces an X-ray image of the soft tissues (skin, subcutaneous fat, ligaments, cartilages, the connective tissue framework of the parenchymatous organs, etc.) which are invisible on ordinary radiographs because they are radiolucent.

2. Computer tomography produces an image of all the organs in a single plane of body tissue, much like sections of a frozen cadaver prepared according to the method developed by N. I. Pirogoff.

The living human being should be the main object of study in anatomy, with examination of cadavers providing supplementary information (P. F. Lesgaft). But because modern technology is still unable to supply the means for a profound study of the living human body, cadaver dissection remains the most important method of anatomical study.

In addition, experimental anatomy, in which experiments are performed on animals, is an important method of anatomical research.

As can be seen, modern anatomy has at its disposal a rich store of means for studying the structure of both the dead and the living human body.

# GENERAL PART

## BRIEF HISTORY OF ANATOMY

The history of anatomy is a history of the conflict of materialism and idealism in their views on the structure and development of the human organism. This conflict dates from the origin of the class system in the slave-owning era.

### THE BEGINNING OF ANATOMICAL SCIENCE AT THE TIME OF THE ANCIENT GREEKS

Anatomy started forming as a science under the ancient Greeks, who, as K. Marx pointed out, will be our teachers forever.


The social revolution of the 7-6th centuries B. C., which abolished the remnants of the tribal system in ancient Greece and gave rise to the slave-owning system, also caused an upheaval in the general mode of thinking. Antique science, as yet indistinguishable from philosophy, was born. Together, philosophy and natural science formed a single entity—natural philosophy.

The historical role of ancient Greek philosophy is determined by its materialistic character. A materialistic view on the structure of the human organism was formed under the influence of the materialism of Democritus and the dialectics of Heraclitus who voiced the famous thesis "all is flux, nothing is stationary" (*panta rhei*).

A contemporary of Heraclitus, *Alcmaeon of Crotona* (c. 500 B.C.), for instance, dissected cadavers and wrote a book of anatomy. As opposed to the idealists, he was the first to recognize the brain as the centre of mental activity.

Another eminent physician of ancient Greece, *Hippocrates* (460-377 B.C.) believed that four "humours" formed the basis of the structure of the organism: blood (*sanguis*), phlegm (*phlegma*), yellow bile (*chole*), and black bile (*melas chole*). The predominance of one of these "humours" determines a person's temperament: sanguine, phlegmatic, choleric, or melancholic. A person's temperament, as one of the manifestations of his mental activity, is, therefore, determined by the state of the body "humours", that is, matter. This approach constituted Hippocrates' materialism.

According to Hippocrates, the various types of temperament simultaneously determine different constitution types. An individual's constitution, according to Hippocrates' theory, is diverse and may alter in accordance with changes in the body humours (dialectics). Proceeding from such a concept of the organism, Hippocrates considered diseases to be the result of an



Hippocrates

improper combination of the humours. On this basis he introduced the practice of treating disease with different "humorogogues", thus originating the "humoral" theory of the structure of the human body. As a result of this theory, which has retained its importance to a certain measure to this day, Hippocrates is considered the "Father of Medicine".

There are many errors in the anatomical information supplied by Hippocrates. He did not, for instance, distinguish nerves from tendons; hence the name aponeurosis for the sheet of fasciae. It seemed to him that arteries (Gk *arteria* windpipe) contained air because in cadavers they were empty. At the same time, it should be pointed out, his works correctly hint at the idea of the circular movement of blood in the body. In his book *Fractures*, for example, Hippocrates wrote that one vessel gives rise to many other vessels, but that the beginning or the end of the vessel is impossible to determine since it "forms a circle".

*Plato* (427-347 B. C.), an ideologist of the reactionary aristocracy, was an opponent of materialism and an advocate of antique idealism. Plato's idealistic outlook was reflected in his concept of man. According to him, the organism is controlled not by a material organ, the brain, but by three types of soul, or "pneuma", contained in the three main organs of the body, i.e. the brain, the heart, and the liver (Plato's tripod).

*Aristotle* (384-322 B. C.), one of the greatest scholars and philosophers of ancient Greece, the disciple of Plato and the teacher of Alexander of Macedonia, was a dualist, an eclectic. On the one hand, he developed his teacher Plato's idealistic doctrine of entelechy, which viewed the soul as the

active, life-giving principle. Aristotle was an advocate of vitalism, an idealistic doctrine claiming that the organism and each of its parts possess a specific vital power. In addition, he was an advocate of teleology (Gk *telos* end, purpose), a theory which promoted the idealistic view that all in nature, including man, is subordinate to a higher purpose. On the other hand, Aristotle, in contrast to Plato, adhered to the materialistic view of the soul, which he believed to be part of the body, and therefore mortal, dying with the body.

Aristotle did not study anatomy specifically, but, as a great philosopher and a naturalist, he influenced its development significantly. He was the first to attempt a comparison of the body structure of animals with the embryo and was the pioneer of comparative anatomy and embryology. Aristotle voiced the true conception contradicting religion that any animal originates from an animal (*omne animal ex animali*).

## THE ALEXANDRIAN PERIOD

After the collapse of the great empire of Alexander III of Macedonia, the centre of Greek culture moved to Alexandria, which became the junction of major trade routes and in which favourable conditions were created for the flourishing of philosophy, science, technology, and arts.

Medicine and biology progressed, and a turn from speculative natural philosophy to observation and experiment became evident. Well-known physicians of the Alexandrian period were Herophilus and Erasistratus.

*Herophilus* (c. 304 B.C.), court physician to Ptolemy II (who himself was interested in anatomy), established anatomy as an independent science; previously it was regarded only as a part of surgery. It was Herophilus who began dissecting human cadavers, thus giving rise to the term anatomy. Using this method, he described various anatomical structures: the brain and its meninges; vascular network and venous sinuses and their confluence (*torcular Herophili*); nerves, which he distinguished strictly from tendons; arteries, which he differentiated from veins; the chyloferous vessels (though he did not appreciate their significance) and other vessels, including the pulmonary veins. He also discovered the duodenum and the prostate. Herophilus compiled the anatomical information he had collected and all the information existing before his time in a book on anatomy. His anatomical study of the vascular system was conducted to substantiate morphologically the humoral theory advanced by Hippocrates.

*Erasistratus* (350-300 B.C.), basing his theories on the materialistic philosophy of Democritus and Epicurus on the atomic structure of matter, believed the human organism to be formed of minute, indivisible particles. Like Herophilus, he made some discoveries concerning the vascular system and founded the science of vascular anastomoses. Erasistratus was the first to differentiate motor and sensory nerves and after studying the contraction of muscles, he developed the theory of movement which was accepted until the seventeenth century.



Claudius Galen

## ANCIENT ROME

*Claudius Galen* (130-c. 200 A.D.), known as the Aristotle of medicine, was an eminent philosopher, biologist, physician, anatomist, and physiologist of ancient Rome. Although he almost equalled Aristotle in creative talent and depth, his primary sphere of activity was medicine. Galen was court physician to the emperor and philosopher Marcus Aurelius and was provided with exceptional working conditions for his studies as a scientist and physician.

Galen was in essence an eclectic. In his views regarding the organism he, on the one hand, developed Plato's idealism and Aristotle's teleology, while, on the other, he studied the organism from the materialistic standpoint. As an ardent Platonist he believed the organism to be controlled by three organs: the liver, in which physical pneuma was produced and then distributed along the veins; the heart, in which vital pneuma originated and was then transmitted along the arteries; and the brain, in which the psychic pneuma was concentrated and then distributed along the nerves.

Following Aristotle's teleologic hypotheses, Galen considered the human organism to be a divine machine of a design beyond human perfection created for a higher purpose by the supreme artist. These idealistic postulates existed together with materialistic ideas. Galen believed that the human body consisted of solid and fluid particles. The four humours postulated by Hippocrates—blood, mucus, yellow bile, and black

bile—were the fluid particles. Diseases were differentiated according to whether they arose from changes in the humours or from changes in the solid parts of the body. Galen taught that functional disorders could not occur without preceding changes in the material composition of the organism.

Galen's materialism was also revealed in his approach to the study of the organism, which he investigated by observing patients and dissecting animal cadavers. He was the first to conduct vivisection and to pioneer experimental medicine, particularly of the nervous system.

As the result of these methods, Galen greatly advanced the study of anatomy. He suggested the classification of bones and joints that still exists today and described different parts of the brain, including the vein which bears his name (*vena cerebri magna Galeni*). Galen's concept of the movement of blood persisted until the discovery of circulation by Harvey in the seventeenth century.

There were many errors in Galen's description of the structure of the human organism because dissection of human cadavers was forbidden. As a result, he was forced to content himself with the dissection of animals, especially monkeys whose structure resembles the human body structure. Medicine was founded on Galen's anatomy and physiology throughout the Middle Ages. His anatomical errors became evident only during the Renaissance when the dissection of human cadavers was again allowed.

## ANATOMY IN THE AGE OF FEUDALISM (5th-17th CENTURIES)


When the system of owning serfs no longer corresponded to the development of the forces of production and the serf-owning society began to disintegrate as the result of wars and revolts by the serfs, a new society, characterized by feudal relationships, formed on its ruins.

The first stage of feudalism (from the fifth to the tenth or eleventh century), "the early medieval times", directly followed the fall of the Western Roman Empire. Early feudalism with its natural economy and almost complete absence of large cities, trade, and other forms of intercourse between countries did not promote the development of science. In Western Europe the reigning Catholic Church with its single ideology of christianity opposed science and prevented its development. Alchemy, magic, and other secret occult pseudosciences flourished instead of true science. As a result, science, including the study of anatomy, began to decline. The human organism was considered to be a miniature world, a "microcosm". Parts of the body were believed to correspond to parts of the sky. As a consequence, astrology developed instead of anatomy. Galen's works, stripped by the clergy of their materialistic essence, were the only medical writings distributed. The clergy encouraged the popularization of Galen's idealistic and teleologic views on the creation of man according to the supreme plan of God and persecuted those who criticized these views.

Having thus established Galen's theories as scholastic dogma, the church provided for the supremacy of galenism during the entire age of feudalism and prevented the further general development of anatomy and medicine in Western Europe. In the East, which was free of the influence of Catholicism, the progress of medicine continued.

After the baptism of Russia, Byzantine culture together with Russian





Ibn Sina (Avicenna)

Orthodoxy spread throughout the country. Monastic medicine based on the most valuable works of ancient science became important at this time.

The first Russian physicians were given an account of anatomy and physiology in an anonymous treatise, *Aristotelevy problemy* (*Aristotle's Problems*), and in a commentary written by Kirill, father-superior of the Belozersk monastery.

The Moslem East also played a positive role in assuring the continuity of antique science. Arabs who invaded Europe from Africa in the seventh and eighth centuries translated into Arabic the works of the philosophers and physicians of ancient Greece and Rome and preserved them for future generations. *Ibn Sina*, or *Avicenna* (980-1037), for example, was a great scholar, physician, poet, and statesman, the "Father of Science" and encyclopaedist who wrote about all the major problems of the second half of the Middle Ages. He was the author of more than one hundred works, the most prominent of which is *The Canon of Medicine* (c. 1000). This book contains valuable anatomical and physiological information adopted from Hippocrates, Aristotle, and Galen to which Ibn Sina added his own belief that the organism is controlled not by three organs (Plato's tripod) but by four, namely the heart, brain, liver, and testis (Avicenna's quadrangle). Ibn Sina's study of the structure of the eye is also original. *The Canon of Medicine* was the best medi-

cal work produced in the feudal age and served as the source of knowledge for physicians of the East and West until the seventeenth century.

The second stage of feudalism, the "developed Middle Ages" (from approximately the eleventh to the fifteenth century), was characterized by still greater religious oppression and decline of science in Western Europe. In the East, Arabic physicians continued contributing to the progress of medicine. One of them, *ibn-al-Nafiz* from Damascus (twelfth century), discovered pulmonary circulation.

## THE RENAISSANCE

The sixteenth and seventeenth centuries witnessed the decline of feudalism and the formation of elements of capitalism from the remnants of the disintegrating feudal society. The rising class, the bourgeoisie, was interested in the development of the forces of production and, consequently, in the development of science. The Renaissance, which Engels called "... the greatest progressive revolution that mankind had so far experienced ..."<sup>1</sup>, began and, with it, a revival of ancient science. The revival embraced all the sciences, including anatomy, which entered the scientific period of its development. At the time, anatomy was characterized by two antagonistic trends, the result of class relations of the epoch: an idealistic trend, which encouraged the subordination of science to the idea of authority (medieval feudal and church traditions), and the materialistic trend, which advocated the criticism of the idea of authority.

During this period, mere scholasticism was replaced by objective study of the human body. The "revival" destroyed the fear of the cadaver and laid the foundation for a proper understanding of the structure and performances of the human body.

The Renaissance was "... a time which called for giants and produced giants—giants in power of thought, ... in universality and learning".<sup>2</sup> The study of anatomy produced such titans as well. They destroyed Galen's scholastic anatomy and laid the foundation of scientific anatomy. Leonardo da Vinci initiated this titanic work, which was continued by Vesalius and completed by Harvey.


*Leonardo da Vinci*<sup>3</sup> (1452-1519), the genius of the Renaissance, was a painter, engineer, philosopher, and scientist in various fields of science, including anatomy. He first became interested in anatomy as an artist but later approached the subject from a scientific point of view. He did not restrict himself to the study of the external relief of the human body but was one of the first scholars to dissect human cadavers and was a genuine innovator in the study of the human organism.

Da Vinci's methods of investigation were themselves innovative. He dissected human cadavers, sawed and analysed bones, and prepared models, which he drew from various perspectives to produce three-dimensional images of the organs. These drawings were the first correct representations of various organs of the human body. Despite religious ideas of the creation of Eve from Adam's rib, da Vinci was firm in his claim that males had twelve pairs of ribs.

<sup>1</sup> F. Engels. *Dialectics of Nature*. Foreign Languages Publishing House, Moscow, 1954, p. 30.

<sup>2</sup> *Idem*.

<sup>3</sup> Cited from D. A. Zhdanov, *Leonardo da Vinci* (1955) and M. A. Tikotin, *Leonardo da Vinci in the History of Anatomy and Physiology* (1957) (both in Russian).



Leonardo da Vinci

Leonardo da Vinci contributed greatly to the development of the study of human and animal anatomy and he was the founder of the study of plastic anatomy. It has been suggested that his creative work in turn influenced the work of Andreas Vesalius, a revolutionary in anatomical science.

**The Paduan school (Venice).** The first sources of capitalist production were evident as early as the fourteenth and fifteenth centuries in various towns along the shores of the Mediterranean Sea, particularly in the famous Venetian Republic. The republic's cultural centre was Padua, with its ancient university founded in 1222 in which the first medical school of the capitalist era (the Paduan school) was formed. Padua is also the home of Europe's first anatomical theatre built in 1490.

The lively atmosphere of new interests and demands created in Padua was congenial to the reformer, or rather, the revolutionary in anatomical science, *Andreas Vesalius* (van Wesel) (1514-1565). Vesalius was a Belgian, Flemish by origin. Instead of the scholastic method of interpretation characteristic of medieval science, his approach to the study of the organism was materialistic, and he used the objective method of observation. In numerous dissections of cadavers, Vesalius studied the structure of the human body systematically for the first time. He boldly demonstrated and corrected Galen's numerous anatomical errors (more than 200) and thus began to undermine



Andreas Vesalius

the authority of Galen's anatomy which reigned at the time. In this period, as Engels pointed out, it was necessary to study objects before investigating processes. Thus, a metaphysical, analytic period occurred in anatomy, during which many discoveries of a descriptive nature were made.

During this period Vesalius focused his attention primarily on the discovery and description of new anatomical facts which he compiled in the large and richly illustrated manual *De humani corporis fabrica*, consisting of seven books (1543). I. P. Pavlov characterized this work of Vesalius as the first account of human anatomy in modern history that did not merely repeat the hypotheses and opinions of ancient authorities but was based on the work of a freely inquiring mind.

The publication of Vesalius' book caused, on the one hand, a revolution in the anatomical conceptions of that time and, on the other, the furious opposition of reactionary Galenic anatomists, who attempted to preserve Galen's declining authority. Vesalius was subjected to persecution; he was slanderously accused of dissecting the body of a noble woman whose heart was allegedly still beating. As punishment he was sent on a pilgrimage to Jerusalem. According to one version (cited by V. N. Ternovsky), he died on his way back home. Vesalius' work, however, was continued by his students and followers.

*Gabriele Fallopio* (1523-1562), for instance, gave the first detailed description of bone development and structure (the scalp, in particular) and of the development and structure of the muscles, the sex organs, the organs of



William Harvey

hearing and sight, and other organs. His discoveries are described in *Observationes anatomicae*. Various anatomical structures, for example, the fallopian tubes, Fallopius' canal still bear his name.

*Bartolomeo Eustachio* (1520-1574) described the structure of the teeth, kidneys, veins, and the organs of hearing. He discovered the thoracic duct of horses. Besides his work in descriptive anatomy, he studied the history of the development of organisms, a subject Vesalius did not cover. His anatomical knowledge and descriptions are presented in the *Manual of Anatomy* published in 1714. Various anatomical structures bear his name: the Eustachian tube, the Eustachian valve.

The "anatomical triumvirate" of Vesalius, Fallopio, and Eustachio built a firm foundation for descriptive anatomy in the sixteenth century.

The seventeenth century was a turning point in the development of medicine and anatomy since during this century the scholastic and dogmatic anatomy of the Middle Ages was completely defeated and the foundation for true scientific thought was laid. This ideological defeat was connected with the name of an eminent representative of the Renaissance, an English physician, anatomist, and physiologist, *William Harvey* (1578-1657). Like his great predecessor Vesalius, Harvey fought against idealism in anatomy and approached the study of the organism from the materialistic standpoint, i.e. using observation and experiment.

Harvey did not restrict his study of anatomy to simple description of structures, but conducted his investigations from a historical (comparative anatomy and embryology) and functional (physiology) standpoint. He was the first to offer the brilliant hypothesis that an animal in the process of ontogenesis repeats the phylogenetic process and was thus the first to establish the biogenetic law later proved by A. O. Kovalevsky and formulated by Haeckel and Mueller in the nineteenth century. In opposition to religion, Harvey advanced the materialistic premise that all animals develop from an egg (*omne animal ex ovo*), an idea which became the basis for further development of embryology. Harvey discovered that the embryonal disc was an embryo and described the process of labour, the placenta, and the umbilical cord, which was of great use in the practice of medicine. All this allows Harvey to be considered the founder of embryology.

Since the dissection of cadavers, introduced by Vesalius, could not yield information on the vital functions of the organism, Harvey performed experiments on animals. Dissection and experiment were the two methods that made it possible for him to investigate the most important vital function—the circulation of the blood. As the result of this approach, Harvey provided a true picture of blood circulation for the first time. In view of the importance of this discovery, we dwell on it here separately.

## THE DISCOVERY OF THE CIRCULATION OF THE BLOOD

Following Galen, an idealistic doctrine had reigned in medicine that claimed that blood, endowed with pneuma, moved in the vessels like the tides of a sea. Prior to Harvey, it was not known that the blood flows in a circular fashion. This concept originated in the fight against Galenism in which several materialistic anatomists participated.

When Vesalius became convinced that the septum between the ventricles of the heart was impermeable, for instance, he criticized Galen's idea that the blood entered the left half of the heart from the right half through a supposed opening in the interventricular septum.

Vesalius' pupil *Realdo Colombo* (1516-1559) showed that blood from the right half of the heart entered the left half not through the septum but by way of the lungs through the pulmonary vessels. The Spanish physician and theologian *Miguel Servetus* (1511-1553) also pointed this out in his work *Christianismi Restitutio*. As an enemy of idealism, he was accused of heresy and burnt at the stake with his book in 1553. The development of anatomy was thus linked with the tragic fate of many progressive scientists who encroached upon the authority of the church. It is hard to say today who first discovered pulmonary circulation, the Italian Colombo or the Spaniard Servetus, but they both evidently had no knowledge of the discovery made by the Arab *ibn-al-Nafiz* mentioned above.

*Hieronymus Fabricius ab Aquapendente* (1537-1619), another successor to Vesalius and the teacher of Harvey, described the venous valve<sup>1</sup> in 1547.

<sup>1</sup> Fabricius also studied the development of the chick from the egg and was the first to compare the human embryo with animal embryos.

These investigations paved the way for Harvey's discovery of the circulation of the blood. On the basis of seventeen years of experiments, Harvey repudiated Galen's idealistic doctrine on *pneuma* and drew a well-composed picture of the circulation of the blood instead of the idea that blood moves like the tides of the sea. He gave an account of the results of his investigations in the famous essay *Anatomical Treatise on the Movement of the Heart and Blood in Animals* (1628).

Harvey's small book was a landmark in medicine. Its publication caused a reaction of two kinds: sympathy on the part of progressive scientists and anger on the part of the conservatives. Scientists of the time were separated into the followers of Galen and the followers of Harvey. They supported two different forms of ideology in science: idealistic and materialistic. Like Vesalius, Harvey himself suffered persecution and slander, but his materialistic doctrine won.

After Harvey's discovery it was still not clear how arteries and veins were connected, although Harvey predicted the existence of anastomoses between them invisible to the naked eye. This was confirmed with the invention of the microscope and the development of microscopic anatomy.

Using the microscope *Marcello Malpighi* (1628-1694) made many discoveries in the microscopic structure of the skin (Malpighi's layer), spleen and kidney (Malpighian corpuscles), and other organs. After studying plant anatomy, Malpighi, the founder of that branch of anatomy, extended Harvey's premise that "almost all animals, even those which bring forth their young alive, and man himself, are produced from eggs" (usually quoted as *omne vivum ex ovo*). Malpighi was the scientist who discovered the capillaries predicted by Harvey. He contended, however, that blood from the arterial capillaries first entered 'intermediate spaces' and only after that flowed into the venous capillaries.

It was *A. M. Shumlyansky* (1748-1795) who, after studying the structure of the kidneys, proved that there were no mythical "intermediate spaces" and that the arterial and venous capillaries communicated directly. A.M. Shumlyansky thus first demonstrated that the blood-vascular system is closed, and in this way finally "closed" the blood circuit.

In the year Harvey's work was published, a book by *Gaspar Aselli* (1581-1626) appeared. Aselli discovered the lacteal vessels in 1622 and pioneered the study of the lymphatic system, which facilitated better understanding of the circulation of the blood. The famous Dutch anatomist *Frederik Ruysch* (1638-1731) contributed greatly to studying the anatomical paths along which the blood moved. He developed a new method of injecting substances into vessels, thus considerably expanding the knowledge of the anatomy of the blood-vascular system.

Ruysch believed that the blood vessels permeating all the organs were the foundation of the organism. He was also an advocate of the humoral theory. He developed his own embalming techniques and built the best anatomical museum of the time ("the eighth wonder of the world"). Ruysch sold most of his splendid preparations to his student Peter I.

The concept of the circulation of the blood was therefore the result of

creative work by a number of brilliant scientists, from Vesalius to Harvey. The intervening period is characterized by the struggle between materialism and idealism as a result of which scholastic Galenism in medicine was completely defeated.

The discovery of the circulation of the blood was therefore important not only for anatomy and physiology, but for all biology and medicine. It marked a new epoch: the end of the scholastic medicine of feudalism and the beginning of the scientific medicine of capitalism.

## ANATOMY IN THE AGE OF CAPITALISM

The French bourgeois revolution of the eighteenth century broke the chains of feudalism and established the capitalist system. F. Engels pointed out that this political coup was preceded by a revolution in philosophy as a result of which eighteenth-century French materialism was formed.

French materialism combatted both idealism and religion. Divesting man of his claim to divinity, French materialism contended that all inorganic and organic nature, including man, was governed by the same laws. Since mechanics was the only relatively well-developed science at the time, these general laws were patterned after the laws of mechanics. Thus French materialism itself, among whose representatives were physicians, was mechanistic in character.

*Julien Offroy de La Mettrie* (1709-1751) regarded the human organism as a peculiar animated machine and called his famous treatise *l'Homme machine* (1748). For the publication of this atheistic work, La Mettrie was attacked and persecuted by the clergy.

The views of other prominent anatomists of the eighteenth century, Morgagni, Bichat, and others, also formed on the basis of mechanistic materialism.

*Giovanni-Batista Morgagni* (1682-1771) founded the study of pathological anatomy in his investigations of the anatomical changes associated with various morbid phenomena. Since changes of the large structures, the organs, were the most striking findings in the cadavers he dissected, Morgagni thought morbid conditions of the organs were the cause of disease and considered the organism to be a mechanical sum of organs. This tendency to focus attention on the organs persisted in medicine for a period of time and was of some progressive significance.

*Marie François Xavier Bichat* (1771-1802) furthered the mechanistic trend in French science by focusing attention on the tissues and by laying the foundation of histology, the science of tissues. Morgagni regarded the organism as a sum of organs. Bichat, in contrast, considered it to be a sum of tissues, which he believed to be the carriers of disease. He also established the important concept of "sympathy", that is, the concept of the organism's performances as interrelated and determined by the affinity between the tissues. Hence the term "sympathetic" nervous system. Although Bichat's general views regarding the organism were a mixture of mechanistic materialism and idealism (he claimed that the tissues possessed special vital power), they nonetheless played an important part in the development of morphology.



## THE CELL THEORY

A cell structure was first discovered in plants by Robert Hooke, Malpighi, and others. But the real definition of the cell theory was made in 1839 by Theodor Schwann who recognized that cells are common to plants and animals and are the basic material of the tissues and organs of all living animals.

With the cell theory (despite the erroneous interpretation of the relationship between the cells and the organism as a whole), physiology obtained for the first time a material substrate for the processes it studied. At the same time biology acquired firm ground for the idea of the evolutionary development of the organic world, and medicine found a basis for understanding pathology. That is why, when characterizing the successes in natural science, F. Engels named the cell theory among the three greatest discoveries of the nineteenth century.

The cell theory was elaborated in the works of several scientists among whom Johannes Purkinje and Rudolf Virchow were particularly noteworthy. The Czech histologist *Johannes Purkinje* (1787-1869), using considerably improved microscopic techniques, described the microscopic structure of various tissues and organs and discovered bone cells, specialized fibres in the heart (Purkinje's fibres) and special cells in the cerebellum (Purkinje cells, or corpuscles). In addition to other discoveries he isolated the germinal nucleus of the chicken's egg (the first phase of the embryo).

The German morphologist *Rudolf Virchow* (1821-1902), the founder of cellular pathology, applied the cell structure theory to the study of the sick organism. Virchow made a great contribution by focusing attention on the study of the cell under normal and abnormal conditions and accumulating a rich factual material. This constituted the positive aspect of his activity. His ideas, however, had a negative influence as well. As a statesman, he supported the bourgeois regime in Prussia at the time and compared the organism to a state of cells, a federation of cellular territory. This denial of the integrity of the organism was mechanistic in essence, while the endowment of the separate cellular territories with the ability to live independently was vitalistic, that is, idealistic. Virchow's views on the organism were contrary to the progressive philosophy of dialectical materialism being formed at the time and were therefore criticized by one of the founders of this philosophy, F. Engels. Virchow did not recognize the leading role of the nervous system in uniting the organism and thus hindered the development of the idea of nervism. He also opposed Darwin's evolutionary ideas and thus showed himself to be a metaphysician.

"Virchowianism", the sum of these idealistic, mechanistic, and metaphysical concepts, reigned in bourgeois medicine which acquired an anatomological character. A considerable length of time, almost one hundred years, was needed to defeat Virchowianism ideologically. This was accomplished in the Soviet Union, the birth place of the dialectical materialistic idea of nervism, which replaced the reactionary theory of Virchowianism.

## THE EVOLUTIONARY IDEA AS APPLIED TO MAN

The evolutionary idea of development greatly influenced the development of anatomy. A metaphysical view of nature reigned in biology until the second half of the nineteenth century. The Swedish naturalist *Carolus Linnaeus* (Karl von Linne, 1707-1778), in his work *Systema Naturae*, proposed a "ladder of living beings" on which he arranged all animals according to species and order, placing man at the top. The creation of this zoological ladder was the most valuable achievement of eighteenth-century natural science because it offered the first classification of the animal world, which is used to this day. This classification, however, included the concept of the immutability of the animal species and of the origin of man as the result of "divine creation".

In opposition to this metaphysical view, the dialectical theory of development began gaining strength in the nineteenth century. It caused a revolution in biology and medicine and formed the basis of Darwinian theory, which in turn served as the foundation for evolutionary morphology.

The previous course of science, particularly of embryology and comparative anatomy, paved the way for Darwinism. A member of the Russian Academy of Sciences, C. F. Wolff (1733-1749), for instance, showed that organs are not preformed during embryogenesis (preformism), but originate and develop anew (epigenesis). In opposition to the idealistic theory of preformism and to the biblical interpretation of the origin of the embryo, Wolff therefore advanced the materialistic theory of epigenesis and pioneered the study of materialistic embryology, for which he was persecuted by adherents of idealism.

The French naturalist *Jean Baptiste Lamarck* (1744-1829) was among the first to propound, in his work *Philosophie Zoologique* (1809), the idea of the organism's evolution under the influence of the environment. The Soviet biologist Michurin and his followers later freed Lamarckism from idealism while preserving its rational core (the possibility of the inheritance of acquired characters) in their work.

The Russian Academician K. M. Baer (1792-1876), in continuing Wolff's embryological research, discovered the ova of mammals, including man, and determined the principal laws governing the individual development of organisms (ontogenesis), which underlie modern embryology. Known as the Father of Embryology, Baer investigated the early stage of embryonal development (the blastula) and developed the theory of germinal layers. He advanced the idea of the transformation of species before Darwin, and, although he later criticized Darwin's theory of the struggle for existence, he nonetheless claimed to have "paved the way for Darwin's theory".

Engels appraised the activity of all the scientists mentioned above as follows: "... C. F. Wolff in 1759 launched the first attack on the fixity of species and proclaimed the theory of descent. But what in his case was still only a brilliant anticipation took firm shape in the hands of Oken, Lamarck,

Baer, and was victoriously carried through by Darwin in 1859, exactly a hundred years later."<sup>1</sup>

The brilliant English scientist *Charles Darwin* (1809-1882), in his epoch-making work *The Origin of Species* (1859), proved that animal species change in the process of adaptation to the conditions of existence. He also established the unity of the animal kingdom and man's place in its evolutionary process. Darwin came to the conclusion that man, like the modern anthropomorphic monkey, descended from highly developed, anthropoid apes resembling man though now extinct.

Darwinism, the complex of facts and theory developed by Darwin, dealt religion a crushing blow by challenging the biblical legend claiming that man was created by God. For this reason, the church and reactionary science hindered the development of Darwinism in Western Europe and America. In Russia the work of progressive Russian scientists-materialists (the brothers A. O. and V. O. Kovalevsky, I. M. Setschenov (Sechenov), E. I. Metchnikoff, K. A. Timiryazev, A. N. Severtsov, and others) aided the rapid development of Darwinism.

*E. I. Metchnikoff* (1845-1916) established that, in the period of embryonal development, both invertebrates (with the exception of coelenterates) and chordates have three germinal layers. This discovery established the first link between the invertebrates and the vertebrates. The second link was *A. O. Kovalevsky's* (1840-1901) discovery in the adult *Balanoglossus* of certain features inherent in the chordates (gill slits, germs of the chorda). Finally, *A. O. Kovalevsky* succeeded in proving that the lancelet was a hybrid form since it had features of both invertebrates (e.g. the skin structure) and vertebrates (e.g. the presence of an axial skeleton, i.e. the chorda, and the location of the nervous system). From his study of the development of the *Balanoglossus*, *Ascidia*, lanceletes and vertebrates, *Kovalevsky* was able to reform the classification of the animal kingdom and establish a new phylum, Chordata, to which man also belongs.

By establishing a connection between the invertebrates and the vertebrates, *Kovalevsky* filled the gap existing at the time in Darwin's doctrine. Darwin himself appraised this discovery highly. *Kovalevsky* also determined that the nervous system arose from the outer germ layer (ectoderm) while the primary gut arose from the internal layer (entoderm).

The embryological research carried out by *Kovalevsky*, as well as by *Baer*, *Mueller*, *Darwin*, *Haeckel*, was reflected in the biogenetic law "ontogenesis repeats phylogenesis". This law was formulated more thoroughly and corrected by *A. N. Severtsov*, who showed the influence of environmental factors on animal body structure. By applying evolutionary science to the study of anatomy, *Severtsov* became the founder of evolutionary morphology. In this way Darwinism developed in the works of Russian morphologists and embryologists.

The classics of Marxism-Leninism criticized Darwin's theory for certain

<sup>1</sup> F. Engels. *Dialectics of Nature*. Foreign Languages Publishing House, Moscow, 1954, p. 42.

methodological errors, but nonetheless appraised it highly as one of the three greatest discoveries in natural science of the nineteenth century.

Darwin's solution to the problem of evolution—man's descent from ape-like ancestors—was necessarily one-sided since he dealt with the problem only from the biological perspective. This one-sided approach prevented him from discussing the factors which determined man's origin. This problem was solved by the founders of Marxism, *Karl Marx* and *Friedrich Engels*. Engels in his work *The Part Played by Labour in the Transition from Ape to Man* (written in 1876, published in 1896) showed that the use of tools was the decisive factor in the formation of man. His hypothesis, expressed in the phrase "labour created man", states that the use of tools transformed a tribe of apes into a human society. Engels' theory, called the labour theory of the origin of man, formed the basis of progressive modern science.

Darwin's theory and Engels' labour theory greatly influenced the study of human anatomy and posed a number of new questions to anatomists whose task was now not only to describe and explain the human body structure, but to disclose the regular patterns of its formation so that further changes to the human organism might be directed. These questions particularly concerned Soviet anatomists, working in the best traditions of their native school of anatomy, a short account of which follows.

## ANATOMY IN RUSSIA BEFORE THE GREAT OCTOBER SOCIALIST REVOLUTION

The state of anatomy in old Russia was discussed on p. 24.

Since no secular medical school existed in feudal Russia, medical science developed in monastery hospitals established by the clergy. Monks translated the works of Greek and Roman physicians and wrote their own medical books. The monk Yermolai Erasm, for instance, set forth an original system of anatomical and physiological ideas on the human body structure in the sixteenth century.

The seventeenth century was characterized by repeated wars, which called for the organization of medical personnel. An office of medical administration, the Apothecaries' Office (*Prikaz*), was established for this purpose in 1620, to which the first Russian medical school was attached in 1654. Anatomy was taught in the medical school according to Vesalius' well-known manual on the structure of the human body. The manual was translated from the Latin into Russian by the famous writer, translator, and scientist *Epifany Slavinetsky* in 1658, more than one hundred years before it was translated in a number of European countries. The first Russian medical students thus studied the scientific anatomy of Vesalius instead of the scholastic anatomy of Galen, used in European universities at the time.

At the start of the eighteenth century, Russia's development was greatly accelerated by reforms made by Peter I, who "opened a window onto Europe". Peter I was himself interested in anatomy, which he studied with the famous anatomist Ruysch during his visits to Holland. He also obtained a collection of anatomical preparations from his teacher. Together with other freak specimens collected at Peter's decree, these preparations formed the collection of the Museum of Natural Curiosities in St. Petersburg, Russia's first natural science museum. Some of the preparations have been preserved to date.

Conditions in feudal Russia demanded the development of science as a necessary precondition for the development of industry. With this in mind, the Russian Academy of Sciences was established in St. Petersburg in 1725. The Academy provided anatomy with a firm foundation for its progress.


*M. V. Lomonosov*, one of the greatest Russian scientists and the pioneer of natural science in Russia, worked at the Academy. Lomonosov was a materialist, who advocated the study of anatomy by observation and thus laid the proper foundation for the future development of the science. He also correctly assessed the value of the microscope in the examination of structures invisible to the naked eye. Lomonosov's general materialistic view formed the philosophic basis for the idea of nervism, an advanced and progressive philosophy unique to Russian medicine (see below).

Lomonosov's pupil *A. P. Protasov* (1724-1796) was the first Russian anatomist to be admitted to the Academy. Applying his teacher's materialistic philosophy to the study of the human organism, Protasov advocated the unity of the spirit and body. He contended that the organism consisted of matter ("substance"), which differed in structure in the various organs ("instruments") and performed various functions ("actions"). In his thesis "On the Movement of Blood in the Lungs" (1751), Protasov criticized the ideas of Kay-Boerhaave, a great authority from another country, while in the thesis "Anatomo-physiological Discourse on the Action Exerted by the Stomach on the Food Entering It" (1768), he developed the idea of the unity of form and function and of anatomy and physiology. True to Lomonosov's tradition of concern for public health, particularly for the health of children, Protasov wrote two works "On the Necessity of Movement for Health Preservation" and "On the Physical Education of Children".

Other students of Lomonosov also contributed to the development of anatomy: *K. I. Shchepin*, the first to teach anatomy in Russian, *M. I. Shein*, the author of the first Russian anatomical manual, *Syllabus*, and *N. M. Maximovich-Ambodik*, the author of the first Russian dictionary of anatomical terms, *Anatomo-physiological Russian-Latin-French Dictionary* (1783).

The basis for the study of microscopic anatomy in Russia was laid in the eighteenth century. This development is linked with the name of *A. M. Shumlyansky* (1748-1795), who was one of the first to use the microscope. In his thesis "On the Structure of the Kidneys" (1782), Shumlyansky made several discoveries in the microscopic structure of the kidney and disclosed for the first time the essence of the renal (Malpighian) corpuscle, which might more correctly be called the Malpighian-Shumlyansky corpuscle. In his study of the human organism, Shumlyansky attached special importance to the functions performed by the various organs and to the nervous system regulating all the processes of the body. As is noted above, Shumlyansky contributed the conclusive data to the proper idea of the circulation of the blood, and his name should therefore stand in a row with Harvey and Malpighi.

The outstanding eighteenth-century revolutionary, scientist, writer, and philosopher *A. N. Radishchev* (1749-1802) advanced materialistic views on the structure and development of the human organism, which surpassed



P. A. Zagorsky

the views of even the most progressive philosophers of his time, the French materialists. Radishchev opposed both the biblical legend of the creation of man and the theory of racism. Almost one hundred years before Darwin, Radishchev wrote that man is a descendant of the ape and differs from the ape in that he speaks and leads a social way of life. In the field of embryology, Radishchev, whose work was highly praised by V. I. Lenin, argued against the idealist preformation theory and defended the materialistic epigenesis theory.

The first Russian anatomists and biologists thus showed themselves to be progressive men of science of their time, who, as supporters of natural-scientific materialism, actively opposed idealism. They not only assimilated the anatomical knowledge accumulated by previous generations critically but enriched it creatively with new facts, examination methods, and generalization in the field of materialistic philosophy.

At the turn of the eighteenth century, the politics of tsarist Russia required growth of the army and the medical staff serving it. With this in mind, the St. Petersburg Medico-Surgical Academy (now the Kirov Military Medical Academy) was organized in 1798 for training military physicians.

The department of anatomy and physiology at the Academy was held by P. A. Zagorsky (1764-1846), who wrote the first textbook of anatomy in Russian, *Concise Anatomy or Guide for Understanding the Structure of the Human Body for the Benefit of Students of the Physician's Science* (1802), and organized the first Russian anatomical school. Zagorsky was a polemical materialist who opposed various manifestations of idealism in biology and medicine that hindered the development of anatomy. Zagorsky's scientific




I. V. Buyalsky

and educational work contributed richly to the development of Russian anatomy; a prize for outstanding work in anatomy is awarded regularly in his honour.

*I. V. Buyalsky* (1789-1866) was an outstanding student of Zagorsky and his successor as the head of the department of anatomy and physiology. He was one of the first Russian scientists to study systematically the general features of the structure of the human organism in his manual *Brief Anatomy of the Human Body* (1844). Buyalsky pioneered the theory of individual variability, which was later developed by the Soviet anatomist V. N. Shevkunenko (see below). He studied man in unity with his environment, from the standpoint of the unity of physical and psychic properties. Buyalsky adhered to the mechanistic ideology of natural-historical materialism. But because this trend of materialism opposed clerical and idealistic ideas reigning in science during the 1840s, an entire chapter on the subject was deleted from Buyalsky's book by the censor. Buyalsky was also the author of a handbook of plastic anatomy. He was perhaps even more famous as a surgeon than as an anatomist (he treated the great Russian poet A. S. Pushkin for example, for wound received in the duel which proved fatal to the poet) and his work *Anatomico-Surgical Tables* (1828) links anatomy with surgery. The work was translated into many languages and brought world fame to Russian anatomy.

The first half of the nineteenth century was the period of the decay of serfdom and the formation of industrial capitalism in Russia. Progressive Russian science, which was necessary for the development of industry, was successful in overcoming the obstacles, presented by the reactionary politics of tsarism, the persecution of materialistic ideas, and theological instruction in the schools. Use of the microscope was introduced into anatomical practice,



N. I. Pirogov

and anatomists began conducting scientific experiments about this time. The introduction of new technical equipment was paralleled by the infusion of new ideas into the study of anatomy. The discovery of the cell and successes in paleontology, comparative anatomy, and embryology greatly influenced anatomy, which began to flourish. At the same time comparative anatomy, histology, and pathological anatomy began to emerge as independent disciplines, and the growing requirements of surgery encouraged the development of surgical or topographic anatomy as an independent science. Buyalsky and Pirogov, the great Russian anatomists and surgeons, were largely responsible for the development of topographic anatomy in Russia. As a result of Pirogov's work, Russian medicine, particularly anatomy, developed rapidly and acquired an international reputation.

*N. I. Pirogov* (Pirogoff) (1810-1881) in particular was responsible for the creation of topographic anatomy. His work *Surgical Anatomy of Vascular Trunks and Fascia* (1837) brought him world-wide fame. He introduced the technique of "ice anatomy", a method based on examination of successive sections of frozen cadavers. Pirogov's *Complete Course of Applied Anatomy* (1844) and the atlas *Topographic Anatomy in Sections Through Frozen Cadavers* (1859) are based on this method. These were the first manuals of topographic anatomy.

Pirogov, whose general outlook was that of a natural-scientific materialist, emphasized its immense importance for surgery. At the same time he showed that surgery in turn influenced anatomy, and together with Buyalsky



he initiated the applied trend in anatomy. Pirogov's approach was based on the idea of the unity of the organism and its environment as well as the unity of form and function. Pirogov stressed the importance of function and pioneered the functional trend in anatomy, which was later developed in Russia by Lesgaft and by Soviet anatomists.

Pirogov's application of anatomy to surgery gave him a reputation that exceeded that of many celebrated European surgeons. It was Pirogov, for example, who was called in to remove the bullet from the famous Italian revolutionary Garibaldi.

Pirogov's creative work formed an epoch in the development of medicine and anatomy. After Pirogov's death his body was embalmed by Vyvodtsev, and sixty years later re-embalmed by Soviet anatomists.

Pirogov organized the Anatomical Institute in the Medico-Surgical Academy and invited W. L. Gruber, the Prague anatomist, to work with him. Russia became Gruber's second homeland.

*Wenceslaus Leopold Gruber* (1814-1890) collected many specimens demonstrating the variants and anomalies of different organs and expanded considerably the museum established in the institute by Zagorsky and Buyalsky. Gruber's work enriched descriptive anatomy with a number of new anatomical facts. A medal, with the inscription "To the teacher of eight thousand Russian physicians", was stamped in his honour.

## THE IDEA OF NERVISM IN APPLICATION TO ANATOMY

A progressive trend in Russian medicine called nervism became firmly established in the second half of the nineteenth century.

Nervism is the conception of the integrity of the organism, of its unity with the external environment. According to this theory, the nervous system, particularly the most highly developed organ, the brain, is primarily responsible for the unification of the individual organism into an organic whole in connection with the external environment. The nervous system is thus in charge of all the processes of the individual organism. According to I. P. Pavlov, nervism is a physiological tendency to spread the influence of the nervous system to as many activities of the organism as possible.

The idea of nervism originated in Russia in the eighteenth century and became the basis for the development of Russian medicine. Lomonosov's materialistic ideology formed its philosophic basis: his atomistic theory of the structure of matter, his discoveries of various laws of physics and chemistry, and his concept that in the organism "all mutually connected parts have a single causative origin, as of a single whole".

At Lomonosov's initiative a university was established in Moscow in the middle of the eighteenth century (1755) where *S. G. Zybeline* worked. Zybeline applied Lomonosov's general philosophic views to the understanding of the human organism and advanced the proposition that the psyche was the result of the movement of atoms and was dependent on the conditions of life. This idea paved the way for the study of the effect of the environment on the psyche and for establishment of preventive trend in medicine. The ideas voiced by Zybeline marked the first sources of nervism. Later, Radishchev spoke of the unity of the spirit and body and showed the difference in the importance of sound and word for man. He showed the importance of words for improving mankind and thus provided the basis for the development of I. P. Pavlov's theory of the two signalling


systems (see below). Zybeline and Radishchev explained the integrity of the organism by the unity of the physical and psyche. *E. O. Mukhin* (1766-1850), a professor of anatomy at Moscow University, attributed it, in contrast, to the activity of the nervous system, the brain in particular. He indicated three components of that part of the reflex arc which Pavlov later called the analyser. In studying the anatomy of the central and peripheral nervous system, Mukhin discovered some of its mechanisms: he suggested that the brain is concerned with a trophic function, and he was the first anatomist to apply the idea of nervism to anatomy. His brilliant discussion of the significance of anatomy for medicine, in his seven-volume *Course in Anatomy*, played a decisive role in the formation of Buyalsky's and Pirogov's ideas. Buyalsky claimed that the brain, the organ of mental activity, develops under the effect of external stimuli. He also pointed out that all vegetative processes are accomplished by "a system of ganglionic nerves" (i.e. the vegetative system) subordinate to the brain, and he applied the principle of nervism to his study of the digestion process. Buyalsky's approach to the question of nerve endings was developed later by neurohistologists.

Pirogov considered the organism as an integral whole controlled by the nervous system. He believed the reflex (in which he distinguished three components) to be the main mechanism of vital processes. Pirogov's ideas were a link connecting the nervism of I. M. Sechenov and I. P. Pavlov with the pre-Sechenov nervism.

The ideas of the revolutionary democrats A. I. Gertsen (Herzen), V. G. Belinsky, N. G. Chernyshevsky, N. A. Dobrolyubov, and D. I. Pisarev greatly influenced the development of the idea of nervism in the middle of the nineteenth century. The question of whether the brain was a substrate of neuropsychic activity was an issue of ideological debate at the time. The revolutionary democrats answered the question affirmatively. They regarded the organism as an integral whole inseparably linked to the environment. In their opinion, the spirit and body are in unity, and the spirit is the function of the body organ, the brain. The brain is the most important part of the organism, which regulates all its processes. The ideas of the physiologists I. M. Sechenov and I. P. Pavlov formed under the influence of the revolutionary democrats.

The works of the "Father of Russian Physiology" *I. M. Sechenov* greatly advanced the ideas of nervism in the middle of the nineteenth century. Sechenov hypothesized that the life of an organism was impossible without the environment sustaining its existence and that the environment should therefore be included in the scientific definition of the organism. In his epoch-making work *Reflexes of the Brain* (1863), he showed that the most complicated forms of nervous activity are in essence reflexes in origin. Thus the brain was established as an organ of mental activity from the physiological standpoint as well. Anatomical proof of the unity of structure and function of the brain was needed.

The proof was supplied by a professor of anatomy at Kiev University *V. A. Betz* (1834-1894), who discovered giant pyramidal cells (Betz's cells) in the fifth layer of the cerebral cortex and detected the difference in the cell composition of different areas of the cerebral cortex. On these grounds he suggested a new principle for dividing the cortex into parts, the principle of cellular structure, and laid the foundation for the science of cytoarchitectonics of the cerebral cortex (Betz also systematized all information on osteogenesis



V. A. Betz

and discovered the chromaffin system). As a materialist Betz opposed religious prejudices and racism.

*D. N. Zernov* (1843-1917), a professor at Moscow University, was another anatomist who contributed greatly to the knowledge of brain anatomy. He suggested the best classification of the sulci and gyri of the brain. Zernov proved that the brain structure of different nationalities, including that of so-called "backward" races, was identical. In this way Zernov offered an anatomical basis for the fight against racism. As a materialist he spoke against Lombroso's idealistic theory of the congenital anatomical substrate of crime. Zernov's work *Manual of Descriptive Human Anatomy* ran into fourteen editions (the last was published in 1939).

The eminent neurologist and psychiatrist *V. M. Bechterew* (1857-1927) contributed richly to the study of the anatomy of the brain and spinal cord. He expanded the knowledge of the localization of functions in the cerebral cortex, expounded more thoroughly the reflex theory, and formed the anatomical and physiological basis for the diagnosis and clinical picture of nervous diseases. Bechterew discovered various cerebral centres and tracts, which bear his name, and wrote the fundamental work *The Conducting Pathways of the Brain and Spinal Cord* (1894).

Thus, precise anatomical and physiological facts were known at the time of publication of *V. I. Lenin's* great work *Materialism and Empirio-Criticism* (1909). In a chapter of the book entitled "Does Man Think with the Help of the Brain?", Lenin emphasized that thought is the function of the brain. In this work Lenin developed the theory of reflection, according to which the brain can be considered an organ reflecting reality.

The idea of nervism was finally completed in the works of *I. P. Pavlov*, who showed the leading role of the nervous system, the cerebral cortex in particular, in forming the organism as an integral whole and uniting it with the environment. The ideas that were theoretically substantiated and elaborated by *I. M. Sechenov* in experiments and by *S. P. Botkin* in the clinic were completely formulated by Pavlov in his study of the reflex character of cerebral activity and of conditioned reflexes.


Though Pavlov was a physiologist, he nonetheless contributed much valuable information to the study of anatomy, especially to the study of the nervous system. He changed radically the concept of the brain centre and the cerebral cortex and showed that the entire cortex of the cerebral hemispheres, the motor zone included, was an aggregate of perceiving centres. He greatly extended the idea of the localization of functions in the cerebral cortex, introduced the concept of the analyser, and established the theory of the two cortical signalling systems. Pavlov also gave more precise ideas of the peripheral nervous system (triple nervous control, innervation of the heart, etc.). Pavlov's teaching as a whole is the natural-scientific basis of Lenin's theory of reflection and the philosophy of dialectical materialism.

At the beginning of the twentieth century, the centre of the proletarian revolutionary movement was transferred to Russia, which also became the centre of progressive scientific thought. During this period, Leninism, the highest achievement of world culture, also developed. By this time, Sechenov, Botkin, and Pavlov had supplied medicine with a firm materialistic foundation, the theory of nervism.

*K. A. Timiryazev* and *I. V. Michurin* developed Darwinism in biology and changed it from a science which simply explained organisms to one which transformed them. This new line of thought in evolutionary science had an adverse effect on the old descriptive anatomy, which was concerned only with the description of structures without discussing their development or function and which was restricted to a contemplative, passive attitude to nature and man. The first serious challenge to descriptive anatomy was made by *P. F. Lesgaft* (1837-1909), who, after *Pirogov*, was the greatest anatomist of pre-revolutionary Russia.

Lesgaft was brought up on the ideas of the revolutionary democrats and Lamarck and produced anatomical proof of the influence of the environment on the human organism. Proceeding from the idea of the unity of the organism and the environment and believing that acquired characters were heritable, Lesgaft argued that physical education can have a direct effect on the human organism. This hypothesis thus linked anatomy with the practice of physical culture and sports. Instead of the passive, contemplative attitude to the human organism, the study of anatomy acquired an effectual character in Lesgaft's hands.

Lesgaft used the experimental method of research extensively. He advocated the study of the anatomy of living persons, and was among the first to use X-rays in anatomy. He contributed much new information to our understanding of the anatomy of the motor apparatus, viscera, and vessels. He did not, however, restrict himself to simple description of the facts but ex-



P. F. Lesgaft

pounded the general regular features in the structure of the human body in his work *Osnovy teoreticheskoi anatomii* (*Fundamentals of Theoretical Anatomy*) (1892).

All Lesgaft's works were based on materialistic philosophy and on the idea of the unity of the organism and its environment. By stressing the unity of form and function, Lesgaft supplied the foundation for a new trend in anatomy, the functional trend. Lesgaft criticized sharply the reactionary views in biology and the limited scope of the descriptive method which still prevailed in anatomy. All his life Lesgaft was attacked by reactionary elements and persecuted by the tsarist government for his progressive ideas. The functional trend in anatomy created by Lesgaft was developed further by his pupils and followers, particularly A. P. Protasov, P. A. Zagorsky, and N. I. Pirogov.

"Age anatomy", the science of the age characteristics of the organism, began developing at the beginning of the nineteenth century under the influence of evolutionary theory. It was founded by N. P. Gundobin (1860-1908) who, as a paediatrician, devoted much of his attention to the study of the anatomy and physiology of children. In the Soviet period, E. I. Valker (1893-1955), P. O. Isaev (1895-1961), and V. I. Puzik conducted special investigations into the development of organs after birth.

Biology and medicine in Russia were, therefore, sufficiently well developed at the beginning of the twentieth century by the time of the Great October Socialist Revolution. Several progressive trends were established in anatomy.

1. The functional trend, associated with the names of A. P. Protasov, P. A. Zagorsky, N. I. Pirogov, P. F. Lesgaft, and V. N. Tonkov (see below).

2. The applied trend, associated with the names of I. V. Buyalsky and N. I. Pirogov, in particular, and with that of V. I. Shevkunenko (see below).

3. The evolutionary trend, which was based on the tenets of Darwinism (A. N. Severtsov).

4. The idea of nervism, the development of which can be attributed firstly to S. P. Botkin, I. M. Sechenov, and I. P. Pavlov and to the anatomists V. A. Betz, D. N. Zernov, and V. M. Bechterew.

These trends, particularly the functional trend, developed in opposition to the old descriptive anatomy, which was founded on metaphysical and mechanistic materialism and Virchowianism.

There were only thirteen departments of anatomy in Russia on the eve of the Great October Socialist Revolution. They were headed by the leading anatomists of the country, among them V. N. Tonkov (Kazan), G. M. Iosifov (Tomsk), V. P. Vorobyev (Kharkov), and D. N. Zernov (Moscow) stood out. Almost all of them lived to the Great October Socialist Revolution and were given full scope for their activity, the range of which grew truly only under conditions of Soviet power.

## ANATOMY IN THE USSR

As a result of the Great October Socialist Revolution the proletariat, the progressive revolutionary class, replaced the ruling bourgeoisie. Exceptional conditions were thus created for the flourishing of science and higher education. The number of medical institutes grew rapidly in the first decade alone from 13 to 35. Today there are more than 80. The progressive ideology of the proletariat, dialectical materialism, began penetrating deeply into the study of biology and medicine. Reorganization also occurred in anatomical science, anatomy acquired new life and direction on the path of progressive development. This development was promoted by resolutions of the Communist Party on ideological problems, which guided science in building communism.

Soviet anatomists and anthropologists waged a decisive attack on the so-called theory of "racism" developed by reactionary bourgeois scientists along imperialistic lines.

The most prominent Soviet anatomists are as follows.

V. P. Vorobyev (1876-1937), academician, professor of anatomy at the Kharkov Medical Institute, studied the human organism in association with the external environment. Using the binocular magnifying glass, he elaborated the stereomorphological method for studying the construction of organs and laid the foundation for macro-microscopic anatomy, of the peripheral nervous system in particular. Vorobyev wrote several textbooks of anatomy and published the first *Soviet Atlas of Anatomy* in five volumes. He developed (jointly with B. I. Zbarsky) a special preservation method by means of which the body of V. I. Lenin was embalmed and preserved for successive generations. This was Vorobyev's great service to the Soviet people and to the workers of all countries. Vorobyev also established a school of Soviet anatomists, one



V. P. Vorobyev

of whom, *R. D. Sinelnikov*, succeeded him in the department and is developing successfully the work of his teacher in the field of embalming and macro-microscopic anatomy; Sinelnikov is also the author of an excellent *Atlas of Anatomy*.

*V. N. Tonkov* (1872-1954), Member of the USSR Academy of Medical Sciences, professor at the Military Medical Academy, performed experiment on living animals to study the vascular system and was the next after Lesgaft to create experimental (functional) anatomy. Tonkov elaborated the science of collateral circulation jointly with his pupils (among whom were *B. A. Dolgo-Saburov*, *G. F. Ivanov*, and others). Tonkov wrote a textbook of anatomy, which has run into six editions, and established a large school of Soviet anatomists. An eminent representative of this school and Tonkov's successor in the department was *B. A. Dolgo-Saburov* (1900-1960) who developed his teacher's pursuit successfully with his colleagues. After the discovery of X-rays, Tonkov was among the first scientists to use them (1896) in studying the skeleton. He marked the path along which the Soviet anatomists *A. S. Zolotukhin* and then *M. G. Prives* and his colleagues as well as radiologists (*Rokhlin* and others) developed a new branch of anatomy called X-ray anatomy.

*V. N. Shevkunenko* (1872-1952), Member of the USSR Academy of Medical Sciences, professor of topographic anatomy at the Military Medical Academy, developed further the applied trend in anatomy established by *N. I. Pirogov*. He developed the study of extreme forms of individual variability with his pupils and showed its significance for surgical practice. Variants of the structure of the nervous and venous systems which Shevku-



V. N. Tonkov

nenko had studied in detail were expounded in the large *Atlas of the Peripheral Nervous and Venous Systems* for which he and his pupil and successor in the department A. N. Maksimenkov were awarded the USSR State Prize. Shevkunenko used the facts of phylogenesis and ontogenesis in explaining the different variants of the structure of the nervous system and in this way developed the evolutionary trend in anatomy.

G. M. Iosifov (1870-1933), professor of anatomy at the Tomsk Medical Institute and later at the Voronezh Medical Institute, contributed considerably to the knowledge of the anatomy of the lymphatic system. His monograph *Anatomy of the Lymphatic System* (1930) brought him world-wide fame and demonstrated the high level of Soviet anatomy. Iosifov established a school of anatomists, an outstanding representative of which is D. A. Zhdanov. On the basis of his own work and the work of his colleagues, Zhdanov published various important monographs dealing with the functional anatomy of the lymphatic system. One of the monographs, *Surgical Anatomy of the Thoracic Duct* (1945), was awarded the USSR State Prize.

Much has been accomplished in the Soviet Union in the field of the anatomy and X-ray anatomy of the lymphatic system. For instance, M. R. Sapin, Zhdanov's pupil, Corresponding Member of the USSR Academy of Medical Sciences, developed the study of the anatomy of the lymphatic system with his colleagues. Zhdanov studied the lymph nodes in particular and showed them to differ in morpho-functional properties in various regions of the organism.

Another pupil of D. A. Zhdanov, professor A. V. Borisov, head of the department of normal anatomy at the Leningrad Medical Institute of Sanita-





V. N. Shevkunenko

ry Hygiene, studied thoroughly the anatomy of the lymph capillaries. Other pupils of Zhdanov in Leningrad also contributed to the advancement of research into the anatomy of the lymphatic system. Professor *M. G. Prives* (First Leningrad Medical Institute) first elaborated (1933) the X-ray method for examining the lymphatic system and made the first radiographs of the lymph vessels and nodes of a living person. His monograph *Radiography of the Lymphatic System* (1948) was the first generalizing work in the field of X-ray anatomy of this system. *Yu. I. Borodin*, Member of the USSR Academy of Medical Sciences, head of the department of normal anatomy at the Novosibirsk Medical Institute, contributed much information to the study of the anatomy and X-ray anatomy of the lymphatic system, the lymph nodes in particular. With his pupils he showed that the X-ray anatomical picture of the lymph nodes varies according to the regional and individual features of their structure and the level of functional activity of the organs that are drained. Borodin also proved that the lymph flows into the blood not only at the sites where the lymph ducts drain into the veins, but also in the lymph nodes, where most of the lymph enters the venous tract. In phlebohypertension, in contrast, part of the blood enters the lymph sinuses, which is one of the mechanisms of compensation in venous hypertension.

*E. A. Vyrenkov* (Ivanovo) greatly advanced the study of the anatomy of the lymphatic system. His son *Yu. E. Vyrenkov* (Central Institute of Postgraduate Medical Training, Moscow) developed his farther's teaching further and contributed richly to the study of the structure, function, and topography of the lymph vessels and nodes.

Professor *V. V. Kupriyanov*, Member of the USSR Academy of Medical Sciences, from the department of normal anatomy at the Second Moscow Medical Institute, used his original modification of the non-injection method for the examination of vessels to study thoroughly the anatomy of the microcirculation channel. With his pupils Kupriyanov distinguished exactly five of the channel's links. He was awarded the USSR State Prize for this work. His pupil *N. I. Karaganov* demonstrated the connection between the blood and lymph capillaries and produced a model containing six links of the microcirculation channel, including the lymphatic link. He also showed the anatomical connections between the paths of movement of blood, lymph, and interstitial fluid in the microcirculation channel.

*S. S. Mikhailov* (of the department of anatomy at the Moscow Stomatological Institute) wrote a textbook of anatomy for stomatologists, dealing with the topography and anatomy of the cerebral veins in particular. He also contributed richly to the study of the anatomy of the arteries of the heart, veins of the brain, and topography, for which he was awarded the *V. P. Vorobyev* prize.

Professor *M. G. Prives* (of the department of normal anatomy at the First Leningrad Medical Institute) with his colleagues conducted research into the anatomy of intraorganic vessels and advanced the study of the effect of the nervous system on collateral circulation (*R. A. Bardina*). They introduced various new trends in anatomical science. These are as follows.

1. The study of the anatomy of persons of various occupations: the effect of various professions, sports (sports anatomy), and space travel (aviation-space anatomy) on the structure of the bone and vascular systems.

2. The study of the influence of social factors on the individual variability of the skeleton.

3. *M. G. Prives* also developed a method for preserving cadavers and individual parts of the body without the use of formaldehyde. The method produces dry specimens which need not be kept in solution and maintain their structure, natural colour, consistency, elasticity, and bulk for more than twenty-five years. Specimens prepared according to this method are kept at the anatomical museum of the First Leningrad Medical Institute, which enjoys a reputation as one of the best in the world.

Various anatomists promoted the development of sports anatomy and anthropology.

*P. I. Karuzin* (1864-1939) published a valuable *Dictionary of Anatomical Terms* (1928). His research in the field of anatomy of the nervous system was developed further in the works of *A. A. Deshin* and his successor in the department *V. N. Ternovsky*. *A. A. Deshin* (1869-1946), professor at the Second Moscow Medical Institute, extended the knowledge of the brain conduction tracts and the vegetative nervous system. *V. N. Ternovsky*, Member of the USSR Academy of Medical Sciences and of the International Academy of the History of Medicine, is famous not only for his work on the anatomy of the nervous system but for his research into the history of anatomy and the translation of *Vesalius'* and *ibn-Sina's* books into Russian. *Ternovsky's* translation of the *Vesalius'* work is the only extant translation

since that by E. Slavinetsky in the seventeenth century has not survived.

*N. K. Lysenkov* (1865-1941), professor at Odessa University, was engaged in all the main branches of anatomical study concerned with the normal structure of man: normal topographic and plastic anatomy. He wrote various manuals on these subjects, one of which *Normal Human Anatomy* (co-authored by V. I. Bushkovich in 1932) has run into five editions. *Ya. B. Zeldovich* (1870-1949), professor of the Second Leningrad Medical Institute, was among the first to apply X-rays to the study of anatomy, and also trained a brilliant group of anatomists. An eminent representative of this school, *S. N. Kasatkin*, professor at the Volgograd Medical Institute, conducted research into the anatomy of the digestive organs and their vessels with his colleagues.

Various other Soviet anatomists deserve mention for their successful research into the anatomy of the motor apparatus, the respiratory organs, the urogenital organs, the blood-vascular system, the lymphatic system, the nervous system, and the organs of sense.

*S. I. Lebedkin* and his pupils contributed to the study of embryology. A prominent representative of this school, *D. M. Golub*, professor at the Minsk Medical Institute, Member of the Byelorussian Academy of Sciences, conducted valuable research with his colleagues into the anatomy and embryology of the vegetative nervous system and the reinnervation of the organs. He also published a specialized textbook on the development of the nervous system. The work of A. G. Knorre and P. G. Svetlov in embryology is also notable.

Soviet anatomy is successfully developing the best traditions of pre-revolutionary Russian anatomy on the basis of the progressive philosophy of dialectical materialism.

# Author Index

- Aristotle, 20, 21  
Aselli, Gaspar, 30
- Baer, K.M., 33  
Bechterew, V.M., 42  
Betz, V.A., 41  
Bichat, Marie François Xavier,  
31, 51  
Borisov, A.V., 47  
Borodin, Yu.I., 48  
Buyalsky, I.V., 38
- Colombo, Realdo, 29  
Crompecher, 97
- Darwin, Charles, 34, 62, 63, 64  
Davies, 123, 125, 127, 146  
Deshin, A.A., 49  
Dolgo-Saburov, B.A., 46, 107
- Efroimson, V.P., 60  
Engels, Friederich, 15, 17, 25,  
35, 58, 62, 63  
Erasistratus, 21  
Eustachio, Bartolomeo, 28  
Fabricius ab Aquapendente,  
Hieronymus, 29  
Fallopia, Gabriele, 27
- Galen, Claudius, 22  
Golub, D.M., 50  
Gruber, W.L., 40  
Gundobin, N.P., 44
- Harvey, William, 28, 29  
Heraclitus, 19
- Herophilus, 21  
Hippocrates, 19, 20
- Ibn-al-Nafiz, 25  
Ibn Sina (Avicenna), 24  
Iosifov, G.M., 47
- Karaganov, N.I., 49  
Karuzin, P.I., 49  
Kasatkin, S.N., 50  
Kovalevsky, A.O., 34  
Kupriyanov, V.V., 49
- Lamarck, Jean Baptiste, 33  
La Mettrie, Julien Offroy, 31  
Lebedkin, S.I., 50  
Lenin, V.I., 42  
Lesgaft, P.P., 43, 107  
Linnaeus, Carolus, 33  
Lomonosov, M.V., 36, 40  
Lysenkov, N.K., 50
- Malpighi, Marcello, 30  
Marx, Karl, 15, 16  
Maximovich-Ambodik, N.M.,  
36  
Metchnikoff, E.I., 34  
Mikhailov, S.S., 49  
Morgagni, Giovanni Batista,  
31, 51  
Mukhin, E.O., 41, 59
- Pavlov, I.P., 43, 58, 60, 87  
Pirogov, N.I., 39, 40  
Plato, 20
- Protasov, A. P., 36,  
Purkinje, Johannes, 32
- Radishchev, A.N., 36, 40  
Rokhlin, G.D., 108  
Ruysch, Frederik, 30
- Sapin, M.R., 47  
Sechenov, I.M., 41  
Servetus, Miguel, 29  
Severtsev, A.N., 34  
Shchepin, K.I., 36  
Shein, M.I., 36  
Shevkunenko, V.N., 46  
Shumlyansky, A.M., 30, 36  
Sinelnikov, R.D., 46
- Ternovsky, V.N., 49  
Tonkov, V.N., 46  
Tsargorodtsev, 59,
- Vesalius, Andreas, 26, 29  
Vinci, de Leonardo, 25  
Virchow, Rudolf, 32, 51  
Vorobyev, V.P., 45  
Vyrenkov, E.A., 48  
Vyrenkov, Yu.E., 48
- Wolff, C.F., 33
- Zagorsky, P.A., 37  
Zeldovich, Ya.B., 50  
Zernov, D.N., 42  
Zhdanov, D.A., 47  
Zybelin, S.G., 40

# Subject Index

- Abdomen, 78  
abduction, 121  
acetabulum, 238  
acinus, 511  
acromion, 214  
acropodium, 208  
adduction, 121  
adenoids, 417  
aditus, laryngis, *see also* larynx,  
inlet, 492  
orbitae, 193  
adrenal gland, 592  
cortex, 592, 597  
function, 593  
medulla, 592  
adulthood, 78  
age periods, 77  
allantois, 67, 75, 575  
alveoli of lungs, 511  
amnion, 67, 75  
amphiarthroses, 121, 127  
ampulla, or bile duct, 644  
rectal, 453  
of vas deferens, 547  
anatomical snuffbox, 354  
anatomy, age, 14, 44  
applied, 15, 45  
comparative, 14  
descriptive, 13  
dynamic aspect, 16, 122  
evolutionary aspect, 14, 47  
functional aspect, 15, 44  
macroscopic, 17  
microscopic, 17  
normal, 16  
pathological, 16  
plastic, 16  
regional, 16  
relief, 16  
sport, 16, 111  
study of, methods, 18  
surgical, 16  
systematic, 15  
topographic, 16  
X-ray, 16  
angle(s), of mandible, 186  
of parietal bone, 175  
of scapula, 214  
subpubic, 242  
of tooth, sign, 400  
vertebral, 138, 141  
angulus, costae, 151, 153  
pubicus, 247  
ventriculi, 428  
animal world, classification,  
61  
anomaly, 83  
ansa, 533  
anteflexio uteri, 566  
anteflexion, 126  
anteversio uteri, 566  
anthropogenesis, 14  
anthropology, 14  
anatomical, 16  
antrum, Highmori, 180  
pyloricum, 428  
anulus, femoralis, 379  
fibrosus, 143  
tympanicum, 171  
anus, 454  
apertura pelvis, 243  
aperture(s), of nose, 193  
piriform, 199  
of sphenoid sinus, 167  
aponeurosis, 283  
epicranial, 326  
m. biceps brachii, 336, 350  
palmar, 339, 352  
plantar, 376  
apophyses, 99  
apparatus, 56  
appendices epiploicae, 448  
appendix, of testis, 544  
vermiformis, *see also* process  
vermiform, 449  
arbor vitae, 564  
arch(es), alveolar, 181, 187,  
branchial, 158, 160  
of foot, 271  
hyoid, 158, 161  
mandibular, 158  
palatoglossal, 394  
palatopharyngeal, 394  
superciliary, 176  
vertebral, 132, 138  
zygomatic, 185  
arcus, iliopectineus, 378  
pubis, 247  
tendineus m. solei, 368  
venosus juguli, 322  
area(e), gastricae, 431  
intercondylaris, 254  
articulation(s), *see also* joint(s)  
115  
consecutive, 127  
contiguous, 115, 124  
humeroradial, 224  
humeroulnar, 224  
interrupted, 116  
parallel, 127  
radioulnar distal, 227, 232  
proximal, 225  
synovial, 118  
atlas, 133  
autopodium, 208  
axial rudiment complex, 68  
axis, 134  
constructional, of upper limb,  
220  
axon, 54  
Basiopodium, 208  
bladder urinary, 540  
coats, 541  
development, 527  
nerves, 543  
vessels, 543  
blastocoele, 67  
blastomeres, 66  
bodies, chromaffin, 594  
para-aortic, 594  
body, build, 81, 83  
coccygeal, 596  
carotid, 594  
height, 79  
planes, 84  
proportions, 79  
Wolffian, 572  
bone(s), 90  
age changes, 91, 104  
blepiphyseal, 101  
capitate, 228, 230  
carpal, 227  
chemical composition, 91  
cuboid, 209, 263  
cuneiform, 263  
development, 95, 103, 162,  
effect of occupation on, 108  
effect of social and biological  
factors on, 113  
ethmoid, 162, 177,  
flat, 91, 101  
of fontanelles, 191  
of forearm, 221, 223  
frontal, 162, 175  
growth, 99  
hamate, 209, 228, 230  
of hand, features typical of  
modern man, 237  
ossification, 229  
radiographs, 236  
hyoid, 161, 169  
interparietal, 164, 191  
lacrimal, 162, 183  
long, 101  
lunate, 227, 230  
membrane, 90, 95  
metacarpal, 229  
metatarsal, 263  
mixed, 102  
monoepiphyseal, 101  
nasal, 162, 183  
navicular (of foot), 263  
navicular (of hand), 209  
occipital, 163  
palatine, 162, 182  
parietal, 162, 175  
pisiform, 227  
scaphoid, 227  
sesamoid, 101, 264, 283  
short, 101  
sphenoid, 162, 165  
spongy, 91, 101  
structure, 91  
supernumerary (of foot), 265  
sutural, 191

- bones  
   tables, 93  
   temporal, 162, 169  
   of toes, 264  
   trapezium, 228, 230  
   trapezoid, 228, 230  
   triquetral, 227, 230  
   tubular, 91, 101  
   turbinate, 162, 183  
   wormian, 191  
   X-ray examination, 102  
   zygomatic, 162, 185  
 bone marrow, 93  
   red, 93, 100  
   yellow, 94, 100  
 bouquet, anatomical, 172  
 breast-bone, *see also* sternum, 129, 150  
 bronchi, 503  
   development, 523  
   lobar, 507  
   lobular, 511  
   principal, 503  
   segmental, 507  
 bronchioles, respiratory, 507, 511  
   terminal, 507, 511  
 bronchoscopy, 506  
 bulb, duodenal, 440  
   of penis, 553  
   of vestibule, 571  
 bursa(e), anserina, 362  
   bicipitoradialis, 336  
   deep infrapatellar, 259  
   hepatic, 475  
   iliopectinae, 357  
   ischiadica m. obturatorii interni, 360  
   omental, 475  
   pregastric, 475  
   subcutaneous prepatellar, 259  
   subdeltoid, 332  
   subfascial prepatellar, 259  
   subscapularis, 335  
   subtendinea m. subscapularis, 220  
   subtendineous prepatellar, 259  
   suprapatellar, 257  
   synovial, 119, 286  
   tendinis calcanei, 368  
   trochanterica m. glutei, 358, 359  
 Caecum, 449, 485  
 calcaneus, 262  
 calvaria, *see also* skull-cap 156, 159  
 calyces, 536  
 canal(s), alimentary, 367, 389  
   alveolar, 181  
   anal, 453  
   carotid, 174  
   evacuation, 433  
   femoral, 379  
   greater palatine, 195  
   Haversian, 91  
   incisive, 181, 200  
   infraorbital, 181  
   inguinal, 309  
   lesser palatine, 183  
   mandibular, 187  
   musculotubal, 173  
   nasolacrimal, 180, 193, 202  
   obturator, 243  
   optic, *see also* canales optici, 193, 196  
   pterygoid, 167, 195  
   pyloric, 428  
   sacral, 137  
   vertebral, 132  
   Volkmann's, 91  
   canales optici, *see also* canal(s), optic, 166  
 canalis, adductorius, 379  
   carpalis, 353  
   carpi radialis, 353  
     ulnaris, 353  
   condylaris, 165  
   cruropopliteus, 379  
   facialis, 174  
   humeromuscularis, 353  
   hypoglossi, 165  
   musculoperoneus, 379  
   n. radialis, 353  
   obturatorius, 378  
 canine(s), 403, 404  
 capillaries, respiratory, 512  
 capitis femoris, 250  
 capitulum (of humerus), 218  
 capsule, articular, 119  
   Shumlyansky-Bowman, 532  
 carpus, 227  
 cartilage(s), articular, 95, 99, 118  
   arytenoid, 494  
   corniculate, 495  
   cricoid, 493  
   cuneiform, 495  
   epiglottis, 495  
   epiphyseal, 95  
   intra-articular, 120  
   metaepiphyseal, 99  
   nasal, 491  
   semilunar, 256  
   thyroid, 493  
 cartilago triticea, 496  
 caruncula(e), hymenales, 569  
   myrtiformes, 569  
   sublingualis, 393  
 cavity, abdominal, 426  
   axillary, 352  
   cerebral, 162  
   glenoid, 214  
   infraglottic, 501  
   joint, anatomical, 139  
   X-ray, 139  
   of larynx, 500  
   medullary, 93, 99, 102, 108  
   nasal, 162, 199, 388, 483, 489  
   oral, 388, 391  
   pelvic, 243, 426  
   peritoneal, 471, 475  
   pharyngeal, 417  
   pleural, 517  
   thoracic, 164  
   tympanic, 171  
   cavum vaginale, 551  
 cellulae, ethmoidales, 178  
   mastoidea, 174  
 centrum perineale, 577  
 cheeks, 392  
 chest, types, *see also* thorax, 164  
 chiasma, 166  
   tendineum, 340  
 chin, 187  
 choanae, 185, 197, 199  
 chorda, *see also* notochord, 68  
   90  
 chorion, 67, 75  
 circulation, placental, 77  
   vitelline, 76  
 circumduction, 121  
 circumferentia articularis, 221  
 clavicle, *see also* collar bone, 213  
   X-ray, 216  
 cleavage, 66  
 clitoris, 571  
 clivus, 165  
 cloaca, 388, 575  
 coccyx, 138  
 coelom, 72, 387  
 collar bone, *see also* clavicle, 208  
 colliculus seminal, 555  
 colon, ascending, 447, 451, 485  
   descending, 447, 452, 485  
   sigmoid, 447, 452, 480, 485  
   transverse, 447, 452, 485  
 coloscopy, 570  
 column(s), renal, 529  
   vertebral, *see also* vertebral column  
 columnae rugarum, 569  
 compact substance of bone, 92  
   96, 99, 102, 108  
 conchae, nasal, 178, 183  
 condyle(s), 125  
   of femur, 248  
   occipital, 165  
   of tibia, 253  
 conjugata vera, 244  
 connexus intertendineus, 344  
 constitution, 81  
   types, 82  
 conus elasticus, 496  
 cord(s), oblique, 227  
   spermatic, 544, 547, 551  
   umbilical, 76  
   vocal, 501  
 cornua, coccygea, 138  
   sacralia, 138  
 corona glandis, 554  
 corpora cavernosa penis, 552  
 corpus, adiposum buccae, 392  
   albicans, 561  
   luteum, 561  
   spongiosum penis, 553  
 corpuscle, renal, 532  
 cranium, cerebral, 156, 162  
   premodiale, 159  
   visceral, 156, 158, 162  
 crest(s), conchal, 180  
   ethmoidal, 181  
   frontal, 176  
   iliac, 239  
   infratemporal, 167  
   intertrochanteric, 248  
   lacrima, 181  
   nasal, 181, 183  
   neural, 69  
   occipital, 165  
 crista(e), buccinatoria, 188  
   ethmoidalis, 183  
   sacralis, 137  
   sphenoidalis, 166  
   tuberculi majoris et minoris, 217  
 crura, penis, 522  
   of thoracoabdominal diaphragm, 299  
 curvature(s), of stomach, 428  
   spinal, 148  
   of tooth, sign, 400  
 cystoscopy, 542  
 cytology, 17  
 Darwinism, 33  
 deglutition, 420  
 dendrites, 54  
 dens, 134, 140  
 dermatome, 60, 71

- diaphragm, pelvic, 576, 579  
   thoracoabdominal, 299  
   X-ray, 525  
   urogenital, 576  
 diaphragma oris, 319, 392  
 diaphysis, 98, 100, 102  
 diarthrosis, 116, 118  
 dilators, 326  
 Diogenes cup, 238  
 diploe, 92  
 disc(s), articular, 191  
   interpubic, 242  
   intervertebral, 143  
 distantia, cristarum, 244  
   spinarum, 244  
   trochanterica, 244  
 diverticulum Meckel's, 443  
 duct(s), alveolar, 511  
   bile, common, 465  
   cystic, 465  
   hepatic, common, 465  
   mesonephric, 572  
   Muellerian, 573  
   pancreatic, 470  
   accessory, 471  
   paramesonephric, 573  
   prostatic, 559  
 ductules, bile, 463  
   interlobar, 463  
   papillary, 533  
 ductuli aberrantes, 546  
 ductus, choledochus, 465  
   cysticus, 465  
   deferens, 546  
   efferentes testis, 546  
   ejaculatorius, 547  
   excretorius, 547  
   parotideus, 415  
   submandibularis, 416  
 duodenum, 438, 440  
   development, 485  
   shapes, 442  
   X-ray, 440  
 dura mater, 176  
  
 Ectoderm, 68, 73  
   primary, 69  
   skin, 70  
 electromyography, 384  
 embryoblast, 66  
 embryogenesis, 14  
 embryology, 14, 33  
 eminence, arcuate, 171  
   cruciate, 165  
   iliopubic, 239  
   intercondylar, 253  
   parietal, 175  
 endocrine glands, 583  
   anatomo-physiological properties, 583  
   connection with nervous system, 584  
   development, 584  
   ectodermal, 586  
   entodermal, 586  
   mesodermal, 586, 596  
 endomysium, 277  
 endoskeleton, 89  
 endothelium, 52  
 entoderm, 67, 70  
 epicondyles, of femur, 248  
   of humerus, 218  
 epididymis, 544  
 epigastrium, 78  
 epiphyses, 98, 100  
 epistropheus, 134  
 epithellum, 52  
  
 epoophoron, 563  
 exoskeleton, 89  
 extension, 121  
  
 Fabella, 255  
 facet, articular, 134  
   costal, 134  
 falx inguinalis, 311  
 fascia(e), 284  
   antebrachial, 35  
   axillary, 302  
   brachial, 350  
   buccopharyngeal, 331  
   cervical proper, 321  
   cervicalis, 323  
   clavicopectoral, 301  
   cremasteric, 551  
   crural, 374  
   deltoid, 301, 350  
   dorsalis manus, 352  
   pedis, 376  
   endocervical, 322  
   endothoracic, 302  
   iliac, 377  
   lata, 373  
   lumbar, 295  
   masseteric, 331  
   parotid, 331  
   pectoral, 301  
   pelvic, 581  
   of penis, 554  
   of perineum, superficialis, 582  
   pharyngobasilar, 418  
   popliteal, 374  
   prevertebral, 322  
   renalis, 528  
   spermatic, external, 551  
   spermatica interna, 311, 551  
   subperitoneal, 305, 373  
   subscapular, 335  
   temporal, 331  
   thoracolumbalis, 295  
   of urogenital diaphragm, 581  
 fauces, 396  
 femur, 247  
   ossification, 248, 254  
 fibrae intercrurales, 311  
 fibres, nerve, 54  
 fibula, 254  
 fissure, horizontal, 507  
   oblique, 507  
   orbital inferior, 193, 195  
   superior, 167, 197  
   petrosquamous, 169  
   petrotympanic, 169  
   pterygoid, 167  
   sphenopetrosal, 191  
   tympanosquamous, 169  
 flexion, 121  
 flexor retinaculum, 235  
 flexure, duodeno-jejunal, 440  
   perineal, 453  
   sacral, 453  
 fluid synovial, 119  
 fold(s), alar, 258  
   aryepiglottic, 418, 500  
   caecal, 478  
   circular, 443  
   glosso-epiglottic, 411  
   infrapatellar synovial, 258  
   interarytenoid, 500  
   neural, 69  
   pharyngo-epiglottic, 411  
   rectouterine, 567  
   sublingual, 393, 416  
   synovial, 119  
  
 umbilical, 474  
 ureteric, 542  
 vestibular, 500  
   vocal, 501  
 follicles Graafian, 561  
 fontanelles, 117, 159, 190, 203  
   205  
   anterior, 203  
   mastoid, 204  
   posterior, 203  
   sphenoidal, 204  
 fonticuli, 117  
 foramen, caroticum externum, 172  
   cecum lingua, 410  
   cecum (of tooth), 403  
   epiploicum, 476  
   ethmoidal, 193  
   infraorbital, 180  
   infrapiriforme, 377  
   intervertebral, 132  
   jugular, 197  
   magnum, 162, 164  
   mandibular, 188  
   mastoid, 174  
   mental, 187  
   obturatum, 240  
   optic, 166  
   oval, 167, 197  
   palatine, greater, 183, 197  
   papillary, 529  
   parietal, 175  
   quadrilaterum, 353  
   rotundum, 195, 197  
   sacral, 137  
   sciatic, 242, 377  
   sphenopalatine, 183, 195  
   spinous, 167, 197  
   stylomastoid, 172, 175  
   supraorbitale, 176  
   suprapiriforme, 377  
   transversarium, 133  
   trilaterum, 353  
   vascular, 221  
   venae cavae, 301  
   vertebral, 132  
 foregut, 391, 483  
 foreskin, 554  
 formula, dental, 407  
 fornix, pharyngis, 417  
   of stomach, 428  
   vaginae, 569  
 fossa(e), acetabular, 238  
   axillary, 352  
   of caecum, 478  
   canine, 180  
   carotica, 319  
   condylar, 165  
   coronary, 218  
   cranial, 171, 197  
   cribriform, 374  
   cubital, 353  
   digastric, 187  
   ductus venosi, 463  
   femoralis, 380  
   hypophysialis, 166  
   iliopectinea, 379  
   infraclavicular, 297  
   inguinale, 311  
   infraspinous, 214  
   infratemporal, 195  
   ischiopectoral, 581  
   intercondylar, 248  
   jugular, 172  
   lacrimal, 176  
   of lacrimal sac, 184, 193  
   malleolar, 254  
   mandibularis, 170

- fossa(e)  
 olecrani, 218  
 palatine, 197  
 popliteal, 379  
 pterygoid, 167  
 pterygopalatine, 167, 195  
 radialis, 218  
 retrouretica, 542  
 subscapular, 214  
 supraspinous, 214  
 supravesical, 312  
 temporal, 194  
 terminalis, 556  
 tonsillaris, 395  
 transverse, 196  
 trochanteric, 247  
 trochlear, 176  
 vesicae fellae, 463  
 fovea, articularis, 134  
 pterygoidea, 188  
 foveolae gastricae, 431  
 frenulum, clitoridis, 570  
 labii, 391  
 labiorum, 570  
 linguae, 392
- Galea aponeurotica, 326  
 gall bladder, 465  
 gastroscopy, 437  
 gastrulation, 67  
 geniculum canalis facialis, 175  
 gerontology, 14  
 glabella, 176  
 gland(s), 52, 54, 390  
 alveolar, 390  
 Bartholin's, 571  
 bulbourethral, 557  
 classification, 390  
 complex, 390  
 Cowper's, 557  
 duodenal, 445  
 endocrine, *see also* endocrine glands  
 gastric, proper, 431  
 interstitial, 596  
 intestinal, 444  
 Littre's, 554  
 mixed, 390  
 of oral cavity, 414  
 parathyroid, 588  
 parotid, 415, 417  
 pineal, 591  
 pituitary, *see also* hypophysis cerebri, 589  
 pyloric, 431  
 simple, 390  
 sublingual, 416  
 submandibular, 416  
 suprarenal, *see also* adrenal gland, 591  
 thyroid, 586, 587  
 tubular, 390  
 urethral, 554  
 vesical, 542  
 vestibular, greater, 571  
 glans, of clitoris, 571  
 of penis, 553  
 glomerulus, 532  
 glomus, caroticus, 549  
 coccygeum, 596  
 groove, *see also* sulcus bicipital, 217  
 gubernaculum testis, 549  
 gum(s), 391, 398
- Haemorrhoids, 455  
 half-joint, *see also* hemiarthrosis  
 hamulus ossis hamati, 228  
 hand, development, 212  
 haustra coli, 448  
 hemiarthrosis, 115, 118  
 hiatodontia, 408  
 hiatus, aorticus, 299  
 canalis n. petrosi, 171  
 maxillary, 180  
 sacralis, 138  
 saphenus, 373, 380  
 tendineus, 340, 379  
 hilum, of kidney, 528  
 of lung, 506  
 of ovary, 560  
 hindgut, 391, 485  
 hip bone, 238  
 histogenesis, 72  
 histological differentiation, 72  
 histology, 17  
 humerus, 217  
 humulus pterigoideus, 169  
 hymen femininus, 569  
 hypogastrium, 79  
 hypophysis cerebri, 590  
 function, 591  
 hypothernar, 346
- Ileum, 440, 442  
 X-ray, 446  
 ilium, 238  
 implantation, 67  
 impression, trigeminal, 171  
 impressioes digitatae, 169, 176  
 incisor(s), 401, 403  
 incisura, acetabuli, 238  
 angularis, 428  
 cardiaca pulmonis sinistra, 507  
 fibularis, 254  
 ligamenti teretis, 462  
 pancreatis, 470  
 radialis, 221  
 scapulae, 214  
 sciatica, 239  
 thyroidea, 494  
 trochlearis, 221  
 ulnaris, 223  
 infancy, 77  
 infundibulum ethmoidale, 202  
 integration, 72  
 intersectiones tendineae, 283, 305  
 intestine large, 447  
 innervation, 459  
 mucous membrane, 449  
 muscular coat, 449  
 serous coat, 449  
 sphincters, 457  
 vessels, 458  
 X-ray, 456  
 intestine small, 74, 438  
 development, 485  
 glands, 444  
 innervation, 447  
 movements, 447  
 mucous coat, 443  
 muscular coat, 446  
 serous coat, 446  
 structure, 443  
 vessels, 447  
 X-ray, 446  
 intestinum tenue mesenteriale, 442  
 ischium, 238
- islets of Langerhans, 471, 597  
 isthmus faucium, 398
- Jejunum, 438, 442  
 X-ray, 446  
 Joint(s), *see also* articulation(s)  
 117  
 acromioclavicular, 216  
 ankle, 266  
 age changes, 265  
 radiographs, 270  
 atlanto-axial, 146  
 atlanto-occipital, 146, 382  
 ball-and-socket, 124, 126  
 biaxial, 125  
 bilocular, 122  
 biomechanics, 119  
 calcaneocuboid, 268  
 carpometacarpal, 235  
 cartilaginous, 117  
 cavity of, 119  
 anatomical, 139  
 X-ray, 139  
 Chopart's, 268  
 classification, 122  
 combined, 122  
 complex, 122  
 compound, 122  
 condyloid, 124  
 coordinating, 127  
 cotyloid, 124, 126  
 costotransverse, 153  
 costovertebral, 152  
 cricoarytenoid, 496  
 cricothyroid, 496  
 cuneonavicular, 268  
 elbow, 224  
 movements, 225  
 radiograph, 223, 226  
 ellipsoid, 124  
 fibrous, 117  
 hinge, 123  
 hip, 249  
 movements, 250  
 radiograph, 251  
 intercarpal, 233  
 interchondral, 152  
 intermetacarpal, 235  
 interphalangeal, 236, 270  
 intertarsal, 267  
 movements, 269  
 intervertebral, 144  
 knee, 256  
 movements, 259  
 radiograph, 259  
 Lisfranc's, 269  
 mediocarpal, 233  
 metacarpophalangeal, 236  
 metatarsophalangeal, 268  
 movements at, 121, 382  
 multiaxial, 126  
 pisiform, 234  
 pivot, 123  
 plane, 124, 126  
 radiocarpal, 233  
 saddle, 126  
 screw, 123  
 shoulder, 218  
 movements, 220  
 radiographs, 218, 220  
 simple, 122  
 sternoclavicular, 215  
 sternocostal, 152  
 subtalar, 267  
 synovial, 118  
 talocalcaneonavicular, 268  
 talocrural, 266



- joint(s)  
   tarsometatarsal, 269  
   temporomandibular, 191  
     movements, 192  
   tibiofibular, 260  
   trochoid, 123  
   uniaxial, 123  
 Jugs, alveolaria, 180, 187  
   cerebralis, 176  
  
 Key of pelvis, 242  
 kidney, 527  
   capsules, 528  
   convoluted part, 530  
   cortex, 529  
   excretory tract, 536  
   fascia, 529  
   fornical apparatus, 536  
   fornix, 536  
   head, 71  
   hilum, 528  
   medulla, 529  
   nerves, 535  
   primary, 71  
   radiate part, 530  
   sinus, 529  
   structure, 529  
     segmental, 537  
   topography, 528  
   vessels, 534  
   X-ray picture, 527  
 kyphosis, 148  
   senile, 149  
  
 Labia pudendi, 570  
 labiodontia, 408  
 labrum glenoidale, 218  
 labyrinth, bony, 171  
   ethmoidal, 202  
 lacuna, musculorum, 378  
   vasorum, 378  
 lacunae urethrales, 556  
 lamellae, growth, 99  
 lamina, cribrosa, 178  
   externa, 93  
   interna, 93  
   perpendicularis, 178  
   vastoadductoria, 379  
   vitrea, 93  
 larynx, 492  
   cartilages, 493  
   development, 523  
   inlet, *see also* aditus laryngis  
     492, 500  
   ligaments, 495  
   muscles, 495  
   nerves, 502  
   vessels, 502  
 ligament(s), 122  
   acromioclavicular, 216  
   alar, of odontoid process, 147  
   annular, of radius, 225  
     of trachea, 503  
   apical, of odontoid process,  
     147  
   arcuate, 242, 299  
   Bertin's, 250  
   bifurcate, 268  
   broad, of uterus, 567  
   calcaneocuboid, 268  
   calcaneofibular, 267  
   calcaneonavicular, 268  
   carpometacarpal, 235  
   collateral, 236  
   coracoacromial, 217  
   coracoclavicular, 216  
   coracohumeral, 219  
   coronary, 474  
   costoclavicular, 215  
   costotransverse, 153  
   cricothyroid, 496  
   cruciate, 258  
   cruciform, of axis, 146  
   deep transverse metacarpal  
     236  
   deltoid, 267  
   falciiform, 462, 474  
   gastrocolic, 476  
   Gimbernat's, 304  
   hepatoduodenal, 474  
   hepatogastric, 474  
   hepatorenal, 474  
   hyoepiglottic, 496  
   iliac, 242  
   iliofemoral, 250  
   iliolumbar, 242  
   inguinal, 303  
   intercarpal, 233  
   interclavicular, 215  
   interosseous, intercarpal, 233  
     metacarpal, 235  
     talocalcaneal, 268  
   interspinous, 144  
   intertransverse, 145  
   ischiofemoral, 250  
   lacunar, 304  
   long plantar, 271  
   longitudinal, 144  
   median umbilical, 540  
   metacarpal, 235  
   nuchal, 144  
   oblique of knee, 257  
   of ovary  
     palmar, 236  
     patellar, 257  
   phrenicocoli, 479  
   pisohamate, 235  
   pisometacarpal, 235  
   plantar calcaneonavicular,  
     268  
   Poupart's, 303, 309  
   pubic, 242  
   pubofemoral, 250  
   radial, collateral, 225  
   radiocarpal, 233  
   round, of uterus, 567  
   sacrocoxygeal, 145  
   sacroiliac, 242  
   sacrospinal, 242  
   sacro-tuberous, 242  
   scapular, transverse, 217  
   sphenomandibular, 188  
   sternoclavicular, 215  
   sternocostal, 152  
   stylohyoid, 172, 190  
   of superior tibiofibular joint,  
     260  
   supraspinous, 144  
   suspensory, of clitoris, 572  
     of ovary, 561  
     of penis, 556  
   talofibular, 267  
   talonavicular, 268  
   tarsometatarsal, 269  
   teres hepatis, 462, 474  
   thyroepiglottic, 496  
   thyrohyoid, 495  
   tibiofibular, 261  
   transverse, of acetabulum  
     249  
     of axis, 146  
     of knee, 256  
     perineal, 581  
   triangular, 474  
   phrenicocoli  
     ulnar, collateral, 225  
     vestibular, 496  
     vocal, 496  
     yellow, 144  
 ligamentum, capitis costae in-  
   traarticulare, 153  
   capitis costae radiatum, 153  
   collaterale carpi radiale, 233  
   fibularae, 257  
   tibiale, 257  
   ulnare, 233  
   intercarpea, 233  
   interfoveolare, 311  
   pisohamatum, 339  
   pisometacarpum, 339  
   radiocarpeum, 233  
   reflexum, 311  
   sphenomandibulare, 191  
   stylomandibulare, 172, 191  
 limbus vertebrae, 141  
 line(s), arcuate, 239, 305  
   of chest, 78  
   intertrochanteric, 248  
   mylohyoid, 187  
   nuchal, 144  
   superior, 196  
   oblique, 187  
   pectineal, 239  
   temporal, 175, 194  
   terminal, 243  
 linea, alba, 296, 308, 316, 321  
   aspera, 248  
 lingua, mandibulae, 188  
   pulmonis, 507  
 lip(s), 391  
   hares, 482  
 liver, 74, 460  
   caudate lobe, 463  
   development, 485  
   left lobe, 462  
   ligaments, 474  
   quadrate lobe, 463  
   right lobe, 462  
   structure, 463  
   segmental, 468  
   surfaces, 461  
   topography, 466  
   vessels, 467  
 lobules, cortical, 530  
   pulmonary, 510  
 lobuli, epididymidis, 546  
   hepatis, 463  
   testis, 545  
 loop, Henle's, 533  
   vitelline, 485  
 lordosis, 148  
 lumbarization, 129, 142  
 lungs, 506  
   boundaries, 521  
   circulation, 512  
   development, 523  
   functions, 511  
   hilum, 506, 524  
   lobes, 507, 515, 516  
   nerves, 513  
   root, 506, 524  
   segments, 515  
   structure, 507  
   segmental, 513  
   vessels, 512  
   X-ray, 523  
  
 Malleolus, 254  
   tertius, 270  
 man, distinguishing features,  
   85

- mandible, 185  
manubrium sterni, 150  
margin, falciform, 373  
  infraorbital, 180  
masses, lateral, 134  
maxilla, 179  
meatus, acousticus, externus, 169  
  internus, 171  
nasal, common, 202  
  inferior, 193, 202  
  middle, 198, 202  
  superior, 200, 202  
mediastinum, 520  
  testis, 545  
membrana tectoria, 147  
membrane(s), atlanto-occipital, 145  
  cricovocal, 496  
  elastic, of larynx, 501  
  fibrous, 119  
  interosseous, 117  
    cruris, 261  
    of forearm, 190  
    of skull, 190  
  obturator, 242  
  sternal, 152  
  synovial, 119  
  thyrohyoid, 495  
  tympanic, 171  
menisci, 120  
mesenchyma, 54, 72  
  extraembryonic, 67  
mesenterium, 428  
mesentery, 477  
  development, 487  
  of tendon, 286  
mesocolon, transverse, 452, 474  
mesoderm, extraembryonic, 67, 71, 73, 88  
mesogastrium, 78  
mesometrium, 567  
mesonephros, 572  
mesorectum, 454  
mesosalpinx, 562  
mesotendineum, 286  
mesovarium, 561, 567  
metacarpus, 229  
metameric character of human body structure, 62  
metanephros, 573  
metaphyses, 98, 100  
metatarsus, 263  
molar(s), 405, 406  
mons pubis, 570  
monstrosity, 84  
morphology, 18  
movements, types, 87  
midgut, 391, 485  
mucosa, nasal, 490  
muscle(s), 272  
  abdominal, 269, 302, 385  
  abductor digiti minimi, 348  
    digiti minimi, 372  
    hallucis, 370  
    pollicis brevis, 346, 383  
    pollicis longus, 345, 383  
  abductors, 283  
  action of, 308, 384  
  adductor brevis, 364  
  hallucis, 371  
    longus, 364  
    magnus, 364, 383  
    minimus, 364  
    pollicis, 347  
  adductors, 283  
  agile, 280  
  anconeus, 337, 383  
  antagonists, 280  
  aryepiglottic, 499  
  auricularis, 327  
  autochthonous, 273  
  of back, origin, 287  
  belly of, 278, 283  
  biarticular, 283  
  biceps brachii, 366, 382, 385  
    femoris, 362, 383  
  biomechanics, 278  
  bipinnate, 283  
  brachialis, 336, 383  
  brachioradialis, 342, 383, 385  
  broad, 283  
  buccinator, 329, 385, 392  
  bulbospongiosus, 578  
  of chest, 297  
  circular, 283  
  classification, 283  
  coccygeus, 580  
  constrictor cuni, 578  
    of pharynx, 419  
  contractility, 278  
  coracobrachialis, 335, 382  
  corrugator supercillii, 328  
  cremaster, 304, 551  
  cricocarytenoid, lateral, 497  
    posterior, 500  
  cricothyroid, 500  
  deltoid, 332, 382, 385  
  depressor anguli oris, 329  
    labii inferioris, 329  
    septi, 331  
  detrusor urinae, 542  
  digastric, 314  
  distribution, 282  
  dorsal interossei, 372  
  epicranium, 326  
  erector spinae, 293, 382  
  extensor carpi, radialis, 343, 383  
    carpi, ulnaris, 344, 383  
    digiti mini, 344, 383  
    digitorum, 344, 383  
    hallucis, brevis, 370, 384  
    hallucis longus, 366, 384  
    inducis, 345  
    pollicis, brevis, 345  
    pollicis longus, 345  
  extensors, 283  
  flexor carpi, radialis, 339, 383  
    carpi, ulnaris, 339, 383  
    digiti minimi, 348, 383  
    digitorum, accessorius, 372  
    digitorum, brevis, 372, 384  
    digitorum, longus, 368, 384  
    digitorum, profundus, 341, 383  
    digitorum, sublimis, 339, 383  
    hallucis, brevis, 371, 384  
    hallucis, longus, 369, 384  
    pollicis, brevis, 346, 383  
    pollicis, longus, 340, 383  
  flexors, 283  
  gamelius, 360, 383  
  gastrocnemius, 368, 384  
  genioglossus, 411  
  geniohyoid, 315  
  gluteus, maximum, 358, 383  
    medius, 358, 383  
    minimus, 358, 383  
  gracilis, 364, 383  
  hyoglossus, 412, 414  
  illocostocervicalis, 293  
  iliopsoas, 357, 383, 385  
  infraspinatus, 334, 382  
  innervation, 277  
  intercostal, 296, 298  
  interossei, 349, 383  
  interspinales, 294  
  intertransverse, 295, 382  
  ischiocavernosus, 578  
  latissimus dorsi, 288, 290, 382, 385  
  levator, anguli oris, 329  
    ani, 579  
    fornicis, 536  
  labii superioris, 328  
  scapulae, 291, 332, 382  
  levatores costarum, 295, 382  
  of limbs, development, 274  
  long, 283  
  longissimus, 293, 382, 384  
  longitudinal, 413  
  longitudinalis calycis, 536  
  longus, capitis, 318, 382  
    collis, 318, 381, 382  
  lumbrical, of foot, 372  
  of hand, 348, 383  
  masseter, 324, 385  
  of mastication, origin, 323  
  mentalis, 329  
  multiarticular, 284  
  mylohyoid, 314, 392  
  nasal, 331  
  of neck, 312  
  oblique, 283  
    arytenoid, 499  
    of back, 294  
  obliquus abdominis, externus, 302, 382  
    internus, 304  
  obturator, externus, 360, 383  
    internus, 359, 383  
  omohyoid, 316, 332  
  opponens, digiti minimi, 348, 372  
    pollicis, 346, 383  
  orbicularis, oculi, 328  
    oris, 330, 391  
  palatoglossus, 395, 412  
  palatopharyngeal, 395, 420  
  palmaris, brevis, 348  
    longus, 339, 383  
  pectineus, 364, 383  
  pectoralis, 297, 332, 382, 385  
  peroneus, brevis, 367, 384  
    longus, 366, 384, 385  
    tertius, 366, 384  
  piriformis, 359, 383  
  plantaris, 368  
  popliteus, 363, 384  
  prevertebral, 318  
  porta of, 278  
  procerus, 328  
  pronator, quadratus, 341, 383, 385  
    teres, 337, 383, 385  
  pronators, 283  
  psoas, 357, 383  
  pterygoid, 324  
  pubovesical, 542  
  pyramidalis, 305  
  quadratus, femoris, 360, 383, 385  
    lumborum, 308, 382  
  rectouterine, 567  
  rectus, abdominis, 296, 305, 381, 384  
    capitis, 318, 382  
    femoris, 361, 383, 385  
  rhomboid, 291, 382  
  risorius, 329  
  rotators, 283

- muscle(s)**  
 sacrococcygeus, 294  
 sacrospinal, 293  
 sartorius, 362, 383  
 scalene, 316, 381  
 of scalp, 326  
 semimembranosus, 362, 383  
 semispinalis, 382  
 semitendinosus, 362, 383  
 serratus, 291, 298, 332, 382  
 short, 283  
 skeletal, 278  
 soleus, 368  
 sphincter, ani externus, 456, 581  
     urethrae, 578  
     vesicae, 542  
 spinalis, 293  
 spiralis calycis, 536  
 splenius, capitis, 293, 381  
     cervicis, 293, 381  
 sternocleidomastoid, 313, 385  
 sternohyoid, 316  
 sternothyroid, 316  
 straight, 283  
     of back, 294  
 striated, 278  
 strong, 280  
 styloglossus, 412  
 stylohyoid, 315  
 stylopharyngeus, 420  
 subclavius, 298, 332, 382  
 subcostal, 298  
 subscapularis, 335  
 supinator, 345, 383  
 supinators, 283  
 supraspinatus, 334  
 suspensorius duodeni, 440  
 synergists, 281  
 temporal, 324, 385  
 tensor, fasciae latae, 358, 383  
     veli palatini, 398  
 teres, major, 335, 382  
     minor, 334, 382  
 thoracic transversus, 299  
 thyroarytenoid, 499  
 thyroepiglottic, 500  
 tibialis, anterior, 365, 384  
     posterior, 369  
 transverse, arytenoid, 499  
     perinei, 577, 579  
     of tongue, 414  
 transversospinalis, 293  
 transversus abdominis, 304  
 trapezius, 367, 384  
 triceps, brachii, 336, 383  
     surae, 367, 384  
 truncifugal, 273  
 truncipetal, 274  
 of trunk, origin, 272  
 uniaxial, 283  
 unipennate, 283  
 uvulae, 396  
 venter of, 283  
 verticalis, 413  
 vessels of, 278  
 vocalis, 500  
 zygomatic, 329  
 musculature, somatic, 87  
     visceral, 87  
 myosepta, 273  
 myotome(s), 54, 60, 71, 128, 272
- nephrotomes, 71  
 nervism, 40, 58  
 neurite, 54  
 neurocranium, 156, 158  
 neuron(s), 54, 70  
 neurosecretion, 584, 591  
 Nomina Anatomica, 86  
 norm, 83  
 nose, 489  
 notochord, *see also* chorda, 68, 90  
 notch, clavicular, 150  
     ethmoid, 176  
     jugular, of occipital bone, 165  
     of sternum, 150  
     lacrimal, 181  
     mastoid, 174  
     nasal, 180  
     sphenopalatine, 183  
     supraorbital, 176  
 nucleus pulposus, 123, 142, 144
- Occiput, 78  
 occlusion, of teeth, 408  
 oesophagoscopy, 426  
 oesophagus, 421  
     abdominal, 422  
     cervical, 421  
     development, 483  
     glands, 424  
     structure, 423  
     thoracic, 421  
     topography, 421  
     X-ray, 424  
 olecranon, 221  
 omentum, greater, 474, 476  
     lesser, 474  
 ontogenesis, 14  
 opisthodontia, 409  
 opposition, 236  
 orbit, 193  
 organ(s), 54  
     of animal life, 57  
     definite, 55  
     extraembryonic, 67, 75  
     permanent, 55  
     provisional, 55, 67  
     system of, 55  
     temporary, 55  
     of vegetative life, 56  
 organism, concept of, 52, 81  
     and environment, 59  
     integrity of, 58  
 organogenesis, 72  
 os, acromiale, 215  
     basilare, 165  
     centrale carpi, 237  
     coxae, 238  
     intercuneiforme, 265  
     intermaxillare, 182  
     intermetatarsium, 265  
     piriforme, 209  
     sesamoideum, cubiti, 223  
     peroneum, 265  
     styloideum, 237  
     subtibiale, 265  
     supranaviculare, 265  
     supratals, 265  
     tibiale externum, 265  
     trapezoideum secundarium, 237  
     triangulare, 237  
     trigonom, 265  
 ossein, 91  
 ossification, *see also* osteogenesis, 95  
     accessory points, 100
- centre, 95  
 classification, 100  
 endesmal, 95  
 intramembranous, 95  
 nucleus, 95, 97  
     X-ray, 103  
 perichondral, 96  
 periosteal, 96  
 primary, 98  
 principal points, 99  
 secondary, 97  
 osteoblasts, 94  
 osteoclasts, 94, 99  
 osteogenesis, *see also* ossification, 95  
     angiogenic, 98  
     chondral, 97, 117  
     desmal, 97, 117  
 osteon, 91  
 osteophytes, 104  
 osteoporosis, 104  
 ostium, abdominale tubae, 562  
     appendicis vermiformis, 451  
     cardiacum, 428  
     urethrae externum, female  
         571  
         male, 554  
     uteri, 563  
     vaginae, 571  
 ovary, 560, 596  
     accessory, 561  
     anomalies, 561  
 ovulation, 66
- Pacchionian granulations, 175, 176  
 palate, 393  
     cleft, 482  
     hard, 182, 196, 393  
     soft, 393  
 palatum, molle, 393  
 osseum, 393  
 pancreas, 470  
     accessory, 471  
     development, 485  
     structure, 471  
 papilla duodenum, major, 443  
     minor, 444  
 papillae renalis, 520  
 parachordalla, 160  
 paradidymis, 546  
 paraganglia, 594  
 parametrium, 567  
 paraoophoron, 563  
 patella, 209, 248  
     cubiti, 223  
     ossification, 255  
 pediculi arcus vertebrae, 132, 138  
 pelvis, 238, 243  
     anteroposterior diameter, 245  
     axis, 245  
     conjugate diameter, 244  
     false, 243  
     inlet, 243  
     intercrystal diameter, 244  
     interspinous diameter, 244  
     measurement, 244  
     outlet, 243  
     radiographs, 247  
     renal, 536  
     sex differences, 246  
     transverse diameter, 244  
     true, 243  
 penis, 551  
 perichondrium, 96  
 perimysium, 277
- Nasopharynx, 417  
 neck, topography, 318  
 nephron, 533, 534

- perineum, 57  
 period, adolescence, 77  
   natural infancy, 77  
   puberty, 77  
   suckling, 77  
 periodontium, 398  
 periosteum, 94  
   alveolar, 398  
 peritoneum, 427, 471, 480, 487  
 petiolus epiglottidis, 495  
 Peyer's patches, 445  
 phalanges, 229, 284  
 pharynx, 417  
   development, 483  
 phylogenesis, 14  
 physiology, 17  
 pit(s), gastric, 431  
   oral, 481  
 placenta, 67, 75  
   haemochorial, 75  
 plate(s), cartilaginous, 160  
   lateral, 71  
   neural, 69  
   prechordal, 68, 70  
 platysma, 313  
 pleura, 516  
   costal, 520  
   cupula of, 517  
   diaphragmatic, 520  
   mediastinal, 520  
   parietal, 516, 517  
   visceral, 516, 517  
 plica(e), adiposae, 119  
   gastricae, 431  
   longitudinalis duodeni, 443  
   palatinae transversum, 393  
   transversales recti, 455  
   umbilicalis, 311  
 pocket, gingival, 398  
 porta hepatis, 463  
 porus acusticus, externus, 170  
   internus, 171  
 pouch, Douglas', 567  
   pharyngeal, 483  
   Rathke's, 481  
   retrouterine, 480, 567  
   retrovesical, 480, 541  
   utero-vesical, 480, 541, 566  
 premolar(s), 404, 405  
 prepuce, of clitoris, 570  
   of penis, 554  
 process, accessory, 136, 139  
   articular, 132, 139  
   caudate, 463  
   clinoid, 166, 167  
   condylar, 108  
   coracoid, 214  
   coronary, 188  
   coronoid, 221  
   frontal, 185  
   jugular, 165  
   mastoid, 173  
   odontoid, 146  
   orbital, 183  
   pterygoid, 167  
   styloid, of radius, 223  
     of temporal bone, 172  
     of ulna, 221  
   temporal, 185  
   vermiform, 449  
     mesentery, 475  
     position, variants, 450  
   xiphoid, 150  
   zygomatic, of frontal bone  
     176  
     of maxilla, 182  
     of temporal bone, 169  
 promontorium, 137  
 pronation, 211, 225  
   of foot, 269  
 prostate, 557  
   isthmus, 559  
   lobes, 559  
 protuberance, mental, 187  
   occipital, 164, 165  
 psalidodontia, 408  
 pubis, 238  
 pudendum femininum, 570  
 pylorus, 428  
 pyramid(s), renal, 171  
   of temporal bone, 171  
  
 Radius, 221  
 rami, mandibulae, 186, 188  
   ossis pubis, 239  
 ramus ossis ischii, 239  
 raphe, palatini, 393  
   pharyngis, 420  
   of scrotum, 550  
 recess(es), duodenal, 477  
   costodiaphragmatic, 521  
   costomediastinal, 521  
   ileo-caecal, 477  
   retrocaecal, 479  
 recessus, intersigmoideus, 479  
   piriformis, 418  
   sacciformis, 225  
 rectoromanoscopy, 458  
 rectum, 477, 453, 485  
   coats, 455, 480  
   parts, 454  
   shapes, 454  
   topography, 456  
 regulation, hormonal, 583  
 reposition, 236  
 rete testis, 546  
 retinaculum, extensor, of foot  
   374  
   of hand, 351  
   flexor, of foot, 375  
   of hand, 352  
   of patella, 362  
   peroneal, 376  
 retroflexion, 126  
 retroflexio uteri, 566  
 retroversio uteri, 566  
 rib(s), 130, 150  
   accessory, 152  
   development, 136  
   false, 150, 152  
   floating, 150  
   joints of, 152  
   ossification, 151  
   true, 150  
   X-ray, 151  
 rima, glottidis, 496, 501  
   pudendi, 570  
   vestibuli, 501  
 rims, cartilaginous, 120  
 ring, inguinal, 311  
   lymphoepithelial, Pirogov's,  
   417  
 root, of lung, 506, 524  
   of tongue, 411  
   of tooth, 398  
 rostrum of sphenoid, 167  
 rotation, 121  
 rugae vaginales, 569  
  
 Sac(s), digestive, 433  
   gastric, 433  
   pleural, 520  
   urinary, 76  
   yolk, 76  
  
 saccules, air, 511  
 sacralization, 129, 142  
 sacrum, 136, 139  
 scapula, *see also* shoulder blade,  
   214  
   ligaments, 217  
   ossification, 214  
 sclerotome, 60, 71, 128,  
   272  
 scoliosis, 149  
 scrotum, 551  
 segment(s), bronchopulmonary,  
   513, 515  
   of kidney, 537  
 sella turcica, 166  
   types, 202  
   X-ray, 202  
 semicanalis, m. tensor tympani,  
   173  
   tubae auditivae, 173  
 septa, interalveolar, 187  
   intermuscular, 284  
   brachii, 335, 350  
 septula testis, 545  
 septum, femorale, 380  
   intermusculare, cruris, 374  
   femoris, 374  
   linguae, 410  
   nasal, 199, 489  
   retrovesical, 558  
   of sphenoid sinus, 167  
 sex characters, 80  
 sheath(s), 284, 285  
   of rectus abdominis muscle,  
   305  
   synovial, 286  
     common of flexor tendons,  
     354  
     intertubercular, 219, 336  
     of long flexor muscle of  
     thumb, 355  
     of tendons of hand, 355  
 shield, embryonic, 67  
 shoulder blade, *see also* scapula,  
   208  
 shoulder girdle, 213  
   development, 208  
   joints, 215  
   movement, 382  
   musculature, 331  
 sinus, air, 202  
   costomediastinalis, 521  
   of epididymis, 551, 544  
   ethmoidal, 491  
   frontal, 179, 491  
     X-ray, 205  
   of kidney, 528  
   of larynx, 501  
   maxillary, 180, 491  
     X-ray, 205  
   mesenteric, 477  
   paranasal, 491  
   phrenicocostal, 521  
   pleural, 521  
   sphenoidal, 167, 198, 491  
   superior petrosal venous, 173  
   tarsi, 263  
   tonsillar, 395  
   urogenital, 572  
   ventriculi, 433  
 skeleton, 87, 89, 101  
   of athletes, 111  
   development, 90  
   of foot, age changes, 265  
   function, 89  
   of hand, age changes, 230  
   human, characteristic fea-  
   tures, 131

- skull, 156, 193  
   age features, 203  
   base of, 156, 160, 195  
   bony, 157, 159  
   brachiocephalic, 206  
   cartilaginous, 157, 159  
   development, 156, 159  
   dolichocephalic, 206  
   growth periods, 204  
   at mature age, 204  
   membranous, 157, 159  
   mesocephalic, 206  
   of newborn, 203  
   sagittal section, 197  
   sex differences, 205  
   structure, 193  
   vault, 156  
   X-ray, 202, 204  
 skull-cap, *see also* calvaria, 156  
 sockets, dental, 181, 187  
 soma, 57  
 somatopleure, 387  
 somites, 71, 128  
 space(s), intercostal, 164  
   pretracheal, 322, 503  
   prevesical, 322, 541  
   retropubic, 541  
   retrovisceral, 323  
 spatium, antescalenum, 320  
   interaponeurotica supraster-  
   nale, 322  
   interossea metatarsi, 263  
   interscalenum, 319  
 sphincter(s), 326  
   antri, 428, 433  
   ileocaecal, 451  
   physiological, 433  
   pylori, 431  
 spina bifida, 140  
 spine(s), iliac, 239  
   ischial, 240  
   mental, 187  
   movements, 381  
   nasal, 176, 180, 194  
   of scapula, 214  
   of sphenoid bone, 167  
   supramental, 174  
   trochlear, 176  
 splanchnopleure, 387  
 splanchnotomes, 71, 72  
 spongy substance of bone, 92  
   97, 99, 100, 108  
   X-ray, 103  
 squama occipitalis, 164  
 stegodontia, 408  
 sternum, *see also* breast-bone  
   131, 150  
   ossification, 151  
   X-ray, 151  
 stomach, 428  
   autoplasty apparatus, 436  
   coats, 431, 432  
   development, 428  
   movements, 437  
   nerves, 438  
   roentgenoanatomic nomen-  
   clature, 433  
   shapes, 434  
   structure, 430  
   topography, 428  
   vessels, 437, 438  
   X-ray, 432  
 stylopodium, 208  
 sulcus, a. occipitalis, 174  
   a. subclavius, 151  
   bicipitalis, 353  
   calcanei, 262  
   caroticus, 166  
   carpi, 228  
   chiasmatis, 166  
   deltoideopectoralis, 297  
   femoralis anterior, 379  
   iliopectineus, 379  
   infraorbitalis, 181  
   intertubercularis, 217  
   lacrimalis, 180, 183  
   medianus, 353  
   mylohyoideus, 188  
   n. petrosi, 171  
   n. radialis, 217, 353  
   n. ulnaris, 218, 353  
   obturatorius, 239  
   palatinus, 180, 182, 183  
   paracolici, 479  
   plantaris, 379  
   sinus, petrosi, 165, 173  
     sagittalis, 165, 175, 176  
     sigmoides, 165, 174, 175  
     transversi, 165  
   spiralis, 217  
   subclavius, 506  
   tali, 262  
   tendinis m. peronei longi, 263  
   terminalis linguae, 410  
   venae cavae, 433  
     subclaviae, 151  
     umbilicalis, 462  
 supination, 212, 225  
   of foot, 269  
 sustentaculum tali, 262, 271  
 suture(s), 117, 159, 190  
   coronal, 195  
   frontal, 191  
   incisive, 182  
   lambdoid, 195  
   plane, 117, 124, 190  
   sagittal, 195  
   serrate, 117, 124, 190  
   squamous, 117, 190  
 system(s), Haversian, 90  
   digestive, 55, 390, 480  
   locomotor, 71, 87  
   of organs, 55  
   reproductive, 56, 543  
   respiratory, 56, 488  
   urogenital, 56, 526, 387  
 symphysis, mandibulae, 186  
   pubica, 242  
 synarthrosis, 115  
 synchondrosis, 115, 117, 124  
   arycorniculata, 496  
   fibrous, 118  
   hyaline, 118  
   petrooccipitalis, 191  
   sphenopetrosa, 191  
   syndesmosis, 115, 124  
 synelastosis, 117  
 synostosis, 100, 117, 124  
 synsarcosis, 331  
  
 Talus, 209, 261  
 tarsus, 261  
 teeth, 396  
   anomalies, 409  
   antagonists, 408  
   canine, 403, 404  
   deciduous, 396, 407  
   development, 397  
   eruption, 407  
   incisor, 401, 403  
   molar, 405, 406  
   permanent, 396, 400, 401  
   premolar, 404, 405  
   structure, 398  
   surfaces, 399  
   X-ray, 409  
   tendon, 278  
     Achilles, 368  
     calcaneal, 368  
     central, 299  
   teniae, coli, 448  
     libera, 448  
     mesocolica, 449  
     omentalis, 449  
   teratology, 84  
   testes, 544  
     coats, 551  
     innervation, 554  
     structure, 544  
     vessels, 554  
   thenar, 346  
   thorax, *see also* chest, 149,  
   164  
     apertures, 164  
     infrasternal angle, 164  
     movements, 156  
   thymus, 589  
   tibia, 253, 255  
   tissues, 52  
     bone, 53  
     connective, 52  
     contractile, 54  
     extraperitoneal, 472  
     integumentary, 52  
     neural, 54  
     muscular, 54  
   tongue, 392, 409  
   muscles, 411  
   papillae, 411  
   tonsil, intestinal, 451  
     lingual, 411  
     palatine, 394  
     pharyngeal, 417  
   tonus, 277  
   torus villosus, 391  
   trabeculae, 92  
     cranii, 159  
   trachea, 502  
     bifurcation of, 502  
     structure, 503  
     topography, 502  
   tract, iliotibial, 374  
   triangle, lumbar, 304  
   lumbocostal, 301  
   Petit's, 304  
   sternocostal, 301  
   subclavian, 319  
   trigonum, caroticum, 319  
   clavipectoralis, 352  
   femorale, 379  
   omoclaviculare, 319  
   pectoralis, 352  
   submandibulare, 319  
   subpectorale, 352  
   vesicae, 542  
   trochanter, greater, 247  
   lesser, 247, 248  
   trochlea, 218  
   tali, 261  
   trophoblast, 67  
   tube, neural, 69  
     respiratory, 388  
     urogenital, 389  
     uterine, *see also* uterine tube  
   tubule(s), collecting, 533  
   convoluted, 532  
   junctional, 543  
   renal, 532  
   seminiferous, 545  
   straight, 533  
   tuber, calcanei, 263  
   frontal, 176  
   maxillary, 180  
   omentalis of pancreas, 470

- tubercle(s), articular of temporal bone, 170  
 carotid, 133  
 conoid, 213  
 epiglottic, 495  
 greater, 217  
 infraglenoid, 214  
 intercondylar, 253  
 lesser, 217  
 mental, 187  
 pharyngeal, 165  
 pubic, 239  
 scalene, 151  
 spinous, 137  
 supraglenoid, 214  
 vertebral, 133  
 X-ray, 139
- tuberculum, costae, 150  
 dentale, 402  
 ossis scapuloidea, 228  
 sellae, 186  
 trapezii, 228
- tuberositas, ossis, cuboidei, 263  
 metacarpi V, 229  
 metatarsalis V, 264  
 navicularis, 263  
 phalangis distalis, 229, 264
- tuberosity, deltoid, 217  
 iliac, 239  
 ischial, 239  
 masseteric, 186  
 pterygoid, 186  
 radial, 223  
 sacral, 137  
 of tibia, 254  
 of ulna, 221
- tunica, albuginea, 544, 553  
 dartos, 551  
 vaginalis testis, 551
- tunnel, carpal, 235
- Ulna, 221  
 ureter, 538
- urethra, female, 543  
 male, 554  
 external orifice, 553  
 membranous, 556  
 prostatic, 554  
 spongy, 556  
 vessels, 556
- urethral orifice, external, 543  
 internal, 542, 543
- urination, 557
- uterus, 563  
 anomalies, 575  
 development, 575  
 innervation, 569  
 isthmus, 563  
 radiograph, 567  
 topography, 565  
 vessels, 568  
 wall, 564
- uterine tube, 562  
 anomalies, 575  
 radiography, 568
- utricle, prostatic, 555
- uvula, of palate, 394  
 vesical, 542
- Vagina, 569  
 anomalies, 575  
 development, 575
- valleculae epiglottica, 411
- valve, ileocaecal, 447, 451
- vault of pharynx, 417  
 spiral, 466
- valvula pylorica, 431
- vas deferens, 546
- velum palatinum, 394
- vesicle(s), amniotic, 67  
 seminal, 547  
 yolk, 67
- vertebra(e), 128, 131  
 body of, 132  
 X-ray, 138
- cervical, 132  
 coccygeal, 132, 138  
 features, 131  
 joints, 142  
 lumbar, 132, 135  
 number, 129  
 ossification nuclei, 140  
 prominens, 133  
 sacral, 132, 136  
 thoracic, 132, 134  
 waist of, 138  
 X-ray, 138  
 of newborn, 141  
 in growth and maturation, 141
- vertebral column, 131, 147,  
 development, 128  
 function, 131  
 movements, 149  
 X-ray image, 138  
 in ageing, 141
- vertex, 78
- vestibule, of larynx, 500  
 of omental bursa, 476  
 of vagina, 570
- villi, intestinal, 443
- vincula tendinum, 286
- «Virchowianism», 32
- viscera, 57, 387
- Wing(s), of Ilium, 238  
 of sphenoid bone, 166
- Zeugopodium, 208
- zona orbicularis, 251
- zone, haemorrhoidal, 455
- zygote, 66

# THE STRUCTURE OF THE HUMAN BODY

## THE ORGANISM

Since the object of study in anatomy is the organism, we shall first give a general account of its structure. The difference between the materialistic and idealistic ideologies in anatomy stands out most strikingly in the concept of the organism. Mechanistic materialism regards the organism as a simple mechanical sum of organs (Morgagni), tissue (Bichat) or cells (Virchow). The German scientist Virchow, in particular, likened the organism to a federal state of cells in which some of the cellular territories (cellular federations) led an independent life. Such a separation of individual parts from the whole organism is metaphysics, while endowment of some of the cellular territories with the ability to lead an independent life is vitalism (*L vita* life). According to dialectics, in contrast to this, the organism is not a mechanical sum of bones, blood, cartilages, muscles, tissues, etc.

The organism is the highest form of unity of protein bodies capable of exchanging substances with the environment and of growing and multiplying. The organism is a historically formed, integral, continuously changing system with a specific structure and developmental pattern. The organism lives only under definite environmental conditions to which it is adapted and beyond which it cannot exist. Continuous exchange of substances with the environment is an essential feature of the organism's life. With the cessation of this exchange, life also ceases. The development of cybernetics gave rise to the view that the ability to control is one of the fundamental properties of living material. From this standpoint the organism is regarded as the highest self-controlling device of nature.

## THE ORGANISM AND ITS COMPONENTS

The organism is built of separate individual structures, i.e. organs, tissues, and tissue components united into a whole.

In the process of the evolution of living substances, first the *non-cellular forms* (protein moners, viruses, and so on) and later the *cellular forms* (unicellular and the lowest multicellular organisms) developed. With further, more complex organization, different parts of the organism became specialized in the performance of separate functions as the result of which the organism was adapted to the conditions of its existence. As a consequence, specialized complexes originated from the non-cellular and cellular structures, namely, *tissues, organs*, and, finally, complexes of organs or

*systems*. In reflection of the differentiation process, the human organism contains all these structures. In the human organism, just as in the organism of all other multicellular animals, the cells exist only as components of the tissues.

## TISSUES<sup>1</sup>

We shall restrict ourselves here to a brief account of the earliest information about tissues. Tissues are described in detail in the course of histology.

**Tissues** are historically formed, individual systems of the organism. They are composed of cells and their derivatives and possess specific morphophysiological and biochemical properties.

Each tissue is characterized by development from a definite embryonal bud in ontogenesis, by relationship to the other tissues, and by a particular location in the organism. Tissues are formed morphologically of cells and an intercellular substance.

The great variety of tissues in the human and animal organism may be conditionally divided into four groups: (1) the integumentary tissues, or the epithelium (Gk *epi* upon, L *tela*, tissue fine as a web); (2) tissues of the organism's internal environment, or connective tissues; (3) muscular tissues, and (4) neural tissues (Fig. 1).

The **integumentary, or epithelial** tissues are located on surfaces bordering the external environment (hence the name skin-type epithelium given to some of them) and form the lining of the hollow organs (intestinal-type epithelium) and closed cavities of the body (cellonephrodermal- and ependymogial-type epithelium). Epithelium lining the vessels is called *endothelium*. Complexes of epithelial cells in the shape of tubes, saccules, and other structures form glands (glandular epithelium). The main functions of epithelium are tegumentary and secretory.

**Tissues of the internal environment, or connective tissues.** These tissues are isolated from the external environment, they differ greatly in properties and are joined in one group on the basis of a common function (which also determines the main signs of their structure), the maintenance of homeostasis.

In the process of evolution of the vertebrates, the tissues of the internal environment developed in three main directions: one subgroup became concerned with trophic and protective functions (fluid tissues, the blood and lymph, and the haemopoietic tissues), another group with the supporting function (fibrous connective and skeletal tissues), and a third group with the contractility function (mesenchymal-type unstriated muscular tissue). All the subgroups are in turn divided into tissue types, for instance, the skeletal tissues are of three types: cartilaginous, bone, and dentin (the bone of teeth). This classification may be detailed still further. For example, in the character of its interstitial substance the cartilaginous tissue may be hyaline, or glassy or fibrous and elastic containing a network of elastic fibres.

<sup>1</sup> The section *Tissues* is written by professors N. A. Shevchenko and G. S. Katinas.



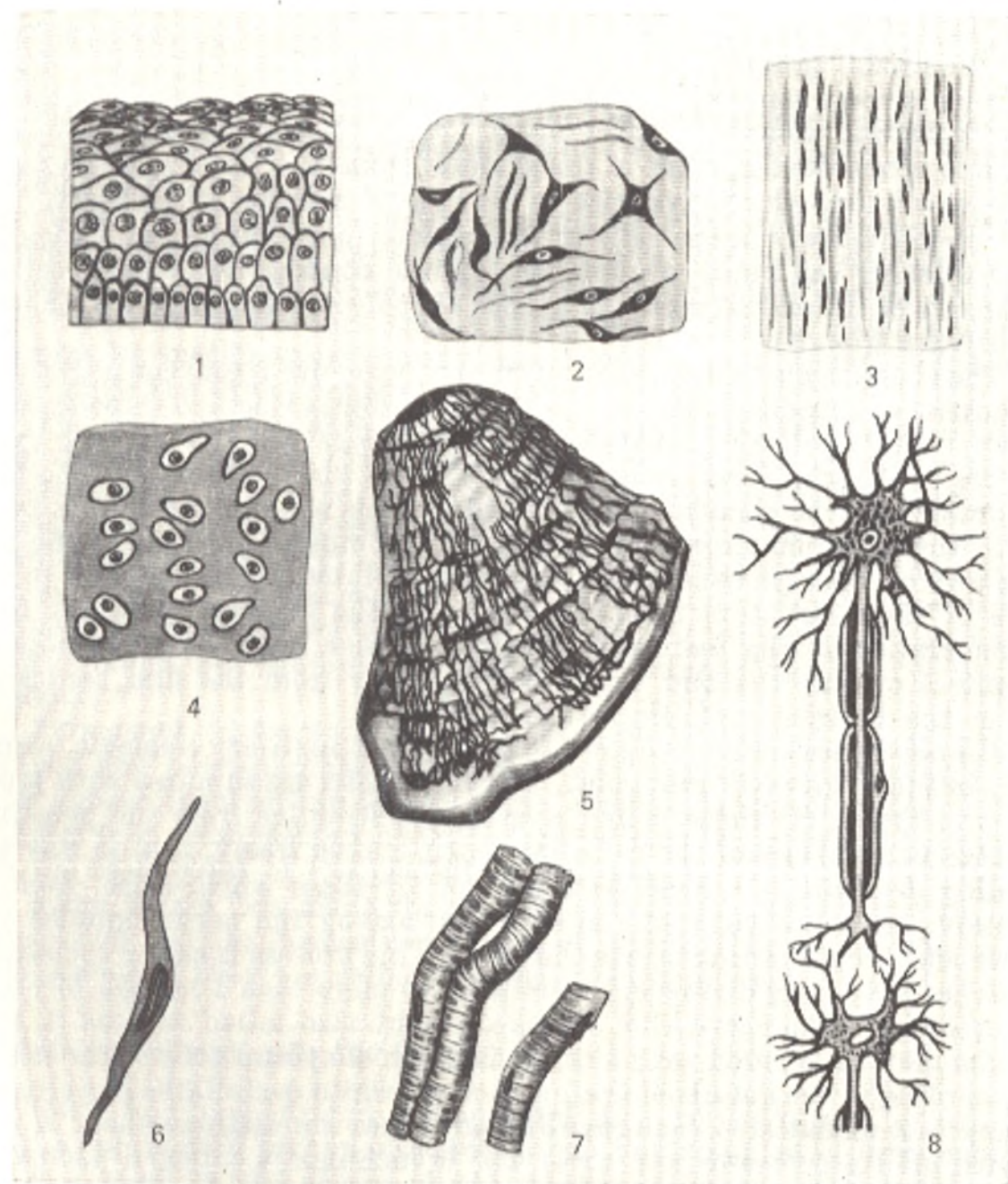


Fig. 1. Types of tissues.

- |  |                                     |
|--|-------------------------------------|
| 1, epithelium;                               | 5, bony tissue;                     |
| 2, loose connective tissue;                  | 6, smooth (unstriated) muscle cell; |
| 3, formed elastic fibrous connective tissue; | 7, striated muscle fibres;          |
| 4, cartilaginous tissue;                     | 8, nerve cells                      |

Bone tissue is the hardest and strongest (after dental enamel) tissue in the organism and excels by far iron and granite in firmness. It owes these properties to the interstitial substance which is impregnated with layers of lime. It is more convenient to discuss the mesenchymal-type unstriated muscular tissue together with the other muscular elements.

**Contractile tissues, muscular tissues,** are grouped together according to the functional property, the ability to contract. The contractile elements arise from several sources: (1) the *mesenchyma* (which is present in the wall of the intestine, vessels, urinary tract, etc.); (2) the *myotomes* which are the source of the development of the skeletal (somatic) tissue; (3) the *embryonal coelomic lining* which gives rise to the muscular tissue of the heart; (4) the *neural germ* from which the cells of the muscle constricting and those of the muscle dilating the pupil are derived; (5) the contractile (basket) cells are components of the end segments of glands of *epidermal* origin (sweat, thoracic, and salivary glands).

The smooth, unstriated, or involuntary muscular tissue contracts slowly and consists of spindle-shaped or stellate cells containing fine threads, microfilaments. The skeletal (somatic) muscular tissue consists of long (up to 10-12 cm in length) fibres measuring only 10-15  $\mu\text{m}$  in diameter. The fibrils also contain specific elements in the form of cross striated myofibrils possessing, in turn, a submicroscopic structure. The muscular tissue of the heart is made up of separate cells containing cross striated fibrils differing in some details of their structure from the fibrils of the skeletal muscular fibres. Another distinguishing feature is that the cardiac muscle is not subject to the control of our will and works continuously from the first contraction made at the beginning of life to the last one.

**Neural tissues** are made up of nerve cells and auxiliary elements, neuroglia, or, in short, glia (Gk *glia* glue). The nerve cells are supplied with processes of two types: (1) those which convey the stimulus from the perceiving apparatus to the body of the cell and which branch freely, that is why they are called *dendrites* (Gk *dendron* tree) and (2) those which arise, each one separately, from the body of the cell and convey the nerve impulse from it to the effector cell which exerts the effect. This process is called the *neurite*; it stretches for a long distance, sometimes for more than 1 m, and forms the axial cylinder of the nerve fibre and is therefore also called an *axon* (L *axis*). The axon may be covered with a myelin sheath of special cells of the neuroglia. According to the details of their structure, white medullated (myelinated) and grey non-medullated (non-myelinated) fibres are distinguished. A nerve cell with all its processes and their end branchings is called a *neuron* (Gk *neuron* nerve).

## ORGANS

An **organ** (Gk *organon* tool, instrument) is the part of the human body that serves as an instrument for the adaptation of the organism to the environment. The organs form as the result of a long-term process of the selection of useful adaptations of the organism to certain conditions of nutrition, reproduction, and protection, the selection and strengthening of such adaptations from generation to generation, and at the same time the dropping out of least adapted organisms. An organ is the body's natural instrument.

The organism possesses its own "natural technology", i.e. vegetative

and animal organs which play the role of the implements of production in the life of plants and animals.

An organ is a part of a single whole and cannot exist outside the organism (see the Chapter "Interrelation of the Organism as a Single Whole and its Components").

At the same time, an organ is a *relatively integral structure which has a definite, inherent only in it, form, structure, function, development, and position in the organism*. It is a historically established system of different tissues (often of all the four main tissues) one or more of which prevail and determine its specific structure and function. The vital activity of the organ occurs under the direct effect of the nervous system.

The heart, for instance, is made up not only of cardiac muscular tissue but of different types of connective tissue (fibrous, elastic), elements of the nervous system (cardiac nerves), endothelium, and unstriated muscle fibres (vessels). The cardiac muscular tissue prevails, however, and it is exactly its property (contractility) that determines the structure and function of the heart as an organ of contraction. A large part of the body concerned with a definite function and marked by its own specific development may also be called an organ. For example, according to F. Engels, the hand is the organ of labour.

*Permanent (definitive)* organs, i.e. those characteristic of an adult organism and persisting throughout life and *temporary (provisional)* organs which appear in a certain stage of the organism's development and then disappear (e.g. some embryonal and extraembryonal organs) are distinguished from the standpoint of the periods of ontogenesis.

Some organs are made up of many structures which are similar in organization and are themselves formed of several tissues (e.g. the nephron in the kidney). They are called morpho-functional units.

## SYSTEMS OF ORGANS AND APPARATUS

Some functions cannot be accomplished by only one organ. That is why a complex of organs, systems, form. For instance, a limb cannot be bent at a joint by the action of one muscle, a flexor, another muscle, an extensor, is needed. The complex of all muscles make up the muscular system.

The **system of organs** is a collection of homogeneous organs marked by a common structure, function, and development. It is a morphological and functional assemblage of organs, i.e. organs which have a common plan of structure and a common origin and which are connected with each other anatomically and topographically.

The bone system, for instance, is a set of bones with common structure, function, and development. The same applies to the muscular, vascular or nervous system.

The digestive organs seem to differ, but they all have a common origin (the epithelium of most of the digestive tract, including the liver and the pancreas, arises from the entoderm), a common plan of structure (three layers in the wall of the digestive tube), and a common function; all are

connected anatomically and related topographically. The digestive organs, therefore, also form a system<sup>1</sup>.

Some organs and systems of organs differing in structure and development may be united for the performance of a common function. Such functional collections of heterogeneous organs are called an **apparatus**. The apparatus of movement, for instance, includes the bone system, the articulations of bones, and the muscular system. The endocrine apparatus consists of the endocrine glands which differ in structure and development but are united by a common function, the production of hormones. Separate small structures of organs marked by a definite functional importance, like the importance of devices, are also called an apparatus, e.g. the receiving apparatus of the nerve cell (receptor).

The following systems of organs and apparatus are distinguished.

1. Organs concerned with the principal process characterizing life, the exchange of substances with the environment. This process is a unity of opposite phenomena, *assimilation* and *dissimilation*. That is why there are organs by means of which the organism incorporates nutrients and oxygen and which form the *digestive* and the *respiratory systems*, and organs which excrete from the body waste substances that have become unfit for use; these make up the *urinary system*. Waste substances are also excreted through the digestive and respiratory organs and the skin.

2. Organs concerned with the maintenance of the species, the reproductive, or sex organs; they form the *genital*, or *reproductive system*.

The urinary and reproductive systems are closely related in development and structure and are therefore united under the term *urogenital system*.

3. Organs by means of which substances incorporated by the digestive and respiratory systems are distributed throughout the organism while substances which must be excreted are brought to the excretory system. These are the organs of circulation, the heart and vessels (blood and lymph vessels). They make up the *cardiovascular system*.

4. Organs responsible for the chemical connection and regulation of all processes in the organism. These are the endocrine glands or organs; they form the *endocrine apparatus*.

The organs of digestion, respiration, and reproduction, the urinary organs, the vessels, and the endocrine glands are grouped under the term *organs of vegetative life* because similar functions are encountered in plants.

5. Organs concerned with adaptation of the organism to the environment by means of movement form the *motor apparatus* consisting of movement levers, i.e. the bones (the bone system), their articulations (joints and ligaments), and muscles which make them move (the muscular system).

6. Organs perceiving stimuli from the external environment make up the *system of sensory organs*.

7. Organs which accomplish the nerve connections and unite the function of all organs into a single whole form the *nervous system* with which the

<sup>1</sup> The designation system is sometimes used inexactly in the clinic. For instance, fluid tissues (blood and lymph) together with the haemopoietic organs are grouped under the name of the blood system.

higher nervous activity (psyche) is associated. In the process of the development of the animal world, the nervous system became the main system providing the integrity of the organism and its unity with the conditions of life. It is responsible for the exchange of substances with the surrounding nature.

The motor apparatus, the sensory organs, and the nervous system form the group of organs of *animal* life because the function of movement and nervous activity are inherent only in animals and are almost absent in plants.

The separate grouping of organs of vegetative from those of animal life is justified not only because they differ in function but because they differ in development. Thus, two tubes are laid in the body of the embryo, a vegetative tube which gives rise to the organs of digestion and respiration with which the urogenital organs become related, and an animal tube from which the nervous system forms.

In view of the unity of the vegetative and animal processes in the integral organism, however, it should be borne in mind that such separate grouping is relative and necessary for the convenience of study.

The motor apparatus and the skin covering it (i.e. the organs of animal life) form the body proper, the *soma*, within which there are the thoracic and abdominal cavities. Therefore, the soma forms the walls of the cavities. The contents of these cavities are called the *viscera*. These are the digestive, respiratory, urinary, and the reproductive organs, and the endocrine glands connected with them (i.e. the organs of vegetative life). The viscera and soma are supplied with *tracts conveying fluids*, i.e. vessels that carry blood and lymph and make up the vascular system, and *tracts that conduct stimuli*, i.e. nerves which together with the spinal cord and brain form the nervous system.

The tracts conveying fluids and stimuli form the anatomical basis for uniting the organism by means of neurohumoral regulation in which the nervous system plays the principal role. The viscera and soma are therefore parts of a single whole organism and are set apart conditionally.

As a result the following scheme of the organism's structure can be marked out: *the organism—the system of organs—the organ—the morpho-functional unit of the organ—the tissue—the tissue elements*.

It should be emphasized, however, that the different organs and systems are so closely related that it is impossible to isolate one system from another in the organism from the anatomical or from the functional standpoint. But for the convenience of studying the vast factual material and because the structure of the integral organism cannot be thoroughly understood at once, anatomy is traditionally studied according to systems. A definite branch of anatomy corresponds to each system: the study of the bone system (osteology), the articulations of bones (arthrosyndesmology), the muscular system (myology), the viscera (splanchnology), the cardiovascular system (angiology), the nervous system (neurology), the sensory organs (aesthesiology), and the endocrine glands (endocrinology).

## THE INTEGRITY OF THE ORGANISM

The organism, a living, biologically integral system capable of self-reproduction, self-development, and self-regulation, is a single whole. K. Marx called it the highest form of integrity. The organism is not simply the sum of its organs, tissues, and cells, as advocates of mechanistic materialism claimed. According to F. Engels "an animal is expressed neither by its mechanical composition from bones, blood, gristle, muscles, tissue, etc., nor by its chemical composition from the elements. Hegel (*Enzyklopädie*, I, p. 256). The organism is *neither simple nor compound*, however complex it may be".<sup>1</sup>

A. The integrity of the organism is provided by (1) the structural relation of all parts of the organism (the cells, tissues, organs, fluids, etc); (2) the connection of all parts of the organism by means of: (a) fluids circulating in its vessels, cavities, and spaces (humoral connection, *L humor* moisture); and (b) the nervous system which regulates all processes in the organism (nervous regulation).

Unicellular Protozoa organisms still devoid of the nervous system (e.g. the amoeba) have only one type of connection, the humoral. Two types of connection, the humoral and the nervous, occur with the appearance of the nervous system. As the organization of the animals gradually becomes more complex and the nervous system develops, the latter "takes hold of the body" more and more and places under its control all processes occurring in the organism, including the humoral processes. As a result a single neurohumoral system of regulation is established, in which the nervous system plays the principal part.

Thus, the *integrity of the organism is achieved through the activity of the nervous system, which permeates all the body organs and tissues with its branchings and which is the material anatomical substrate of the integration of the organism into a single whole*. This is one of the main propositions of the materialistic idea of nervism characteristic of Soviet biology and medicine.

B. The integrity of the organism also depends on the *unity of the vegetative and animal processes in it*, as was proved in I. P. Pavlov's works. These processes were thought to be absolutely separate before Pavlov.

C. The integrity of the organism also results from the unity of the spirit and body and the *unity of the psychic and the somatic*. The philosophy of idealism separates the spirit from the body and considers it to be independent and incognizable. Dialectical materialism believes that there is no psyche isolated from the body. The functions usually assigned to the psyche are performed by a bodily organ, the brain, which is the most highly developed and specifically organized matter capable of thought.

This modern conception of the organism's integrity is founded on the principles of dialectical materialism and its natural-scientific basis, I. Pavlov's physiological teaching.

<sup>1</sup> F. Engels. *Dialectics of Nature*. Foreign Languages Publishing House, Moscow, 1954, p. 283.

## RELATIONSHIP OF THE ORGANISM AS A SINGLE WHOLE TO THE ELEMENTS COMPOSING IT

A *single whole* is a complex system of interdependent elements and processes that possesses a specific property distinguishing it from other systems. A *part*, in contrast, is an element of the system and is subordinated to the whole. The organism as a whole is greater than the sum of its parts (cells, tissues, organs), a fact which developed as the result of the interaction of the parts in the process of phylogenesis and ontogenesis. The *ability to exist independently in a given environment* is a specific property of the organism which distinguishes it from other structures, which are incapable of independent life. This is what we call the organism's "organicism".

A unicellular organism (e.g. the amoeba), for instance, can live independently, whereas a cell that is a part of the organism (e.g. a leukocyte) cannot live outside the organism and perishes when removed from the blood.

The organism as a single whole plays the *principal role* in relation to its parts, a role which is expressed in the subordination of the activity of all the organs to neurohumoral regulation. Organs isolated from the organism, therefore, cannot perform functions that are characteristic of them within the integral organism. This explains the difficulty of organ transplantation. The organism as a whole, however, can exist after the loss of some of its parts. Evidence of this is provided by surgical practice, when different organs and parts of the body are removed during operation (removal of one kidney or one lung, amputation of limbs).

The subordination of a part to the whole is not absolute since some parts possess relative independence. Some cells, for instance, can live and multiply outside the organism (tissue cultures, development of the embryo *in vitro*). But the function of such isolated cells is not identical to that of the same cells within the integral organism since they are excluded from the common exchange with other tissues. Parts characterized by relative independence can have an effect on the whole. Changes occurring in the whole organism as a result of disease in individual organs provide evidence of this.

## THE ORGANISM AND THE ENVIRONMENT

I. M. Sechenov wrote that an organism cannot exist without an environment to sustain it. The environment should therefore be included in the scientific definition of the organism because it has an effect on the organism whose existence is dependent on it. Sechenov also taught that life always depends on the cooperation of two factors, a definite but changing organization and an effect exerted from the outside.

The organism, as G. I. Tsaregorodtsev wrote in 1966, is inseparably linked with the environment that surrounds it, the border between the organism and its habitat is relative in character. In a living organism the external is continuously transformed into the internal and vice versa. The

assimilation of nutrients is an example of the transformation of the external into the internal.

The unity of the organism with the conditions of its life is achieved through the exchange of substances between it and the surrounding nature; life ceases with the cessation of this exchange. In animals and man the exchange of substances is determined by neurohumoral regulation, in which the nervous system plays the leading role. According to Pavlov, the nervous system acts as "a finest instrument, which brings the organism into equilibrium with the environment".

The unity of the organism and the environment is the basis of the evolution of organic forms. The process of evolution results in structural variability of the organisms as they adapt to the changing conditions of existence. This adaptation is determined by the influence of the environment in which it occurs and by hereditary and other properties of the altering organisms.

"Hereditary adaptation to a given external factor results not from alteration of the hereditary properties of the individual organism corresponding directly to the influence of the external factors exerted on it during development, but from directed selection of numerous hereditary alterations, which occurs irrespective of the action of the environmental factor initiating the process of adaptation" (V. P. Efroimson. *Introduction to Medical Genetics*, 1964. In Russian).

Changes in the environment lead to changes in the organism, which constantly adapts itself to the changing conditions of the surroundings. Conversely, the environment changes to a certain degree under the effect of the developing organism. The conditions of habitation constitute the biological environment of animals. In the case of man, the social as well as the biological environment is of decisive importance.

Labour is of primary importance in the existence of man. Labour activity is the most important factor of man's environment. The processes of labour are associated with special nervous and muscular activity, which is determined by the character of the occupation in which the individual is engaged. Professional specialization leads to the greater development of those parts of the organism whose function is associated with the given occupation. As a result, each profession leaves a certain mark on the bodily structure of those engaged in it. The different variants in the normal structure of the human organism are explained to a great extent by the character of the work in which a person is engaged.

Besides work, all other conditions of life (nutrition, housing, clothing, and other every-day factors) have an effect on the human organism. The mental state of man, which is dependent on his social standing, is of great importance. The conditions of labour and every-day life constitute that which is known as the *social environment*. The last has a great and diverse influence on man.

The class structure of the society plays a decisive role in the development of the human organism. The life span of people belonging to the exploited classes and people living under colonial oppression is typically shorter



than that of individuals of the ruling class. Living under conditions of moral oppression, poverty, and exhausting labour, the oppressed classes and peoples are, naturally, subject to malnutrition and disease, which affects future generations as well. When India was a colony of Great Britain, for instance, the average life span was no more than 20-30 years. Life expectancy began increasing after the establishment of India's national independence. In the Soviet Union the average life expectancy increased more than two fold under the Soviet system, from 32 to 70 years<sup>1</sup>.

## THE PLACE OF MAN IN NATURE

The question of the origin of man and his place in living nature has long been the object of disagreement between materialists and idealists. The idealistic viewpoint, which takes the form of various religious beliefs, is based on the legend of the creation of man by a particular divine power. Science, on the contrary, has advanced a harmonious materialistic theory of the origin of man as the result of long-term evolution of living nature. In the process of this evolution, different forms of plants, animals, and, finally, man originated from the lowest unicellular and multicellular organisms.

To understand the place of man in the animal kingdom, it is necessary to bear in mind the genealogical tree based on the classification of the animal world from the lowest to the highest forms.

### *Phylum—Chordata*

A. Acrania: *Amphioxus lanceolatus*.

B. Craniota, or Vertebrata

a) Anamnia (devoid of an amnion), lowest organisms:

Class I, Cyclostomata: lampreys, hagfishes (*Myxiniidae*);

Class II, Pisces (fish): selachii (sharks, rays), ganoids (sturgeons), teleost fishes;

Class III, Amphibia: caudate (salamander), tailless (frogs), Hymnophions (legless);

(b) Amniota (possessing an amnion), highest:

Class IV, Reptilia: crocodiles, tortoises, lizards, snakes;

Class V, Aves (birds);

Class VI, Mammalia.

Subclasses: Monotremata (cloacal); Marsupialia; Placentalia with the orders: insectivorous, cheiroptera, edentate, rodents, carnivores, cetaceans, primates.

According to this zoological classification, man, together with all other vertebrates, belongs to the phylum Chordata because of the presence of a dorsal notochord in embryogenesis, which later reduces, and to the sub-phylum Vertebrata because of the presence of an axial skeleton, the vertebral column.

<sup>1</sup> The average life span is calculated not as an arithmetical mean but with consideration for the birth rate and the child mortality rate, which has fallen sharply during more than 65 years of Soviet government.

The vertebrates, man included, have many structural characteristics in common<sup>1</sup>. We shall point out here the most important principles, or laws, manifested in the structure of the human body.

I. *Polarity*, the presence of two variously differentiated ends, or poles, of the body; the opening for receiving nutrients, the *oral pole* (L *os*, *oris* mouth) is on the cranial end of the body, the *aboral pole* (L *ab* from, away) is on the opposite, caudal end.

II. *Bilateral symmetry*: both halves of the body are similar. Owing to this, most organs are paired: they are located on both sides of the median plain. Some of the organs are unpaired, and they are located on the midline of the body and can be divided into two symmetrical parts. Other unpaired organs are located asymmetrically (the heart, stomach, etc.) but they arise in the midline in the intrauterine period and are later displaced.

III. *Segmental*, or *metameric character*, the separation of a part of the body into segments or metameres (Gk *meta* after, *meros* part), i.e. into a series of segments arranged one after the other and almost similar in construction. This structure is maintained to this or that measure during evolution in all chordate animals and in man.

In the course of the long-term evolution, the human maintained the metameric structure not in the whole body but only in that part of it which served as the foundation for the development of all the other parts during phylogenesis, namely the trunk. The separate vertebrae, ribs, their articulations, the muscles of the trunk located between the separate vertebrae and ribs, the intercostal vessels and nerves, and the segments of the spinal cord—all are manifestations of the metameric structure and development of the human organism.

IV. *Correlation*, the regular proportion between the different parts of the body. Darwin called it the law of growth proportions. According to this law, the shapes of some parts of the body are always associated with the shape of other parts which seem to be in no way connected with the former.

In mammals, for instance, the separated hoofs are linked, as a rule, with the presence of a complex stomach adapted to rumination. In a similar way, in man "the gradually increasing perfection of the human hand, and the parallel development and adaptation of the feet for erect gait, undoubtedly also, owing to such correlation, reacted on other parts of the organism".<sup>2</sup>

*Physiological* correlations due to functional dependence (e.g. the relationship of the structure of the teeth and other organs of digestion and the paws of an animal of prey fitted with claws), *topographic* correlations (the relationship of the shape of adjacent organs which exert an effect on one another because of their proximity), and *genetic* correlations (caused by the specific arrangement of genes in the chromosomes, e.g. white fur, blue eyes, and deafness in cats) are distinguished.

<sup>1</sup> The correspondence in origin between parts of the body is called *homology* (e.g. between the fins of fish and the limbs of a terrestrial animal).

<sup>2</sup> F. Engels. *Dialectics of Nature*. Foreign Languages Publishing House, Moscow, 1954, p. 231.

Various other features of the structure of animals and humans can be deduced by studying individual parts of the body on the basis of Cuvier's law of correlation. This is important for palaeontology (when separate bones of fossil animals are discovered) and for forensic medicine (when it is necessary to establish the identity of a body on the basis of individual parts).

Plastic anatomy is also guided by the law of correlation in its canons in determining the proportions of the human body.

Man belongs to the highest class of vertebrates, to the class Mammalia, characterized by viviparity (with the exception of the Monotremata organisms which lay eggs) and feeding the newborn with the mother's milk (hence the name of the class).

Viviparity, a constant body temperature which is independent of the fluctuations of the environmental (air) temperature, intensive metabolism, and, of most importance, the progressive development of the brain, its cortex in particular, helped mammals to become adapted to the most various conditions of life and stand the competition with the lower classes of the vertebrates, and provided their extensive distribution and the possibility for further evolution.

Among the mammals, man belongs to the subclass *Mammalia placentalia*. The biological aspect of his being has formed in the last stage of anthropogenesis under the dominant influence of social factors.

Man belongs to the order of Primates (*L primus* first) which consists of four suborders.

1. Tarsioidea (Gk *tarsos* sole of the foot).
2. Lemuroidea (lemurs).
3. Tupaioida (insectivores).
4. Pithecoidea (Gk *pithekos* ape, *eidos* form) or Anthropeidea.

Man belongs to this last suborder Pithecoidea, or Anthropeidea, which includes the following two sections:

1. Platarhini, the wide-nosed monkeys of the Old World.
2. Catarhini, the narrow-nosed monkeys of the New World.

The section Catarhini has the following two suprafamilies:

- (1) Cynomorpha, the dog-like primates;
- (2) Anthropomorpha, the human primates.

The Anthropomorpha suprafamily includes two families:

- (1) Simiideae, the anthropoid apes;
- (2) Hominoideae (*L homo* man), humans.

The Hominoideae family consists of genera, species, and subspecies.

Genus: (a) *Pithecanthropus*, extinct man; (b) *Homo*, surviving man.

Human species: (1) *Homo Heidelbergensis*; (2) *Homo primigenius*, the primitive Neanderthal man; (3) *Homo sapiens*.

Subspecies of *Homo sapiens*: *Homo fossilis* and *Homo recens*.

## F. ENGELS' LABOUR THEORY OF THE ORIGIN OF MAN

In the famous works *The Origin of Species* (1859) and *The Descent of Man* (1871), Darwin proved irrefutably, on the basis of a rich natural-scientific data base, the unity of the origin of man and the animals and the descent of man from anthropoid apes now extinct. Man inherited from his ape ancestors many anatomical features, which we shall mention in the corresponding

sections of anatomy. At the same time, however, man differs sharply from the apes, most of all in his level of psychic development, which was achieved in direct connection with work and social life, i.e. the social environment. "The most that the animal can achieve is to *collect*; man *produces*, he prepares the means of life ..."<sup>1</sup>.

Having proved the descent of man from ape-like ancestors, Darwin solved the problem of anthropogenesis on the basis of biological evidence alone. His interpretation is, consequently, one-sided. He did not disclose the decisive factors responsible for the transition from this ape-like ancestor to man. In the famous work *The Part Played by Labour in the Transition from Ape to Man*, Engels showed that labour was the principal factor in this transition. According to Engels, labour in fact created man. The essence of Engels' labour theory of the origin of man consists in the following: many hundreds of thousands of years ago, in the Tertiary period, a highly developed race of anthropoid apes lived in the tropical zone; they were covered with hair, had beards and pointed ears, and lived in tribes in the trees. Climbing and clambering from tree to tree led to the development of a special function of the forearm. The apes developed the capacity to grasp branches and swing from tree to tree (branchiation). The forearm thus became a hand. Later, walking on the ground, the apes no longer used their hands and mastered an erect gait. Thus, "the decisive step was taken in the transition from ape to man: the hand became free and could attain the high degree of perfection that has enabled it to conjure into being the pictures of Raphael, the statues of Thorwaldsen, the music of Paganini"<sup>2</sup>.

From an organ of movement in apes, the hand changed to an organ of labour in man and became capable not only of using available surrounding objects, as in the case of apes who grasp sticks to defend themselves from their enemies or bombard the enemy with stones, but of making tools. Apes cannot adapt nature to their needs; they adapt themselves to nature. No ape's hand has ever made a stone knife, however crude.<sup>3</sup>

The human hand, in contrast, became capable of making tools as the result of the gradual development of its muscles, ligaments and, later, bones. This was in part also the result of the development of the nervous system and the refinement of human consciousness, which allowed man to adapt to the environment according to his needs by means of the tools. Under the continuous effect of labour, the human hand acquired a structure different from that of the ape and thus became not only the organ but also the product of labour.

The hand, however, was not a self-sufficient entity, but simply a member of the organism as a whole. Thus, whatever benefited the hand benefited

<sup>1</sup> F. Engels. *Dialectics of Nature*. Foreign Languages Publishing House, Moscow, 1954, p. 404.

<sup>2</sup> F. Engels. *Dialectics of Nature*. Foreign Languages Publishing House, Moscow, 1954, p. 230.

<sup>3</sup> On the basis of recent experimental studies of anthropoid apes, some scientists claim that apes are capable of producing primitive implements sporadically. Man, therefore, differs from the ape by his ability not simply to produce tools, but to produce them systematically and use them.

the whole body as well. The domination of man over nature, which began with the development of the hand and labour, broadened his mental outlook, while labour itself served to unite members of the society. Thus, the newly evolved human beings acquired the need to speak to one another, to associate with each other. This need created its own organ: the undeveloped throat of the apes, together with the organs of the mouth, gradually transformed into the organs of speech, which aided the further refinement of the human consciousness. Labour, later with the help of articulate speech, stimulated the development of the brain which came more and more to resemble the human brain as we know it.

The development of the brain was paralleled by the development of its immediate instruments, the sense organs, which enabled man to orient himself in his surroundings to an ever increasing degree. The tactile sense specifically, which the ape possesses in a crude form, developed in man as the human hand itself developed, in association with labour which facilitated the development of the brain. At the same time, the evolving human consciousness and its increasing refinement had a positive effect on the development of labour and on the facility of speech.

This process of the mutual influence of labour and speech on the human body structure continued for hundreds of thousands of years and resulted in the origin of a society of humans from a tribe of apes. "And what do we find once more as the characteristic difference between the hand of monkeys and the human society? *Labour.*"<sup>1</sup>

The further development of man's labour and the improvement of technology and technical equipment stimulated the development of the human society and changed its social structure. Changing social conditions affected, in turn, the biological characteristics of man. After a series of stages of human evolution (Pithecanthropus, Neanderthal man, and modern man), the human organism reached the higher level of organization characteristic of man today.

The characteristic features distinguishing man from the anthropoid apes are as follows:

- (1) erect gait;
- (2) the hand as the organ of labour;
- (3) articulate speech;
- (4) advanced development of the brain and its receptacle, the skull;
- (5) the position of the viscera, corresponding to the vertical position of the body;
- (6) skin almost absolutely devoid of hair.

Proceeding from this, the structure of all human organs and tissues have specific features. These features are mentioned in the corresponding accounts of the anatomical material.

<sup>1</sup> F. Engels. *Dialectics of Nature*. Foreign Languages Publishing House, Moscow, 1954, p. 235.

## THE MAIN STAGES IN THE INDIVIDUAL DEVELOPMENT OF THE HUMAN ORGANISM

According to the environment in which the individual is developing, the whole ontogenesis is separated into two large periods between which is the moment of birth.

1. The intrauterine period, in which the newly conceived organism develops in the mother's womb, lasts from the moment of conception to the time of birth.

2. The extrauterine or postnatal (*L natus* birth) period, in which the new individual continues development outside the mother's body, lasts from the moment of birth until death.

The intrauterine period is separated, in turn, into two phases: (1) the embryonic phase (the first two months) in which the initial development of the embryo occurs and the organs are mainly laid; (2) the foetal phase (3rd to 9th months) in which the foetus develops further.

### THE INITIAL DEVELOPMENT OF THE HUMAN ORGANISM<sup>1</sup>

The embryonic development of man is best studied in a general course on embryology, and its discussion here is restricted to the briefest primary information necessary for understanding the bodily structure of an adult human.

The early developmental stages of the human embryo in the oviduct and uterus are conditionally subdivided into five periods following one another with no sharp delimitation: (1) ovulation and the formation of the zygote; (2) cleavage; (3) gastrulation; (4) differentiation of the main rudiments of the organs and tissues; (5) development of the organs (organogenesis) and tissues (histogenesis).

1. *Ovulation and the formation of the zygote.* Immature germ cells undergo a series of profound transformations significant from the biological standpoint (reorganization of the nucleus, reduction in the number of chromosomes, etc.) as a result of which they become mature germ cells, or gonocytes. Ovulation is a specific process, possible only within one and the same species. It occurs in the oviduct: the male germ cell, the spermatozoon (*Gk sperma* seed), penetrates the female germ cell, the ovum; they fuse and form a new individual, a new organism in the earliest developmental stage, which is called a *zygote*.

2. *Cleavage.* The zygote undergoes cleavage, i.e. a series of consecutive divisions into cells, blastomeres (*Gk blastos* germ, *meros* part), the number of which reaches several hundreds by the end of this period. Cleavage of the different blastomeres is asynchronous and the human therefore has two-cell, three-cell, four-cell, five-cell, and six-cell stages of blastomeres; they become smaller and smaller, up to a certain point. Some blastomeres are grouped together into a spherical mass called the *embryoblast*, others grow

<sup>1</sup> Written by Prof. A. N. Shevchenko.

over the surface of the embryoblast and form the *trophoblast*. A cavity, the blastocoele, forms between the embryoblast and the trophoblast; fluid accumulates in it as a result of which a vesicle forms, this is the blastocyst whose diameter measures about 100 microns.

Due to the lysing effect of the trophoblast on the uterine mucous membrane the embryo is embedded in it on the 7th-8th day of development. This process is called implantation, it provides the embryo with the necessary conditions for its further development and for connection with the maternal organism.

Some cells are expelled from the embryoblast into the blastocystic cavity, the blastocoele, where they reproduce vigorously and form the *extraembryonic mesoderm*. The extraembryonic mesoderm then develops into the extraembryonic mesenchyma which gives rise to the connective tissue and vessels. The vessels grow from the inner surface towards the trophoblast and form together with it an outer membrane, the chorion (Gk *chorion* a skin).

Outgrowths—villi—form on the outer surface of the trophoblast and are penetrated by blood vessels. These villi grow into the uterine mucosa together with which they form the placenta (Gk *plax* flat surface). The placenta is also called the afterbirth because it is delivered after the birth of the child.

3. *Gastrulation* (Gk *gaster* stomach). Two stages of this complex process are distinguished. A layer of cells flattened into a plate separates from the embryoblast and gives rise to the inner germ layer, or the entoderm (Gk *entos* within, *derma* skin). This is the first stage of gastrulation, it occurs on the eighth day. The remaining part of the embryoblast soon transforms into an *amniotic vesicle* whose floor is the outer germ layer, or the *primary ectoderm*. The entoderm located directly under the floor of the amniotic vesicle soon also transforms into a vesicle which is known as the *yolk vesicle* (see Fig. 5). As can be seen in Fig. 5, the floor of the amniotic vesicle, which is composed of the outer germ layer, the primary ectoderm, adjoins the roof of the yolk vesicle formed by the *inner germ layer*, the *entoderm*. Both the germ layers, the primary ectoderm and the entoderm, make up a single whole, the *embryonic shield*. The extraembryonic mesoderm is adjacent to the outer walls of the amniotic and yolk vesicles.

In this stage of gastrulation, the body of the embryo (the embryonic shield) is therefore formed by the cells of the floor of the amniotic vesicle (the primary ectoderm) and the adjoining part of the yolk vesicle (the entoderm). The lateral parts and the roof of the amniotic vesicle as well as the greater part of the yolk vesicle are not components of the body of the embryo. Together with the extraembryonic mesoderm they give rise to the *provisional* (i.e. temporary), or *extraembryonic organs*. These include, besides the chorion mentioned above, the amnion, the yolk sac, and the allantois. Very powerful and (compared to the development of the embryo itself) very early development of the provisional organs is a characteristic feature of the embryogenesis of the anthropoid apes and man.

The second stage of gastrulation begins in the 15th-16th day. Very

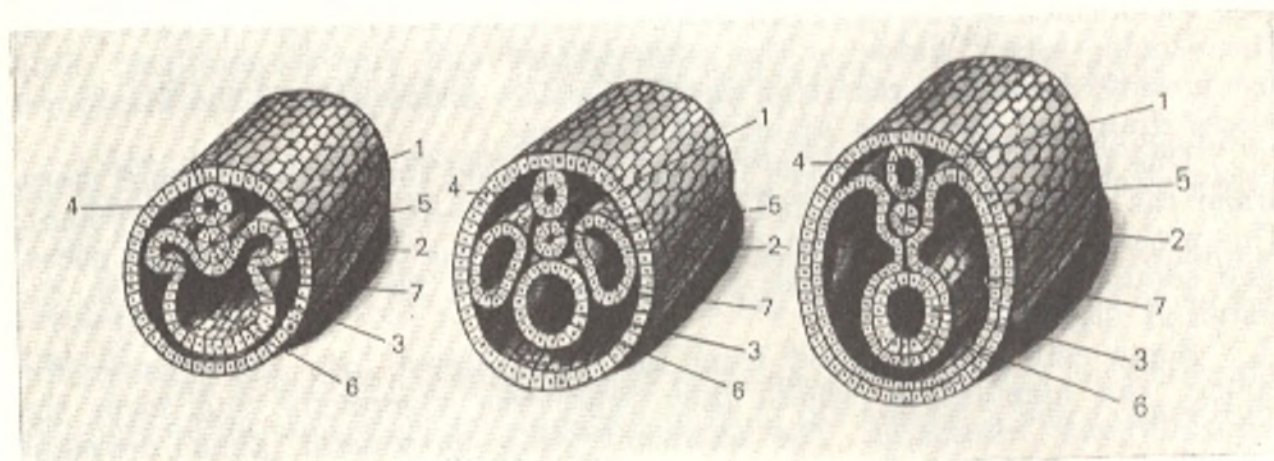


Fig. 2. Initial ontogenesis period of the lancelet.

- |                 |               |
|-----------------|---------------|
| 1, ectoderm;    | 5, notochord; |
| 2, mesoderm;    | 6, gut;       |
| 3, entoderm;    | 7, coelom     |
| 4, neural tube; |               |

important and complex regrouping and transposition of cells take place.

As a result of the regrouping, some cells of the primary ectoderm are displaced and again become components of the entoderm which is isolated from the embryoblast; the displaced cells of the primary ectoderm make up the foremost part of the inner germ layer, called the *prechordal plate*. Thus, the primary ectoderm also takes part in the final formation of the inner germ layer, the entoderm.

The cells of the embryonic shield penetrate between the ectoderm and entoderm from a thickening known as the primitive streak. Cells growing to the front on the midline of the body give rise to the *chorda* (notochord) and on both sides of it to the *middle germ layer*, the *mesoderm* (Gk *mesos* middle).

After the cells of the prechordal plate are expelled and the mesoderm isolated, the outer layer of the embryonic shield (the primary ectoderm) is known as the *outer germ layer* or the *ectoderm* (Gk *ektos* outside).

Multiplication of cells in the ectoderm results in the formation of the neuroectoderm.

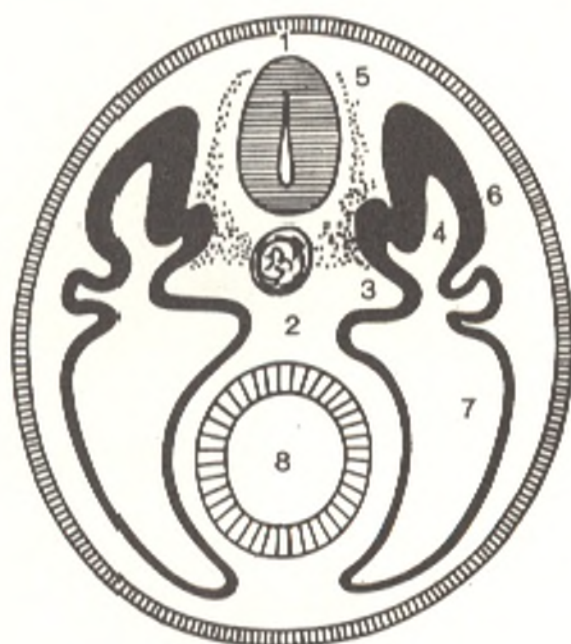
In this second stage of gastrulation, the structure of the embryo becomes more complex, an *axial rudiment complex* forms in it. This complex consists of the following parts: (1) the neural plate or groove which transforms later to the neural tube; (2) the *chorda*, or notochord (Gk *noton* back, *chorde* cord) lying beneath it; (3) the mesoderm located to the right and left of it. The axial complex of rudiments is shown in Fig. 3 (cross section of an embryo).

The arrangement of the axial complex of rudiments on the dorsal surface and their mutual localization are extremely characteristic not only of a human embryo, but of all organisms related to the Chordata (Fig. 2) and is the most ancient sign which they share in common. The period of



Fig. 3. Diagram of transverse section through the embryonic trunk.

- 1, neural tube;
- 2, chorda (notochord);
- 3, sclerotome;
- 4, myotome;
- 5, mesenchymal rudiment of the dorsal vertebral arch;
- 6, dermatome;
- 7, coelom;
- 8, primitive intestine (gut)



gastrulation is completed with the appearance of this sign in the structure of the embryo. The differentiation of other rudiments of the future tissues also takes place during gastrulation.

4. The next, fourth, developmental period is the *period of the differentiation of the body of the embryo*, the main rudiments of its organs and tissues. This occurs by means of the body fold. It appears first on the ventral (the more developed) end of the body, then on the dorsal end, and later in the middle part of the body. The shaping of the body of the embryo, its isolation from the auxiliary extraembryonic parts takes place in this period. The embryo grows in length and turns into a cylindrical structure with a head (cranial) and tail (caudal) ends. Further development of the embryo is characterized by progressive differentiation of the germs in different directions. The further the differentiation advances, the greater become the differences between the cells of the germs. We shall dwell here on the transformation of the germ layers (Fig. 4).

**The outer germ layer, or ectoderm.** The ectoderm is heterogeneous after completion of gastrulation. Most of it is the skin ectoderm, but on the dorsal surface along the midline it gives rise to the neural plate (neuroectoderm). The plate gradually caves in and first turns into a groove (open on the dorsal surface), the margins of which are raised to form the neural folds. Penetrating deeper and deeper, the neural groove sinks under the ectoderm, while the neural folds approach each other until they fuse; the groove is thus converted into the neural tube. The latter is the rudiment of the spinal cord and brain. The neural tube widens towards the ventral end, and the brain rudiment, which is massive in the human embryo, forms. In the dorsal part the neural tube has a metameric structure. The ectoderm and the walls of the neural tubes give rise to neural folds which transform into a band of cells called the neural crest. Its cells give origin to the spinal and cranial ganglia.

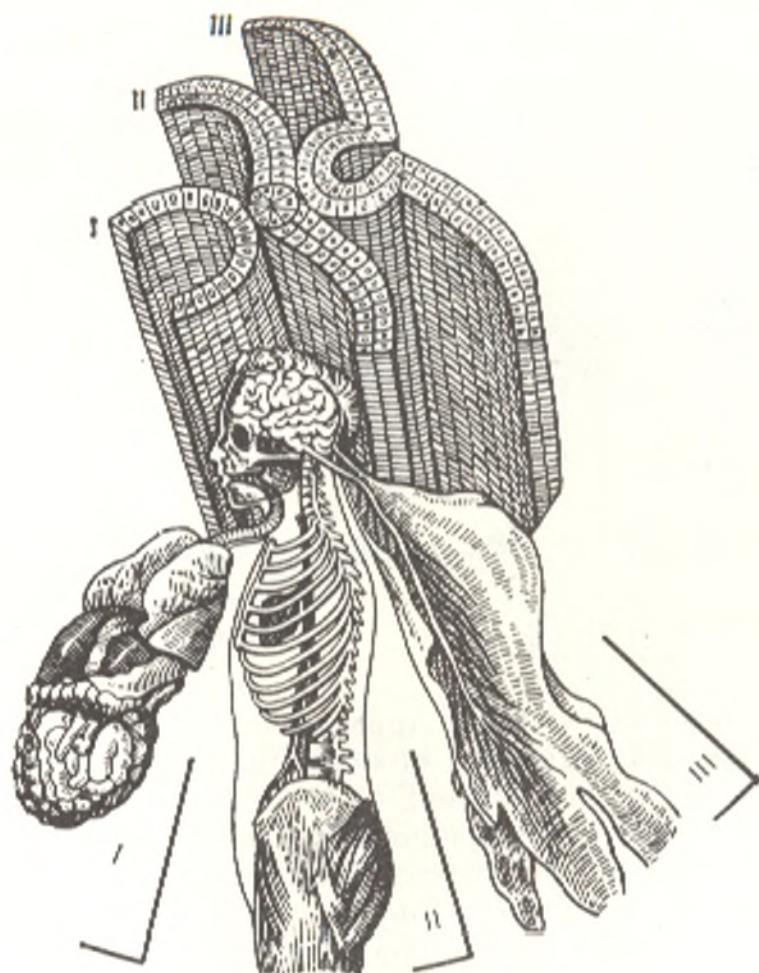


Fig. 4. Derivatives of the three germ layers.

*I*, entoderm—intestine and glands; *II*, mesoderm—bones, muscles, and vessels; *III*, ectoderm—nerves, skin

The neural tube gives rise to the nerve cells (neurons) and different auxiliary ependymo-glial elements, components of the nervous system and sensory organs of adults, e.g. the contractile elements of the iris, the pigmented epithelium, etc.

After the neural rudiment has been set apart, the remaining part of the ectoderm is called the *skin ectoderm*. It gives rise to the following structures: the skin epithelium (the tegumental tissue) or the epidermis and its derivatives (the hair, nails, sebaceous and sweat glands, the mammary glands); part of the epithelium of the oral mucous membranes and glands; the dental enamel; the stratified epithelium of the anal region; the epithelium of the urinary tract and ductus deferens.

**The inner germ layer, or the entoderm.** As it is pointed out above, this embryonic germ is heterogeneous: its ventral part is the prechordal plate (i.e. ectoderm material, included again in the entoderm), while the remaining part is the intestinal entoderm.

The prechordal plate gives origin to the tegumental and glandular

tissues of the epidermal type: the lining (i.e. epithelium) of the respiratory tract and lungs and a considerable part of the oral and pharyngeal mucous membrane. The glandular tissues of the anterior pituitary lobe, the thyroid and parathyroid glands, the epithelial foundation of the lobes of the thymus gland, and the tegumental epithelium and the glands of the oesophagus also arise from the prechordal germ.

The tegumental epithelium and glands of the stomach and intestine, the liver, the epithelium of the biliary ducts, and the glandular tissues of the pancreas develop from the intestinal entoderm.

**The middle germ layer, or the mesoderm.** At first this layer is represented by spinal segments arranged metamERICALLY to the right and left of the chorda. These segments are called *somites* (Gk *soma* body) and are connected by means of segmented limbs (*nephrotomes*) to the ventral unsegmented parts of the mesoderm which are called *splanchnotomes* (Gk *splanchna* viscera) or *lateral plates* (see Fig. 3). The maximum number of somites, 43 or 44 pairs, occurs by the end of the 5th week of development, when the embryo is 11 mm long.

Each somite, with the exception of the first two, differentiates into three portions: (1) the dorsolateral portion, which is the mesenchymal germ of the skin connective tissue, the *dermatome*; (2) the medioventral area, which gives rise to the cartilaginous and bony tissues of the skeleton, the *sclerotome* (Gk *scleros* hard); and (3) the portion between the dermatome and the sclerotome; it gives origin to the skeletal musculature and is called the *myotome* (Gk *mys* muscle) (Fig. 3).

The muscles of the body develop from the myotomes later. The cutis plate underlies the skin ectoderm and develops into the connective-tissue layer of the skin. The sclerotomes give origin to the mesenchymal skeletogenous cells accumulating around the neural tube and chorda and giving rise to the vertebrae, ribs, and intervertebral discs. The last contain the remnants of the chorda in the form of nucleus pulposus, which are very instructive from the standpoint of phylogenesis. The sclerotomes are also responsible for the formation of other parts of the skeleton.

The historical development of the urinary organs of vertebrate animals and man is vividly reflected in the embryonic development of the *segmented limbs*, or *nephrotomes* (Gk *nephros* kidney). The nephrotomes are located along the distance between the cranial and caudal ends of the embryo in the region of the head, trunk, pelvis and give rise to different structures.

Nephrotomes located in the region of the head give rise to the *head kidney* which develops into the urinary organs in lower vertebrates. In the human embryo, there is some development (in reflection of phylogenesis), although it is poor.

The nephrotomes in the region of the trunk in embryos of higher vertebrate animals and man give origin to the *truncal*, or *primary*, kidney which grows considerably; its tubules function for some time, but then undergo reduction. The caudal part of this nephrotome, in contrast, persists and becomes connected with the tubules of the male gonad, the testis. The tubules of this part are no longer concerned with a uriniferous function but are

converted to seminiferous tubules connecting the testis with the epididymis. In a female embryo these tubules hardly develop.

The excretory organ of man, the *kidney*, develops from the unsegmented part of the *nephrogenous tissue in the pelvic region* in the form of renal tubules, or nephrons, which are the morphological and functional unit of the kidney.

The splanchnotomes, or the lateral plates (unsegmented part of the mesoderm) appear at first as compact cellular masses. Then a secondary body cavity, or *coelom* (Gk *koiloma* hollow), forms in it as a result of which each splanchnotome (right and left) is subdivided into two sheets: (1) the *parietal* sheet (L *paries* wall) lining the wall of the body and adjoining the ectoderm (from the direction of the abdominal cavity) and (2) the *visceral* sheet which forms the serous coat of the internal organs. The coelom gives rise to the pericardial, pleural, and abdominal cavities.

Cells with processes wander away from the coelomic lining of both sheets. Like the cells of the cutis plate and sclerotomes mentioned above, these cells, multiplying and proliferating, fill the spaces between the germ layers and the embryonic germs in the body of the embryo and in the extra-embryonic parts. They constitute a specific embryonic tissue spreading throughout the body of the embryo and outside it, called the *mesenchyme*. It is characterized by a loose arrangement of stellate cells.

Absolutely different tissues are derived from the mesenchyme later; they differ in the cell composition and the character of the intercellular substance. Since at first the mesenchyme conveys nutrients to different parts of the embryo, i.e. is concerned with trophic function, the blood and haemopoietic tissues, the lymph, the blood vessels, the lymph nodes, and the spleen are derived from it later.

Besides the derivatives mentioned above (the sclerotomes and cutis discs), the mesenchyme also gives rise to: (a) the fibrous connective tissues differing in the character and amount of intercellular substance and cells (ligaments, articular capsules, tendons, fasciae, etc.); (b) cartilages, bones, unstriated muscles.

5. The fifth period of embryogenesis is the period of the development of organs (*organogenesis*) and tissues (*histogenesis*). Organogenesis is the anatomical formation of organs. The acquisition of specific morphological, physiological, and biochemical properties by the developing cells and tissues is called *histological differentiation*, while the process of the development of properties characteristic of the tissues of an adult organism is designated *histogenesis*. The processes of histogenesis in different germs differ in general in their character and direction.

The differentiation of the embryo, i.e. the development of organ and tissue rudiments, which become more and more heterogeneous, from the relatively homogeneous cell material of the germ layers is paralleled by the development and intensification of *integration*, i.e. the incorporation of parts into a harmoniously developing single whole.

This interaction is at first accomplished by primitive methods (biochemical effect of cells), but later the nervous system and the endocrine glands subordinate to it become responsible for the integrating function.

During the development of the organs and tissues the cells of the embryonic germs grow into each other, unite with cells of another differentiation and from other germs, thus achieving new interconnections, and form different regular combinations characteristic of each organ.

With the incorporation in the rudiments of organs, the complexes of cells of different qualities are arranged in a regular manner in them and are orientated topographically in a definite way in relation to the neighbouring anatomical structures and the environment.

The conspicuousness of growth is very unequal in the different embryonic germs in different stages of embryogenesis. The further the development, the closer (though very slowly in general) the changes occurring in the embryo bring the relationship of its parts to the definitive state. This state is achieved with the conclusion of growth, by about the age of 20 years, but its general contours are outlined much earlier. The uneven growth of the embryonic germs is of great significance in this process. The germ of the skeletogenous mesenchyme, for instance, grows intensively. Because of the powerful development of the intercellular substance the skeletal tissues account for approx-

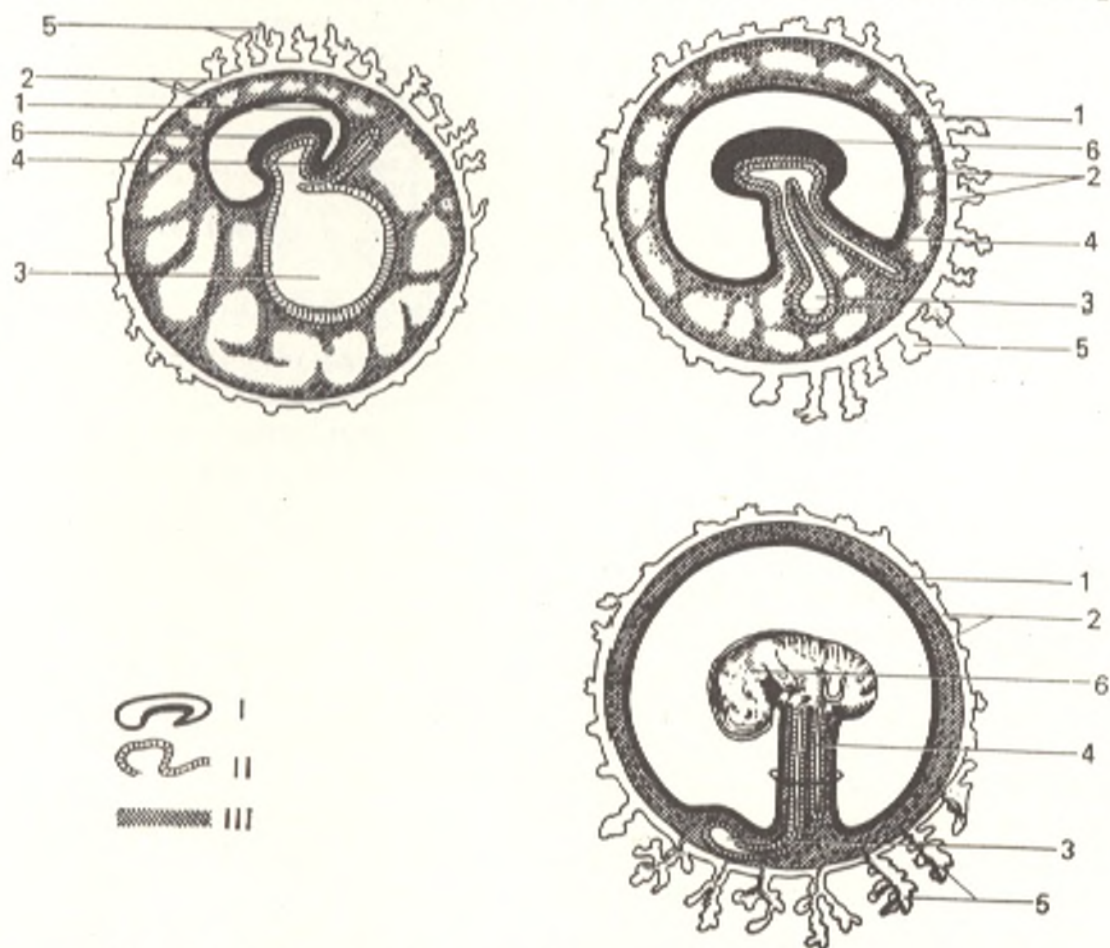


Fig. 5. Development of the embryo and extraembryonic parts.

I, ectoderm;  
II, entoderm;  
III, mesoderm  
1, amnion;  
2, chorion;

3, yolk sac;  
4, allantois;  
5, chorionic villi;  
6, embryo;

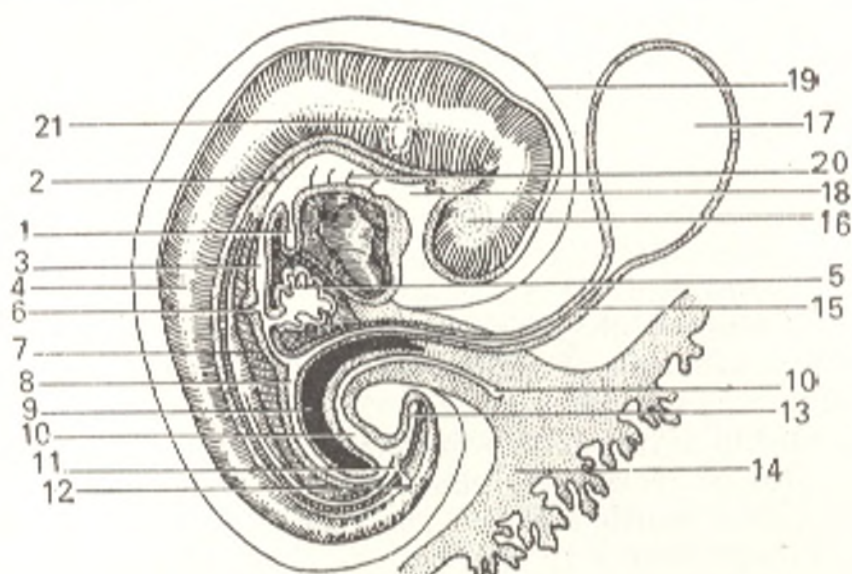


Fig. 6. Human embryo (beginning of the 5th week).

- |                                |                              |
|--------------------------------|------------------------------|
| 1, lung germ;                  | 12, ureter germ;             |
| 2, chorda dorsalis;            | 13, hindgut;                 |
| 3, stomach;                    | 14, chorion;                 |
| 4, spinal cord;                | 15, ductus omphaloentericus; |
| 5, liver;                      | 16, eye;                     |
| 6, posterior germ of pancreas; | 17, yolk sac;                |
| 7, primary mesentery;          | 18, foregut;                 |
| 8, midgut;                     | 19, amnion;                  |
| 9, pleuroperitoneal cavity;    | 20, branchial pouches;       |
| 10, allantois, urinary sac;    | 21, germ of internal ear     |
| 11, cloaca;                    |                              |

imately 20 per cent of the total body weight of an adult. A large part of the human body is composed of the myotome derivatives, the skeletal musculature, which makes up about 40 per cent of the total body weight. The other embryonic germs yield considerably to the mesenchyme and myotomes in the contribution of their derivatives to the formation of the adult organism.

The epithelial lining of the small intestine, for instance, accounts for only 1/50 of the thickness of the intestinal wall in an adult and constitutes a very small part of the body; in the embryo, in contrast, the intestinal entoderm is an incomparably larger part of its body (in that developmental period). At the same time, the surface dimensions of the epithelial tissues in an adult are very extensive. According to rough calculations, the epithelium of the villi of the small intestine covers a surface of about 43 m<sup>2</sup>, while the surface of the glands in it measures 14 m<sup>2</sup>.

One of the germs of the embryonic intestinal entoderm develops into the liver which in an adult weighs 1.5 kg on the average and accounts for approximately 1/50 of the body weight. In an embryo 31 mm long, the liver constitutes 10 per cent of its volume; in the newborn the liver weighs about 150 g, i.e. accounts for about 1/20 of the body weight. These figures illustrate that the weight of the liver in relation to the total body weight in a newborn is more than twice that in an adult. The parts of one and the same organ may grow unequally, for example the lobes of the liver, the cortex and medulla of the adrenal gland. The unequal growth is sharply reflected in the external

shape of the embryo and the age changes in the proportions of the parts of its body.

At the end of the second month of intrauterine development, the head of the embryo is disproportionately large (because of the powerful development of the brain); the pelvis and short lower limbs are disproportionately small. In the fifth and tenth months of development, the head constitutes  $\frac{1}{3}$  and  $\frac{1}{4}$  of the total length of the embryo's body, respectively.

The rate of growth is incomparably greater in the intrauterine period than after birth. Comparison between the mass of the zygote, the body of the newborn, and the body of an adult shows that a newborn child is 32 000 000 times larger than a zygote, while the body weight of an adult is only 20-25 times that of a newborn. It should, moreover, be taken into account that nine months pass from conception to birth but 20 years, if not more, from birth to maturity.

The organs and tissues of the embryo which arise from the germs start functioning specifically when histological differentiation begins in them. This differs in time in the different organs; in general, those organs whose functioning is necessary in the given moment for the further development of the embryo come ahead (the cardiovascular system, the haemopoietic tissues, some endocrine glands, etc.).

Auxiliary *extraembryonic organs* play a significant role in the development of the embryo equally with the organs forming within it (Figs. 5 and 6).

#### THE AUXILIARY EXTRAEMBRYONIC ORGANS AND THE CONNECTION OF THE EMBRYO WITH THE MATERNAL ORGANISM

The extraembryonic organs are as follows: (1) the chorion; (2) the amnion; (3) the allantois, and (4) the yolk sac. The developing human embryo is covered with two membranes, an outer (chorion) and an inner (amnion) membrane. The sources from which the chorion and its components are derived are pointed out above in the paragraph dealing with cleavage. The *chorion* (see Fig. 5) forms the outer membrane of the foetus and envelops the embryo together with the amniotic and yolk sacs. Its relation to the uterine mucous membrane differs considerably in the different groups of mammals.

The interrelation between the embryo and the maternal organism in many lower viviparous mammals is relatively simple: a placenta does not develop in them and a small amount of yolk and a nutrient secretion produced by the uterine glands serve as the food materials for the embryo. Mammals devoid of placenta (Marsupials, Monotremata) form the group aplacentalia.

In higher vertebrate animals possessing the placenta and included because of this feature in the subclass placentalia, the interrelationship between the embryo and the maternal organism occurs in different ways. It can be seen that the placenta becomes gradually more complex and modified in the different representatives of this subclass. In the human placenta, the branching villi of the chorion grow into wide blood vessels, the lacunae, located in the mucous membrane of the uterus. Such a placenta is called haemochorial (Gk *haima* blood); this term emphasizes the haemotrophic

character of the human placenta. The placenta is connected to the foetus by the *umbilical cord* containing the umbilical (placental) vessels which convey blood from the placenta to the body of the foetus and in the opposite direction. These vessels originate from the allantois which protrudes from the ventral wall of the gut into the extraembryonic part through the umbilical orifice.

The *amnion* (Gk the foetal membrane), the inner membrane of the foetus, is a vesicle filled with fluid (amniotic), because of which it is called the water membrane; in it the embryo develops and remains until birth. All higher vertebrates have an amnion. Because of this feature they are united in the group amniota; the lower vertebrates form, correspondingly, the group anamniota (i.e. animals which do not produce an amnion). The amniotic fluid takes part in metabolism, protects the foetus from harmful mechanical effects, and facilitates an easy process of labour.

The *allantois*, or the urinary sac, resembles a sausage in shape, hence the name (Gk *allas* sausage, *eidos* form). In the higher vertebrates and in man, it plays an important, although dissimilar, role. In reptiles and birds, for example, it provides for gaseous exchange. In its walls numerous blood vessels develop which are joined to the vessels of the embryo. The allantois is concerned with the excretory function; metabolites, urates, accumulate in it (for which reason it is called the urinary sac).

In animals of the placentalia group, the allantois loses its importance as an organ of metabolism. In man the entodermal germ of this extraembryonic organ is reduced, but powerful development of blood vessels takes place in the extraembryonic mesenchyme surrounding the reduced germ; these vessels are converted later to the vessels of the umbilical cord. Allantoic circulation, of later phylogenetic origin, provides metabolism for the embryo. This is the new significance acquired by the allantois.

The *yolk sac* in all animals whose ova have no store of food materials in the form of the yolk loses its significance as the source of nutrients for the embryo. The mesenchyme of the yolk sac wall gives rise to the first blood vessels and the first blood cells in them, but vitelline (L *vitellus* yolk) circulation is greatly reduced in the placentalia animals and in man.

The appearance of the yolk sac in a human is of phylogenetic significance. As is pointed out above, extremely early and intensive development of the extraembryonic parts, i.e. the amnion and the yolk sac, as well as the trophoblast, is a sign characteristic of man and anthropoid apes. In man, in distinction from all animals, the extraembryonic mesoderm develops most intensively. As a result extraembryonic factors creating conditions for the development of the embryo as such appear before the embryo itself forms.

## THE EXTRAUTERINE DEVELOPMENTAL PERIOD OF THE ORGANISM

The act of birth may be considered a dialectic leap in the development of the individual who leaves the constant environment of the womb and enters the external environment marked by continuously changing conditions.



The quality of metabolism and the organs concerned with it also alter. In the intrauterine period, nutrition and respiration are accomplished through the mother's blood and the placenta (placental circulation). In the extrauterine period, these processes take place through the newborn's alimentary and respiratory organs. Placental circulation is replaced by pulmonary circulation as soon as the lungs begin functioning.

The following age periods are distinguished in the life of a human after birth.

I. The neonatal period (the first two or three weeks after birth) in which the organism must become adapted to the new conditions of extrauterine life. The body of the newborn differs drastically from that of an adult in shape and dimensions. The height of a newborn is 50 cm on the average and the weight 3250-3500 g. The head (the cerebral part mainly) is very large and accounts for  $1/4$  of the height (in an adult the head constitutes  $1/7$ - $1/8$  of the height), the legs, in contrast, are short ( $1/3$  of the height). The abdomen is larger than the chest and bulges forward because the pelvis is narrow. The upper and lower limbs are approximately equal in length. The predominance of the upper over the lower part of the body is explained by its better supply of blood in the womb (see "Circulation in the Foetus").

II. The suckling period (infancy) from the age of 4 weeks to 12 months.

III. The period of deciduous dentition (natural infancy) from the age of 12 months to 7 years, i.e. from the beginning of the eruption of the deciduous teeth to the beginning of the eruption of the permanent teeth. The secondary sex characters, both in girls and in boys, are poorly pronounced.

This period is separated into the pre-preschool (12 months to 3 years) and preschool (3 to 7 years) periods.

IV. The adolescence period (bisexual childhood) lasts from the age of 7 to 15-16 years, from the beginning of permanent teeth eruption to the end of the eruption of all second molars, to the beginning of puberty. The grade school age (7-11 years) and the middle school age (12-15-16 years) are distinguished in this period. The middle school age is characterized by intensified formation of secondary sex characters in both sexes and because of this the period is also known as prepuberty.

V. The puberty period or juvenile (*L. juvenis* youth) age. This period begins at the end of eruption of the second molars and lasts till growth ceases and physical maturity is attained.

This period lasts from the age of 13-14 to the age of 18 in girls and from the age of 15-16 to the age of 19-23 in boys. The period between 16 and 18 years of age is also known as the high school age; the middle and high school age are known together as the teen-age period. Secondary sex characters develop during puberty, as a result of which boys become young men, and girls become young women.

In this period the height and body proportions come close to those of adults. Two periods of intensified growth are distinguished: at the end of natural infancy (5 to 7 years of age) and during puberty (girls at the age of 11-14 years and boys at the age of 13-16 years). Growth also continues after the onset of puberty.

Since World War II, pubescence has been found to occur earlier. It has also been noted in the Soviet Union that the modern generation is better developed physically than previous generations.

VI. The change of the organism from the juvenile age to the adult state does not mean that development ceases. It continues but changes in the form and structure of the body are less marked.

The following three stages are distinguished in the *development of an adult organism*.

1. Prime of adulthood. This stage lasts from the age of 25 to the age of 45 in males and from 20 to 40 years of age in females.

2. Maturity lasting to the time of the appearance of changes associated with old age (attrition and loss of teeth, obliteration of the sutures of the skull).

3. Old age (senium) characterized by progressive involution of the bodily organs and systems which leads to death.

There are also other gradations of adulthood: (1) young adults of college age (19 to 30 years of age); (2) middle-aged, mature adults (31 to 50 years of age); (3) elderly adults (51 to 70 years of age); (4) old adults (over 70 years of age). Three stages of ageing are distinguished according to the latest classification (World Health Organization, 1964): (1) middle-aged people (45 to 59 years of age); (2) elderly people (60 to 74 years of age); (3) people of old age (75 years of age and older).

People 90 years of age and older form the longevity group.

## THE FORM, SIZE AND SEX OF THE HUMAN BODY

The human body is made up of the **head** (*caput*), **neck** (*collum*), **trunk** (*truncus*), and two pairs of **limbs**, or **extremities**, the **upper** (*membra s. extremitates [BNA] superiores*) and **lower** (*membra s. extremitates [BNA] inferiores*). The following parts are distinguished in the head: the **forehead** (*frons*); the **highest point of the skull** (*vertex*); the **back of the head** (*occiput*); the **temples** (*tempora*) and the **face** (*facies*). The trunk consists of the **chest** (*thorax*), the **abdomen** (*abdomen*) and the **back** (*dorsum*). The following lines are drawn for orientation on the chest surface: (1) **midline** (*linea mediana anterior*); (2) **sternal line** (*linea sternalis*) stretching along the sternal border; (3) **mamillary line** (*linea mamillaris s. medioclavicularis*) passing through the nipple or the middle of the clavicle; (4) **parasternal line** (*linea parasternalis*) passing midway between the sternal and mamillary lines; (5) **anterior**, (6) **middle**, and (7) **posterior axillary lines** (*lineae axillarea anterior, media and posterior*), the first and last passing through the anterior and posterior folds of the axilla, respectively, and the middle line passing through the point midway between these folds; (8) **scapular line** (*linea scapularis*) passing through the inferior angle of the scapula.

The abdomen is divided by two horizontal lines, one drawn between the ends of the 10th ribs and the other between both the anterior superior iliac spines, into three parts, one located above another: the **upper part of the abdomen** (*epigastrium*), the **middle part** (*mesogastrium*) and the **lower**

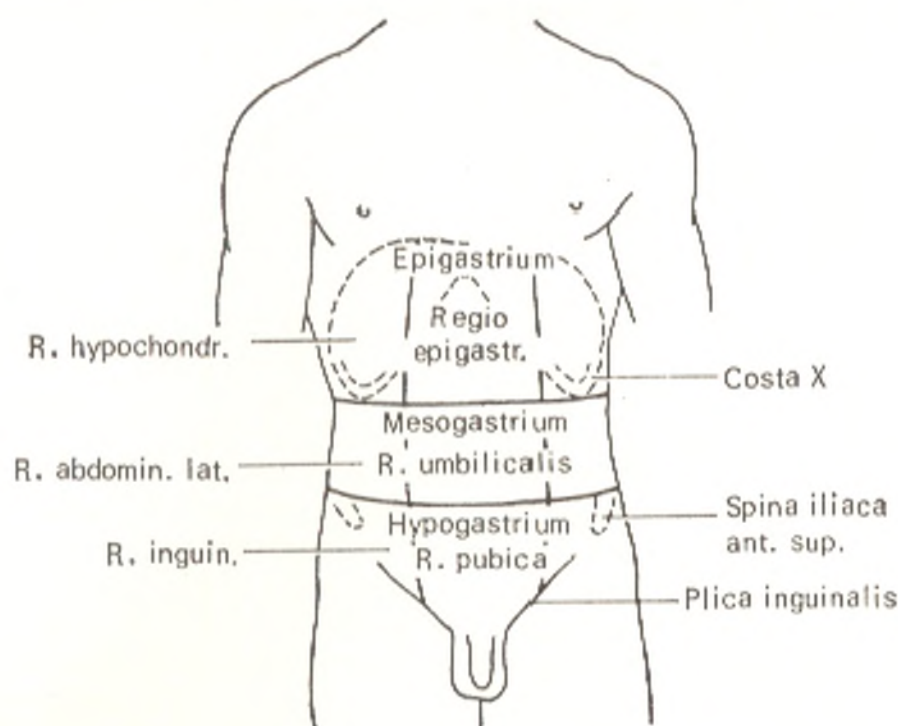
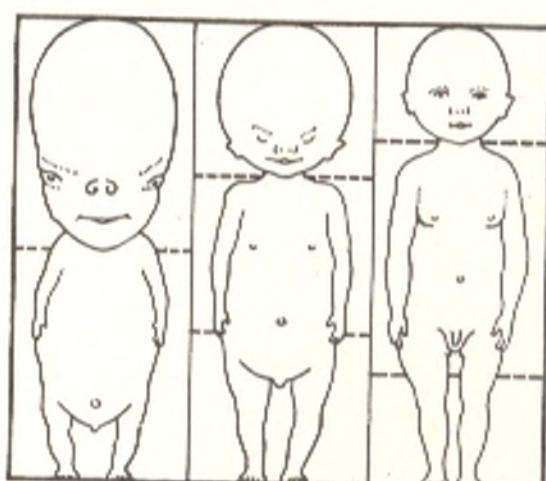


Fig. 7. Subdivision of the abdomen into regions

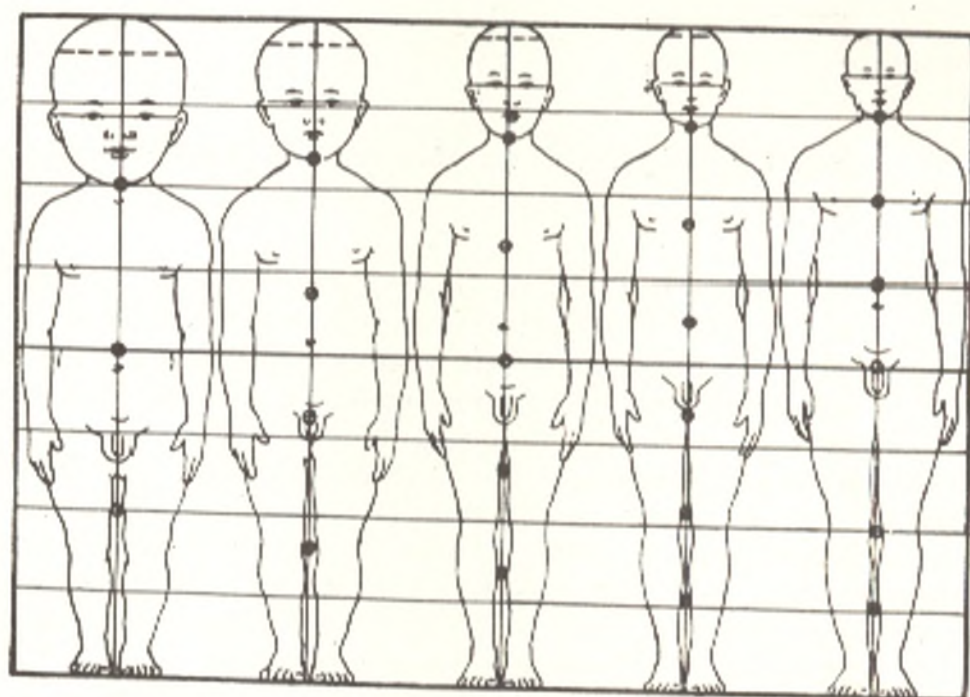
part (*hypogastrium*) (Fig. 7). Each of these three parts of the abdomen is subdivided by two vertical lines into three secondary regions: the epigastrium is divided into a middle epigastric region (*regio epigastrica*) and two lateral regions, the right and left hypochondrium (*regiones hypochondriacae dextra* and *sinistra*). The middle abdomen is divided in the same manner into a medial umbilical region (*regio umbilicalis*) and two lateral, right and left lumbar regions (*regiones abdominales laterales, dextra* and *sinistra*). Finally, the hypogastrium is divided into the pubic region (*regio pubica*) and two lateral, right and left inguinal regions (*regiones inguinales, dextra* and *sinistra*). The upper limb is divided into the arm (*brachium*), the forearm (*antebrachium*) and the hand (*manus*); the palm (*palma manus*), the back (*dorsum manus*) and the fingers (*digiti manus*) are distinguished in the hand. The lower limb, in turn, is divided into the following parts: the thigh (*femur*), the leg (*crus*), and the foot (*pes*), in which the sole (*planta*), the dorsum of foot (*dorsum pedis*), and the toes (*digiti pedis*) are distinguished.

According to Martin, the individual normal height ranges from 129.9 (dwarf body length) to 200 cm and more (giant body length) in males and from 148.9 to 187.0 cm and more in females. Individuals of small (141 cm) and big (182 cm) height are encountered in one and the same geographic zone (Equatorial Africa). The length of the body, therefore, is not related to the geographic location of the various ethnic groups or to the climate in which they live (Ginzburg, 1963).

The proportions of the body are determined by the age and sex. In the process of foetal development, the upper parts of the body develop intensely, but after birth intense development of the lower parts occurs. As a result the height of the head only doubles



a



b

Fig. 8. Bodily proportions of the embryo, foetus, and newborn (a). Postnatal age changes in the proportions of the body (b)

after birth, while the length of the trunk increases threefold, the length of the upper limbs fourfold, and the length of the lower limbs fivefold (Fig. 8).

Some body dimensions of males and females (Russian) of the same height are shown in the following Table (after V.V. Bunak, 1937).

The *sex characters* distinguishing a male from a female are divided into primary and secondary. The reproductive organs, the sex glands in the first instance, which determine the sex are the primary characters. All the other characters are secondary. Females are smaller in height (by 12 cm on the

	Body length			
	165 cm		153 cm	
	M	F	M	F
Head + trunk length	77.0	75.1	72.7	71.3
Trunk length	51.5	51.2	49.0	48.8
Shoulder width	37.5	35.6	35.4	34.0
Pelvis width	28.0	29.5	26.2	27.4
Lower limb length	88.0	89.2	81.2	82.9
Upper limb length	74.5	74.5	69.1	69.1

average) and weigh less (a female weighs 55 kg on the average). In relation to the body height, the trunk is shorter in a female than in a male, but the lower limbs of a female are longer. The shoulders are narrower in females, but the lower part of the trunk is wider because a female pelvis is wider than the pelvis of males. The chest of a female is shorter and narrower than that of a male as a result of which, as well as because the female pelvis is inclined more to the front, the abdomen of a female is longer. The average total bulk of muscles makes up 40 per cent of total body weight in males but only 32 per cent in females, as a consequence the physical strength of females is in general less than that of males. The adipose tissue is developed more copiously in females. Developed mammary glands are a typical secondary sex character of females; in males these glands are rudimentary. The skin of males is thicker and coarser and, moreover, is more hairy (especially on the face).

## CONSTITUTION

The general concept "organism" defined above does not adequately portray the notion of an actual individual who must be dealt with both in the study of anatomy and in the physician's practice. Closer study of individuals discloses marked differences between them, both morphological and functional. These differences provided the material for the science of the human constitution. Constitution is the totality of those features of build which are associated with specific, mainly biochemical, peculiarities of the organism's vital activity. These peculiarities are manifested morphologically by the deposit of fat and the development of the musculature, which affects the shape of the chest, abdomen, and back.

The term *constitution* usually means a complex of individual physiological and morphological features, related only to the given individual, that form under definite social and natural conditions and are displayed in the organism's reaction to different influences (pathological among others). Certain hereditary factors acquired from previous generations are accepted as the kernel of this complex. Therefore, in each individual internal (hereditary) and external (environmental in the broad sense of the word) factors unite to make up a specific body build or constitution. Differences in height, for instance, are associated with heredity but are also determined by environ-

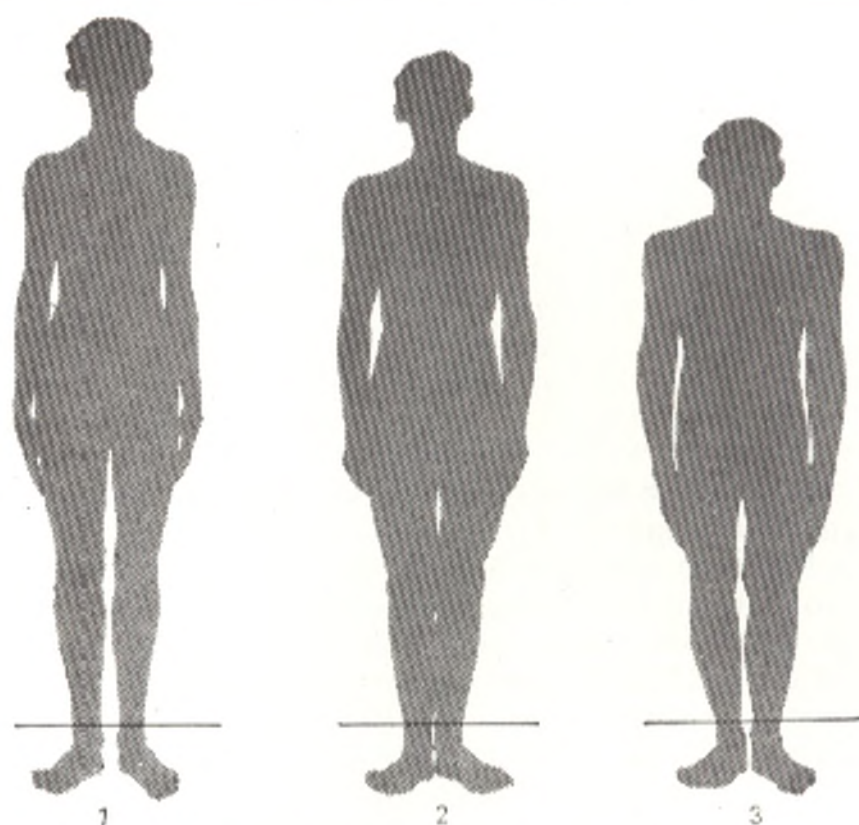


Fig. 9. Types of constitution (after Chernorutsky).

1, asthenic; 2, normosthenic; 3, hypersthenic

mental influences to which the organism is exposed during development (nutrition, occupation, living conditions, etc.).

Despite the diversity of individual features encountered among humans, these features may nonetheless be grouped into types of constitution. Three constitutional types are differentiated from the morphological standpoint (Fig. 9).

1. **Hypersthenic**, marked by predominant growth in breadth, massive bulk, and good nourishment. The trunk is relatively long, but the limbs are short. The head, chest, and abdomen are very large because the corresponding body cavities are greatly developed. There is relative predominance of the size of the abdomen over that of the chest and of the transverse dimensions over the longitudinal dimensions.

2. **Asthenic**, characterized by predominant growth in length, just proportions, slenderness of body build, and poor general development. The limbs predominate over a relatively short trunk, the chest over the abdomen, and the longitudinal dimensions over the transverse dimensions.

3. **Normosthenic**, a constitutional type intermediate between the other two.

The internal structure, i.e. the size, shape, and location of the viscera and vessels, conforms to the external body structure. In persons of hypersthenic constitution, for instance, the heart is relatively large, and it lies transversely on a raised diaphragm. The aorta is wide, and the lungs are short.

The large and relatively short stomach is located in a high, transverse position. The loops of the small intestine stretch mainly horizontally. The liver, pancreas, kidneys, and spleen are large.

In asthenics the picture is entirely different: most of the viscera are lower, as if they were ptotic, and smaller; the lungs are longer than those in hypersthenics in accordance with the length of the thoracic cage.

Because of the correlation between the internal and external structure, the features of the internal structure can be determined from the external bodily structure. In exact diagnosis, therefore, it is important to take into account the constitution of the patient examined.

According to another classification, *three types of body build* are also distinguished.

1. **Dolichomorphic**, marked by a body that is long or of above average height, a relatively short trunk, a small chest circumference, narrow or moderately wide shoulders, long lower limbs, and slight tilting of the pelvis.

2. **Brachymorphic**, characterized by moderate or shorter than average height, a relatively long trunk, a large chest circumference, relatively wide shoulders, short lower limbs, and marked inclination of the pelvis.

3. **Mesomorphic** type is an average body build, intermediate between the two described above.

## NORM AND ANOMALIES

In the process of formation the human organism became adapted to the environment. As a result a definite equilibrium was established between it and the concrete environmental conditions. This equilibrium, attained because of definite morphological and functional features of the organism, is designated the **norm** and the body structure corresponding to the norm is considered normal. Since different factors of the internal and external environment cause an effect on the organism, its structure and the structure of its organs and systems vary under normal conditions. However, this variability does not disturb the established equilibrium with the environment. The norm, therefore, is not something fixed and unchangeable, as is claimed by advocates of metaphysics. Rather, it is diverse and is represented by many structural variants which together constitute the organism's variability caused by both hereditary and environmental factors.

The structure of the organism and its organs has many variations, *variants of the norm*, some of which are encountered more and others less frequently. According to variation statistics, they form a variation series at the ends of which are extreme forms of individual changeability. The norm is therefore the sum total of all the structural variants characteristic of man as a species.

An **anomaly** (Gk *anomalos* irregular) is a deviation from the norm; it is manifested to different degrees. Anomalies also have variations, some of which result from improper development but do not disturb the established equilibrium between the organism and the environment and therefore have no effect on function. Location of the heart in the right side (dextrocar-

dia) or abnormal position of the viscera (*situs viscerum inversus*) serve to illustrate the point. Other anomalies are attended by impaired function of the organism or some of the organs. They disturb the equilibrium between the organism and the environment (e.g. cleft palate, see Fig. 230) or are even incompatible with life (e.g. absence of the skull or *acrania*, absence of the heart or *acardia*, etc.). Such a gross developmental anomaly is called a *monstrosity* or a *teratism*. The branch of anatomy and embryology concerned with the study of anomalies and malformations is called *teratology* (Gk *teras* monster, *logos* science). Teratology is also part of pathological anatomy because it studies structures pathological in essence.

## ANATOMICAL TERMINOLOGY

A person beginning to study anatomy is struck first of all by the copious terminology that must be firmly understood and completely mastered by every student and physician. These terms usually designate spatial relations, the shape or size of various organs, and so forth.

In mathematics and physical geography, certain initial points and planes are accepted from which distances are measured to establish spatial relations. In anatomy as well, there are generally accepted designations of perpendicular planes by means of which the position of organs or their parts in space is determined exactly. Three such planes are of primary importance: sagittal, frontal, and horizontal. It should be borne in mind that the planes are related to an erect human body (Fig. 10).

The **sagittal** plane is a vertical plane by means of which we divide the body mentally (for example, a fixed, frozen cadaver) with an arrow (*L sagitta* arrow) piercing it from front to back and with an arrow along the length of the body. The sagittal plane that passes through the middle of the body and divides it into two symmetrical, right and left, parts is called the **median** plane (*L medius* middle) (Fig. 11). A plane drawn also vertically but at right angles to the sagittal plane is called the **frontal** plane and is parallel to the forehead (*L frons* forehead). The frontal plane divides the body into the front and back parts. The third, **horizontal**, plane in accordance with its name passes horizontally, i.e. at right angles to both the sagittal and the frontal planes. It divides the body into the upper and lower halves.

The positions of the different points or lines in these planes are designated as follows: those located nearer to the median plane are called **medial** (*medialis*) (*L medius* middle); those located further from the median plane are designated **lateral** (*lateralis*) (*L latus* side). Points and lines found on a front to back plane are designated as follows: those located nearer to the front surface of the body are called **anterior** or **ventral** (*ventralis*) (*L venter* belly); those nearer to the back are known as **posterior** or **dorsal** (*dorsalis*). The following points and lines are distinguished in the vertical plane: those nearer to the upper end of the body are called **upper**, **superior**, or **cranial** (*cranialis*) (Gk *kranion* skull); those nearer to the lower end are referred to as **lower**, **inferior** or **caudal** (*caudalis*) (*L cauda* tail).



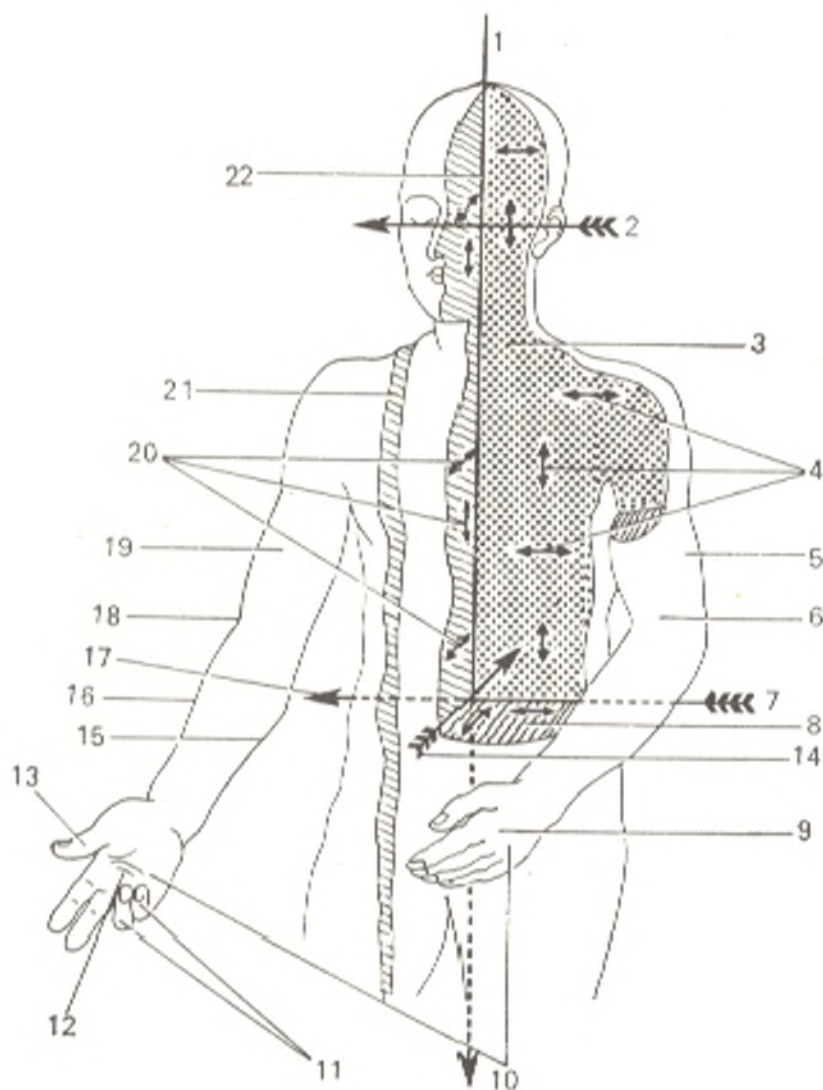


Fig. 10. Diagram of axes and planes of the human body.

- 1, vertical axis;  
 2, transverse axis;  
 3, one of the frontal planes;  
 4, horizontal and vertical lines on the frontal plane;  
 5, the arm is drawn to the trunk (adductio);  
 6, the left upper limb is flexed at the elbow joint (flexio);  
 7 and 17, transverse axis, one of the horizontal axes in the frontal plane;  
 8, transverse plane (one of the horizontal planes), the arrows on it indicate the sagittal direction (from front to back) and the transverse direction (from left to right and from right to left);  
 9, the hand is pronated, the thumb is directed at the trunk (pronatio);  
 10, change from the pronated position to supination, example of rotation (rotatio);  
 11, the ring and little fingers are flexed (flexio);  
 12, the hand is supinated, the thumb faces outward (supinatio);  
 13, the thumb is drawn away from the median line (abduction);  
 14, sagittal axis;  
 15, medial margin of the forearm;  
 16, lateral margin of the forearm;  
 18, the right upper limb is extended at the elbow joint (extensio);  
 19, the arm is drawn away from the trunk (abductio);  
 20, horizontal and vertical lines in the sagittal plane (arrows);  
 21, one of the parasagittal planes;  
 22, median plane, plane of symmetry (one of the sagittal planes)

The terms proximal and distal are used in reference to the parts of the limbs. *Proximal* (L *proximus* nearest) is applied to parts nearer to the point of origin of the limb from the trunk; *distal*, in contrast, is a term ap-



Fig. 11. Diagram of transverse section through the trunk.

1, median line (mediana);  
2, sagittal line;  
3, frontal line

plied to parts farthest from the trunk (*L. distare* to be distant). On the upper limb, for instance, the elbow is proximal in comparison to the fingers, while the latter are distal in relation to the elbow.

The terms **external** (*externus*) and **internal** (*internus*) are used mainly to designate positions in relation to the body cavities and whole organs, either outward or inward; the terms **superficial** (*superficialis*) and **deep** (*profundus*) are used for organs located "less deep" or "more deep" in relation to the surface of the body or organ.

The commonly used terms for size are **great** (*magnus*); **small** (*parvus*); **greater** (*major*); **lesser** (*minor*). The last two terms, major and minor, are used to designate the comparative size of two related or identical structures, e.g. tuberculum majus and minus on the humerus. The term *magnus* (great) does not imply the presence of another identical but smaller structure. For instance, *nervus auricularis magnus*, the great auricular nerve, is called so because of its thick trunk; there is no *nervus auricularis parvus*.

The shapes of the various structures, particularly in osteology, have many designations whose meaning is best mastered during study of these structures.

A new anatomical nomenclature, the Paris Nomina Anatomica, was approved by the Sixth International Congress of Anatomists held in Paris in 1955. This textbook, therefore, uses the terms of the Paris Nomina Anatomica (PNA) with amendments and additions approved by the seventh and eighth international congresses held in New York in 1960 and Wiesbaden in 1965, respectively, and by the latest international congresses including the tenth congress held in Tokyo in 1975. Some terms from the old Basle Nomina Anatomica, from which the names of diseases were derived and which became firmly established in clinical literature, are preserved. They are given in the text next to the new terms, followed by the letter *s.* (i.e. *seu* or) and by the abbreviation for the Basle Nomina Anatomica (BNA). For example: *axis s. epistropheus* (BNA). This means that *axis* is a new term from the Paris classification, while *epistropheus* is the old Basle term. Some of the terms are given in abbreviated form: *art.*—articulatio (joint); *lig.*—ligamentum (ligament), *a.*—arteria (artery), *aa.*—arteriae (arteries); *v.*—vena (vein), *vv.*—venae (veins); *n.*—nervus (nerve), *nn.*—nervi (nerves); *m.*—musculus (muscle), *mm.*—musculi (muscles).

# THE SUPPORTING (WEIGHT-BEARING) AND LOCOMOTOR SYSTEM

## INTRODUCTION

Adaptation to the environment by movement is the principal property distinguishing an animal from a plant. In his book *Twenty Years' Experience in Objective Study of Nervous Activity* published in 1951, Pavlov wrote that the most important manifestation of the higher activity of an animal, i.e. its visible response to the external world, is movement, the result of the activity of its skeleto-muscular system.

Three types of movement are encountered in the animal world: (1) amoeboid movement by means of pseudopodia, protrusions of the protoplasm, e.g. in amoeba; (2) ciliary movement by means of cilia, e.g. in infusoria; (3) muscular movement by means of special contractile muscle elements in most animals. In reflection of the process of phylogenesis, man has preserved all three types of movement in his body: the amoeboid movement of the leucocytes, the oscillation of the cilia of the ciliated epithelium, and the contraction of special cell elements, muscle fibres, which compose complexes called muscles. Contraction of the muscles is responsible for all movements of the body and its organs.

All the musculature in the organism can be classified as visceral or somatic. The *visceral* musculature is a component of the viscera located in the body; it consists for the most part of unstriated muscle cells and only partly of striated fibres (the cranial end of the alimentary tract, the muscles of the larynx and heart). The movements effected by it are mainly restricted to the viscera and do not change the position of the body itself in space. The *somatic* musculature, composed entirely of striated muscles, is located in the walls of the body (soma) cavities enclosing the viscera and also forms the main mass of the limbs. The movements performed by the somatic musculature are manifested by a change in the position of the whole body and its parts in their surroundings. The totality of the somatic musculature along with a small part of the skeletal muscles of the head (see section "Muscles of the Head") make up the **locomotor system** of the body to which the skeleton and its articulations also belong. Since in addition to the function of movement, this system also performs the function of bearing the weight of the body on the ground, it is also called the weight-bearing and locomotor system.

It should be kept in mind that the human organism is born, develops, and exists under the earth's gravitational pull (*L. gravis* heavy). Each movement of the body is concerned with overcoming this gravitation and the weight-bearing and locomotor system therefore performs an antigravitation

function too. That is why it can also be called the **antigravitation system**.

It is thus quite natural to distinguish the *passive* (the skeleton and its articulations) and *active* (muscles) parts of the locomotor system. Both parts are closely related functionally and originate from one and the same germ, the mesoderm. As a result, the weight-bearing and locomotor system is made up of three systems of organs: (1) bones, (2) their articulations or joints, and (3) muscles and their auxiliary devices. The weight-bearing and locomotor system constitutes the greater part of the total body mass. Its organs account for 72.45 per cent of the body weight of an adult. The musculature makes up about one-fifth of the total body weight, the skeleton between one-seventh and one-fifth. This explains the fact that the weight-bearing and locomotor system is the main determinant of the shape of the body and its separation into the trunk, head, and limbs.

# THE PASSIVE PART OF THE SUPPORTING (WEIGHT-BEARING) AND LOCOMOTOR SYSTEM OSTEOARTHROSYNDESMOLOGY, THE SCIENCE OF THE BONES AND THEIR ARTICULATIONS

## GENERAL OSTEOLOGY, OSTEOLOGIA

The **skeleton** (Gk *skeletos* dried up)<sup>1</sup> is a complex of hard structures that originate in the mesenchyme and possess mechanical importance. It consists of separate bones joined to each other by means of connective cartilaginous or bony tissue, which together make up the passive locomotor apparatus (system).

**The significance of the skeleton.** The bone system performs different functions, which are of either predominantly mechanical or predominantly biological significance. We shall discuss here the functions of *predominantly mechanical* importance. An internal skeleton, endoskeleton, is typical of all vertebrates. Some species among the vertebrates also have, besides an endoskeleton, a more or less developed outer skeleton, exoskeleton, arising in the skin (bony scales in the skin of fish). When the hard skeleton first appeared, it served as protection of the organism from harmful environmental effects (the exoskeleton of the invertebrates). As the endoskeleton developed in the vertebrates, it was at first a support (framework) for the soft tissues. Some parts of the skeleton became levers which could be set in motion by the muscles as a consequence of which the skeleton acquired the locomotor function. Thus the mechanical functions of the skeleton include protection, support, and movement.

*Support* (weight-bearing) is provided by attachment of the soft tissues and organs to the different parts of the skeleton. *Movement* is possible because the bones have the structure of long and short levers connected by mobile articulations and set in motion by muscles, which are regulated by the nervous system. Finally, *protection* is provided by the vertebral canal, which protects the spinal cord; a bone case, the skull, which protects the brain; the thoracic cage, which protects vitally important organs of the thoracic cavity (heart, lungs); and the pelvis, which protects the reproductive organs which are important for the continuance of the species.

The *biological function* of the bone system is associated with the participation of the skeleton in metabolism, particularly mineral metabolism (the skeleton is a reservoir of mineral salts, phosphorus, calcium, iron, etc.). This is important in understanding metabolic diseases (rickets, etc.) and in making diagnoses with radiant energy (X-rays, radioactive isotopes). The skeleton also performs the function of haemopoiesis since the bone marrow

<sup>1</sup> An ancient method of skeleton preparation consisted in drying the skeleton in the sun or in hot sand.

(medulla ossium) is located within the bones. Contrary to popular opinion, the bone is not simply a protective casing for the bone marrow, which is an organic component of the bone. Not simply the medulla, but the whole bone performs a haemopoietic function. The development and activity of the medulla are reflected in the structure of the bone matter (Krompecher), and conversely, the mechanical factors have an effect on the function of haemopoiesis: intensified movement promotes haemopoiesis. In developing a programme of physical exercise, therefore, it is necessary to take into account the unity of all skeletal functions.

**The development of the skeleton.** In the lower stages of organization as well as in the embryonic period, the first germ of the endoskeleton in all vertebrates is the notochord (*chorda dorsalis*) arising from the entoderm. The notochord is a characteristic sign of the lower representative of the phylum Chordata, the lancelet (*Amphioxus lanceolatus*) whose skeleton is made up of a cord stretching along the dorsal surface of the body and the connective tissue around it. In the lower species of vertebrates, i.e. the Cyclostomata, selachii (sharks), and cartilaginous ganoids, the connective-tissue skeleton around the notochord and along the remaining distance is replaced by a cartilaginous skeleton which, in turn, becomes bony in the higher organized vertebrates, from the teleost fish to the mammals. With the development of the bony skeleton, the notochord disappears except for negligible remnants (the nucleus pulposus of the intervertebral disc). Aqueous forms can make with a cartilaginous skeleton because the mechanical load experienced in water is incomparably less than that experienced on land. It is only the bony skeleton, however, that allowed animals to leave the water for the land, raise their body above the ground, and stand firmly on their legs.

Therefore, in the process of phylogenesis, three types of the skeleton replaced one another in sequence as a phenomenon of adaptation to the environment. This replacement also takes place in the ontogenesis of man during which three stages in the development of the skeleton are encountered: (1) *connective-tissue* (membranous); (2) *cartilaginous*, and (3) *bony*. Almost all bones go through these three developmental stages. The exceptions are the bones of the skull cap, most bones of the face, and parts of the clavicle, which form directly from connective tissue without going through the stage of the cartilage. These bones, called membrane bones, may be considered derivatives of an exoskeleton existing in former times which had been displaced deep in the mesoderm and which, with further evolution, became joined to the endoskeleton as additions to it.

## BONE AS AN ORGAN

**Bone** (*os, ossis*) as an organ of the living organism, consists of several tissues among which bone tissue is most important. The bulk and significance of bone tissue can be demonstrated on macerated bone (removed from the body, freed of the soft tissues, and treated anatomically by soaking and drying). Despite such treatment, the bone preserves its shape, size,

structure, and strength. The strength of the bone results from the combination of two main properties, hardness and elasticity, which are the result of certain chemical substances in the bone itself.

**The chemical composition and physical properties of bone.** Bone matter consists of two types of chemical material: organic (one-third), mainly ossein, and inorganic (two-thirds), mainly calcium salts, calcium phosphate in particular (51.04 per cent). When bone is exposed to an acid solution (hydrochloric, nitric, etc.), the calcium phosphate salts dissolve (decalcification, decalcination), while the organic material remains and preserves the shape of the bone, although it is soft and elastic. If bone is subjected to burning, however, the organic material burns away, while the inorganic material remains and also preserves the shape and hardness of the bone, although the bone is now very fragile. Therefore, the elasticity of bone is determined by ossein, whereas its strength depends on the mineral salts. The combination of inorganic and organic materials in the bone gives it exceptional strength and elasticity. The age changes in bone are also convincing evidence of this. The bones of young children, which contain comparatively greater amounts of ossein, are marked by greater pliability, and their fractures are consequently rare. In contrast, in old age, when the proportion of the organic and inorganic materials changes in favour of the latter, bones become less elastic and more fragile. As a result, bone fractures are encountered most frequently in individuals of old age. (The technique of X-ray examination of the skeleton of a living person is based on the impermeability of calcium to roentgen rays, while the possibility of obtaining labelled phosphorus atoms allows the performance of fine radiological studies.)

Bone also contains vitamins A, D, and C. A lack of salts or vitamin D in the period of growth reduces bone hardness and causes deformities of bones (rickets) in children. Vitamin A deficiency leads to abnormal thickness of bones, and the bone cavities and canals become empty.

**The structure of bone.** The structural unit of bone, visible with a magnifying lens or slight microscopic magnification, is the *osteon*, or the *Haversian system*, i.e. a system of bone lamellae arranged concentrically around a canal (Haversian canal) containing vessels and nerves (Fig. 12). The osteons are not densely situated, and the spaces between them are filled with intermediate (interstitial) bone lamellae. The osteons are not scattered at random but are arranged in accordance with the functional load exerted on the bone: parallel to the length of the bone in tubular bones, perpendicular to the vertical axis in spongy (cancellous) bone, and parallel to the bone surface and radially in the flat bones of the skull. Together with the intermediate lamellae, the osteons form the main middle layer of the bone matter lined inside (as viewed from the endosteum) with an inner layer of general bony lamellae and outside (as viewed from the periosteum) with an outer layer of general lamellae. This last layer is permeated with blood vessels passing from the periosteum into the bone matter in special canals called Volkmann's canals. It can be seen on macerated bone that these canals begin as numerous vascular openings (foramina vasculosa). The blood vessels conveyed in the Volkmann and Haversian canals provide for metabolism in the bone.

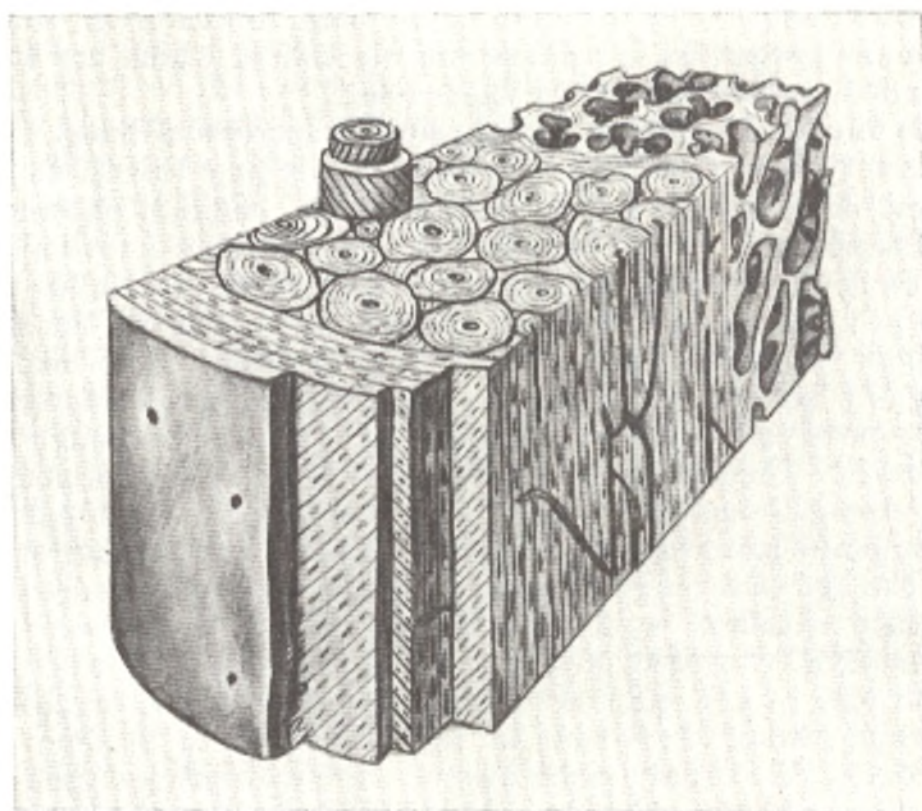


Fig. 12. Bone macro-microstructure.

Osteons form larger elements of the bone which are visible to the naked eye on a section of bone or on radiographs; these are the *trabeculae* of the bone matter. Two types of bone substances are built from the trabeculae. **Compact substance** (*substantia compacta*) forms if the trabeculae fit tightly to each other. Loosely arranged trabeculae, with bony pores between them, resembling a sponge, form the **spongy, or trabecular, substance** (*substantia spongiosa, s. trabecularis*). The distribution of the compact and spongy substances depends on the function of the bone. The compact substance is found in those bones and those parts of bones that are concerned predominantly with the functions of support (stanchion) and movement (levers), e.g. in the diaphysis of tubular bones. The spongy substance forms in bones or their parts that are large in bulk but which must be light and at the same time strong, e.g. in the epiphyses of tubular bones (Fig. 13).

The trabeculae of the spongy substance are arranged not randomly but in a regular pattern, also in accordance with the functions of the long bone or its part. Since bones experience two types of action, pressure and traction of muscles, the trabeculae are arranged on the lines of the forces of compression and stretching. In accordance with the different direction of these forces, the different bones or even their parts differ in structure. In the membrane bones of the skull cap, which perform predominantly a protective function, the spongy substance can be distinguished from the spongy substance of other bones which fulfil all three functions of the skeleton. This spongy substance is referred to as **diploe** (Gk *fold*); it consists of irregularly



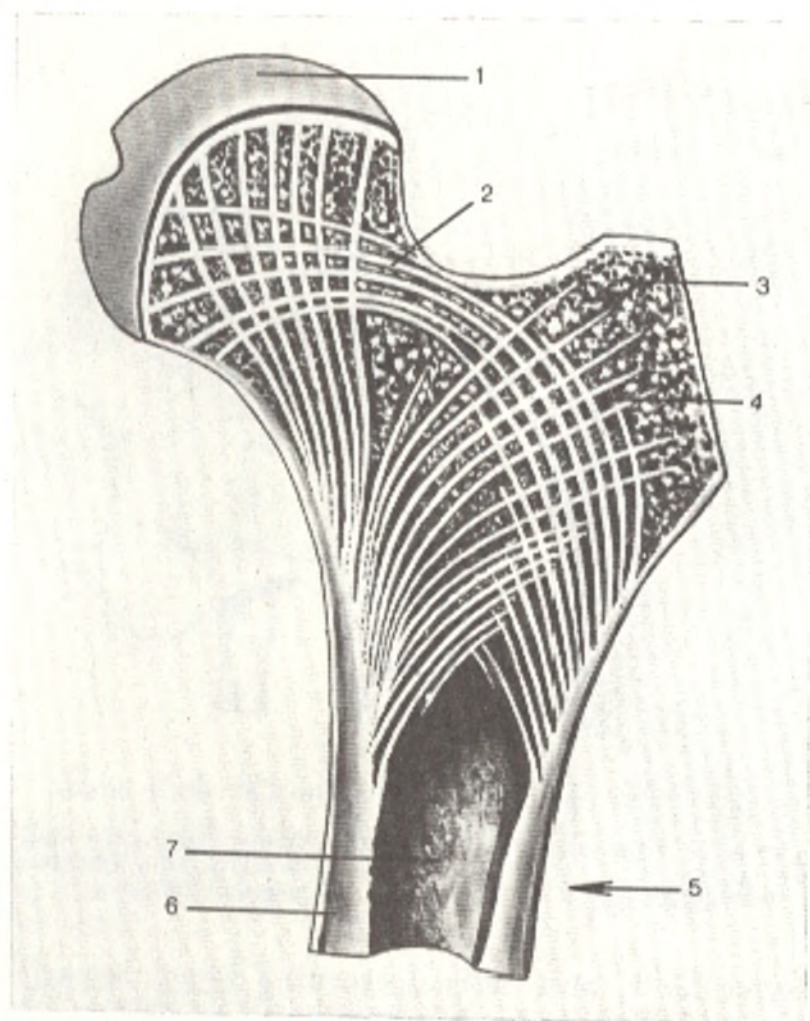


Fig. 13. Structure of the femur in section (after Kiss and Szentagóthai).

- |                      |                       |
|----------------------|-----------------------|
| 1, epiphysis;        | 5, diaphysis;         |
| 2, metaphysis;       | 6, compact substance; |
| 3, apophysis;        | 7, marrow cavity      |
| 4, spongy substance; |                       |

shaped bony compartments lying between two bone tables, the *outer (lamina externa)* and the *inner (lamina interna)*. The latter is also called vitreous (*lamina vitrea*) because it fractures more easily than the outer table in injury to the skull (Fig. 14).

The bony compartments contain the **bone marrow** (*medulla ossium*), the organ of haemopoiesis and biological protection of the organism. Bone marrow also takes part in nutrition and the development and growth of the bone. In the tubular bones, the medulla also fills the central canal which is consequently called the **marrow, or medullary, cavity** (*cavitas medullaris*). All the internal spaces of the bone are thus filled with marrow which is an indispensable part of the bone as an organ.

There are two types of bone marrow, red and yellow. **Red bone marrow** (*medulla ossium rubra*) (the details of its structure are described in the course in histology), is seen as a fine red mass of reticular tissues in whose meshes lie cells directly concerned with haemopoiesis and bone formation (cells

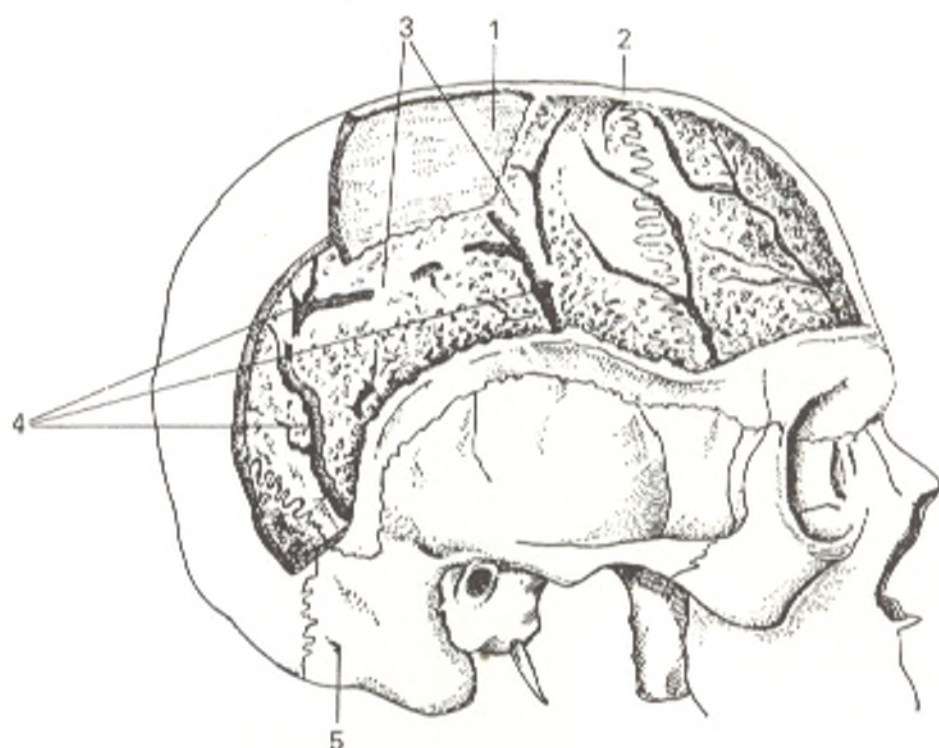


Fig. 14. Spongy substance of the flat skull bones.

1, inner table, or plate (compact bone substance);  
2, outer table, or plate;

3, spongy substance (diploe);  
4, canals in the spongy substance;  
5, mastoid foramen

forming bone, *osteoblasts*, and cells destroying bone, *osteoclasts*). It is permeated by nerves and blood vessels supplying nutrients to the marrow and the inner layers of the bone. The blood vessels and the blood elements lend the marrow its red colour. **Yellow bone marrow** (*medulla ossium flava*) owes its colour to the fat cells, of which it is mainly composed.

During the development and growth of the organism, when intensified haemopoietic and osteogenetic functions are necessary, the red bone marrow predominates (embryos and newborns have only the red marrow). With growth of the child the red marrow is gradually replaced by yellow marrow, which in adults fills the medullary cavities of the tubular bones entirely.

Bone, with the exception of the articular surfaces, is covered by **periosteum** (Fig. 15). The periosteum is a thin, strong, pale pink connective-tissue membrane which surrounds the bone on the outer surface and is attached to it with connective-tissue fibres penetrating the bone through special canaliculi. It consists of two layers, an outer fibrous layer and an inner bone-forming (osteogenetic, or cambial) layer. It is rich in nerves and vessels and contributes therefore to the nutrition and the growth of the bone in thickness. Nutrients are conveyed by blood vessels penetrating in great numbers the outer (cortical) layer of the bone from the periosteum through numerous vascular openings (foramina nutricia, or, to be more precise, foramina vasculosa). Growth of the bone occurs due to osteoblasts, which are located in the inner (cambial) layer and adhere to the bone. The articulating

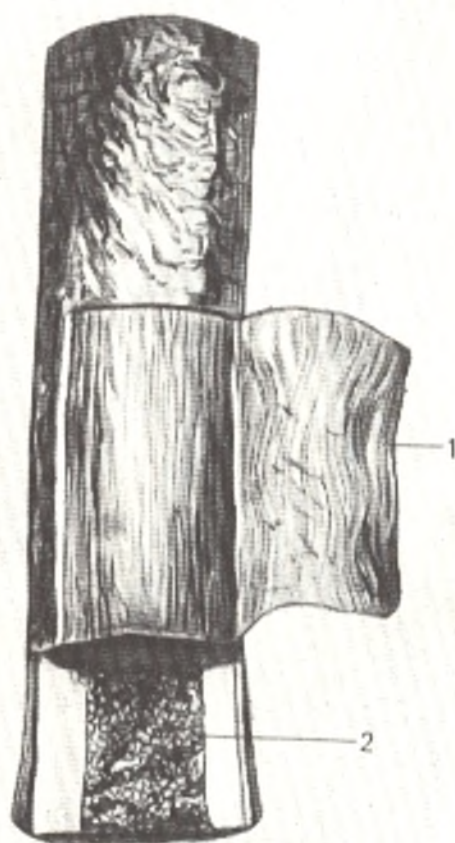


Fig. 15. Periosteum (1) and bone marrow (2) in the middle segment of the femur. Part of the periosteum is turned aside to the right

surfaces of bone are free of the periosteum and are covered by the **articular cartilage** (*cartilago articularis*), which has the common structure of hyaline cartilage and is referred to as the **epiphyseal cartilage** (*cartilago epiphysialis*).

Thus, the concept of bone as an organ includes the bone tissue forming the main mass of the bone, as well as the bone marrow, the periosteum, the articular cartilage, and numerous nerves and vessels.

## THE DEVELOPMENT OF BONE

Any bone is formed through the activity of young connective-tissue cells of mesenchymal origin, the *osteoblasts*, which produce the intercellular bone matter that performs the important function of support. According to the three developmental stages of the skeleton indicated above, bones may develop from connective or cartilaginous tissue. Therefore, the following **types of ossification** (*osteogenesis*) (*L os* bone) are distinguished: (1) intramembranous or endesmal; (2) perichondral; (3) periosteal; (4) enchondral.

1. *Intramembranous* or *endesmal* ossification (*Gk en in, into, desmos band*) occurs in the connective tissue of the primary (membrane) bones (Fig. 16). As a result of osteoblastic activity, islands of bone substance (the centre, nucleus, or point of ossification) appear on a certain area of embryonic connective tissue which has the contours of the future bone. This site of the

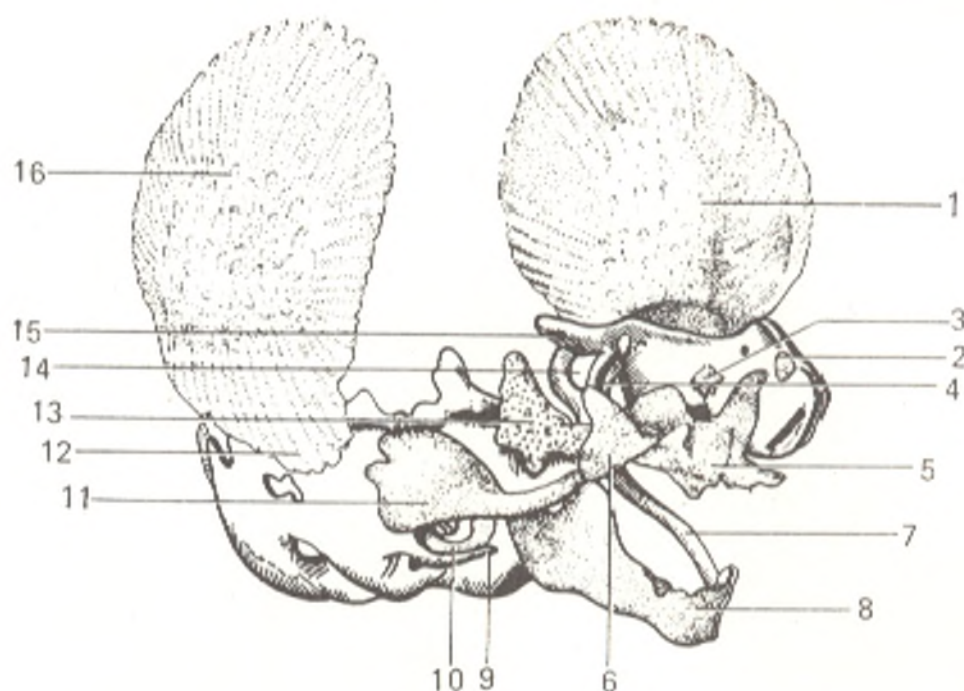


Fig. 16. The skull of a human embryo in the third month of development.

- |                        |                           |
|------------------------|---------------------------|
| 1, frontal bone;       | 10, tympanic bone;        |
| 2, nasal bone;         | 11, squama of temporal    |
| 3, lacrimal bone;      | bone;                     |
| 4, pterygoid bone;     | 12 and 16, parietal bone; |
| 5, maxilla;            | 13, great wing of sphen-  |
| 6, zygomatic bone;     | oid bone;                 |
| 7, Meckel's cartilage; | 14, optic canal;          |
| 8, mandible;           | 15, small wing of sphen-  |
| 9, styloid process;    | oid bone                  |

earliest possible appearance of bone tissue on the membrane bones of the skull cap is noticeable as a small tuber. From the primary centre the ossification process spreads radially in all directions by apposition of the bone substance on the periphery. The surface layers of the connective tissue giving rise to the membrane bone remain in the form of the periosteum which provides for the growth of bone in thickness.

2. *Perichondral* ossification (Gk *peri* around, *chondros* cartilage) takes place on the outer surface of the cartilaginous bone germs with the participation of the perichondrium. The mesenchymal germ which has the contours of the future bone, develops into "bone" of cartilaginous tissue, which is kind of a cartilaginous model of the bone. As a result of the activity of the perichondral osteoblasts covering the cartilage, bone tissue is laid down on its surface directly under the perichondrium. This tissue replaces the cartilaginous tissue gradually and forms a compact bony substance (Fig. 17).

3. With the conversion of the cartilaginous model to a bone model, the perichondrium becomes the periosteum, and further deposition of bone tissue is accomplished by the periosteum; this is *periosteal* ossification. The perichondral and periosteal types of ossification are therefore connected and one follows the other chronologically.

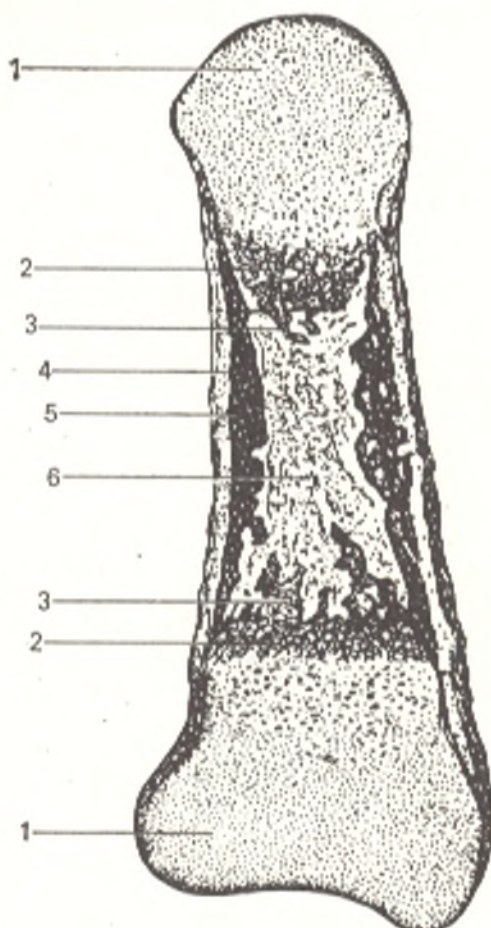


Fig. 17. Longitudinal section through a phalanx of an embryo.

- 1, embryonic cartilage (in the epiphyses);
- 2, calcification zone;
- 3, bone developed by enchondral ossification;
- 4, periosteum;
- 5, bone developed by perichondral ossification;
- 6, bone marrow

4. *Enchondral* ossification (Gk *en* in, into, *chondros* cartilage) occurs in the cartilaginous germs with the participation of the perichondrium, which gives off processes containing vessels into the cartilage. In penetrating deep into the cartilage together with the vessels, the bone-forming tissue destroys the cartilage which had undergone calcification (the deposition of lime into the cartilage and degeneration of its cells) and forms an island of bone tissue (the nucleus, or point of ossification) in the centre of the cartilaginous bone model. The spread of enchondral ossification from the centre to the periphery leads to the formation of the spongy bone substance. Thus, the cartilage does not transform directly into bone, but is destroyed and then replaced by new bone tissue.

This classification of the types of osteogenesis is usually given in all textbooks of anatomy and histology. Another classification exists, however, which was suggested by the Hungarian morphologist Crompecher in 1964. It distinguishes three types of bone formation.

1. The formation of bone from a foundation of cartilaginous tissue, *chondral osteogenesis*.
2. The formation of bone from a foundation of mature connective tissue, *desmal osteogenesis*.

In these cases the bone is prepared, as it were, by the cartilaginous or connective tissue which it replaces. Such types of ossification are therefore called *secondary ossification*. Crompecher considers the term "perichondral" ossification incorrect and obsolete since it indicates bone formation around a cartilaginous bone model without disclosing its character.

3. The formation of bone from a foundation of non-differentiated mesenchyme surrounding the vascular network, *angiogenic* (Gk *angeion* vessel) *osteogenesis*. In this type of ossification, the newly formed bone is not prepared by any mature supporting tissue, either cartilaginous or connective, and the bone is therefore formed directly from immature mesenchyme without preliminary preparation. This type of bone formation is consequently referred to as *primary ossification*.

These three types of ossification are determined functionally. Crompecher's experiments showed them to be dependent on mechanical factors.

*Secondary chondral osteogenesis* is encountered in those parts of the skeleton which are primarily subjected to pressure and are covered with cartilage (e.g. the articulating ends of the tubular bones).

*Secondary desmal osteogenesis* occurs in places primarily subjected to stretching action and are covered with connective tissue (periosteum), e.g. the compact substance of the tubular bones.

*Primary angiogenic osteogenesis* takes place in those parts of the bones which experience neither compression nor stretching, e.g. the margins of the skull-cap bones in the region of the sutures.

Parts of one and the same bone may undergo different types of ossification depending on their functions. The cranial and caudal surfaces of the vertebral body, for instance, are subjected to compression; these surfaces are covered by the intervertebral cartilage, and ossification here occurs by secondary chondral osteogenesis. The anterior and lateral surfaces of the vertebra are exposed to tension; they are covered by the anterior longitudinal ligament which plays the role of the periosteum and ossification here takes place by secondary desmal osteogenesis. Finally, the posterior surface of the vertebral body adjoining the spinal cord experiences neither compression nor stretching and ossifies by primary angiogenic osteogenesis.

The character and order of ossification are determined functionally also by the organism's adaptation to the environment. In aqueous vertebrates (e.g. teleost fish), for instance, ossification by perichondral osteogenesis occurs only in the middle part of the bone which, like any lever, is subjected to a large load (primary ossification nuclei). The same occurs in amphibians. In these organisms, however, a larger area of the middle part of the bone ossifies than does in fish. With the final transition to life on dry land, higher functional demands are placed on the skeleton because body movement is more difficult on land than in water and greater load is exerted on the bones. For this reason, secondary ossification nuclei appear in the land vertebrates; in reptiles and birds the peripheral parts of bones undergo ossification also from these secondary nuclei by enchondral osteogenesis. In mammals the articulating ends of bones even have independent nuclei of ossification. This order is also maintained in the ontogenesis of man, in whom ossification is also functionally determined, and begins first in the central part of the bones, which are subjected to the heaviest load.

Thus, in the second month of intrauterine life, the *primary points* (*centres*) appear first, which give rise to the main parts of bones experiencing the greatest load, i.e. the *shafts*, or *diaphyses* of tubular bones (Gk *dia* between, *phyein* to grow; the part of the bone growing between the epiphyses) and the ends of the diaphyses, the *metaphyses* (Gk *meta* after, beyond). They ossify by perichondral and enchondral osteogenesis. After that, shortly before birth or in the first years after birth, the *secondary points* appear from which the articulating ends of the tubular bones, i.e. the *epiphyses* (Gk *epi* above, *phyein* to grow), develop by enchondral osteogenesis. The ossification nucleus

which appears in the centre of the cartilaginous epiphysis spreads out and becomes the bony epiphysis composed of spongy substance. Only a thin layer of the primary cartilaginous tissue remains on the surface of the epiphysis for life. This is the articular cartilage. The primary and secondary points together are referred to as the *principal point*. Finally, *accessory points* appear in children, adolescents, and even adults; these are small islands of enchondral ossification, from which parts of bone subjected to traction by attached muscles and ligaments, are ossified; these small projections of bone are called **apophyses** (Gk *apo* from, away). An example is the accessory points on the processes of the lumbar vertebrae, which undergo ossification only in adults.

The character of ossification linked with the structure of the bone is likewise functionally determined. For instance, bones and parts of bones composed for the most part of spongy bone substance (the vertebrae, the sternum, the carpal and tarsal bones, the epiphyses of tubular bones, etc.) undergo enchondral ossification, whereas bones and parts of bones formed of both spongy and compact substances (the bones of the girdles and base of the skull, the diaphyses of tubular bones, etc.) develop by enchondral and perichondral ossification.

Some bones of the human body are a fusion of bones that exist independently in animals. In reflection of this process of fusion, these bones develop from ossification foci corresponding in number and location to the fused bones. The human shoulder blade, for instance, develops from two bones which form the shoulder girdle in lower terrestrial vertebrates (the shoulder blade and coracoid). In accordance with this, foci of ossification occur in the coracoid process of the shoulder blade (the former coracoid bone) in addition to the principal nuclei of ossification present in the body of the shoulder blade. The temporal bone which forms from three bones is ossified from three groups of bone nuclei. The ossification of each bone reflects thus the functionally determined process of its phylogenesis.

**Growth of bone.** The long-term growth of the organism and the tremendous difference between the dimensions and shape of the embryonic and final bone are such that its reorganization during growth is inevitable; in the process of reorganization, the formation of new osteons is paralleled by the *resorption* of the old ones whose remnants can be seen among the newly forming Haversian systems (the "intermediate" or interstitial system of lamellae). Resorption is the result of the activity of specific cells, *osteoclasts* (Gk *osteon* bone, *klasis* breaking) in the bone. Owing to their work almost the entire diaphyseal epichondral bone undergoes resorption, and a cavity (the marrow cavity) forms in it. The layer of perichondral bone also undergoes resorption, but new layers are laid down from the periosteum in place of the disappearing bone tissue. As a result the young bone grows in thickness.

The layer of cartilage between the epiphysis and the metaphysis, known as the *meta-epiphyseal cartilage*, or growth lamellae, persists throughout the childhood and juvenile periods. The bone grows in length at the cost of this cartilage, owing to the multiplication of its cells which deposit the interstitial cartilaginous substance. Later the cells cease multiplying,

the meta-epiphyseal cartilage yields to the onset of the bone tissue, and the metaphysis fuses with the epiphysis; *synostosis* (union of the bones) occurs.

The ossification and growth of bone are consequently the result of the vital activity of osteoblasts and osteoclasts performing opposite functions of apposition and resorption, creation and destruction. The development of bone thus illustrates the dialectical law of the unity and conflict of opposites. "Living means dying"<sup>1</sup>.

The following parts are distinguished in every tubular bone according to the described development and function (see Fig. 13).

1. The body (shaft) or **diaphysis**, is a bone tube containing yellow bone marrow in adults and mainly is concerned with the function of support and protection. The wall of the tube consists of a hard compact substance, in which the bony lamellae fit tightly and form a compact mass. The compact substance of the diaphysis is separated into two layers, according to two types of ossification: (1) the outer, cortical (*L. cortex* bark) layer forms by perichondral ossification from the perichondrium or periosteum which supplies it with blood vessels; (2) the inner layer develops by enchondral ossification and receives its nutrients from the vessels of the marrow. The different origin and nutrition of both layers of the compact substance is responsible for their different participation in suppurative processes.

The ends of the diaphysis which adjoin the meta-epiphyseal cartilage are the **metaphyses**. They develop together with the diaphysis but are concerned with the growth of bones in length and consist of spongy substance. The compartments of the "bony sponge" are filled with red bone marrow.

2. The articulating ends of each tubular bone, located on the other side of the meta-epiphyseal cartilage, are the **epiphyses**. They are also composed of spongy substance containing red bone marrow but, in distinction from the metaphyses, they develop by enchondral ossification from an independent bone nucleus laid down in the centre of the epiphyseal cartilage. Their outer surface is the articulating surface which contributes to the formation of the joint.

3. Bony projections, or **apophyses**, are located close to the epiphysis and are the site of attachment of muscles and ligaments. The large apophyses undergo enchondral ossification from an ossification nuclei laid down separately in their cartilage; they are composed of spongy substance. Similar parts can be distinguished in bones not related to tubular bones but which develop from several ossification points.

## BONE CLASSIFICATION

The following parts are distinguished in the skeleton: the bones of the trunk (the vertebrae, ribs, and breast bone or sternum), the skull bones (the calvaria, or skull cap, and the facial skull); the bones of the limb girdles, namely, the shoulder girdle (the shoulder blade and collar bone, or clav-

<sup>1</sup> F. Engels. *Dialectics of Nature*. Foreign Languages Publishing House, Moscow, 1954, 388.

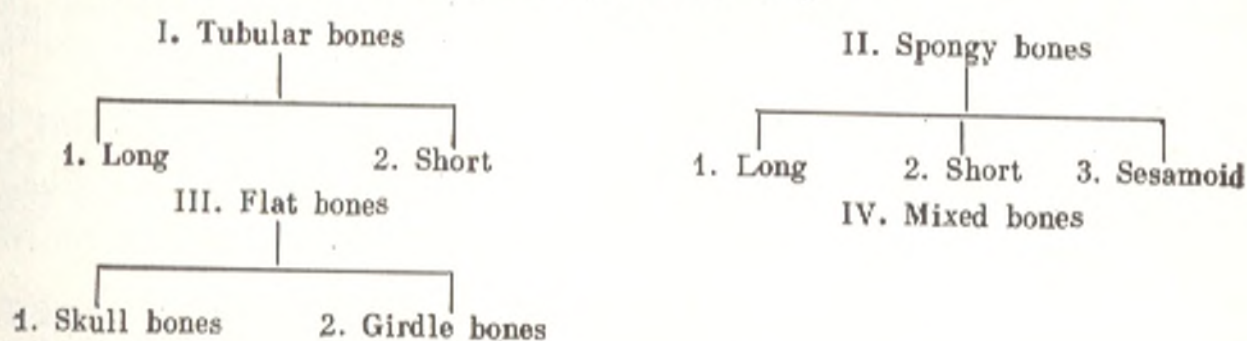


icle) and the pelvic girdle (the ilium, pubis, ischial bone), and the bones of the free limbs: upper (arm bone, or humerus, bones of the forearm, and bones of the hand) and lower (the thigh bone, or femur, bones of the leg, and bones of the foot).

The skeleton of an adult contains more than two hundred separate bones, of which 34 to 40 are located on the midline of the body and are not paired. The rest are paired bones.

Bones are classified according to appearance: long, short, flat, and mixed. This classification according to a single feature (external appearance), established as early as the age of Galen, is one-sided, however, and illustrates the formalism of the old descriptive anatomy. Bones entirely different in structure, function, and origin form a single group. The group of flat bones, for instance, includes both the parietal bone, a typical membrane bone, which undergoes intramembranous ossification, and the shoulder blade which is concerned with the functions of support and movement, ossified from cartilage, and formed of ordinary spongy substance. A pathological process in the phalanges also differs in its course from that in the carpal bones, although both types of bones are referred to as short bones; the same applies to the thigh bone and rib included in the group of long bones.

It is therefore more proper to classify bones according to the three principles on which any anatomical classification should be based, i.e. form (structure), function, and development. The following classification of bone can be suggested from this standpoint (M.G. Prives):



**I. Tubular bones.** These are composed of spongy and compact substance forming a tube with a marrow cavity; they perform all three functions of the skeleton (support, protection, and movement). *Long tubular bones* (arm bone, forearm bones, thigh bone, and leg bones) are supports and long levers of movement and they have enchondral ossification foci in both epiphyses (biepiphyseal bones) but not in the diaphysis. *Short tubular bones* (metacarpal, metatarsal, phalanges) are short levers of movement; an enchondral ossification focus is found only in one (true) epiphysis (monoepiphyseal bones).

**II. Spongy bones.** These bones consist mainly of spongy substance covered with a thin layer of compact substance. *Long* (ribs and sternum) and *short* (vertebrae, carpal, tarsal) *spongy bones* are distinguished. The group of spongy bones also includes *sesamoid bones*, i.e. bones which resemble sesame seeds in shape, hence their name (the knee cap, or patella, the pisiform bone,

the sesamoid bones of the fingers and toes); sesamoid bones act as accessory devices in the work of muscles and develop by enchondral ossification in the thickness of the tendons, which they strengthen. The sesamoid bones are located close to the joints, take part in their formation, and promote movements in them but are not joined directly to the bones of the skeleton.

III. Flat bones: (a) the *flat bones of the skull* (frontal and parietal) perform a function that is mainly protective (membrane bones). Their structure is diploe, and they ossify from connective tissue;

(b) the *flat bones of the girdles* (shoulder blades, pelvic bones) perform supportive and protective functions. Their structure is primarily spongy substance. Ossification occurs in cartilaginous tissue.

IV. Mixed bones (bones of the base of the skull) are formed by the fusion of several parts, which differ in function, structure, and development.

### X-RAY EXAMINATION OF BONE STRUCTURE AND DEVELOPMENT

Simple inspection of macerated bone gives an idea of the external appearance of the bone, but its internal structure can be studied only by dissection. X-rays of the live human subject, however, demonstrate simultaneously the external and internal bone structure without harm to normal anatomical functions.

The compact and spongy substances are easily seen on radiographs. The compact substance produces a shadow of increased density corresponding to the plane of the cortical layer, whereas the shadow in the region of the spongy substance has the character of meshwork (see Fig. 20).

The compact substance of the epiphyses of tubular bones and that of bones composed mostly of spongy substance (the carpal and tarsal bones, the vertebrae) is seen as a thin layer edging the spongy substance. This thin cortical layer is thicker on the articulating cavity than on the head of the bone.

The compact substance in the diaphyses of tubular bones varies in thickness: it is thicker in the middle part but becomes thinner in the direction of the ends. The marrow cavity is discernible between the two shadows of the cortical layer as an area of diminished density against the background of the whole shadow of the bone. A cavity that cannot be traced for its entire length indicates the presence of a pathological process.

The X-ray outlines of the diaphyseal compact substance are clearly defined and regular. At sites of attachment of ligaments and muscles the outlines of the bone are irregular. Thin bands of diminished density, corresponding to the vascular canals, are demonstrated against the shadow of the diaphyseal cortical layer. They usually stretch obliquely, closer to and in the direction of the elbow joint in the long tubular bones of the upper limbs and further from and in the direction of the knee joint in the long tubular bones of the lower limbs. In the short tubular bones of the hand and foot, they stretch closer to and in the direction of the end which has no true epiphysis.

The spongy substance is demonstrated on the radiograph as a looped meshwork of bone trabeculae with spaces of diminished density between them. The character of the meshwork is determined by the arrangement of the bony lamellae in the given area according to the lines of compression and tension.

**Bone development.** It is possible to study the bone system by X-ray from the second month of intrauterine life, when ossification centres originate in the cartilage or connective tissue.

Ossification points are easily identified on radiographs; set apart by the cartilaginous tissue, they are seen as separate bone fragments. They may be the cause of an erroneous diagnosis of a fracture, infraction or necrosis of bone. In view of this, knowledge of the location of bone nuclei and the terms and sequence of their appearance is very important in medical practice. That is why our account of ossification in the corresponding sections is based on the findings of X-ray anatomy (examination of a living human) and not on those of anatomical examination of cadavers. If accessory nuclei fail to fuse with the main part of the bone, they may persist throughout life as independent, inconstant, or accessory bones. Their discovery on radiographs may lead to diagnostic errors.

All the main ossification nuclei appear in the skeletal bones before puberty (Fig. 18,*a*). Fusion of the epiphyses with the metaphyses, i.e. the conversion of synchondrosis joining the bone epiphysis with the bone metaphysis to synostosis, begins with the onset of the pubertal period. This is manifested on the X-ray as a gradual disappearance of the area of diminished density in the meta-epiphyseal zone corresponding to the meta-epiphyseal cartilage separating the epiphysis from the metaphysis. No traces of the former synchondrosis can be discerned after total synostosis forms (Fig. 18,*b*), and the process then ceases. It takes many years to produce synostosis and five stages can be distinguished in the process by X-ray. The stages are graded according to a six-point system:

Stage zero—the meta-epiphyseal zone is clearly seen on all its dimensions because the process of synostosis has not begun.

Stage one—the beginning of synostosis formation; half of the meta-epiphyseal zone is ossified.

Stage two—synostosis is produced in one-third to two-thirds of this zone.

Stage three—synostosis has occurred in almost the whole zone, but areas of cartilaginous tissue that has not undergone ossification persist on its edges.

Stage four—synostosis has formed on the entire meta-epiphyseal zone but there is a noticeable white band stretching along it; this band is produced by sclerosed bone and vertical arrangement of the bone trabeculae which have still not taken their position in accordance with the structure of the spongy bone substance. As a result the bone substance of the meta-epiphyseal zone differs in structure from the surrounding spongy substance and has the appearance of a thin transverse band.

Stage five—the band (zone of sclerosis) has disappeared and synostosis has been established.

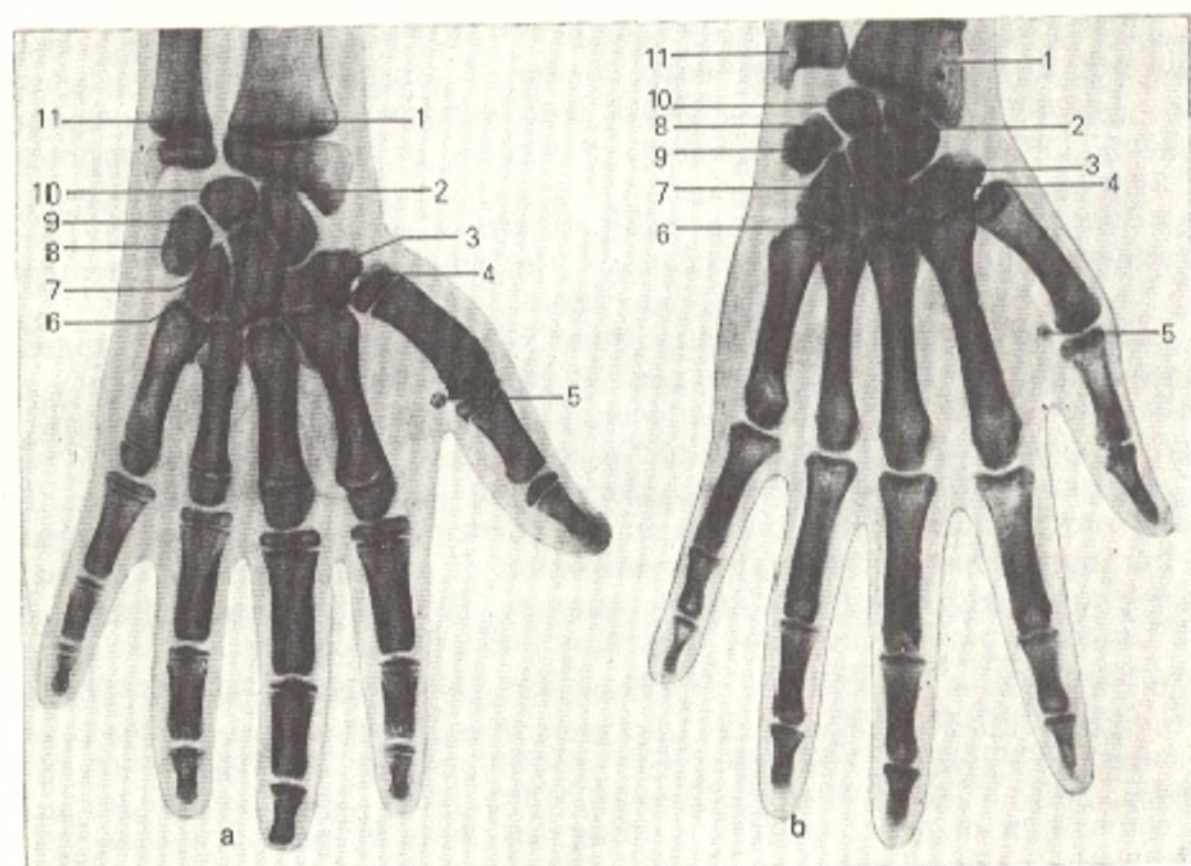


Fig. 18. Radiograph of the hand.

- a, before puberty (the meta-epiphyseal cartilage of the first metacarpal bone can be seen);  
 b, after the onset of puberty (synostosis has formed at the site of the meta-epiphyseal cartilage of the first metacarpal bone).  
 1, diaphysis of radius;  
 2, scaphoid bone;

- 3, trapezoid bone;  
 4, trapezium bone;  
 5, sesamoid bone of thumb;  
 6, hamate bone;  
 7, capitate bone;  
 8, triquetral bone;  
 9, pisiform bone;  
 10, lunate bone;  
 11, diaphysis of ulna

**Ageing of the bone system.** The bone system undergoes great changes at old age. The number of bone lamellae reduces, and rarefaction of bone (*osteoporosis*) occurs. In addition, there is excessive formation of bone in the form of bone outgrowths (*osteophytes*) and calcification of the articular cartilage, ligaments, and tendons at the site of attachment to the bone.

In conformity with this, the X-ray picture of ageing of the osteo-articular system is made up of the following changes which must not be interpreted as signs of a pathological condition (degeneration).

I. Changes caused by atrophy of the bone substance: (1) *osteoporosis* (the density of the bone shadow on the radiograph diminishes); (2) deformity of the articulating head of the bone (distortion of the rounded shape, "ground off" margins, the appearance of "angles").

II. Changes occurring because of excessive deposition of calcium in connective-tissue and cartilaginous structures adjoining the bone: (1) constriction of the "X-ray" joint space due to calcification of the articular carti-

lage; (2) sharply outlined relief of the diaphysis due to calcification at the sites of attachment of the tendons and their fibrous sheaths; (3) bone projections, osteophytes, formed as the result of calcification of ligaments at the site of attachment to the bone.

The changes described are demonstrated particularly clearly in the spine and hand. The following three X-ray signs of ageing are encountered in the other parts of the skeleton: osteoporosis, increased density of the relief of the bone, and constriction of the joint space. In some persons these signs of ageing appear early (at 30 to 40 years of age); in others they occur late (at the age of 60 to 70) or do not develop at all.

A number of normal morphological changes are encountered in this case: (1) the appearance of ossification points, main and accessory; (2) the process of their fusion with each other; (3) age involution of the bone. These changes are normal manifestations of the ageing process of the bone system. The concept of "norm" cannot, therefore, be restricted only to middle-aged adults of a certain "standard" type. The norm must take into account other age groups as well.

## THE DEPENDENCE OF BONE DEVELOPMENT ON INTERNAL AND EXTERNAL FACTORS

The skeleton, just as any other system of organs, is a part of the organism, and the various processes taking place in the organism have an effect on the skeleton. Many factors, consequently, influence the development of the bone system.

**The effect of internal factors.** X-ray examination discloses some morphological bone changes which depend on the activity of other organs. Radiographs demonstrate particularly clearly the connection between the bone system and the endocrine glands (endocrine apparatus). The onset of sex glands activity leads to the beginning of puberty. Prior to this, in the prepubertal period, there is an increase in the activity of other endocrine glands, e.g. the hypophysis cerebri with whose function the appearance of the ossification nuclei is associated. All the main ossification points appear by the onset of the prepubertal period but there is a sex difference in the time of their appearance, one to four years earlier in girls than in boys. The onset of the prepubertal period, linked with the activity of the hypophysis, coincides with the appearance of the ossification nucleus in the pisiform bone, which belongs to the category of sesamoid bones.

Other sesamoid bones, namely those located at the metacarpophalangeal articulation of the thumb, undergo ossification just before the onset of the pubertal period. The beginning of puberty, when, to put it in the expression voiced by the famous investigator of the endocrine apparatus Biedl, the sex glands start playing the main melody in the endocrine concerto, is manifested in the bone system by the beginning of synostosis development between the epiphyses and metaphyses; the earliest of these synostoses is encountered in the first metacarpal bone. That is why synostosis of the first metacarpal bone, in correlation with other signs of sexual development (hair growth, establishment of menstruation, etc.), is considered an indication of the onset of puberty. According to a study conducted in Leningrad, synostosis of the first metacarpal bone occurs at the age of 15-19 years in boys and at 13-18 years of age in girls.

Full maturity of the reproductive organs is also reflected to a certain degree in the skeleton: fusion of the epiphyses with the metaphyses is completed in all the tubular bones at this time (between the ages of 17 and 21 in females and between 19 and 23 years of age in males). Since growth of bone in length ends with the complete formation of synostosis, males, who reach full puberty later than females, are understandably taller than females in general.

Since the bone system is connected with the endocrine system, it is possible, by correlating the data on the age peculiarities of the skeleton with the data on maturation of the reproductive organs and general development of the organism, to speak of the "bone age". Thus, the age of an individual and the progress of the ossification process within the individual may be determined from X-rays of some parts of the skeleton, particularly the hand, which is of practical importance in diagnostics, forensic medicine, and so on. The "passport" age indicates the number of years a person has lived (i.e. is a quantitative index). The "bone" age, in distinction, testifies, to a certain degree, to the quality of life during these years.

X-ray examination also reveals the dependence of the bone structure on the condition of the nervous system which regulates all processes in the organism and is responsible in particular for the trophic function of the bone. With intensified trophic function of the nervous system, more bone tissue is deposited in the bone, which becomes harder and more compact (osteosclerosis). With diminished trophics, in contrast, rarefaction of the bone, osteoporosis, occurs. The nervous system also produces an effect on bone through the muscles, whose contraction it regulates (this is discussed below). Finally, different parts of the central and peripheral nervous system determine the shape of the bones surrounding and adjoining them. For instance, all the vertebrae form a vertebral canal around the spinal cord. The skull bones form a bone case around the brain and acquire the shape of the latter. The bone tissue in general develops around elements of the peripheral nervous system, as a result of which bone canals, fissures, and fossae form to convey nerves and other nerve structures (ganglia).

Bone development is also very closely dependent on the blood vascular system. The entire process of ossification, from the appearance of the first bone nucleus to the final formation of synostosis, occurs with the direct participation of the vessels, which permeate the cartilage and promote its destruction and replacement by bone tissue. The bony (Haversian) lamellae are laid down in a certain order around the blood vessels forming the Haversian systems with a central canal for the corresponding vessel. Consequently the developing bone is built around vessels. This also explains the formation of vascular canals and grooves in bones in places where arteries and veins pass through them or adjoin them.

Ossification and growth of bone after birth is also closely dependent on the blood supply. Research conducted by one of the authors of this book (Prives) showed that it is possible to isolate a number of stages in the ageing process of bone that are linked with corresponding changes in the blood channel (Fig. 19).

1. *Neonatal stage*, typical of the foetus (the last months of intrauterine development) and the newborn; the vascular bed of the bone is divided into a number of vascular areas (epiphysis, diaphysis, metaphysis, apophysis) which do not communicate with each other (closed, isolated character) and in which the vessels do not join one another, i.e. do not anastomose (end character of vessels, "terminal").

2. *Infantile stage*, characteristic of children in whom the development of synostoses has not begun; the vascular areas are still separated, but the vessel within each area form anastomoses with each other and lose their end character ("closed" character in the absence of a "terminal").

3. *Juvenile stage*, typical of youth. This stage begins with the establishment of communications between the vessels of the epiphysis and those of the metaphysis through the meta-epiphyseal cartilage as a result of which

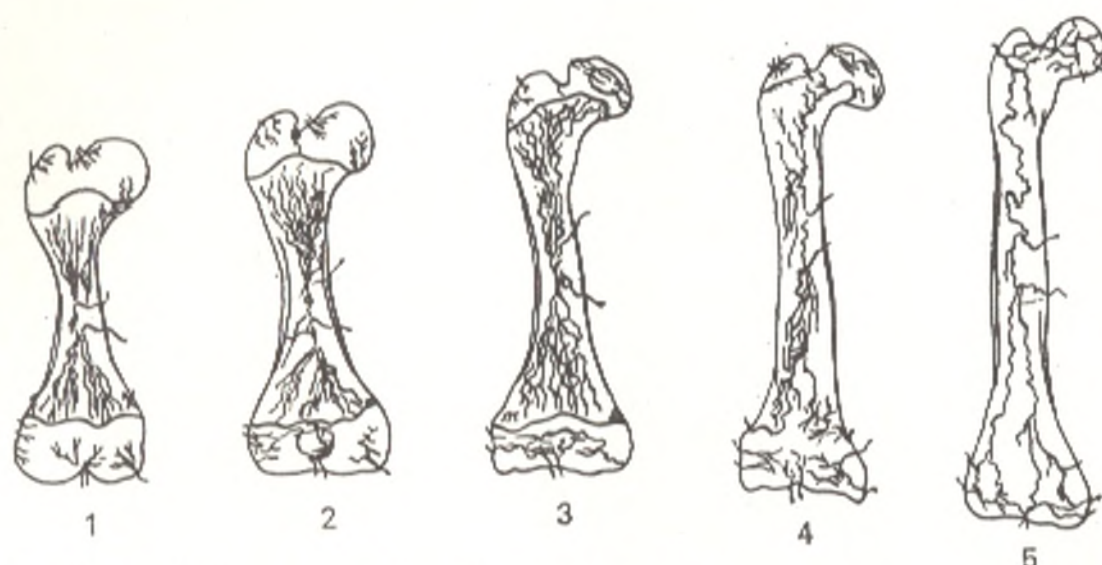


Fig. 19. Schematical representation of age changes in bone linked with changes in its arterial system (after Prives).

1, neonatal stage;  
2, infantile stage;  
3, juvenile stage;

4, mature stage;  
5, senile stage

the epiphyseal, metaphyseal, and diaphyseal vessels begin to lose their closed character.

4. *Mature stage*, inherent in adults; synostoses form fully and all the intraosteal vessels form a single system: they are neither "closed" nor "terminal".

5. *Senile stage*, characteristic of old people; the vessels are thinner, and all the vascular network is poorer.

The shape and position of the bones are also influenced by the viscera for which they form receptacles, seats, fossae, and so forth. The formation of the skeleton and organs occurs at the beginning of embryonal life; during their development they have a mutual effect, as a result of which the organs and their bone receptacles are brought into conformity with each other in their full development, e.g. the thoracic cage with the lungs, the pelvis with its organs, the skull with the brain, etc. The development of the whole skeleton should be considered from the standpoint of this interrelationship.

**The effect of external (social) factors on the structure and development of the skeleton.** *The unity of form and function in the structure of the bones.* When man influences nature through his labour, he sets in motion his natural tools, i.e. hands, feet, fingers, etc. The labour processes have an essential effect on the human body as a whole, on the locomotor system of man, including the bone system.

The work of the muscles is reflected on the skeleton most markedly. Experimental studies conducted by Lesgaft showed that the harder the muscles work, the better the bone develops and vice versa. Dolgo-Saburov disclosed that in the process of muscular activity projections (tuberosities, processes, areas of roughness) form at the site of attachment of the tendons and even on concaved surfaces (fossae) where the muscle fibres are attached. The

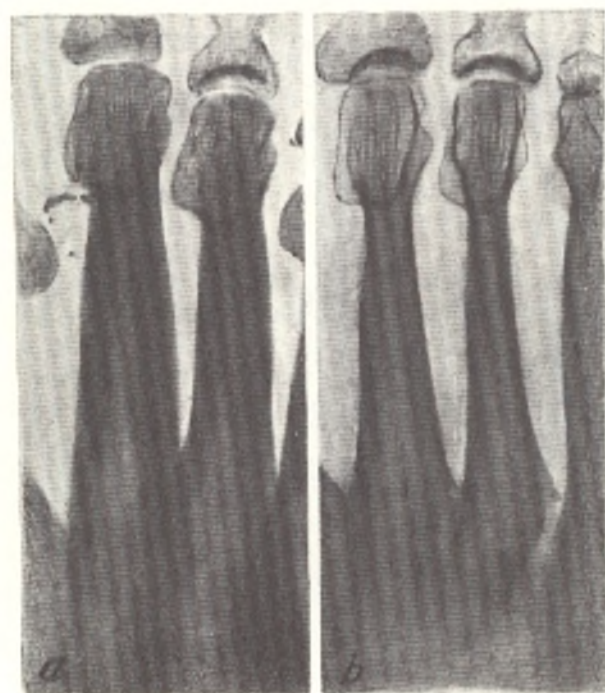


Fig. 20. Radiographs of the metatarsal bones of a female ballet-dancer (a) and a person who works sitting (b)

stronger the development of muscles, the more conspicuous are the sites of their attachment (origin and insertion) on the bones. The bone relief resulting from the attachment of muscles is therefore more pronounced in adults than in children and more pronounced in males than in females.

Long-term and regular contraction of muscles, as is the case in physical exercise and occupational activity, gradually causes changes in the metabolism in the bones through reflex mechanisms of the nervous system. As a result, the bone substance is enlarged; this is known as *work hypertrophy* and was first identified by Rokhlin during X-ray examination (Fig. 20).

#### THE SKELETAL STRUCTURE OF VARIOUS OCCUPATIONAL GROUPS (X-RAY PICTURE)

Different occupations call for different physical effort, and consequently, the bones participate to varying degrees in any given activity.<sup>1</sup> Increased physical exertion on the locomotor system causes work hypertrophy of the bones, as a result of which their shape, width, and length as well as the thickness of the compact substance and the dimensions of the marrow cavity change. The structure of the spongy substance also alters.

*Bone width.* For example, the bones of dock workers widen in proportion to the number of years they have worked, and their bones grow much wider than the bones of office workers. The width of the metatarsal bones of truck drivers, football players, ballet-dancers, and workers whose occupation involves a heavy load on the feet is greater than that of persons not engaged in physical work or sports.

*The thickness of the compact substance.* The compact substance thickens mainly in the second and third metatarsal bones of ballerinas and in the first metatarsal bone of

<sup>1</sup> M. G. Prives. The Skeletal Structure of Various Occupational Groups (in Russian). Paper read to the Seventh International Congress of Anthropologists (1964). The paper was based on the works of M. G. Prives, K. I. Mashkara, M. E. Kalveit, G. D. Rokhlin, N. V. Krylova, D. F. Shpakovsky, and others.



truck drivers and football players (only on the tibial side in truck drivers and both on the tibial and fibular sides in football players).

*The marrow cavity.* In conformity with the thickening of the compact substance in work hypertrophy, the marrow cavity grows smaller. On radiographs it is seen as a narrow space between two shadows of thickened compact substance.

*The spongy substance.* The structure of the spongy substance also undergoes changes. Among the three types of its structure (microporous, moderately porous, and macroporous), the macroporous structure corresponds to increased physical effort. Such structure of the spongy substance is found most frequently in ballet-dancers, football players, truck drivers, and representatives of other occupations whose foot skeleton experiences a similar excessive load, whereas a microporous structure is usually encountered in persons engaged in sedentary work.

*Bone shape. The vertebral column.* Vertebral bodies may assume one of two main shapes: quadrangular, in persons whose occupation does not involve a heavy load on the spine (swimmers) or wedge-shaped, in those engaged in heavy physical work. The wedge-like shape has in turn two varieties: one, in which the wedge tapers to the front, common in weight-lifters, for instance, and another, in which the wedge tapers to the back, e.g. in circus actors whose spines bend sharply backward when they stand on their hands.

*The upper limb.* A thin humerus with a well pronounced surgical neck is usually encountered in persons not trained in sports; in swimmers, the surgical neck is poorly pronounced because the deltoid muscle is hypertrophied, and the diaphysis at the site of its insertion is considerably widened. A similar picture is encountered in the radius of canoe rowers in whom hypertrophy of the biceps causes drastic thickness of the tuberosity of the radius as the neck of the bone is smoothed out. The neck of the radius and the curvature of the whole diaphysis in weight-lifters are smoothed out because the bone is thickened. The bones of both upper limbs develop intensively when work requires increased physical effort of both limbs. The width of the diaphyses and epiphyses of the tubular bones of the hand and the thickness of the compact substance, for instance, are greater in metal workers than in office workers. Metal workers also have an elongated index finger, which is associated with the increased physical exertion of the index finger typical of this occupation. These changes are more pronounced in truck drivers and chauffeurs than in metal workers, and there is relative elongation of their third, fourth, and fifth metacarpals due to the increased effort of these bones in holding tight to the steering-wheel. In dock workers, the diaphyses and epiphyses of the tubular bones of the hands are still wider; the compact substance is very thick; the spongy substance is of macroporous structure; and the first metacarpal is elongated.

In persons who use their hands unequally, changes are more marked in the bones of the hand that works more. Thus, in workers who smooth out insulating bands with the left hand, the bones of this hand, particularly the second and third metacarpals, are more developed. The bones of the right hand are more developed in pianists, and the bones of the left hand are more developed in violinists.

*The lower limb.* The distal end of the femoral diaphysis is usually thickened sharply in a discus thrower, and its shape is distorted. The tibia of a runner is drastically thickened in the area of the tubercle, while the fibula is thickened in the area of the head.

The short tubular bones are subjected to considerable variations. For instance, two forms of the metatarsal diaphysis are encountered: (1) a diaphysis with a constriction ("waist") in the middle; the metaphyses are therefore wider than the mid-diaphysis (e.g. in persons engaged in sedentary work); (2) a diaphysis with no "waist", instead of which there is a distension lending the bone a spindle-like shape (e.g. in ballet-dancers). These two forms, which result from certain types of work, are extreme variations within the spectrum of individual variability.

In workers whose legs bear a heavy load on the job, changes are found in the bones of the lower limbs. In truck drivers, for instance, the cortical layer of the metacarpals is excessively developed on both sides, and the spongy substance is more than 50 per cent macroporous in character. Textile workers, whose left lower limb bears a load, have a wide first metatarsal and a moderately porous structure of the spongy substance of the left foot. The first and second metatarsals are particularly enlarged in male ballet-dancers; the cortical substance prevails on the fibular aspect, and the spongy

substance of the epiphyses and tarsal bones is macroporous in structure. In ballerinas the diaphyses of the second and third metacarpals are highly developed because of the specificity of classical dancing (standing on the toes). Their cortical layer thickens drastically as a result of which the shape of the bones changes (spindle-shaped, with no "waist") and differs, for instance, from the shape of the metatarsals in telephone operators whose work is sedentary (their second and third metatarsals have a "waist" in the middle of the diaphysis).

The above-noted changes are encountered in all the bones of the skeleton but are more pronounced in those which experience the greatest exertion in the given type of work. Individual variability of the bone system is produced as a direct result of different types of work and occupation.

*Change of occupation.* Progressive work atrophy of the metacarpals was demonstrated over a period of three years in a woman working as an electrician. The atrophy was induced by exertion of the bones which was characteristic of this occupation. Four years after the woman changed her occupation and became a storekeeper, radiographs of her hand skeleton showed a decrease in the width of the diaphysis and the thickness of the compact substance of the metacarpal bones and a corresponding increase of the marrow cavity, i.e. as if "regression" of work hypertrophy had occurred. Similar changes were found in the tubular hand bones of former dock workers who were no longer engaged in heavy physical work.

Thus, one can determine to some extent the character of a person's occupation from the character of his bones. Individual variability was formerly attributed mostly to endogenous factors of phylogenesis and ontogenesis, but now it is clear that exogenous factors, i.e. living conditions and occupation, must also be taken into account. This information on the individual variability of the bones as the result of occupational hazards is of practical importance for those concerned with improving working conditions.

Similar changes in the structure of bones occur as the result of physical exercise of an athletic nature; that is why the skeleton is much better developed in individuals who exercise regularly. The bone system is differentiated better in children of a sturdy body build than in those with a weak build. Rational physical exercise and proper living conditions can improve the development of all parts of a child's skeleton, including the thoracic cage, which has a favourable effect on the development of the vital organs contained in it (heart, lungs). Information on the development of the skeleton is, therefore, important for the creation of proper working conditions in the schools.

The changes occurring in bones under the effect of physical effort are the result of functional conditions. The following facts are evidence of this. Bones undergo similar thickening on both sides if the symmetric limbs regularly bear an equal load. If the left upper or lower limb works more strenuously, then the bones of this limb become thicker. Therefore, not only congenital factors (right-handedness or left-handedness) but also the character of physical exertion experienced after birth and throughout life are decisive in the degree of development of the bone substance. As a result, rational physical exercise can have a direct effect on bone growth and can facilitate proper development of the human body. This is the particular effectiveness of anatomy. Remedial physical exercises promoting the healing of bone injuries are also founded on this principle.

The formation of a pathological joint after a fracture is a striking illustration of the role of function in bone formation. In non-union of bone fragments their ends take the shape of smooth articular surfaces as the result of their rubbing against each other for a long time under the effect of the contraction of muscles, and a false joint (pseudoarthrosis) forms at the site of the former fracture. Here is another example. A tibial segment transplanted in place of a resected humeral or femoral segment acquires gradually the structure of the recipient bone. The architecture of the transplant undergoes reorganization according to the new functional demands made of it. A costoclavicular (between a rib and the clavicle) articulation may occur in the form of an amphoarthrosis promoting the mobility of the shoulder girdle in persons engaged in physical work. These facts testify to the dependence of changes in bone shape and structure on changes in functional conditions, illustrate the dialectical law of the unity of form and function, which are mutually conditioned.

The bone is, therefore, one of the extremely plastic organs of our body which undergoes significant changes under the influence of internal and external factors. Many of these

changes are demonstrated by X-rays, and the X-ray proves, consequently, to be a mirror reflecting to a certain degree the life of the organism.

To explain changes to the bone from a normal to a pathological state as the result of overexertion or overuse (overtraining, wear and tear to the bones), a thorough study of normal bone structure must, therefore, take into account the conditions of work and everyday life. Such changes may be diagnosed if we know the normal structure of the bone, the occupation of the individual, and the length of time an athlete has been competing in sports. This is important in the establishment of proper working conditions and sports programmes. An anatomist using only the macerated bones of an unknown person has no possibility for such thorough study. In contrast, extremely detailed study is possible when the anatomist uses X-rays to examine the skeleton of a living person, authentic information on whose working and living conditions can be easily obtained.

## THE SKELETAL STRUCTURE OF ATHLETES ENGAGED IN VARIOUS SPORTS

Physical exertion experienced in various sports induces the same changes in bone structure as those caused by physical effort on the job.

*The vertebral column.* The front and back surfaces of the bodies of thoracic and lumbar vertebrae are equal in height in athletes whose sport does not require a heavy load on the spine. In athletes engaged in heavy athletics, the anterior part of the vertebrae is subjected to considerable weight load, and the anterior height of the vertebral body becomes lower than the posterior height and, as a result, the vertebra becomes wedge-shaped ("a wedge tapering to the front").

*The bones of the upper limb.* The shoulder blade of boxers undergo considerable exertion, and its acromion has a macroporous structure with thick bony trabeculae. In persons whose shoulder blade is used less, the acromion is microporous with thin trabeculae.

In athletes whose sport involves heavy use of the long tubular bones, these undergo increased work hypertrophy. Because of the constant use of the deltoid muscle in swimmers, the site of its attachment, *tuberositas deltoidea*, is drastically hypertrophied and has the appearance of a protruding tuber.

In athletes whose upper limbs are burdened unequally, work hypertrophy develops only in the bones of the limb that works hardest, e.g. in the bones of the right limb in right-handed fencers and in those of the left limb in left-handed athletes.

*The bones of the lower limb.* Similar phenomena are encountered in the bones of the lower limbs. Marked work hypertrophy of all the long tubular bones is found in football players. If one leg bears a heavier load, then work hypertrophy is most marked in the bones of this limb, for instance, in the push-off leg in high-jumping.

Bone changes caused by different sports comprise the subject of sports anatomy which Prives and colleagues were among the first to elaborate. They identified the following general patterns of bone changes induced by sports.

1. Physical exertion in sports causes work hypertrophy, which is manifested by some increase in the width of the bones, thickening of the compact substance, reorganization of the spongy substance with transformation

of its microporous structure to macroporous, enlargement of the processes, tubers, and tuberosities at the site of muscle attachment, delayed formation of synostosis between the epiphyses and metaphyses, and prolongation of the period of bone growth.

2. The "heavy" sports (football, weightlifting, etc.) induce greater work hypertrophy than track and field sports.

3. Work hypertrophy develops to a greater extent in the parts of bones and bones subjected to greater exertion in accordance with the given sport. Thus, if an athlete's sport is known, changes in the bones of the athlete can be predicted.

Sports anatomy helps, consequently, when training the athletes, and is important in sports hygiene and in X-ray diagnosis of pathological changes induced by overexertion in sports.

### ANATOMY AS THE STUDY OF DYNAMIC CHANGES IN BONE SYSTEM

As we pointed out above, the most important feature of the Soviet science of anatomy is its **dynamic aspect**, i.e. it does not passively contemplate and describe the body's structure, but endeavors to discover the regularities in the organism's structure and development and to control and direct the favourable and harmonious development of the human organism.

The social factors responsible for increased individual variability of human beings have a direct effect on their physical structures. According to the theory of dialectical materialism, labour is the most important social factor affecting the structure and development of the human organism. When a man uses a tool, it is as if he has acquired a new organ that alters his anatomical structure. Anatomy is therefore always faced with the task of studying exactly how man's tools affect his normal structure by complementing the natural tools of his body, i.e. the organs.

Modern anatomy thus studies the anatomy of individuals, considering their living and working conditions and looking for the effect different types of work, i.e. occupations, have on the structure of the human body. *Human anatomy under different occupational conditions* (both work and sports) is a new branch of modern anatomy and is being developed at the Department of Normal Anatomy of the First Leningrad Medical Institute. This work was started on the initiative of M. G. Prives and has been continued for more than 25 years by his colleagues. As the result of this trend, anatomy has become a dynamic science. This is illustrated in the sections "The Skeletal Structure of Various Occupational Groups" and "The Skeletal Structure of Athletes Engaged in Various Sports". Here are a few more illustrations.

X-rays of the foot bones of a ballerina taken over a period of twenty years reveal the following. Work hypertrophy of the metatarsals developed when she began dancing, but atrophy appeared when she ceased dancing and became a dancing teacher; the bones acquired the same structure they had before she started dancing. Similar changes were found in the metacarpals

of blacksmiths when some of their manual operations were automated. Consequently, changes in occupation or in the nature of a particular job, changes in the degree of physical exertion connected with various types of work and sports, and changes in different sports training programmes can have a direct effect on bone shape and structure.

For all its hardness and "petrification" bone is a living organ, which continuously reorganizes and changes depending on the degree of physical exertion during movement, work, and other activities.

The study of anatomy of people engaged in different occupations reveals definite patterns of the development of changes in the bones. Thus anatomical science may help to control and direct bone development. The above illustrations of changes in bone structure directly induced by physical loads of varying weight demonstrate that anatomy can be useful.

Thus, research involving people from different occupations and athletes engaged in different sports as well as studies of the X-rays of the same individual over a period of ten or twenty years have enabled us to identify the following definite patterns.

1. The increased physical exertion directly associated with a particular occupation or sport causes work hypertrophy of the bones. Conversely, the compact substance of bones that are little used atrophies within normal levels.

2. The hypertrophy develops specifically in those bones and parts of bones that receive the heaviest load.

3. By choosing the physical load necessary for a given condition, one can influence bone structure in a desired direction.

This is the principal feature of modern anatomy, namely its applicability, which makes deliberate regulation of the structure of bones possible.

4. Such regulation is of practical importance in planning working conditions and sports programmes, in preventing harmful effects from industrial occupational hazards, in the proper training of athletes, and in the proper physical training of schoolchildren.

Thus, Goethe's definition of morphology as a science of structure, formation, and reorganization is becoming a reality. Description of the body structure comprises the descriptive feature of anatomy. The formation of structures makes up its evolutionary and functional features. And reorganization indicates the applicability of anatomy.

#### THE RELATIONSHIP OF SOCIAL AND BIOLOGICAL FACTORS IN BONE DEVELOPMENT

Bone is not, as was once believed, an inanimate object that, once formed, undergoes no further changes. Modern anatomy has risen above this metaphysical view and considers the living activities of bone, even in adults, to be an unceasing exchange of substances with other tissues in the body. The body is a dialectical entity, in which opposite processes, bone formation and bone destruction or resorption, are in conflict. As a result of this conflict, the structure and chemical composition of bone is continuously replaced, so that, for instance, the femur is completely renewed within fifty days. In the course

of this the bone submits to a number of biological laws: adaptation to new living conditions, unity of the organism and the environment, unity of form and function, variability as the result of exercise or lack of exercise, mechanical compression of one part by another, etc. (Darwin, Lamarck, Rous). The morphological manifestation of these laws in the skeleton is the reorganization of bone structure (bone reorganization) according to changing functional requirements, as discussed above. Such, briefly, is the "biological aspect" of the relationship of social and biological factors in bone development.

The following must be borne in mind when considering the "social aspect". Various social factors (occupation, life-style, nutrition, etc.) are related to different levels of physical exertion, which determine the degree to which a particular bone participates in a given task. The work of some professionals involves maintaining a certain body posture for an extended period of time (e.g. bending over a machine or a writing table) or continuously changing from one position to another (e.g. a carpenter bending the trunk forward and then straightening it). The character and volume of the work load determine, therefore, the participation of the given spinal segment and each bone separately in the work and determine the different character and degree of reorganization of the bone structure. With a change in occupation, bone reorganization occurs in the direction of intensified or weakened work hypertrophy, depending on the character of the new work load.

Bone growth in length increases with reasonable physical exercise. Thus, students of trade vocational schools who follow a specific schedule of work, relaxation, and diet have a longer period of bone growth than do high-school pupils whose daily regime may be less rigorous.

Individuals who have worked for many years under proper working conditions are, consequently, not subject to premature wear and tear of the bone tissue, and their bones age later than those of individuals used to poorer working conditions.

Individual variability of the bone system is, thus, caused both by biological and by social factors. External stimuli are perceived biologically by the organism and lead to reorganization of the skeleton. The ability of the bone tissue to adapt itself to changing functional demands by reorganization constitutes the biological cause of bone changeability, whereas the character of the occupation, the work load, the intensity of the work, the person's life-style and other social factors are the social causes of this changeability.

Such is the relationship of social and biological factors in the structure and development of the skeleton. With a proper understanding of this relationship, a direct effect can be produced on the bone system by selecting appropriate physical exercises for work and sports and by changing the social conditions of life. In members of the poor substratum of Vietnam, for instance, who were always forced to walk barefoot over ground on which balance was retained with difficulty and, moreover, to carry heavy loads on their heads (loaded baskets), the toes are widely spread, and the big toe is large, set aside from the other toes, and very mobile, like the big toe of anthropoid apes. This provided the grounds for the racist view of bourgeois anthropologists, who claimed that the Vietnamese were a retarded nation. Such a foot structure, however, is encountered only in the poor and is caused by certain living and working conditions. With the better living conditions in liberated Vietnam, this foot structure is gradually beginning to disappear.

Thus, the social and biological factors in the development of man cannot be separated. The essence of man is social, but it is manifested through his biological substrates. The origin and development of man (anthropogenesis) and the development of the human body structure should, therefore, be considered in the light of a single socio-biological problem solved by concrete scientific research.

## GENERAL INFORMATION ON BONE ARTICULATIONS (GENERAL SYNDESMOLOGY)

Bone fusion by connective or (later) cartilaginous tissue was the elementary form of bone joining (in lower aquatic vertebrates). Such compact joining of bones, however, limits the volume of movements. With the formation of bony levers of movement, slits and cavities began appearing in the interstitial tissue between the bones because of its resorption. As a result a new type of bone joining, interrupted joining, articulation, developed. The bones not only became joined to each other, but they articulated so that joints formed which allowed the bone levers to perform wide movements especially necessary for terrestrial animals. Thus, two types of bone joining developed in the process of phylogenesis: the elementary, compact joining with a limited range of movements and a later, interrupted type allowing wide movements. In reflection of this phylogenetic process of the adaptation of animals to the environment by movement in the joints, the development of bone articulations in the embryogenesis of man also goes through these two stages. At first the skeletal germs are connected to each other by layers of mesenchyme. The mesenchyme transforms to connective tissue from which the bone-joining apparatus develops. If the areas of connective tissue located between the bones are compact, then compact contiguous joining of the bones, called fusion or synarthrosis occurs. If a cavity forms between these

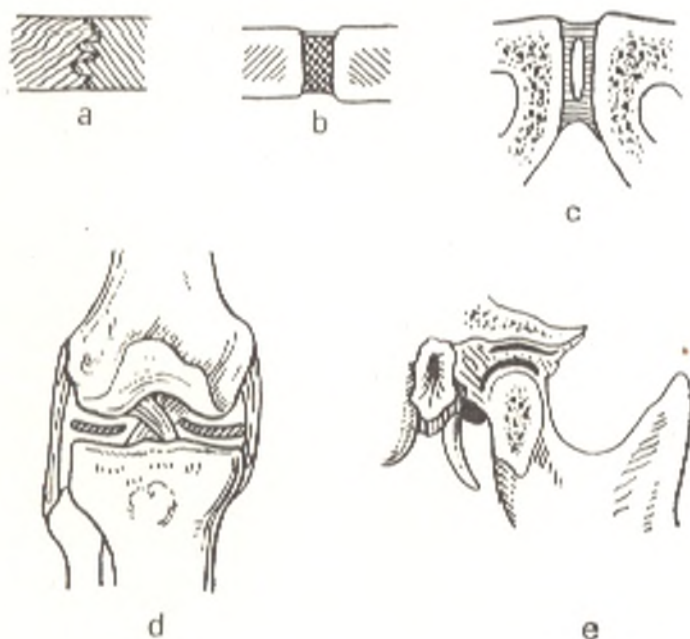


Fig. 21. Schematical representation of types of bone joining.  
Contiguous articulations: a, by means of connective tissue (syndesmosis); b, by means of cartilage (synchondrosis).

Transitional type between contiguous and interrupted articulations:

c, half-joint (hemiarthrosis).

True joint:

d, true joint with intra-articular ligaments and menisci;

e, joint with an intra-articular disc dividing the joint into two storeys

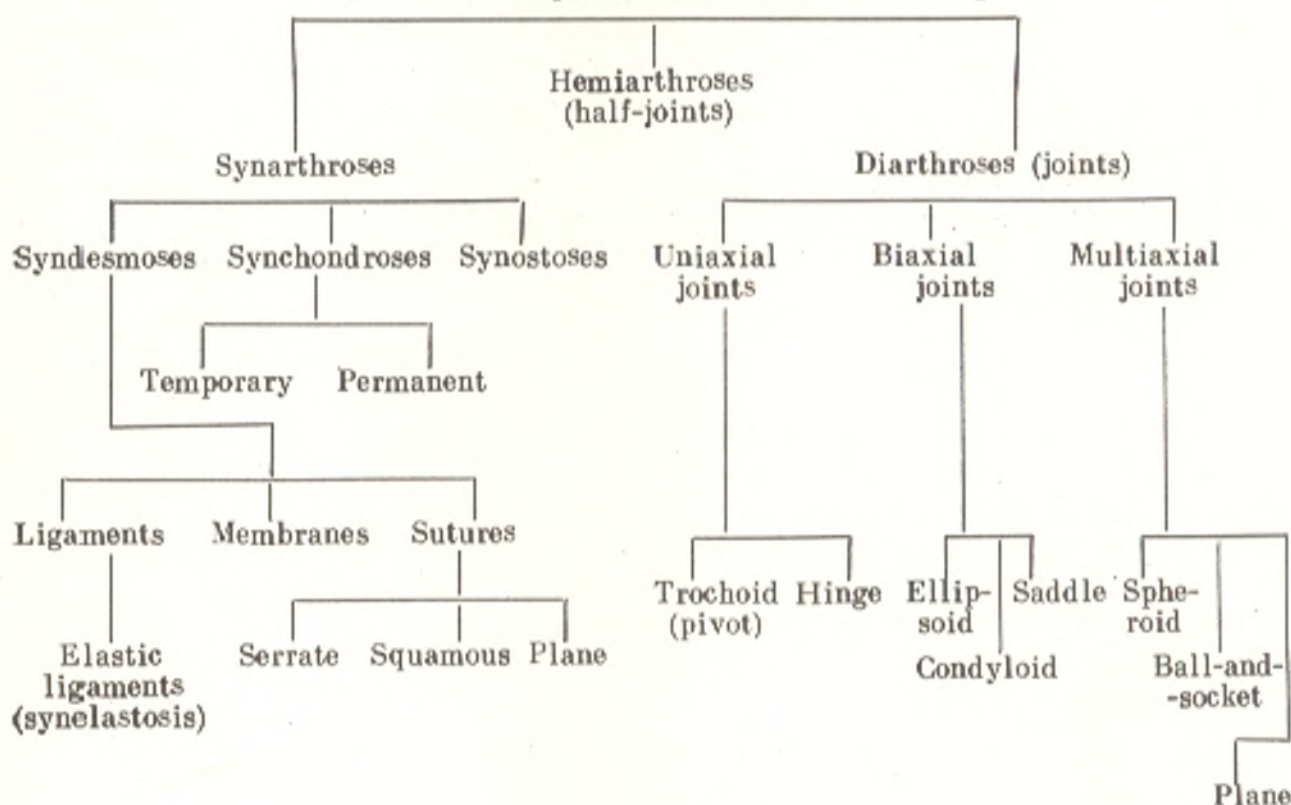
areas as the result of resorption of the connective tissue, then another type of joining, cavitary or interrupted, forms; it is called diarthrosis.

Thus, according to development, structure, and function, all bone articulations (articulationes ossium) can be divided into two large groups (Figs. 21 and 23).

1. *Contiguous* articulations, **synarthroses** (BNA), earliest in development, fixed in function or allowing slight movement.

2. *Interrupted* (synovial) articulations, **diarthroses** (BNA), latest in development and permitting more movements functionally. Between these forms there is a transitional form, from contiguous to interrupted or vice versa. It is characterized by the presence of a small gap which does not have the structure of a true articular cavity, and because of this the articulation is called a half-joint, or **hemiarthrosis**.

#### Schematical Representation of Bone Joining



#### CONTIGUOUS ARTICULATIONS (SYNARTHROSES)

As it is pointed out above, the skeleton goes through three developmental stages: connective-tissue, cartilaginous, and bony. Since the transition from one stage to another is also associated with change of the tissue located between the bones, the joining of bones also goes through three developmental phases as a result of which the following three types of synarthroses are distinguished.



I. If connective tissue remains in the space between the bones after birth, they become joined by means of this tissue and the joint is called **fibrous** (*articulationes fibrosa*), or **syndesmosis** (Gk *syndesmos* ligament).

II. If the intermediate connective tissue transforms to cartilaginous tissue, which remains after birth, the bones become joined by means of cartilaginous tissue, and the joint is called **cartilaginous** (*articulationes cartilaginae*) or **synchondrosis** (Gk *syn* together, *chondros* cartilage).

III. Finally, if the connective tissue between the bones transforms to bone tissue (in desmal osteogenesis) or first to cartilaginous and then to bone tissue (in chondral osteogenesis), the bones become joined by means of bone tissue, and the joint is called **synostosis** (BNA).

The character of bone joining is not permanent throughout an individual's life. According to the three stages of ossification, syndesmoses may change to synchondroses and synostoses. Synchondroses and synostoses are the final developmental phase of the skeleton.

#### TYPES OF SYNDESMOSES

**Syndesmosis** (*articulatio fibrosa*) is contiguous joining of bones by means of connective tissue.

1. If the connective tissue fills a large space between the bones, the articulation acquires the form of **interosseous membranes** (*membrana interossea*), for instance between the bones of the forearm or leg.

2. If the connective tissue between the bones has the structure of fibrous bundles, fibrous **ligaments** (*ligamenta*) form in all the joints. In some places (e.g. between the vertebral arches), the ligaments are composed of elastic connective tissue (*synelastosis*, BNA) and are consequently yellow in colour (*ligamenta flava*).

3. Until wide remnants of the primary connective tissue remain between the bones of the skull-cap, the joints are called **fontanelles** (*fonticuli*).

4. When the intermediate connective tissue takes the character of a thin layer between the skull bones, **sutures** (*suturae*) form. The following sutures are distinguished according to the shape of the articulating bone margins:

(a) *serrate* (*sutura serrata*), when the projections on the margin of one bone fit between the projections on the opposing bone (most bones of the skull-cap articulate in this fashion);

(b) *squamous* (*sutura squamosa*), when the margin of one bone overlaps that of the opposing bone (articulation between the margins of the temporal and parietal bones);

(c) *plane* (*sutura plana*), apposition of smooth margins (joining of the bones of the facial cranium).

#### TYPES OF SYNCHONDROSES

**Synchondrosis** (*articulatio cartilaginae*) is contiguous joining of bones by means of cartilaginous tissue. It is a resilient articulation because of the physical properties of cartilage. Synchondrosis permits only slight movements

of a springy character. They depend on the thickness of the cartilaginous layer: the thicker the layer, the more the range of movements.

According to the property of the cartilaginous tissue (whether hyaline or fibrous), the following types of synchondrosis are distinguished: (1) *hyaline*, e.g. between the ribs and the sternum, and (2) *fibrous*. Fibrous synchondrosis occurs in places of high resistance to mechanical factors, for instance, between the vertebral bodies. Because of its resilience it serves as a buffer of jolts and shocks.

The following synchondroses are distinguished according to the duration of their existence:

1. *Temporary*, existing only to a definite age after which they are replaced by synostoses, for instance, synchondrosis between the epiphysis and metaphysis or between the three bones of the pelvic girdle which fuse to form a single pelvic bone. Temporary synchondroses are the second phase of skeletal development.

2. *Permanent*, existing throughout life, for instance, synchondroses between the pyramid of the temporal bone and the sphenoid bone, between the pyramid and the occipital bone.

### TRANSITIONAL ARTICULATIONS, HALF-JOINTS, HEMIARTHROSES

When a narrow gap that does not have the character of a true articular cavity with an articular surface and a capsule forms in the centre of a synchondrosis, the articulation becomes transitional from the contiguous to the interrupted type, to joints. This articulation is called a **half-joint** (*hemiarthrosis*), e.g. the joint between the two pubic bones, the pubic symphysis (*symphysis pubica*). A hemiarthrosis may form as the result of reverse transition from interrupted to contiguous articulation due to reduction of joints. For instance, in some vertebrates only a gap remains in the intervertebral disc in place of the articular cavity between the bodies of some of the vertebrae.

### INTERRUPTED (SYNOVIAL) ARTICULATIONS, JOINTS, DIARTHROSES

A **joint** is an interrupted, cavitary, mobile articulation (*articulatio synovialis*) (Gk *arthron* joint, hence *arthritis*, inflammation of a joint). Articular surfaces of the articulating bones, the articular capsule enclosing the articular ends of the bones, and a joint cavity within the capsule between the bones are distinguished in each joint (Fig. 22).

1. The **articular surfaces** (*facies articulares*) are covered by **articular cartilage** (*cartilago articularis*), which is hyaline, less frequently fibrous, and 0.2-0.5 mm thick. Because of continuous rubbing articular cartilage is smooth, which reduces friction on the articular surfaces; owing to its elasticity cartilage reduces the shocks and serves as a buffer. The articular surfaces are usually congruent. For instance, if the articular surface of one of the

bones is convex (the articular head), that of the other bone is accordingly concave (the articular cavity, *fossa articularis*).

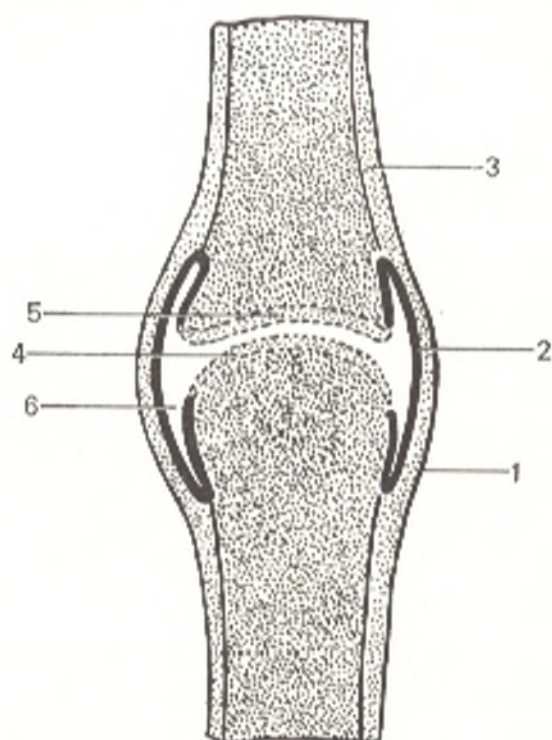
2. The **articular capsule** (*capsula articularis*) encloses the joint cavity hermetically and is attached to the articulating bones along the margin of the articular surfaces or at some distance from them. It consists of an outer *fibrous membrane* (*membrana fibrosa*) and an inner *synovial membrane* (*membrana synovialis*). The synovial membrane surface facing the joint cavity is lined with a layer of endothelial cells which makes it smooth and shiny. The membrane secretes a sticky, clear *synovial fluid* (*synovia*) into the cavity of the joint. The synovial membrane terminates along the edges of the articular cartilages. It often produces small projections called *synovial villi* (*villi synoviales*). In some places it also forms large and small *synovial folds* (*plicae synoviales*), which protrude into the joint cavity. Some of these folds contain a large amount of fat growing into them from the outside as a result of which *fatty pads* (*plicae adiposae*) form. The *plicae alares* of the knee joint are one example.

Sacular protrusions or eversions of the synovial membrane form sometimes in thinned areas and are called *synovial bursa* (*bursae synovialis*). They are found around the tendons or under muscles located close to the joint. The bursae are filled with synovia and reduce the friction of the tendons and muscles during movement.

3. The **joint cavity** (*cavitas articularis*) is a closed, air-tight slit bounded by the articular surfaces and the synovial membrane. Under normal conditions it is not an empty cavity but contains synovial fluid which moistens and lubricates the articular surfaces and lessens the friction between them. Synovia also contributes to fluid metabolism and strengthens the

Fig. 22. Diagram of a joint.

- 1, fibrous layer of the articular capsule (*membrana fibrosa*);
- 2, synovial layer of the articular capsule (*membrana synovialis*);
- 3, periosteum;
- 4 and 5, articulating surfaces of bones covered by articular cartilage;
- 6, joint cavity (*cavum articulare*)



joint by providing cohesion of the surfaces. It also serves as a buffer, which relieves pressure and jolts of the articular surfaces since movement at the joint consists not simply of gliding movements but also in separation of the surfaces. The pressure between the articular surfaces is negative (below that of the atmosphere). That is why atmospheric pressure prevents them from drawing apart. (This explains the sensitivity of some diseased joints to fluctuations of atmospheric pressure, as a result of which such patients can predict a spell of bad weather.)

In injury to the articular capsule, air enters the joint cavity as a consequence of which the articular surfaces draw apart immediately. Besides the negative pressure in the cavity, ligaments (intra-articular and extra-articular) and muscles with sesamoid bones lodged in the thickness of their tendons also prevent the articular surfaces from drawing apart under normal conditions. Ligaments and tendons of muscles constitute the auxiliary strengthening apparatus of the joint.

*Intra-articular cartilages, accessory devices* complementing the articular surfaces, are encountered in some joints. They are made up of fibrous cartilaginous tissue in the form of complete cartilaginous plates called **discs** (*disci articulares*), semilunar structures known as **menisci** (*menisci articulares*) (Gk *meniscos* crescent) or **cartilaginous rims** (*labra glenoidalia*), *articular lips*.

All these intra-articular cartilages are attached to the articular capsule along their circumference. They are usually regarded as devices which serve to level out incongruent articular surfaces. Certain authors, however, claim this point of view to be incorrect since incongruity of the articular surfaces is displayed only on macerated bones whereas all the elements of a joint in a living organism are fully congruent. Intra-articular cartilages form as the result of new functional demands, as a response to complicated and increased static and dynamic load. They develop from the cartilages of primary contiguous articulations and possess strength and elasticity, resist jolts and facilitate movements at the joints.

## JOINT BIOMECHANICS

In the organism of a living human, joints play a triple role (Davies, 1961): (1) they help to maintain body posture; (2) they contribute to the transposition of body parts in relation to one another; (3) they are organs of locomotion of the body in the environment.

This work of the joints is associated closely with the work of muscles. The joints form "gaps" in the rigid skeleton and are a potential source of weakness and instability of the upright and mobile skeleton. This shortcoming is compensated for by the muscles, which even at rest reinforce the joints much as wires reinforce a radio tower. This makes the role of the muscles as active motor organs even more important since without the muscles, the joint, a passive organ of movement, cannot act.

Since the conditions for muscular activity in the process of evolution differed, the articulations that formed differed in shape and function. According to shape, the articular surfaces can be regarded as segments of geometrical rotation bodies: a cylinder rotating on a single axis; an ellipse rotating

on two axes; and a sphere rotating on three or more axes. Movements at the joints occur on three main axes.

The following types of movements at the joints are distinguished:

1. Movement on the frontal transverse (horizontal) axis: **flexion** (*flexio*), i.e. a reduction of the angle formed by the articulating bones, and **extension** (*extensio*), i.e. increase of this angle.

2. Movements on the sagittal (horizontal) axis: **adduction** (*adductio*), i.e. drawing towards the median plane, and **abduction** (*abductio*), i.e. drawing away from it.

3. Movements on the vertical axis, i.e. **rotation** (*rotatio*), inward and outward or to the right and to the left.

4. Movement in a circular manner, **circumduction** (*circumductio*), by changing from one axis to another with one end of the bone describing a circle and the whole bone describing the figure of a cone.

Gliding movements of the articular surfaces are possible as well, as they draw apart, for instance, when the fingers are stretched.

Movements at joints which have several pivotal axes often occur not in isolation on one of the axes, but simultaneously on two or three axes in different combinations. For instance, abduction at the shoulder joint on the sagittal axis is combined with flexion of the joint (*anteflexio*) on the frontal axis. This is usually not noticeable. In some diseases of the joints or disorders of muscle functioning, however, such combination is broken up, and each movement is made separately. In impaired function of the deltoid muscle serving this joint, for instance, to abduct the arm, the patient must first bend it.

The character of movement at the joint is determined by the shape of the articular surfaces. The range of movements at the joints depends on the difference in the size of the articulating surfaces. If, for example, the articular fossa forms an arc of 140 degrees and the head forms an arc of 210 degrees, the arc of movements is 70 degrees. The greater the difference in the length of the articulating surfaces, the larger the arc (range) of movements, and vice versa. If both articulating surfaces are equal, no or only slight movement is possible. Movements at the joints are limited not only by a decrease in the difference in the length of the articulating surfaces but also by various types of brakes; some ligaments, muscles, bony projections, and so on, play this role. Since increased physical (force) load can cause work hypertrophy of the bones, ligaments, and muscles and lead to growth of these structures and restriction of movements, different joint flexibility is encountered in athletes, depending on the sport. For example, the range of movements at the shoulder joint is greatest in track and field athletes and least in weight lifters and wrestlers. Movements at joints with particularly strongly developed brakes are sharply limited. Such joints are called amphiarthroses (see p. 127).

Intra-articular cartilages also have an effect on the range of movements, increasing their number. Thus, the temporomandibular articulation, which belongs to biaxial joints according to the shape of the articular surfaces, has an intra-articular disc which allows three types of movements.

## REGULAR FEATURES OF LIGAMENT ARRANGEMENT

Ligaments (*ligamenta*) are that part of the joint which lends it strength; they direct and check the action of the joints. Therefore, *guiding* and *check* ligaments can be distinguished. Since the number of ligaments in the human body is very great, to study and remember them, one must know the general laws of their arrangement.

1. Ligaments guide the movement of the articular surfaces *on a definite pivotal axis* of a given joint and are consequently distributed in each joint according to the number and position of its axes.

2. Ligaments are arranged: (a) *perpendicular* to the given pivotal axis and (b) *mainly at the ends of the axis*.

3. They are located in the plane of the given movement in the joint.

In an interphalangeal joint with a single frontal rotation axis, for instance, the guiding ligaments stretch along the sides of the axis (*ligamenta collateralia*) and vertically. In the biaxial elbow joint, the collateral ligaments also run vertically, perpendicular to the frontal axis, at its ends, while the annular ligament (*lig. anulare*) stretches horizontally, perpendicular to the vertical axis. Finally, ligaments in the multiaxial hip joint are arranged in different directions.

## CLASSIFICATION AND GENERAL CHARACTERISTICS OF JOINTS

The classification of joints can be based on the following principles: (1) the number of articular surfaces; (2) the shape of the articular surfaces; and (3) function.

*The following joints are distinguished according to the number of articular surfaces.*

1. **Simple joint** (*art. simplex*), which has only two articular surfaces, e.g. the interphalangeal joints.

2. **Compound joint** (*art. composita*), which has more than two articulating surfaces, e.g. the elbow joint. A compound joint is formed of several simple joints at which movements can be made separately. Since there are several articulations in a compound joint, they have ligaments in common.

3. **Complex joint** (*art. complexa*) contains an intra-articular cartilage in the articular capsule. This cartilage divides the joint into two compartments (a bilocular joint) either completely (if the intra-articular cartilage is shaped like a disc, e.g. in the temporomandibular joint) or incompletely (if the cartilage is a crescentic meniscus, e.g. in the knee joint).

4. **Combined joint** is a combination of several isolated joints, located separately but functioning together. Such are, for example, the two temporomandibular joints, the proximal and distal radio-ulnar joints, and others. A combined joint is a functional combination of two or more anatomically separate joints, and in this it differs from the compound and complex joints, each of which is an anatomical entity made up of functionally different articulations.

According to shape and function, joints are classified as follows.

The function of a joint is determined by the number of axes on which the movement occurs. The number of axes on which movements are accomplished in the given joint, in turn, depends on the shape of the articulating surfaces. A pivot, or trochoid (cylindrically shaped) joint, for instance, allows movement only on one pivotal axis. The direction of the axis in this case coincides with the position axis of the cylinder itself: if the cylindrical head is positioned vertically, then the movement will be made about the vertical axis (trochoid, or pivot joint). If the cylindrical head lies horizontally, however, then the movement will be made about one of the horizontal axes coinciding with the position axis of the head, e.g. the frontal axis (hinge joint). In contrast, a spherical shape of the head allows rotation about the many axes that coincide with the radius of the head (ball-and-socket joint) (Fig. 23).

Consequently, there is complete conformity between the number of axes and the shape of the articulating surfaces: the shape of the surfaces determines the character of movements at the joint, and, conversely, the character of movements at the joint determines its shape. This illustrates the law of the unity of form and function. Proceeding from this law, the following common anatomico-physiological classification of joints can be laid down.

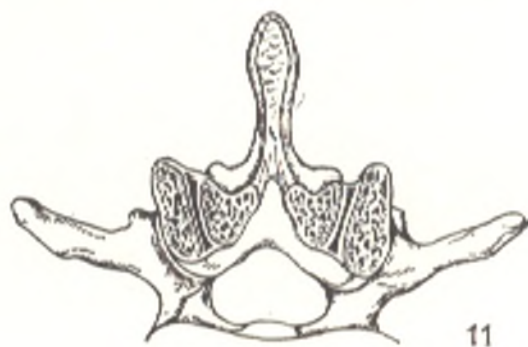
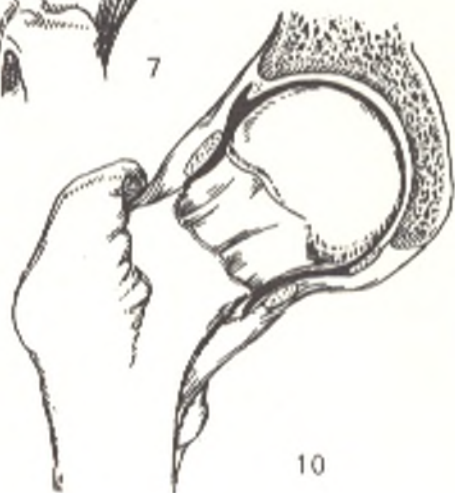
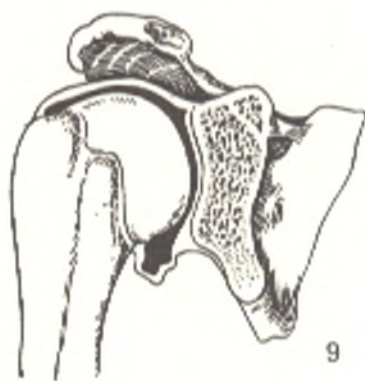
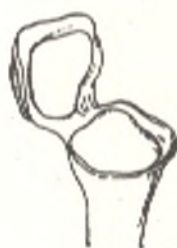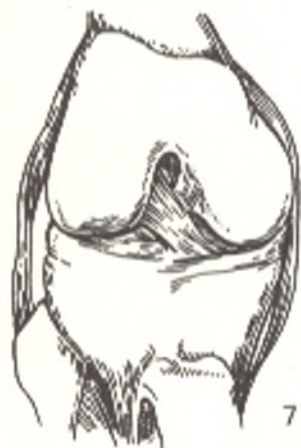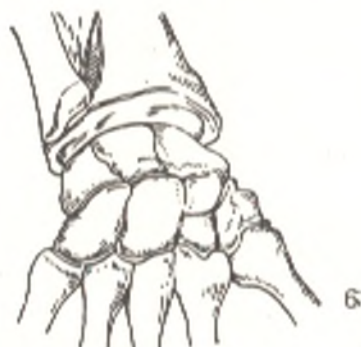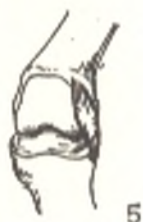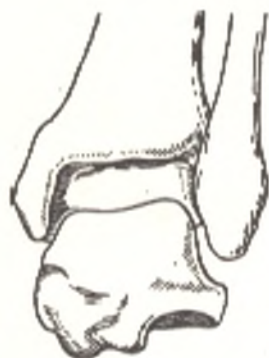
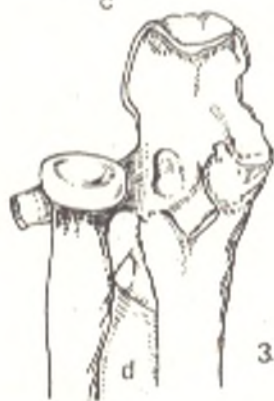
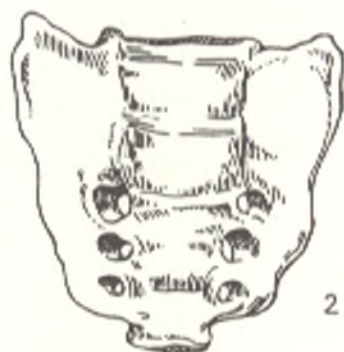
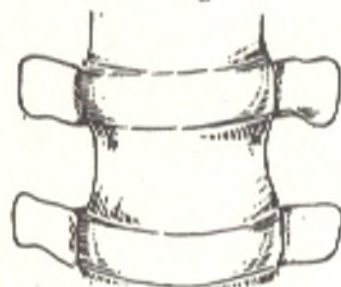
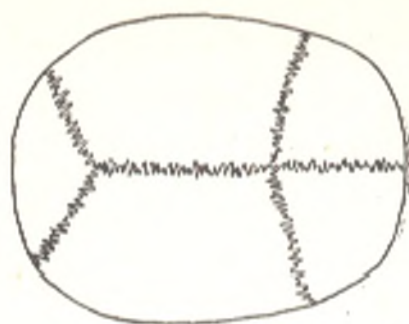
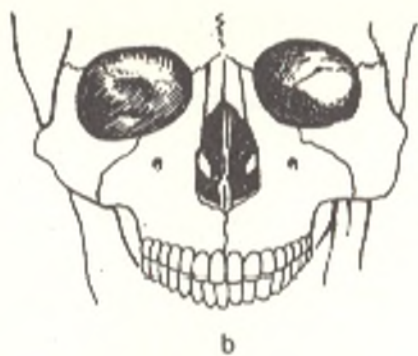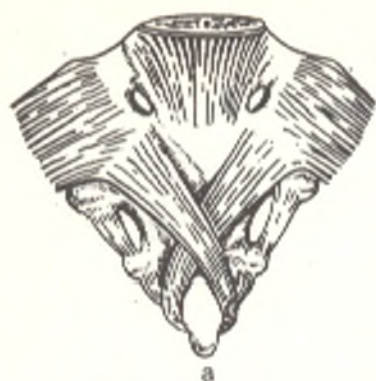
#### UNIAXIAL JOINTS

1. **Trochoid joint** (*art. trochoidea*). This is a cylindrical or wheel-like articular surface (Gk *trochos* wheel, *eidōs* form) whose axis is a vertical line running parallel to the long axis of the articulating bones or to the vertical body axis; it permits movements on one vertical axis, i.e. rotation; it is also called the *pivot joint*.

Davies (1961) distinguishes two types of pivot joints. In the first type the bone pivot rotates within a ring formed by the articular fossa and a ring of ligament: e.g. the proximal radio-ulnar joint in which the radius rotates inward (pronation) and outward (supination). In the second type, in contrast, the ring formed by the ligament and articular fossa rotates on a bone pivot: e.g. the articulation between the atlas and the axial dens. In this joint the ring of the atlas rotates to the right and to the left about the dens of the axial vertebra.

2. **Hinge joint** (*ginglymus*) (Gk *ginglymos* hinge). An example are the interphalangeal joints of the fingers and toes. The articular surface is a cylinder stretching transversely whose long axis is a transverse line running in the frontal plane perpendicular to the long axis of the articulating bones; as a result movements at a hinge joint are made on this frontal axis (flexion and extension). A guiding groove and crest on the articulating surfaces prevent lateral slipping and facilitate movement on a single axis.

If the guiding groove of the hinge is not perpendicular to the axis but forms a certain angle with it, then a screw-like line can be drawn on extension of the groove. Such a hinge joint is regarded as a screw joint (e.g. the





humero-ulnar joint). A screw joint permits the same movement as a true hinge joint.

According to the regular features of ligament arrangement, the guiding ligaments in a pivot joint are perpendicular to the vertical pivotal axis while those in a hinge joint are perpendicular to and on the sides of the frontal axis. So arranged, the ligaments hold the bones in place without hindering movement.

## BIAXIAL JOINTS

1. **Ellipsoid joint** (*articulatio ellipsoidea*) (for instance, the radiocarpal or wrist joint). The articulating surfaces are segments of an ellipse: one of them is convex, oval and unequally curved in two directions; the other is correspondingly concave. They allow movements on two horizontal axes which are perpendicular to each other: flexion and extension on the frontal axis and abduction and adduction on the sagittal axis. Ligaments in ellipsoid joints are perpendicular to and at the ends of pivotal axes.

2. **Condylloid joint** (*articulatio condylaris*) (e.g. the knee joint) (Davies, 1961). A condylloid joint has a convex articular head in the form of a protruding rounded process which resembles an ellipse in shape and is called a *condyle* (*condylus*) (*Gk kondylos* knuckle). A depression on the articular surface of the other bone corresponds to the condyle, though the difference in their size may be considerable.

A condylloid joint may be regarded a variety of the ellipsoid articulation, a transient from the hinge to the ellipsoid joint. The frontal axis is therefore its principal pivotal axis.

A condylloid joint differs from a hinge joint in that the difference in the size and shape of the articulating surfaces is greater. As a result, in distinction from the hinge joint, the condylloid joint allows movements on two axes. It differs from an ellipsoid joint in the number of articular heads. Condylloid joints always have two condyles located more or less sagittally. They are enclosed either in a common capsule (e.g. two condyles of the femur forming the knee joint) or in different articular capsules, as is the case in the atlanto-occipital joint. Since the heads in a condylloid joint are not strictly ellipsoid, the second axis is not necessarily horizontal, as it is typical of an ellipsoid joint; it may be vertical as well (the knee joint).

Fig. 23. Different types of bone joining.

a, b, c, d, different types of syndesmosis (contiguous joining of bones by means of connective tissue):

- a, ligaments;
- b, plane suture;
- c, serrate suture;
- d, membrane;

1, synchondrosis (contiguous joining of bones by means of cartilage);

2, synostosis (contiguous joining of bones by means of bony tissue);

3-11, interrupted joining of bones, joints:

3, trochoid, or pivot joint, art. trochoidea (art. radioulnaris proximalis);

4 and 5, hinge joint, ginglymus (art. talocruralis and art. interphalangea);

6, ellipsoid joint, art. ellipsoidea (art. radiocarpea);

7, condylloid joint, art. condylaris (art. genus);

8, saddle joint, art. sellaris (art. carpometacarpea pollicis);

9, ball-and-socket joint, art. spheroidea (art. humeri);

10, cotyloid joint, art. cotylica (art. coxae);

11, plane joint, art. plana (art. intervertebralis)

A joint in which the condyles are enclosed in different capsules is close to an ellipsoid articulation in function (the atlanto-occipital joint). But if the condyles are located close to each other and enclosed in a common capsule, e.g. the knee joint, the articular head on the whole resembles a cylinder lying on its side (block) and divided in the middle (the space between the condyles). In this case the condyloid joint will be closer in function to the hinge joint.

3. **Saddle joint** (*articulatio sellaris*) (e.g. the carpometacarpal joint of the thumb). This joint is formed by two saddle-shaped articulating surfaces, one "astride" the other moving lengthwise and across the other. As a result this joint allows movement on two mutually perpendicular axes: frontal (flexion and extension) and sagittal (abduction and adduction).

Biaxial joints also permit a change of movement from one axis to another, i.e. movement in a circular manner (circumduction).

## MULTIAXIAL JOINTS

1. **Ball-and-socket joint** (*art. spherioidea*) (e.g. the shoulder joint). One of the articular surfaces forms a convex spherical head, the other—a correspondingly concave articular cavity. Theoretically, movements can occur on many axes which correspond to the radii of a sphere. Practically, however, only the following three main axes, perpendicular to each other and intersecting in the centre of the head, are distinguished: (1) the transverse (frontal) axis, the site of forward flexion, anteflexion, when the moving part together with the frontal plane forms an angle open to the front, and of backward flexion, retroflexion, when the angle is open to the back; (2) the anteroposterior (sagittal) axis, on which abduction and adduction are accomplished; and (3) the vertical axis, on whose circumference inward and outward rotation occurs. Circumduction takes place when movement changes from one axis to another. The ball-and-socket joint is the most freely mobile joint. Since the range of movement depends on the difference in the extent of the articular surfaces, the articular fossa in such a joint is small in comparison to the size of the head. Typical ball-and-socket joints have only a few accessory ligaments, which determines their freedom of movement.

A variety of the ball-and-socket articulation is the cotyloid joint (*art. cotylica*) (Gk *kotyle* cup)<sup>1</sup>. Its articular fossa is deep and embraces the greater part of the head. As a result movement is more restricted at this joint than at a typical ball-and-socket joint. An example of this type of articulation is the hip joint in which the construction lends greater stability to the joint.

2. **Plane joints** (*art. plana*) (e.g. the intervertebral joints). The articular surfaces in these joints are almost flat. They can be regarded as the surfaces of a sphere with a very large radius. They consequently allow movement on all three axes, but the range of movement is small because the articular surfaces differ only slightly.

<sup>1</sup> Enarthrosis (BNA).

The ligaments are arranged on all sides of a plane joint.

*Joints with limited movement (amphiarthroses).* Some manuals identify a group of articulations which differ in the shape of the articular surfaces but are similar in some other features: they have a short, tightly stretched articular capsule and a very strong auxiliary apparatus, particularly short reinforcing ligaments, which cannot be stretched. As a result the articulating surfaces are in close contact, which limits movements sharply. Such joints permitting only limited movement are called amphiarthroses (BNA). They reduce jolts and shocks between the bones. The midcarpal joint is an example of such articulation. Plane joints in which, as was pointed out above, the articular surfaces are equal in extent, can also be amphiarthroses. Amphiarthroses permit only very slight gliding movement.

### COORDINATION OF THE JOINTS<sup>1</sup>

The function of each joint cannot be considered in isolation, just as the functions of the muscles cannot be considered separately. In a living organism all the articulations are coordinated to various degrees which fact plays a decisive role in body statics and dynamics. The coordination of the joints is responsible for the maintenance of a definite body posture or for the change in the shape of its parts. For instance, twisting of the arm bone about the long axis puts the forearm bones in a position which is most favourable for movements; arching of the foot is one of the adaptations for the vertical posture of the body, etc. Coordination of the joints also facilitates a large range of movements of parts of the body by slight movements between some of the bone links: e.g. the great range of movements in the spine on the whole depends on the sum of the slight movements between the vertebrae.

Bones may articulate in parallel or consecutive order. In *consecutive* articulation one bone link is a kind of continuation of the other; in *parallel* joining the bones stretch parallel to each other. For instance, the radius is joined to the humerus and the carpal bones consecutively and with the ulna in parallel.

In consecutive joining of bones, the large range of movements is distributed more easily along several joints each having limited mobility. The large range of movements of the head, for instance, is determined not only by the type of articulation between the skull and the atlas and axis, but also by a great number of hardly mobile cervical vertebrae which are joined consecutively.

*Parallel* joining of bones permits a greater variety of movements.

The distribution of movements between several joints requires a different type of coordination. *Actively* and *passively coordinating joints* are distinguished. Actively coordinating joints are those which are put into action by muscles, for instance all the articulations between vertebrae in flexion and extension of the trunk. Passively coordinating joints are those in which one of the bones is not set in action by muscles but passively follows other joints to which muscles are attached. The subtalar joint serves as an example; movements are made at this joint in dorsal flexion at the ankle joint though the muscles are not attached to the talus. Movement also occurs at passively coordinating joints in stretching ligaments and aponeuroses, e.g. at the articulations of the metatarsal and tarsal bones in passive raising of the great toe.

Knowledge of joint coordination is of practical importance. Thus, if one joint is involved in a disease, movements are disturbed in other joints coordinating with it. Often a patient complains of pain in two joints though only one of them is affected.

<sup>1</sup> This section is based on Davies, 1961.

## THE SKELETON OF THE TRUNK

The components of the locomotor system of the trunk develop in all vertebrates from primary segments (somites) of the dorsal mesoderm stretching to the sides of the notochord and the neural tube (see "The Initial Development of the Human Organism"). The mesenchyme (sclerotome) formed from the medioventral part of the somite gives rise to the skeleton around the notochord, while the middle part of the primary segment (myotome) gives rise to the muscles (the dermatome forms from the dorsolateral part of the somite). With the formation of the cartilaginous and later the bony skeleton, the muscles (myotomes) receive support on the hard parts of the skeleton, as a result of which these parts are also arranged in a metameric fashion, alternating with the muscle segments. This principle underlies the structure of the axial skeleton of the body. The spine or *vertebral column* is composed of a longitudinal row of segments called *vertebrae*, each arising from the nearest halves of two adjacent sclerotomes. In its primitive form, as it is encountered in the lower forms or at the beginning of the development of the human embryo, the vertebral column is made up of cartilaginous *upper and lower arches* arranged in a metameric fashion on the ventral and dorsal aspects of the notochord.

With further evolution, the components of the vertebrae grow, which leads to two results: firstly, to the fusion of all parts of the vertebra and, secondly, to the disappearance of the notochord and its replacement by the vertebral bodies. The bodies grow around the notochord and compress it. As a result it loses its binding significance for the vertebrae and disappears, remaining only between the vertebrae (intervertebrally) as a *pulpy nucleus (nucleus pulposus)* in the centre of the intervertebral discs. The upper (neural) arches embrace the spinal cord and fuse to form the unpaired spinous processes and the paired articular (two pairs) and transverse processes. The lower (ventral) arches give rise to the ribs which lie in the spaces (myosepta) between the muscle segments and enclose the common body cavity. After going through the cartilaginous stage, the vertebral column becomes bony except for the spaces between the vertebral bodies where the intervertebral cartilage connecting them remains.

The evolution of the vertebral column involved mainly the differentiation of its parts as a consequence of the change to a terrestrial mode of life and the movement of the body on dry land by means of the limbs. In aquatic animals (fish) only the trunk and tail are distinguished. Fish have no neck, and all the vertebrae carry ribs; the immobile head is directly continuous with the trunk which lends the front part of the body a stable streamline form advantageous for moving in water. With the change to life on dry land (beginning with the amphibians), the head acquires the capacity for movement. As a consequence, the ribs nearest to it are lost and remain only as the costal part of the transverse processes of the vertebrae. As a result the vertebrae nearest to the head transform to cervical vertebrae and form the cervical part of the vertebral column. The formation of a mobile neck in terrestrial animals is proved by the fact that in aquatic mammals

(e.g. whales), the cervical vertebrae fuse, the neck disappears almost completely, and the head again loses its mobility.

Because developed ribs are preserved, the costal (also called the thoracic) part of the vertebral column can be distinguished since ribs remain only in this segment. In the other segments, the ribs became rudimentary structures included in the transverse vertebral processes. The development of the lungs also distinguished the thoracic part, as did the development of the limbs and the consequent development of the breast bone (sternum). As a result of the development of the breast bone, the thoracic part of the vertebral column contributed to the formation of the thoracic cavity. With the development of the hind limbs in quadrupeds, the pelvic girdle became connected to the axial skeleton, to two or more vertebrae which fused to form a single bone, the sacrum. This led to strengthening of the vertebral column and the lumbar and sacral part were distinguished in it. The sacrum fused mainly in those animals whose body was fully supported only by the hind limbs. By contrast, the tail part of the vertebral column transformed to a small rudimentary remnant because the tail underwent reduction. The processes pointed out led to the separation of the human vertebral column into parts (segments) and to the different structure of the vertebrae.

The number of vertebrae in different mammals varies sharply in reflection of the general line of evolution, i.e. the number reduces in the progression from the lower to the higher mammals and man. There are seven cervical vertebrae in almost all mammals, irrespective of the length of the neck (e.g. in the mouse and the giraffe), which emphasizes their common origin. In the thoracic segment, in contrast, the number of vertebrae ranges from nine to 24 in accordance with the number of the remaining ribs. Man has 12 ribs, though their number may vary from 11 to 13. The number of the lumbar vertebrae varies greatly in animals (from two to nine), while in man there are four to six, usually five, depending on the extent of fusion with the sacrum. Of particular practical interest are phenomena taking place in the human in the region of the transitional vertebrae: the dorsolumbar (the twelfth thoracic), lumbodorsal (the first lumbar), lumbosacral (the fifth lumbar), and the sacrolumbar (the first sacral).

When there is a thirteenth (lumbar) rib, the first lumbar vertebra becomes the thirteenth thoracic vertebra, and only four lumbar vertebrae remain. A twelfth thoracic vertebra that has no rib becomes similar to the lumbar vertebra (lumbarization), in which case there are only eleven thoracic vertebrae but six lumbar vertebrae. A similar lumbarization of the first sacral vertebra may occur when it does not fuse with the sacrum; if the fifth lumbar vertebra fuses with the first sacral and becomes similar to it (sacralization), there will be only four lumbar but six sacral vertebrae.

Thus, there are 24 presacral vertebra in a human, though their number may increase to 25 or reduce to 23. This number of presacral vertebrae reflects strikingly the progressive reduction in their number in the process of evolution and ranges from 28 to 25 in monkeys, including anthropoids, and is 24 in man. The sacrum is also made up of a different number of vertebrae fused to each other; the number of sacral vertebrae with which the pelvic girdle

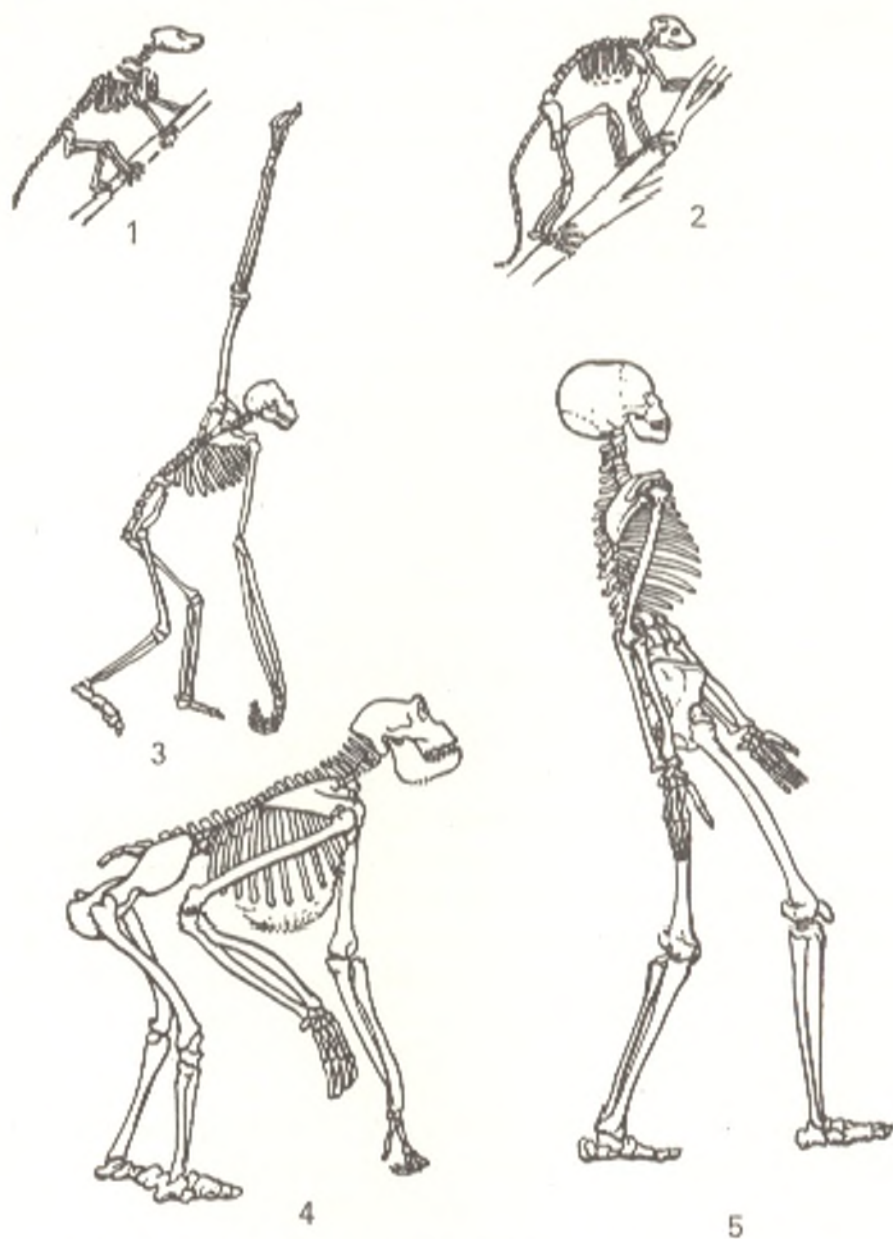


Fig. 24. Evolution of the skeleton of higher vertebrates.

1, fossil marsupial animal;  
2, fossil primate;

3, gibbon;  
4, gorilla;  
5, modern man

articulates increases from monkeys to man (from two to five). The sacrum is very highly developed in man because of man's upright posture. The sacrum usually consists of five or even six (in sacralization) vertebrae.

The tail part of the vertebral column varies greatly depending on the length of the tail. It may contain as many as 46 vertebrae in forms with a long tail and three (orangutan) or four (other short-tailed monkeys) vertebrae in species with a reduced tail. Man has four tail vertebrae (the coccyx), although there may be five or only one, and their number is the least as compared to that in all the other animals. As a result the total number of vertebrae in man varies from 30 to 35, but usually there are 33. The ribs

may be located on the entire length of the vertebral column (in snakes), but usually they develop in the thoracic part and are rudimentary and fused with the vertebrae in the other parts.

In most mammals, the ribs articulate with the spine in two places: with the vertebral bodies and with the transverse processes. The ventral ends of the ribs are attached to the sternum which is found only in terrestrial vertebrates because of the development of the shoulder girdle adjoining it; that is why animals who have lost the limbs, e.g. snakes, do not have a sternum. The sternum of higher terrestrial vertebrates develops from the ventral ends of the ribs which during embryonic life (in the second month in humans) join to form paired thoracic plates which fuse on the midline into an unpaired bone.

The skeleton of the human trunk undergoes changes in association with the *upright position of the body*; as a result it differs from the skeleton of other mammals who have four legs. The vertebral column (except for the cervical segment) in these mammals has the shape of a shallow arch resting on all four limbs. As the result of different static conditions, the human spine is a curved vertical column carrying the head at the top and resting on the lower limbs (Fig. 24). The upright posture also has an effect on the configuration of the thoracic cage (see Fig. 41).

Thus, the *skeleton of the human trunk has the following characteristic features* determined by the upright posture and the development of the upper limb as an organ of labour:

- (1) a vertical vertebral column with curvatures, particularly in the sacral region, where an anterior prominence (promontorium) forms;
- (2) gradual increase in the size of the vertebral bodies in the direction from top to bottom where, in the region of their connection with the lower limbs through the pelvic girdle they fuse to form a single bone, the sacrum, consisting of five vertebrae;
- (3) a wide and flat thoracic cage with a predominant transverse dimension and an extremely small anteroposterior dimension.

## THE VERTEBRAL COLUMN

The vertebral column (*columna vertebralis*) or the spine has a metameric structure (a feature connecting the vertebrates with the earliest invertebrates) and consists of separate bone segments, vertebrae, placed one over another in a series; they are short spongy bones.

*Function of the spine.* The spine acts as the axial skeleton supporting the body. It protects the spinal cord enclosed in its canal and takes part in the movements of the trunk and head. The position and shape of the vertebral column are determined by the upright position of man.

*Common features of the vertebrae.* In accordance with the three functions of the spine, each vertebra (*Gk spondylos*<sup>1</sup>) has the following features (Fig. 25):

<sup>1</sup> Hence spondylitis, inflammation of the vertebrae.

(1) an anterior part, which is responsible for support and which thickens in the shape of a short column, this is the **body** (*corpus vertebrae*);

(2) an **arch** (*arcus vertebrae*), which is attached to the posterior surface of the body by two *pedicles* (*pediculi arcus vertebrae*) and contributes to the formation of the **vertebral foramen** (*foramen vertebrale*); a series of these foramina forms the **vertebral, or spinal, canal** (*canalis vertebralis*), which protects the spinal cord lodged in it from external injury. The vertebral arch, therefore, primarily fulfils a protective function;

(3) the arch also carries structures permitting movement of the vertebra called processes. A **spinous process** (*processus spinosus*) arises from the arch on the midline; a **transverse process** (*processus transversus*) projects laterally on each side; paired **superior and inferior articular processes** (*processus articulares superiores* and *inferiores*) project upward and downward. The articular processes bind **notches** on the posterior aspect; these are the paired *incisurae vertebrales superiores* and *inferiores* from which the **intervertebral foramina** (*foramina intervertebralia*) form when one vertebra is placed on another. The foramina transmit the nerves and vessels of the spinal cord. The articular processes serve for the formation of intervertebral joints at which movement of the vertebrae is accomplished; the transverse and the spinous processes serve for the attachment of ligaments and muscles which make the vertebrae move.

Some parts of the vertebrae in the different parts of the spine have a distinctive size and shape and the following vertebrae are consequently distinguished: cervical (seven), thoracic (twelve), lumbar (five), sacral (five), and coccygeal (one to five). The weight-bearing part of the cervical vertebrae (the body) is naturally relatively small (the first cervical vertebra has almost no body), but from the head down, the vertebral bodies gradually increase in size and are largest in the lumbar segment. The sacral vertebrae carry the whole weight of the head, trunk, and upper limbs, connect the

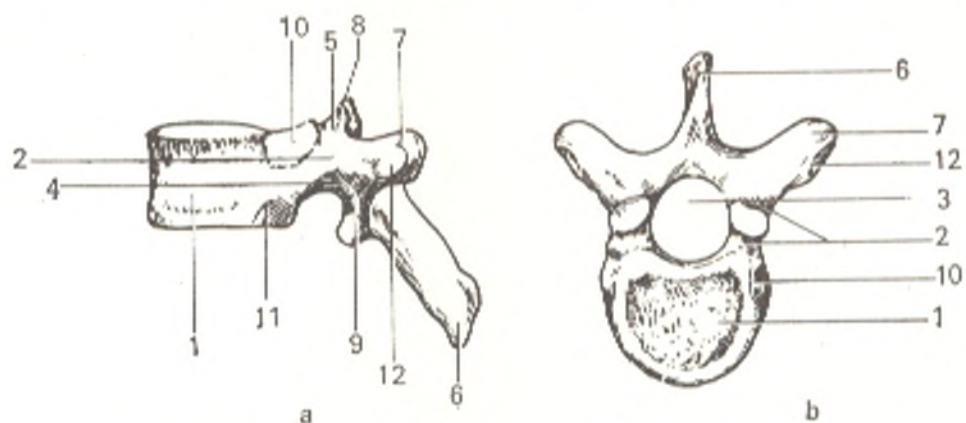


Fig. 25. Thoracic vertebra (*vertebra thoracica*). (Th).

- a, viewed from the side;  
 b, viewed from above.  
 1, corpus vertebrae;  
 2, arcus vertebrae;  
 3, foramen vertebrale;  
 4, incisura vertebralis inf.;  
 5, incisura vertebralis sup.;

- 6, processus spinosus;  
 7, proc. transversus;  
 8, proc. articularis sup.;  
 9, proc. articularis inf.;  
 10, fovea costalis sup.;  
 11, fovea costalis inf.;  
 12, fovea costalis transversalis



skeleton of these parts of the body with the bones of the pelvic girdle, and, through them, fuse with the lower limbs to form a single sacral bone. In contrast, the coccygeal vertebrae, which in man are remnants of a tail, are small bony structures with a body that can hardly be detected and no arch. The vertebral arch, as a protective part, forms a wider vertebral foramen where the spinal cord is thickened (lower cervical, upper thoracic and upper lumbar vertebrae). Since the spinal cord terminates at the level of the second lumbar vertebra, the vertebral foramen of the lower lumbar and the sacral vertebrae gradually narrows and disappears completely in the coccyx. The transverse and spinous processes, the sites of muscle and ligament attachment, are more pronounced in those parts to which the most powerful musculature is attached (lumbar and thoracic segments); on the sacrum these processes are diminished because the tail musculature has disappeared, and they form small crests on the fused sacrum. As a consequence of fusion of the sacral vertebrae, the articular processes disappear; these processes are developed particularly well in the mobile parts of the spine, especially in the lumbar segment. Thus, to understand the structure of the vertebral column, one must bear in mind that the vertebrae and certain vertebral parts develop more in those segments which experience the greatest functional load. Reduction of the corresponding parts of the spine is encountered, in contrast, in segments of which fewer functional demands are made, for instance, in the coccyx which is a rudimentary structure in man.

#### INDIVIDUAL TYPES OF VERTEBRAE

1. **Cervical vertebrae** (*vertebrae cervicales*) (Fig. 26). Since the load suffered by the cervical vertebrae is lighter than that suffered by the more distally located spinal segments, their bodies are correspondingly smaller. The bodies are transverse-oval in shape, and the upper and lower surfaces are concave. Each transverse process is characterized by the presence of a hole (*foramen transversarium*), which forms as a result of fusion of the transverse process with the rib rudiment (*processus costarius*). The canal which forms from a series of these foramina protects the vertebral artery and the vein that it transmits. This fusion is manifested on the ends of the transverse processes as two *tubercles* (*tuberculum anterius* and *posterius*). The anterior tubercle of the sixth vertebra is enlarged and is called the *carotid tubercle* (*tuberculum caroticum*) (the carotid artery can be compressed against it to arrest bleeding). The spinous process is bifid, with the exception of that of the sixth and seventh vertebrae. The seventh cervical vertebra is distinguished by a large spinous process, and for that reason it is called the **vertebra prominens**. This vertebra is easily located in a living person and is often helpful in making diagnosis (Fig. 27).

The first and second cervical vertebrae have a specific shape because they form the mobile articulation with the skull. Most of the body of the first vertebra, the *atlas*<sup>1</sup>, remains separate and joins the second vertebra as a

<sup>1</sup> It supports the skull as the mythical giant Atlas supported the heavens on his shoulders.

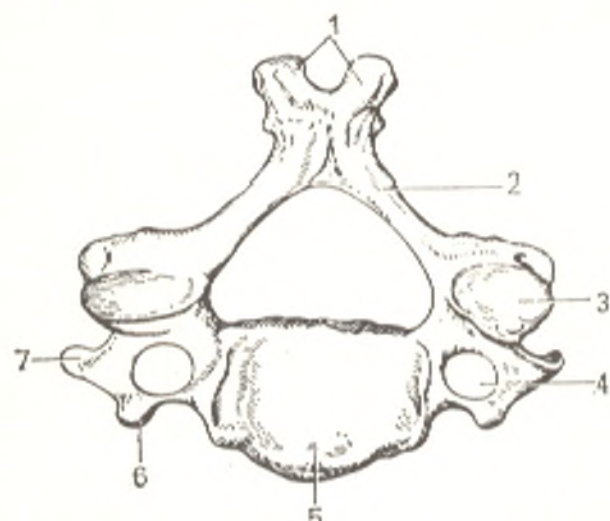


Fig. 26. Fourth cervical vertebra (vertebra cervicalis IV) (C), viewed from above.

- 1, processus spinosus;
- 2, arcus vertebrae;
- 3, processus articularis superior;
- 4, foramen transversarium;
- 5, corpus vertebrae;
- 6 and 7, tuberculum anterius et posterius of the transverse process

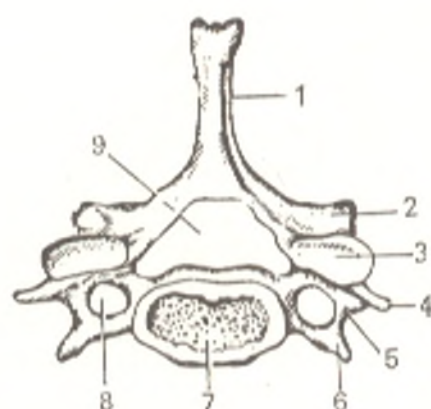


Fig. 27. Seventh cervical vertebra (vertebra cervicalis VII), viewed from above.

- 1, processus spinosus;
- 2, processus articularis inferior;
- 3, facies articularis superior;
- 4, tuberculum posterius;
- 5, processus transversus;
- 6, tuberculum anterius;
- 7, corpus vertebrae;
- 8, foramen transversarium;
- 9, foramen vertebrale

tooth-like process, the *dens*. As a result only the anterior arch is left; to make up for this, the vertebral foramen that receives the dens is larger. The **anterior** (*arcus anterior*) and **posterior** (*arcus posterior*) **arches** of the atlas are connected to each other by **lateral masses** (*massae laterales*). The superior and inferior surfaces of each arch articulate with the adjoining bones: the convex **superior articular facet** (*fovea articularis superior*) receives the corresponding condyle of the occipital bone; the flattened **inferior articular facet** (*fovea articularis inferior*) receives the articular surface of the second cervical vertebra.

The outer surfaces of the anterior and posterior arches carry *tubercles* (*tuberculum anterius* and *posterius*) (Fig. 28).

The second cervical vertebra, the **axis** (consequently the axial vertebra) s. *epistropheus* (BNA) (Gk *epistrephomai* pivot, consequently the pivotal vertebra) differs sharply from all the other vertebrae by the presence of the tooth-like process, the **dens** (Fig. 29). The dens has articular surfaces, which on the anterior aspect serve to articulate with the anterior arch of the atlas and on the posterior aspect to attach the transverse ligament. Another distinction of the axis is that its superior articular surfaces articulating with the atlas are not on the arch but on the superior surface of the body to the sides of the dens.

2. **Thoracic vertebrae** (*vertebrae thoracicae*) (Fig. 30) articulate with the ribs. Their distinctive feature, consequently, is the presence of articular facets for the ribs, **costal facets** (*fovea costales*), on the body of each vertebra close to the base of the arch. Since the ribs usually articulate with two adjoin-

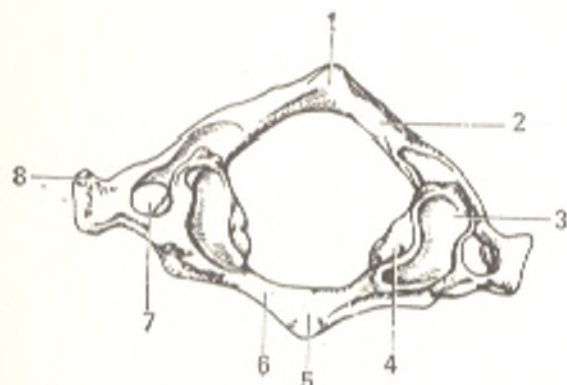


Fig. 28. Atlas, viewed from above.

- 1, tuberculum posterius;
- 2, arcus posterius;
- 3, fovea articularis sup.;
- 4, massa lateralis;
- 5, tuberculum anterius;
- 6, arcus anterior;
- 7, foramen transversarium;
- 8, processus transversus

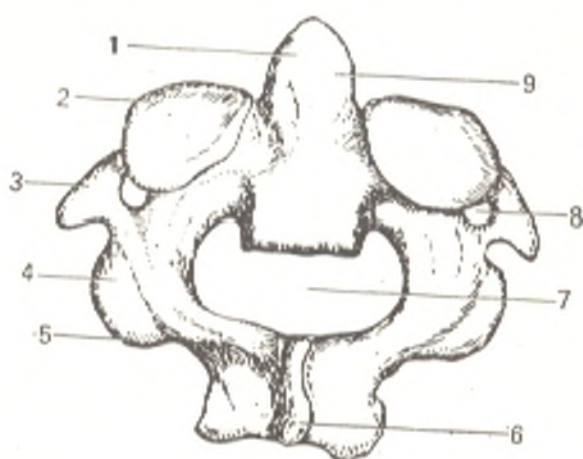


Fig. 29. Axis (epistrophus), viewed from above and from the back.

- 1, dens axis;
- 2, facies articularis sup.;
- 3, processus transversus;
- 4, processus articularis inf.;
- 5, arcus vertebrae;
- 6, processus spinosus;
- 7, foramen vertebrale;
- 8, foramen transversarium;
- 9, facies articularis posterior dentis

ing vertebrae, most vertebral bodies have two incomplete (half) costal facets: one on the superior edge of the vertebra (*fovea costalis superior*) and the other on the inferior surface (*fovea costalis inferior*). When one vertebra is placed on the other, the two half-facets form a single whole articular facet, which receives the head of the rib. The first thoracic vertebra is an exception: it has a complete articular facet on the superior edge for the first rib and a half-facet on the inferior edge for the second rib. The tenth vertebra has only one half-facet for the tenth rib, whereas the eleventh and twelfth ribs each have a complete facet for articulating with the corresponding ribs. These vertebrae (first, tenth, eleventh, and twelfth) can, therefore, easily be distinguished from the others. In accordance with the greater weight they bear, the bodies of the thoracic vertebrae are larger than the bodies of the cervical vertebrae. The articular processes are positioned frontally. The transverse processes are directed laterally and to the back. They have a small articular surface, *transverse costal facet (fovea costalis processus transversus)* for articulating with the tubercle of the ribs. The transverse processes of the last two vertebrae (eleventh and twelfth) lack these facets. The spinous processes of the thoracic vertebrae are long and are inclined sharply downward, as a result of which they overlies one another like tiles, mainly in the middle of the thoracic part of the spine. Such direction of the processes limits extension of the spine here, which is a protective accommodation for the heart.

3. **Lumbar vertebrae** (*vertebrae lumbales*) are distinguished by a massive body since they carry weight that is still greater than that borne by the part of the spine proximal to them (see Fig. 30). The spinous processes are

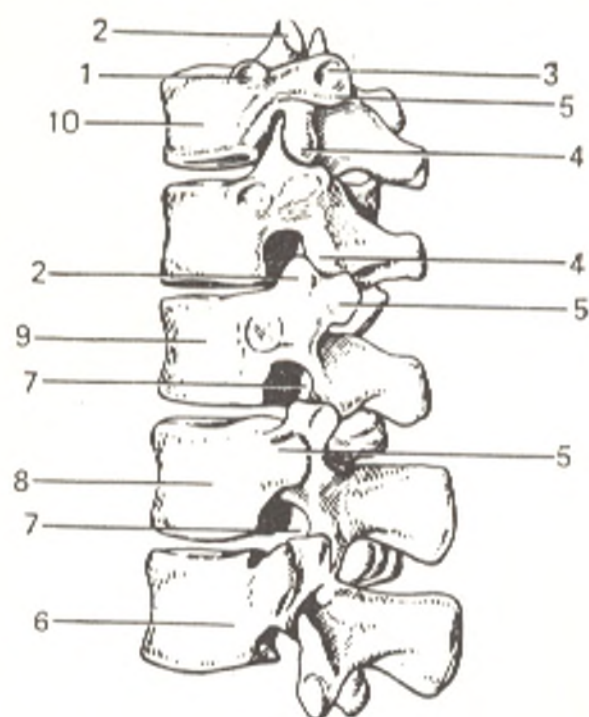


Fig. 30. 10th, 11th, and 12th thoracic and 1st and 2nd lumbar vertebrae.

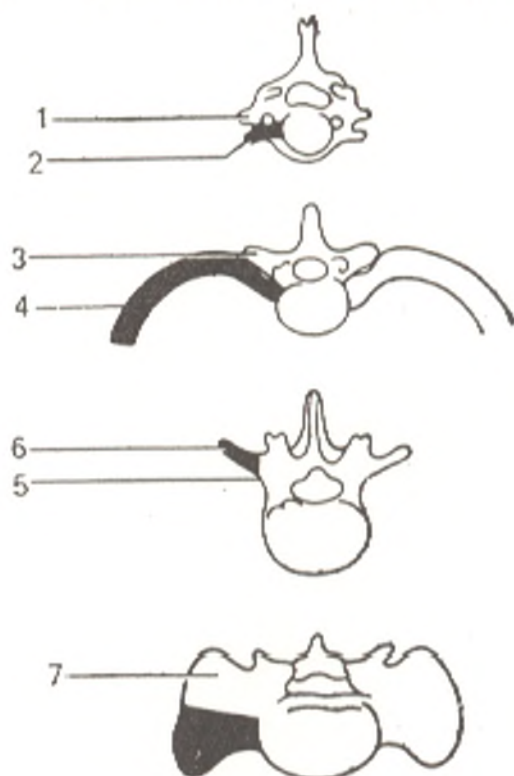
- 1, fovea costalis superior of the 10th vertebra (for the 10th rib);
- 2, processus articularis sup.;
- 3, fovea costalis transversalis;
- 4, processus articularis inf.;
- 5, processus transversus;
- 6, vertebra lumbalis II;
- 7, foramen intervertebrale;
- 8, vertebra lumbalis I;
- 9, vertebra thoracica XII;
- 10, vertebra thoracica X

directed horizontally, to the back. The articular processes are in the sagittal plane. The main part of the transverse process is a rudimentary rib fused completely with a true transverse process, and a small part is preserved as a small process on the posterior aspects of its root and erroneously called the *accessory process* (*processus accessorius*) (Fig. 31).

4. **Sacral vertebrae** (*vertebrae sacrales*) fuse in youth to form a single bone, the sacrum (Fig. 32). This fusion is an adaptation to the considerable

Fig. 31. Diagram of the development of a rib (shaded) and its relation to the transverse processes of four groups of vertebrae: cervical, thoracic, lumbar, and sacral.

- 1, processus transversus;
- 2, processus costarius (cervical vertebra);
- 3, processus transversus (thoracic vertebra);
- 4, costa;
- 5, processus transversus;
- 6, processus costarius (lumbar vertebra);
- 7, processus transversus (sacral vertebra)



load carried by the sacrum because of the upright posture of the human. The sacrum is triangular in shape, and its **base** (*basis ossis sacri*) faces upward, while the **apex** (*apex ossis sacri*) faces downward. The anterior border of the base together with the body of the last lumbar vertebra forms an angle projecting forward, a *prominence* (*promontorium*). The ventral or *pelvic surface* of the sacrum (*facies pelvina*) is concave. The sites of the fusion of the vertebral bodies are seen on it as *transverse lines* (*lineae transversae*) with the *anterior sacral foramina* (*foramina sacralia pelvina*) at their ends. On the dorsal surface there are, correspondingly, the *posterior sacral foramina* (*foramina sacralia dorsalia*). Five crests formed by fusion of different parts of the vertebrae stretch lengthwise on the dorsal surface: an unpaired *spinous tubercles of the sacrum* on the median line (*crista sacralis mediana*) formed as the result of fusion of the spinous processes; the *articular tubercles of the sacrum* (*cristae sacrales intermediae*) (from fusion of the articular processes); and, lateral to these, the *transverse tubercles of the sacrum* (*cristae sacrales laterales*) (sites of fusion of the transverse processes). Lateral to the sacral foramina are the *lateral parts of the sacrum* (*partes laterales*) formed by fusion of the transverse processes and the sacral ribs. They have on their lateral aspect an articular surface curved like the auricle, which is called the *auricular surface* (*facies auriculares*). It serves for joining with the iliac bone. At the back of each auricular surface is the *sacral tuberosity* (*tuberositas sacralis*) (the site of attachment of muscles and ligaments). The *sacral canal* (*canalis sacralis*) passes in the sacrum. It is a continuation of the vertebral canal. As a consequence

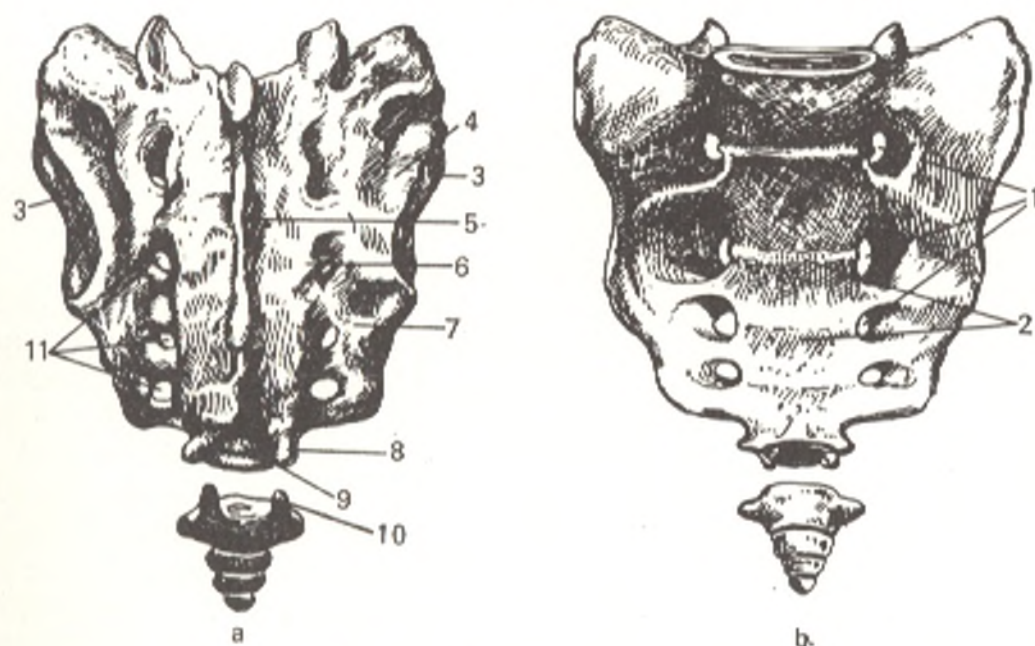


Fig. 32. Sacrum and coccyx.

a, posterior aspect;  
 b, anterior aspect;  
 1, foramina sacralia pelvina;  
 2, lineae transversae;  
 3, facies auricularis;  
 4, tuberositas sacralis;  
 5, crista sacralis mediana;

6, crista sacralis intermedia;  
 7, crista sacralis lateralis;  
 8, cornu sacrale;  
 9, hiatus sacralis;  
 10, cornu coccygeum;  
 11, foramina sacralia dorsalia

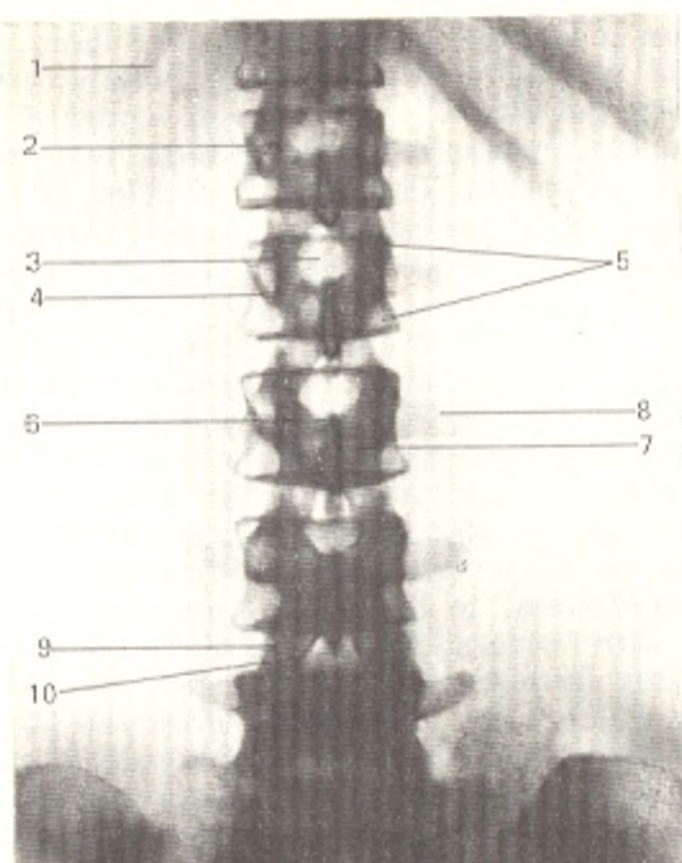


Fig. 33. Radiograph of the lumbar vertebral column in a 32-year-old male (anteroposterior view).

- 1, twelfth rib;
- 2, first lumbar vertebra;
- 3, vertebral body;
- 4, vertebral 'waist';
- 5, vertebral 'angles';
- 6, arch;
- 7, spinous process;
- 8, transverse process;
- 9, superior articular process;
- 10, inferior articular process

of the disappearance of the tail and reduction of the tail musculature in man, the corresponding parts of the sacral vertebrae are reduced. Therefore, the sacral canal is not closed in its distal part but opens as the *sacral hiatus* (*hiatus sacralis*). Lateral to this hiatus are the *sacral cornua* (*cornua sacralia*), remnants of the last sacral vertebra, which articulate with similar cornua of the coccyx.

5. *Coccygeal vertebrae* (*vertebrae coccygeae* s. *caudales*) are remnants of the tail and rudimentary structures fusing at middle age to form a single bone, the *coccyx* (*os coccygis*). The first coccygeal vertebra is larger than the rest and has on the dorsal surface two processes (*cornua coccygea*), which are directed upward to meet the sacral cornua (see Fig. 32).

The X-ray image of an adult vertebral column. The vertebral body, *corpus vertebrae*, of an adult (Figs. 33 and 35) is quadrangular on a radiograph. The angles of the body represent a conventional, purely radiological concept associated with the projection of a cylindrical body on the surface of the radiograph; the apices of the angles are rounded. The outlines of the body are clear and even. Lack of an increase in the height of the body from vertebra to vertebra in the caudal direction is a pathological phenomenon. The bodies of the lumbar vertebrae resemble a "reel" with a narrow "waist" (see Fig. 33). The *pedicle of the arch* (*pediculus arcus*) is demonstrated on an anteroposterior radiograph as a circular or oval contrast shadow superimposed on the shadow of the body. The arch in this case is projected as if in a transverse section.

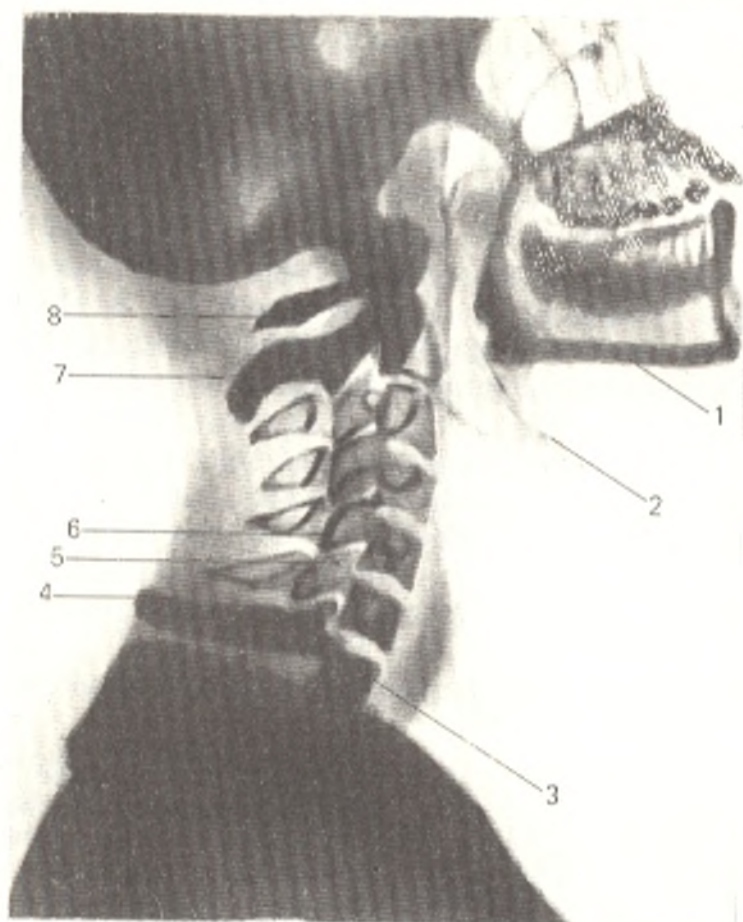


Fig. 34. Radiograph of the cervical vertebral column (lateral view).

- 1, lower jaw;
- 2, hyoid bone;
- 3, body of seventh cervical vertebra;
- 4, spinous process of seventh cervical vertebra;
- 5, superior articular process of sixth vertebra;
- 6, inferior articular process of fifth cervical vertebra;
- 7, spinous process of second cervical vertebra;
- 8, posterior arch and posterior tubercle of first cervical vertebra

On lateral radiographs of the vertebral column (Fig. 34), the arch is clearly seen in all detail. Both arches of the atlas with the posterior and anterior tubercles are demonstrated; the anterior tubercle is the guiding point in counting the vertebrae on the radiograph.

The articular processes (*processus articulares superiores* and *inferiores*) are not adequately demonstrated in different spinal segments. Clarity depends on the position of the articular surfaces. An "X-ray joint cavity" can be seen between them, which differs from the anatomical joint cavity. The latter is the space between the surfaces of the articular cartilage which covers the bone, while the "X-ray joint cavity" is the space between the articular surfaces of the bone, including the cartilaginous tissue which is permeable to X-rays and which produces no image on the radiograph.

The transverse processes (*processus transversus*) are located in the front plane and are demonstrated clearly on anteroposterior radiographs (Figs. 33 and 35). A rudiment of the true transverse processes (*processus accessorius*) is seen at the root of the transverse processes of the lumbar vertebrae. When long (4 mm), it resembles a style (*processus styloideus*). It should not be mistaken for a pathological structure.

The spinous processes, *processus spinosi*, lying in the sagittal plane, are demonstrated best on lateral radiographs.

*The sacrum and coccyx.* The characteristic feature of the sacrum is fusion of the vertebrae to form a single bone. An anteroposterior radiograph

shows a clear image of the whole sacrum and coccyx with all the details described in osteology.

**Ossification.** Radiographs made in the last months of pregnancy make it possible to judge the position of the foetus in the womb and the condition of its bone system, the vertebral column in particular. Ossification nuclei are seen in all vertebrae, with the exception of the coccygeal (except for the first), on a radiograph made on the eve of birth. Each vertebra has three main nuclei, one in the body and two in the arch (one in each of its halves). These nuclei merge only in childhood, and translucencies are consequently seen between them on radiographs of the vertebral column of a newborn infant.

If the mentioned parts of the vertebra do not form a synostosis with each other, clefts may remain in the vertebra for life. On a radiograph they appear as translucencies between the arch and body (*spina bifida lateralis*) (*L bis* two, *findere* to cleave) and between both halves of the arch (*spina bifida posterior*). This developmental anomaly may lead to disorders of spinal statics and dynamics and is therefore of practical importance. *Spina bifida posterior* of the fifth lumbar and sacral vertebrae, however, is encountered as

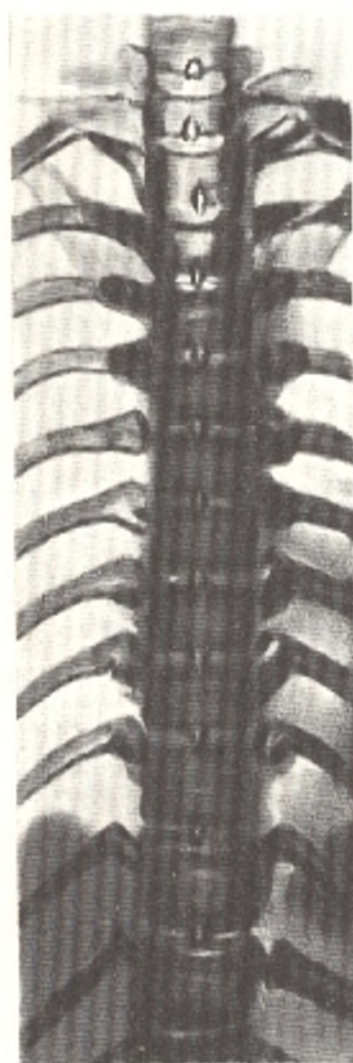

Fig. 35. X-ray picture of the thoracic vertebral column of a 20-year-old male (anteroposterior view)



a rule in children between the ages of 8 and 10. Approximately 25 per cent of all healthy individuals experience a form of spina bifida posterior that does not result in functional disorders or impair participation in sports. Such *spina bifida posterior occulta* (latent) is therefore interpreted not as an anomaly but as a phylogenetically determined (reduction of the tail) variant of the norm.

The vertebral body of a *newborn* has an egg-like shape on the radiograph without the "angles" characteristic of the X-ray picture of the adult vertebra, which lend the body a quadrangular shape. In the lateral view, a depression seen on the anterior surfaces of the vertebral body is produced by incomplete merging of two bony nuclei of the body and the presence here of the remnants of embryonic veins, *venae basivertebrales*. These depressions are particularly pronounced in the first years of life, but may also be encountered until the age of 14. They should not be mistaken for a picture of bone destruction resulting from a pathological process.

In the *period of growth and maturation*, X-rays demonstrate the following morphological changes.

I. Synostosis of the arch and body in the third year of life and synostosis of both halves of the arch.

II. Development and synostosis of the apophysis of the vertebral body. This term applies to smooth ring-like bands of bone substance which border the superior and inferior surfaces of the body and thus limit the rough centre of these surfaces. These annular bands are also called an edging, *limbus vertebrae*. The anulus fibrosus of the intervertebral disc (see section "Joints Between Vertebral Bodies") adjoins it, while the nucleus pulposus comes in contact with the hyaline lamella filling the rough central part of the surface of the vertebral body.

The *limbus vertebrae* ossifies at the expense of independent ossification nuclei which appear at 6-8 years of age in girls and between the ages of 7 and 9 in boys and undergo synostosis with the vertebral body at 23 to 26 years of age. Therefore, the following patterns of the development of *limbus vertebrae* can be encountered in childhood and in youth. At first they appear as triangular structures at the site of the future "angles" of the body. Later, with the gradual merging of the separate ossification points, two thin bands of bone substance are noticed on the superior and inferior surfaces of the vertebral body. These bands are thickened at the ends and separated from the body by a narrow band of translucency at the site of the cartilaginous tissue. After synostosis with the body occurs, both bony bands merge with it. Knowledge of these features will prevent an erroneous diagnosis of a fracture.

III. Fusion of the sacral vertebrae (17-25 years of age).

IV. Disappearance of the depression on the anterior surface of the bodies.

V. Appearance of accessory ossification points on the processes.

After synostosis between all the elements of the vertebra is completed (23-26 years of age), the vertebra acquires the shape typical of an adult.

The X-ray image of ageing of the vertebral column. The X-ray picture of the vertebral column at old age is characterized by the following features.

1. Generalized rarefaction of the spinal bony substance, osteoporosis. Relative translucency of the bone tissue is noted on the radiograph.

2. Calcification of the intervertebral disc.

3. Calcification of the anterior longitudinal ligament at the attachment of the limbus vertebrae as a result of which bony projections, osteophytes, are seen on the superior and inferior edges of the body; due to these osteophytes the rounded apices of the X-ray "angles" of the vertebral bodies change to acute.

Thus, the vertebral body undergoes considerable changes in the process of ontogenesis: in the intrauterine period it contains an ossification point; in the newborn it is shaped like an egg and has no "angles"; in childhood apophyses in the form of three-edged structures appear at the sites of the future "angles"; in an adult the body becomes quadrangular with rounded "angles" as the result of synostosis between the apophysis and diaphysis; at old age these "angles" are tapered. Consequently the age changes in the vertebral column can be judged from the shape of the body and its "angles" on the X-ray picture.

**Variants in the number of vertebrae.** Variations of the number of vertebrae are often found on the radiographs of healthy individuals (see p. 129): lumbarization occurs in 4 per cent and various forms of sacralization (partial, complete, unilateral, bilateral) in 7 per cent of females and 15 per cent of males. The tendency to sacralization is encountered in up to 50 per cent of the population.

#### JOINTS BETWEEN THE VERTEBRAE

The joints between the vertebrae in man reflect the course of their phylogenesis. As mentioned above, initially (in the chordata) the axial skeleton had the character of a notochord, the remnants of which persist in man as the nucleus pulposus. The vertebral column which replaced the notochord acquired a segmental structure preserved in man in the form of a series of bone segments, the vertebrae. That is why joints developed between the vertebrae. At first these joints were contiguous, i.e. they were synarthroses which, according to the three stages of the development of the skeleton in general and vertebral column in particular, initially had the character of syndesmosis. Synchrondroses then occurred along with syndesmoses, and, finally, synostoses developed (in the sacral region). With the gradual change to terrestrial life and improvement of the mode of movement, interrupted joints, diarthroses, also developed between the vertebrae. In some mammals they formed between the vertebral bodies and between the arches by means of special articular processes.

Since anthropoids showed a tendency to walk upright, greater stability of the vertebral column was necessary. Therefore, the joints between the vertebral bodies again started to acquire a contiguous character, although the process was not complete, and half-joints, hemiarthroses, formed in some parts. As a result of such development, the human vertebral column has all types of joints: syndesmoses (ligaments between the transverse and spinous

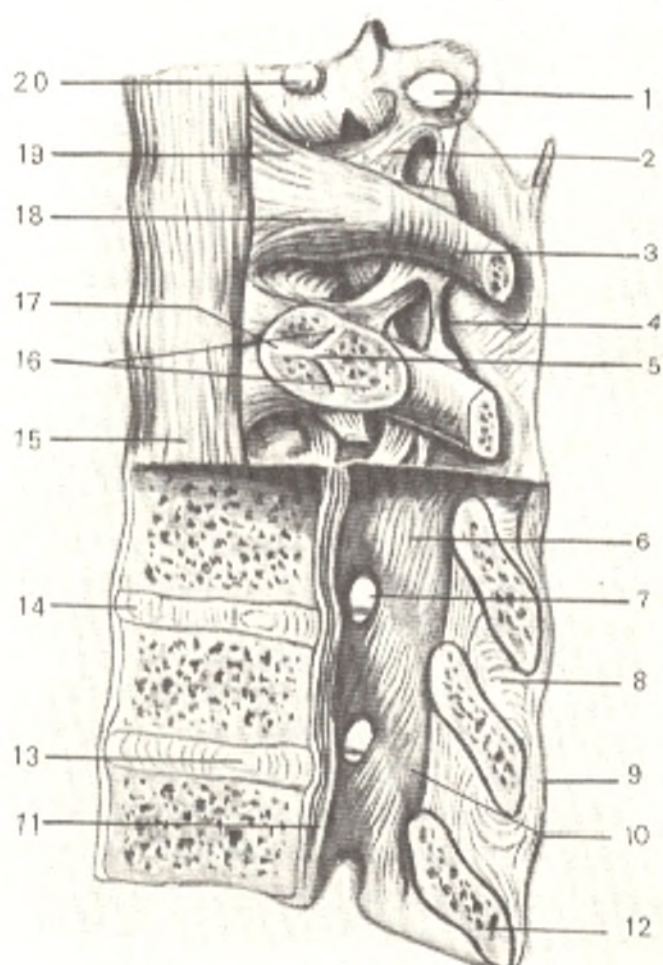
processes), synelastoses (ligaments between the arches), synchondroses (between the bodies of a series of vertebrae), synostoses (between the sacral vertebrae), hemiarthroses (between the bodies of a series of vertebrae) and diarthroses (between the articular processes). All these articulations are segmental in structure in accordance with the metameric development of the spine. Since the separate vertebrae formed a single vertebral column, longitudinal ligaments formed, which stretched along the entire spine and reinforced it as a single structure. As a result all the articulations between vertebrae may be divided according to the two main parts of the spine into articulations between the bodies and articulations between their arches.

#### JOINTS BETWEEN THE VERTEBRAL BODIES

The vertebral bodies forming the vertebral column proper which supports the trunk unite one with another (and also with the sacrum) by means of synchondroses called **intervertebral cartilages** or **discs** (*disci intervertebrales*) or by means of hemiarthroses if there are clefts between them. Each disc is a fibrocartilaginous plate whose periphery is formed of concentric layers of connective-tissue fibres. These fibres form a very strong peripheral *fibrous ring* (*anulus fibrosus*), while the central part of the plate is a *ge-*

Fig. 36. Thoracic segment of vertebral column, left side (sagittal section through the lower part).

- 1, facies costalis transversalis;
- 2, lig. costotransversarium;
- 3, eighth rib;
- 4, lig. intertransversarium;
- 5, crista capitis costae;
- 6, lig. flavum;
- 7, foramen intervertebrale;
- 8, lig. interspinale;
- 9, lig. supraspinale;
- 10, arcus vertebrae;
- 11, lig. longitudinale posterius;
- 12, proc. spinosus;
- 13, nucleus pulposus;
- 14, discus intervertebralis;
- 15, lig. longitudinale anterius;
- 16, art. capitis costae;
- 17, lig. capitis costae intraarticulare;
- 18, art. capitis costae;
- 19, lig. capitis costae radiatum;
- 20, fovea costalis



*Latinous nucleus (nucleus pulposus)* consisting of soft fibrous cartilage (remnant of the notochord). This nucleus is under considerable pressure and continuously tends to distend (on cross-section of the disc it protrudes markedly above the level of the section) and is therefore resilient and acts as a buffer.

The intervertebral discs correspond to the vertebral bodies in shape but are somewhat wider and protrude consequently over the edges of the vertebral bodies as swellings. The discs are thickest where mobility is greatest, i.e. in the lumbar region, and least thick between the thoracic vertebrae.

The column of vertebral bodies united by the intervertebral discs is re-enforced by two longitudinal ligaments running in front and back on the median line. The **anterior longitudinal ligament** (*lig. longitudinale anterius*) stretches on the anterior surface of the vertebral bodies and discs from the tubercle on the anterior arch of the atlas to the upper part of the pelvic surface of the atlas where it is lost in the periosteum. This ligament prevents abnormal backward extension of the spine. The **posterior longitudinal ligament** (*lig. longitudinale posterius*) extends from the second cervical vertebra downward on the posterior surface of the vertebral bodies in the vertebral canal to the upper end of the canalis sacralis. It hinders flexion and is a functional antagonist of the anterior longitudinal ligament (see Fig. 36).

#### JOINTS BETWEEN THE VERTEBRAL ARCHES

The arches are united by joints and ligaments located both between the arches themselves and between their processes (Fig. 36).

1. Union between the articular processes is accomplished by the **intervertebral joints** (*articulationes intervertebrales*). Since these are flat, tight joints, which are limited in movement, they limit flexibility of the spine and give it a definite direction in conformity with the position of the articular surfaces in the different parts of the spine (multiaxial joints).

2. The spaces between the arches are filled by elastic fibres of yellow colour which are, therefore, called **yellow ligaments** (*ligamenta flava*). Because of their elasticity they tend to bring the arches closer to each other and, together with the resilience of the intervertebral cartilages, contribute to a straight spine and upright position.

3. The ligaments between the spinous processes, the **interspinous ligaments** (*ligamenta interspinalia*), are developed most markedly in the lumbar region. A roundish band continuous with the interspinous ligaments in the back stretches over the apices of the spinous processes as a long **supraspinous ligament** (*lig. supraspinale*). In the cervical part of the spine the interspinous ligaments stretch beyond the apices of the spinous processes and form the sagittal **nuchal ligament** (*lig. nuchae*). It is triangular. One of its sides is attached to the spinous processes, another to the external occipital crest, while the third, free side stretches from the seventh cervical vertebra to the external occipital protuberance. The nuchal ligament is most conspicuous in quadrupeds, especially in cattle, and helps to support the head. In man, who walks upright, it is less pronounced; together with the in-

terspinous and supraspinous ligaments it hinders excessive forward flexion of the spine and head.

4. Ligaments between the transverse processes, the intertransverse ligaments (*ligamenta intertransversaria*), limit lateral movements of the spine to the contralateral side.

#### JOINTS BETWEEN THE SACRUM AND COCCYX

The joints between the sacrum and coccyx are similar to those between the vertebrae described above but are less pronounced because the coccygeal vertebrae are rudimentary. The body of the fifth sacral vertebra unites with the coccyx by means of the intervertebral cartilage; the cartilage has a small cavity in it which allows the coccyx to bend backward during childbirth. The anterior sacrococcygeal ligament (*lig. sacrococcygeum ventrale*) passes on the anterior surface of the coccyx and is continuous with the anterior longitudinal ligament. The deep posterior sacrococcygeal ligament (*lig. sacrococcygeum dorsale profundum*) similar to the posterior longitudinal ligament of the spine, lies deeper on the posterior surface; the superficial posterior sacrococcygeal ligament (*lig. sacrococcygeum dorsalis superficiale*) is closer to the surface and corresponds to the yellow ligaments and the capsules of the intervertebral joints. The lateral sacrococcygeal ligaments (*ligamenta sacrococcygea lateralia*) are homologous with the intertransverse ligaments (*ligamenta intertransversaria*) and are therefore attached to the transverse processes of the coccyx; together with the grooves at the apex of the sacrum they form the fifth sacral foramina.

The intervertebral joints are supplied with nutrients by the branches of a. vertebralis (in the cervical part), aa. intercostales posterior (in the thoracic part), aa. lumbales (in the lumbar part), and a. sacralis lateralis (in the sacral part). Venous blood drains into the plexus venosi vertebrales and from there into v. vertebralis (in the cervical segment), vv. intercostales posteriores (in the thoracic segment), vv. lumbales (in the lumbar segment), and v. iliaca interna (in the sacral segment). Lymph drains into nodi lymphatici occipitales, retroauriculares, cervicales profundi (in the cervical segment), nodi lymphatici intercostales (in the thoracic segment), nodi lymphatici lumbales (in the lumbar segment), and nodi lymphatici sacrales (in the sacral segment).

Innervation is effected by the posterior branches of the spinal nerves of the corresponding level.<sup>1</sup>

#### THE UNION OF THE VERTEBRAL COLUMN WITH THE SKULL

The vertebral column is joined to the skull by a combination of several joints permitting movement on three axes as in a ball-and-socket joint.

1. The atlanto-occipital joint (*art. atlantooccipitalis*) is a condyloid joint; it is formed by two condyles of the occipital bone, spondyli occipitales, and the concave articular surfaces (facets) of the atlas, fovea articularis superiores atlantis. Both pairs of the articulating surfaces are enclosed in separate articular capsules but move simultaneously, forming a single combined joint. There are the following auxiliary ligaments: (1) the anterior atlanto-occipital membrane (*membrana atlantooccipitalis ante-*

<sup>1</sup> Some of the information on the vessels and nerves of some of the organs is taken from V. N. Tonkov's textbook.

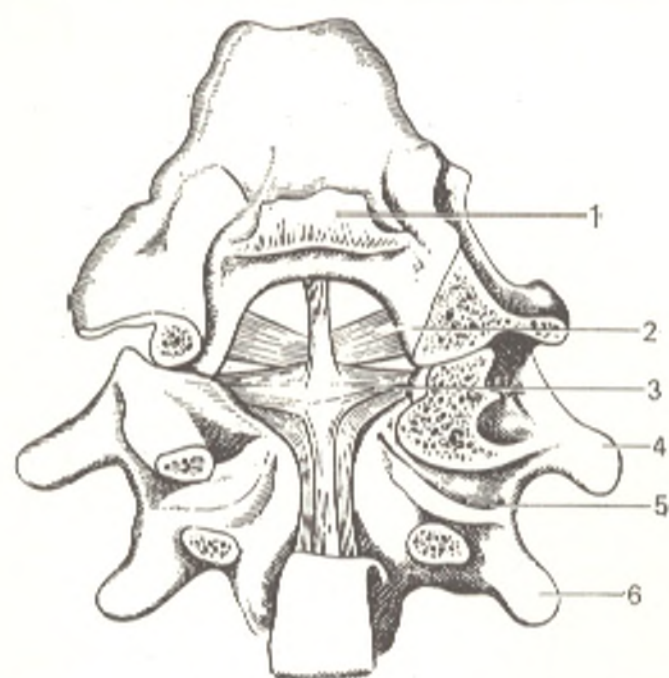


Fig. 37. Joints of the superior cervical vertebrae (posterior aspect).

- 1, upper end of divided membrana tectoria;  
 2, lig. alare;  
 3, lig. cruciforme;  
 4, atlas;  
 5, lateral articulation of atlas with axis;  
 6, axis

rior) stretched between the anterior arch of the atlas and the occipital bone; (2) the posterior atlanto-occipital membrane (*membrana atlantooccipitalis posterior*) located between the posterior arch of the atlas and the posterior margin of the foramen magnum. The atlanto-occipital joint allows movement on two axes, the frontal and the sagittal. Nodding, i.e. bending the head backward and forward in a sign of assent, takes place on the frontal axis. Lateral bending of the head to the right and left, i.e. abduction and adduction, occurs on the sagittal axis. The anterior end of this axis stands somewhat higher than the posterior end. As a result of this oblique position of the axis, the head usually turns slightly to the contralateral side when it flexes laterally.

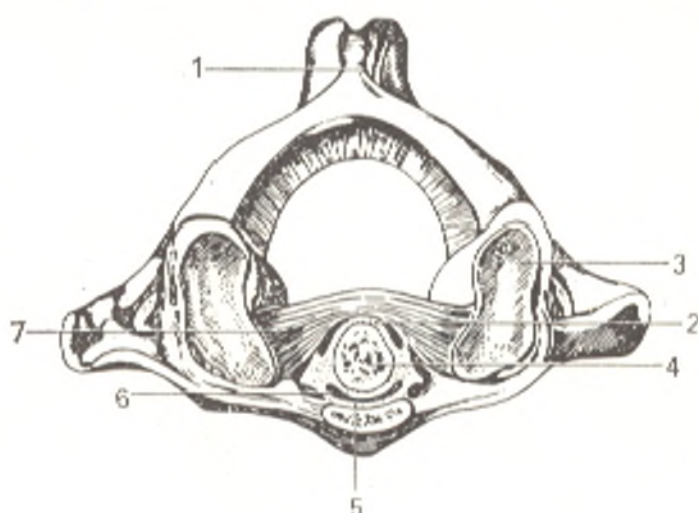
2. The atlas and the axial vertebra unite (Fig. 37) by means of three joints. Two lateral atlanto-axial joints (*articulationes atlantoaxiales laterales*) are formed by the inferior articular surfaces of the atlas and the similar superior surfaces of the axis contiguous to them, thus making up a combined joint. The odontoid process (*dens axis*) located in the middle is joined with the anterior arch of the atlas and the transverse ligament of the atlas (*lig. transversum atlantis*) stretched between the inner surfaces of the lateral masses of the atlas.

The transverse ligament is fibrocartilaginous at its articulation with the dens. The dens is therefore enclosed in a osteofibrous ring formed by the anterior arch of the atlas and the transverse ligament, as a result of which a trochoid joint forms, the median atlanto-axial joint (*art. atlantoaxialis mediana*) (Fig. 38) (type two pivotal joint, Davies, 1961).

Two fibrous bands which had separated from the posterior longitudinal ligament of the spine arise from the superior and inferior edges of the transverse ligament: one stretches upward to the anterior edge of the foramen magnum, the other passes downward to the posterior surface of the axial body. Together with the transverse ligament these two bands

Fig. 38. Articulation between the first cervical vertebra and the dens of the second vertebra; horizontal section (viewed from above).

- 1, tuberculum posterius;
- 2, facies articularis posterior dentis;
- 3, fovea articularis superior atlantis;
- 4, dens axis;
- 5, articular surface of the arch of the atlas;
- 6, facies articularis anterior dentis;
- 7, lig. transversum atlantis



form the **cruciform ligament of the axis** (*lig. cruciforme atlantis*). This ligament is very important functionally: as noted above, it is, on the one hand, an articular surface for the dens and directs its movements, and, on the other, it prevents dislocation of the dens, which might injure the spinal cord or the medulla oblongata, located close to the foramen magnum, a condition that is fatal. An accessory ligament of the joints described is the **apical ligament of the odontoid process** (*lig. apicis dentis*) extending from the tip of the dens to the anterior edge of the foramen magnum. Two strong ligaments, **alar ligaments of the odontoid process** (*ligamenta alaria*) pass from the lateral surfaces of the dens and are attached to the medial surfaces of the condyles of the occipital bone. The whole apparatus of ligaments described is covered posteriorly from the aspect of the vertebral canal by the **membrana tectoria** stretching from the clivus of the sphenoid bone and anterior edge of the foramen magnum to the body of the second cervical vertebra (it is continuous with the posterior longitudinal ligament of the spine).

The atlanto-axial joints permit only a *single type of movement*, rotation of the head on the vertical axis (turning right and left, an expression of disagreement) passing through the dens of the axial vertebra; the head moves about the dens together with the atlas (trochoid joint). Movements occur at the same time at the lateral atlanto-axial joints. During rotation, the tip of the dens is held in place by the above-mentioned ligamenta alaria, which regulate movement and, in this manner, protect the neighbouring spinal cord from jarring. The joints between the skull and the two cervical vertebrae permit only slight movements. A wider range of movements of the head is usually produced with the participation of the whole cervical part of the spine. The craniovertebral joints are most highly developed in man because of his upright posture and the erect position of the head.

## THE VERTEBRAL COLUMN AS A WHOLE

The vertebral column grows gradually thicker from the skull to the first sacral vertebra and then diminishes rapidly and ends at the tip of the coccyx. Such rapid narrowing of the lower part of the vertebral column is

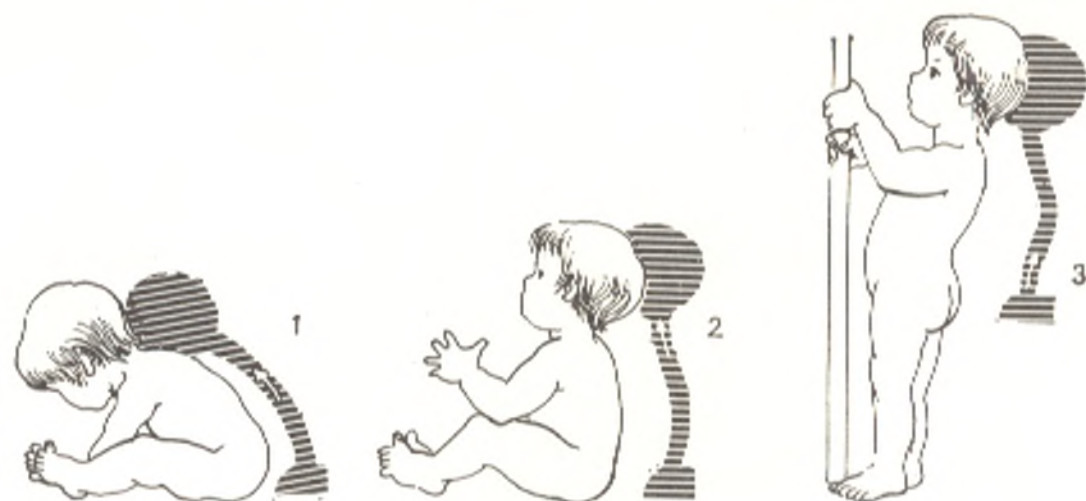

Fig. 39. Gradual formation of spinal curvatures in a child as the result of sitting (1), holding the head raised (2); and standing (3)

caused by reduction of the tail and freeing of the spine from the weight of the limbs.

Although the spine is a vertical column, it is not straight but *curved* in the sagittal plane. The curvatures in the thoracic and sacral parts are posteriorly convex, while those in the cervical and lumbar segments are anteriorly convex. A curvature posteriorly convex is called **kyphosis**; an anteriorly convex curvature is called **lordosis**. The spine of a newborn is almost straight and the curvatures are hardly formed (Fig. 39). When the infant begins to raise his head, a curvature forms in the neck, and the head, whose greatest part is held to the front of the spine, tends to bend down. To hold the head raised, the spine curves forward; the child's repeated attempts to raise the head and hold it in that position by contraction of the posterior muscles of the head facilitate the formation of the curvature. As a result a cervical lordosis forms. Then, when a sitting posture is adopted, the thoracic kyphosis increases, and later, when the child learns to stand and walk, the main curvature, the lumbar lordosis, forms. With the formation of the lumbar lordosis, the pelvis, to which the limbs are attached, tilts; to remain in the vertical position, the spine must curve in the lumbar region as a result of which the centre of gravity is displaced to the back of the hip joint axis. This prevents the trunk from falling forward. The appearance of two lordoses causes the development of two kyphoses (thoracic and sacro-coccygeal) associated with the maintenance of balance in a vertical body posture, which distinguishes man from the other animals.

The spinal curvatures are maintained by the active retaining force of the muscles, by ligaments, and by the shape of the vertebrae themselves. This is important from the standpoint of keeping a stable balance without abnormal expenditure of muscle strength. Owing to its elasticity, the spine curved in this manner bears the weight of the head, upper limbs, and trunk with a springy resistance. With an increase in the load, the spinal curvatures increase; when the load reduces, they become smaller. The spinal curvatures are



important in that they absorb the jerks and shocks directed along the spine in jumping and even in simple walking; the force of the shock is spent on increasing the curvature, without reaching fully the skull and the brain at full force. Besides the mentioned curvatures in the sagittal plane, a less pronounced convex to the right (less frequently to the left) thoracic curvature in the frontal plane is detectable. This lateral curvature, called *scoliosis*, has been given different explanations. According to the latest data, it is a pathological condition not inherent in healthy individuals and is acquired after birth. For instance, marked lateral deformity of the spine may develop in schoolchildren who sit motionless for a long time in an improper, bent posture, particularly when writing; the condition is called school scoliosis. Some occupations involving habitual distortion of the trunk also lead to drastic scoliosis. Rational physical exercises are necessary to prevent scoliosis.

At old age the spine loses its curvatures; because of diminution of the intervertebral discs and the vertebrae and the loss of elasticity, the spine bends forward forming a single big curvature (senile humpback, or senile kyphosis). The vertebral column becomes much shorter. Its length at old age may reduce by 5-6 cm.

**Movement of the vertebral column.** The spine forms a flexible and elastic vertical column by means of the intervertebral cartilages and ligaments. Two elastic systems counteract each other in this column: the cartilages prevent the vertebrae from coming close to one another, while the ligaments prevent them from drawing far apart. It can be seen from the description of the vertebral joints alone that the range of movements between two adjacent vertebrae cannot be wide. Owing to the great number of segments composing the vertebral column, however, the sum total of small-range movements between the vertebrae lend the whole spine rather considerable mobility. This mobility differs in the different parts of the spine. The cervical and upper lumbar parts are most mobile, while the thoracic part is least mobile because it is connected to the ribs. The sacrum is absolutely immobile.

Movements on the following axes are possible in the vertebral column:

- (1) the frontal axis: flexion (forward to an angle of 160 degrees) and extension (backward to an angle of 145 degrees);
- (2) the sagittal axis: abduction and adduction (bending to the right and left with a common amplitude of 165 degrees);
- (3) the vertical axis: rotation of the trunk (turning to the right and left with a common amplitude of 120 degrees). Circumduction is also possible as well as elongation and shortening of the spine through an increase or diminution of the spinal curvatures in contraction or relaxation of the corresponding muscles (springy movements).

## THE THORACIC CAGE

Joining posteriorly with the thoracic vertebrae and anteriorly with the unpaired breast-bone, or sternum, the ribs form the thoracic cage, the thorax, or the chest.

## THE STERNUM

The **breast-bone** (*sternum*) resembling a dagger in shape, consists of three parts: the upper part, the **manubrium sterni**, the middle part, the **body** (*corpus sterni*), and the lower part, the **xiphoid process** (*processus xiphoides*). The manubrium has a **jugular notch** (*incisura jugularis*) on its superior border and lateral to this, a **clavicular notch** (*incisura clavicularis*) on each side, by means of which the sternum articulates with the sternal end of the clavicle. The inferior border of the manubrium and the superior border of the body join at an anteriorly protruding angle, the **angle of the sternum** (*angulus sterni*). The lateral border of the sternal body has **costal facets** (*incisurae costales*) for articulation with the cartilages of the ribs, beginning with the second rib. The body of the sternum widens somewhat toward the lower end and carries on its anterior surface three transverse lines, remnants of the union of the four primary sternal segments.

The xiphoid process varies greatly in appearance and may be perforated, bifid, turned laterally, and so forth. The sternal structure is distinguished by a copious fine, spongy substance with a very rich network of blood vessels, which allows intrasternal transfusion of blood. The abundant development of bone marrow in the sternum makes it an excellent collection point for marrow transplantation in the treatment of radiation sickness.

## THE RIBS

There are twelve ribs on each side, and all articulate by their posterior ends with the bodies of the thoracic vertebrae. The anterior ends of the upper seven ribs are joined directly to the sternum by cartilages. These are the **true ribs** (*costae verae*). The next three ribs, eighth, ninth, and tenth, are joined by their cartilages not to the sternum but to the cartilage of the rib next above, and are referred to as **false ribs** (*costae spuriae*). The anterior ends of the eleventh and twelfth ribs lie free, and these ribs are called **floating ribs** (*costae fluctuantes*).

The **ribs** (*costae*) are narrow curved plates which in their longest, posterior part are formed of bone, *os costale*, belonging to the group of long spongy bones, and in the narrower anterior part, of cartilage, *cartilago costalis*. On the anterior end the bony part of the rib fuses closely with the cartilaginous part. Posterior and anterior ends and a **shaft of the rib** (*corpus costae*) between them are distinguished in each bony rib. The posterior end is slightly enlarged to form the **head of the rib** (*caput costae*), which has an articular facet separated by a ridge; the rib articulates by means of this facet with the vertebral bodies. The facet of the first, eleventh, and twelfth ribs does not have a separating ridge. A narrowed part, the **neck of the rib** (*collum costae*), immediately succeeds the head; it has a longitudinal **crest of the neck of the rib** (*crista colli costae*) on its superior border. The first and last ribs lack this crest. At the junction of the neck and shaft, there is a **tubercle of the rib** (*tuberculum costae*), which carries a facet for joining with the articular surface of the transverse process of

the corresponding vertebra. The eleventh and twelfth ribs do not have this tubercle because they do not articulate with the last thoracic vertebrae. Lateral to the tubercle, the rib curvature is greatly accentuated and the **angle of the rib** (*angulus costae*) is located here posteriorly on the shaft. The angle and the tubercle coincide on the first rib. On the other ribs the distance between them increases down to the eleventh rib, while on the twelfth rib there is no angle. A **groove** (*sulcus costae*) is detectable on the inferior border of the inner surface of the middle ribs; it conducts the intercostal vessels.

The superior surface of the first rib carries the **scalene tubercle** (*tuberculum m. scaleni anterioris*), which is of practical importance because it gives attachment to the **scalenus anterior muscle** (*m. scalenus anterior*). Immediately posterior to this tubercle, a small groove, the groove for the subclavian artery (*sulcus a. subclaviae*), can be seen, into which the subclavian artery fits when it curves over the first rib. Another, flatter **groove for the subclavian vein** (*sulcus v. subclaviae*) is found to the front of the tubercle.

The **size and shape** of the different ribs are closely associated with the shape of the thoracic cage and their location in relation to it. It should firstly be pointed out that the ribs slope, their anterior ends slanting downward considerably. They increase in length from the first to the seventh rib; the seventh and eighth ribs are the longest. The lower four ribs again diminish in length. Since the thoracic cage is ovoid, the ribs are curved in relation to the plane and their border. Longitudinal convexities form posteriorly in the thoracic cage on both sides of the spine and concavities (pulmonary sulcus) on the inner surface because the curvature of the posterior part of the ribs is very steep.

The extreme first, eleventh, and twelfth ribs differ markedly from the other ribs in shape. Their specific features are indicated above.

**The X-ray image of the ribs and sternum.** *Ossification.* Radiographs of the sternum demonstrate separate ossification points: in the manubrium (1-2), in the body (4-13), in which the lower points occur before birth and in the first year of life, and in the xiphoid process (between the ages of 6 and 20). The lower segments of the body fuse at the age of 15-16 years, the upper segment at 25 years of age. The xiphoid process fuses with the body after the age of 30, while the manubrium fuses still later or not at all. In the last case, when the synchondrosis sternalis persists, the radiograph shows a zone of translucency between the shadows of the body and manubrium. One of the ossification points in the sternal body close to the first rib may remain as an accessory bone, os parasternale. The ribs have points of ossification (1) in the region of the angle of the rib; it is the source of ossification of the body except for the anterior end, which remains cartilaginous (costal cartilage); (2) in the head of the rib (epiphysis); and (3) in the tubercle (apophysis). The apophysis appears between the ages of 15-20 and fuse between the ages of 18-25.

In adults, the 12 pairs of ribs are clearly seen on a postero-anterior radiograph; the anterior parts of the ribs are superimposed on the posterior parts and intersect mutually. To interpret the picture properly, it should be borne in mind that the posterior parts of the ribs are connected to the vertebral column and run obliquely, downward and laterally. The anterior parts slope downward, but in an opposite direction, medially. The shadow of the

anterior ends is abruptly interrupted where the bone tissue is continuous with the cartilaginous tissue. The radiograph demonstrates the heads and necks superimposed on the shaft, as well as the transverse processes of the corresponding vertebrae. The tubercles of the ribs and their articulations are also seen close to the transverse processes.

Of most practical importance among variations of costal development are accessory ribs (seventh cervical and first lumbar rib); the twelfth pair of ribs as a rudimentary structure is marked by wider variability than the other ribs. Two forms of the twelfth rib are distinguished: sabre-like, with a long rib sloping downward, and stiletto-like, with a small, short rib stretching horizontally.

## JOINTS OF THE RIBS

**A. Joints of the ribs and the sternum.** The seven true ribs articulate with the sternum by means of their cartilages; the cartilage of the first rib fuses directly with the sternum (synchondrosis), while the remaining costal cartilages commonly form **sternocostal joints** (*articulationes sternocostales*). The joint capsule here is replaced by perichondrium, continuous with the periosteum of the sternum. Anteriorly and posteriorly the joints are strengthened by **sternocostal ligaments** (*ligamenta sternocostalia radiata*) which together with the periosteum on the anterior surface of the sternum form the thick **sternal membrane** (*membrana sterni*). Each false rib (eighth, ninth, and tenth) is connected by the anterior end of its cartilage to the inferior border of the cartilage of the rib above by dense connective tissue fusion (syndesmosis).

According to some data, the tenth pair of ribs usually fails to fuse with the cartilage of the rib above and is free, mobile and does not contribute to the formation of the costal arch, in which event the arch is formed by the seventh, eighth, and ninth ribs. **Interchondral joints** (*articulationes interchondrales*) form between the cartilages of the sixth, seventh, eighth and, sometimes, the fifth ribs; the perichondrium is their articular capsule.

The joints of the ribs and sternum and the sternoclavicular joint (see below) are supplied with *nutrients* by the internal thoracic artery, a. thoracica interna. The *venous blood drains* into the internal thoracic veins. The *lymph drains* along the deep lymphatic vessels into the parasternal and deep cervical lymph nodes, *nodi lymphatici parasternales* and *cervicales profundi*. *Innervation* is supplied by the anterior branches of the intercostal nerves, *rami anteriores nervi intercostales*.

## **B. Joints of the ribs and vertebrae, costovertebral joints (Fig. 40).**

**1. Joints of the heads of ribs** (*articulationes capitis costae*) are formed by the articular facets of the heads of the ribs and the fovea costales of the thoracic vertebrae. The facets on the heads of the second to tenth ribs articulate each with the fovea costales of two adjacent vertebrae. An **intra-articular ligament of the joint of the head of the rib** (*lig. capitis costae intraarticulare*) runs from the crest of the costal head to the intervertebral disc; it separates the joint cavity into two compartments. Since the heads of the first, eleventh, and twelfth ribs articulate with a single fovea costalis on the body of the corresponding vertebra and therefore have no crest, these

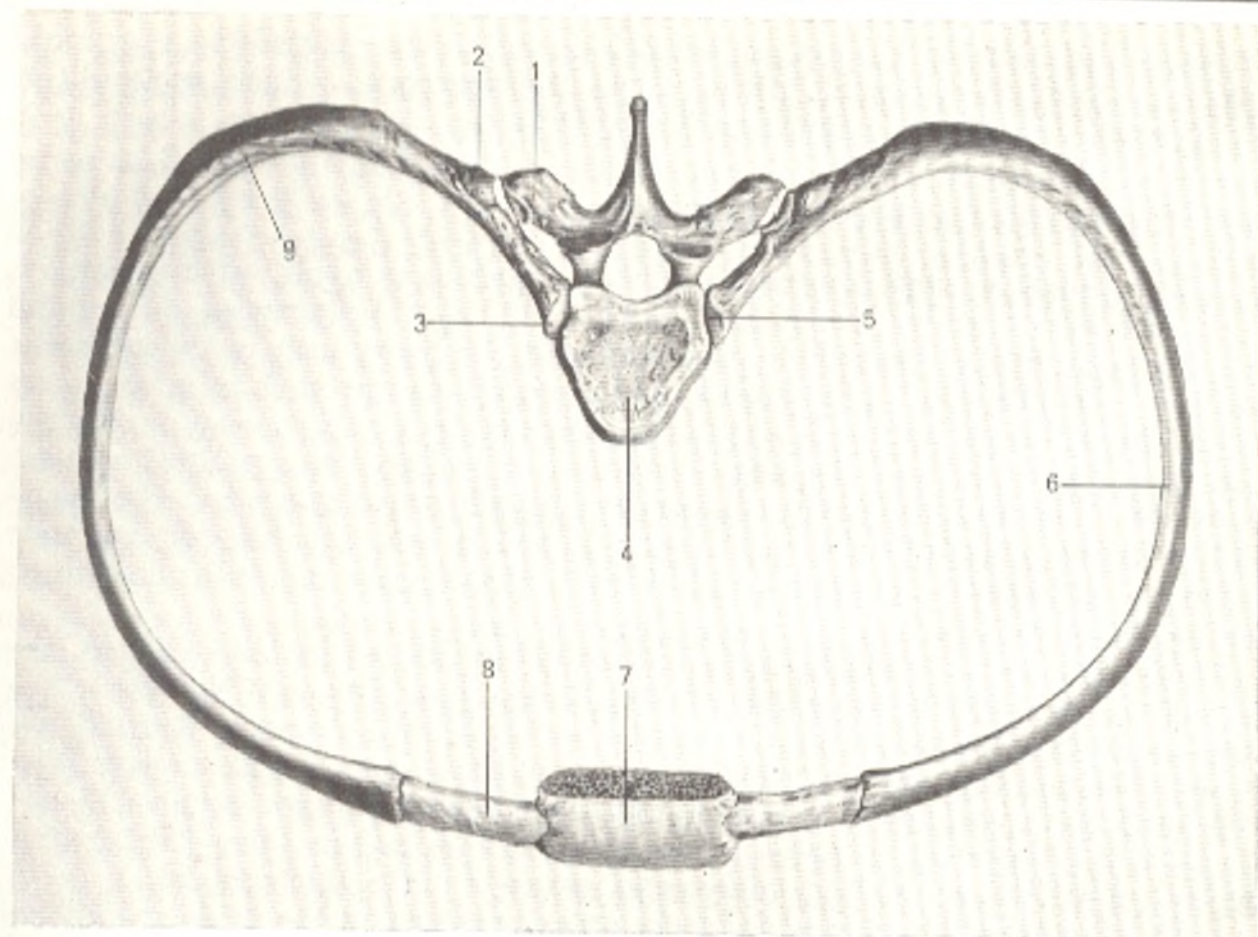


Fig. 40. Union of the ribs with the vertebrae (semischematic representation after R. D. Sinelnikov).

- |  |                                |
|--|--------------------------------|
| 1, processus transversus;                      | 5, articulatio capitis costae; |
| 2, articulatio costotransversaria<br>(opened); | 6, corpus costae;              |
| 3, caput costae;                               | 7, corpus sterni;              |
| 4, nucleus pulposus;                           | 8, cartilago costalis;         |
|  | 9, angulus costae              |

joints do not have an interarticular ligament. The articulationes capitis costae are surrounded by a thin articular capsule, which is strengthened anteriorly by an accessory radiate ligament of the joint of the head of a rib (*lig. capitis costae radiatum*).

2. Costotransverse joints (*articulationes costotransversariae*) form between the tubercles of the ribs and the articular facets of the transverse processes. The last two (eleventh and twelfth) ribs do not have these joints.

The costotransverse joints are strengthened by accessory inferior costotransverse ligaments (*ligamenta costotransversaria*). Both articulations of the ribs with the vertebrae function as a single combined joint (pivotal) with the pivotal axis passing through the neck of the rib.

Thus, the ribs articulate with the vertebrae and sternum by all types of joints. There are synarthroses in the form of syndesmoses (different ligaments) and synchondroses (costal cartilages), hemiarthroses (between some of the costal cartilages and the sternum), and diarthroses (between the ribs and the

vertebrae and between the second to fifth costal cartilages and the sternum). The presence of all types of joints, as in the vertebral column, reflects the line of evolution and is a functional adaptation.

## THE THORACIC CAGE AS A WHOLE

The **thoracic cage** (*compages thoracis, thorax*) is ovoid with a narrow upper end and a wider lower end. Both ends are cut slantwise, the upper part from the front upward to the back and the lower part in the opposite direction. In addition, the thorax is somewhat compressed from front to back. The anterior wall, of which the sternum is a component, is shorter than the posterior wall in the formation of which the vertebral column takes part. The **thoracic cavity** (*cavum thoracis*) has two apertures: the **superior aperture** (inlet) (*apertura thoracis superior*) and the **inferior aperture** (outlet) (*apertura thoracis inferior*), which is closed by a muscular partition, the diaphragm.

The anterior border of the inferior aperture has an incisure shaped like an angle, the **infrasternal angle of the thorax** (*angulus infrasternalis*); the xiphoid process is located at its apex. The vertebral column protrudes into the thoracic cavity on the midline and the above-mentioned wide **pulmonary sulci** (*sulci pulmonales*) form to the sides of the column between it and the ribs; the posterior margins of the lungs are lodged in them. The spaces between the ribs are called **intercostal spaces** (*spatia intercostalia*).

In mammals the thoracic viscera exert pressure on the inferior wall because of their horizontal posture and the thoracic cage is long and narrow; the ventro-dorsal dimension is larger than the transverse dimension as a result of which the thorax appears compressed on the sides and its ventral wall protrudes like the keel of a boat (keeled, or pigeon chest). In monkeys, in whom the hands and feet are distinguished and who begin acquiring a vertical posture, the thoracic cage is wider and shorter, but the ventro-dorsal dimension still predominates over the transverse dimension (monkey chest). Finally, in man, with the final change to an upright position, the hand is freed from

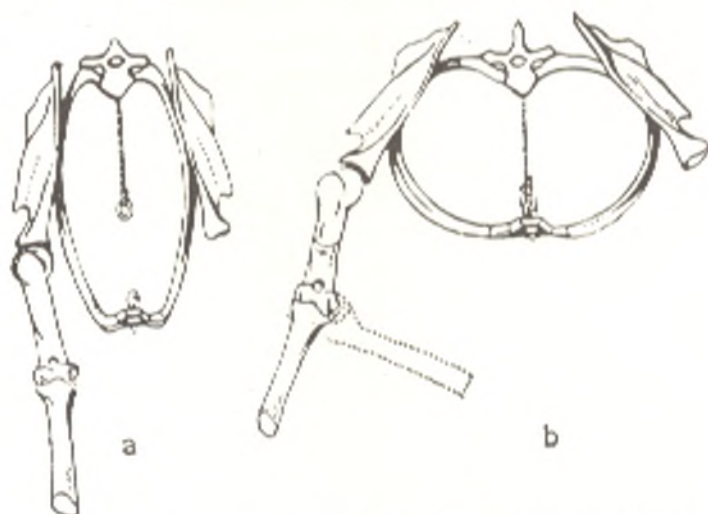


Fig. 41. The shape of the thoracic cage of a quadruped (a) and man (b)

the function of locomotion and becomes the organ of labour, as a result of which the thorax experiences the traction of the upper limb muscles attached to it. The viscera exert pressure not on the ventral wall, which is now the anterior wall, but on the inferior wall formed by the diaphragm. As a consequence the line of weight in a vertical posture of the body is displaced closer to the vertebral column. As a result the thoracic cavity becomes flat and wide so that the transverse dimension predominates over the antero-posterior dimension (human chest, Fig. 41).

In reflection of this process of phylogenesis, the chest changes in shape during ontogenesis. As the child gradually begins to stand, walk, and use his limbs the whole locomotor system and the viscera grow and develop, the thorax gradually takes the shape characteristic of the human chest with the predominance of the transverse dimension<sup>1</sup>.

The *shape and size* of the thoracic cage are also marked by considerable individual variation consequent upon the degree of the development of the muscles and lungs, which in turn is associated with the life-style and occupation of the given person. Since the chest contains such vitally important organs as the heart and lungs, these variations are very important in evaluating the physical development of the individual and in diagnosing internal diseases. Three chest shapes are usually distinguished: flat chest, barrel chest, and conic chest. Individuals with well-developed muscles and lungs have a wide but short thoracic cage, which acquires a *conic shape*, i.e. its lower part is wider than the upper part, the ribs slope only slightly, and the infrasternal angle is large. Such a thorax appears to be in a state of inspiration and is therefore called an *inspiratory chest*. In contrast, in individuals with weak development of the muscles and lungs the thoracic cage is narrow and long and acquires a *flat shape* with a greatly flattened anteroposterior diameter. The anterior wall is almost vertical, the ribs slope markedly, and the infrasternal angle is acute. The thorax appears to be in state of expiration and is therefore called *expiratory*. The *barrel chest* occupies an intermediate position between the two forms described. The female chest is shorter and narrower in the lower part and more rounded than the male chest.

Social factors also influence the shape of the chest. In capitalist countries and colonies, for example, children of the exploited population, who live in poorly lit dwellings and who are undernourished, develop rickets ("English disease"), in which the thorax acquires the shape of a pigeon chest (the anteroposterior dimension predominates and the sternum protrudes forward abnormally as it does in pigeons). The thorax of trumpet players and glass-blowers is wide and bulging because it is continuously expanded in intensified inspiration. In contrast, in cobblers, who worked sitting in a bent posture and used their chest as a support for the heel when they nailed the soles of the shoe, a depression formed on the anterior thoracic wall and the chest became hollower (foveated chest of cobblers). In children with a long and flat chest due to deficient development of the muscles, the thorax is as if in a state of

<sup>1</sup> N. V. Popova-Latkina (1964) claims that the primary shape of the human chest is not a keeled chest but one that is flattened in the antero-posterior and widened in the transverse dimensions.

collapse when they sit improperly at the desk, which has an effect on the activity of the heart and lungs. To avoid disease, children need a certain amount of physical exercise. A person is usually considered fit for service in the armed forces if the circumference of his chest is no less than half his height. The average chest circumference of males between the ages of 20 and 21 is 85.3 cm.

**Movement of the thoracic cage.** Respiratory movement consists in raising and lowering the ribs, together with which the sternum moves also. During inspiration the posterior ends of the ribs rotate on the axis indicated above (on p. 153). The anterior ends rise at the same time and, because of their forward sloping, simultaneously move away from the spine together with the sternum so that the thorax expands in the anteroposterior dimension. Moreover, due to the oblique direction of the pivotal axis, the ribs are simultaneously moved apart laterally, as the result of which the transverse chest dimension also increases. The costal cartilages, being flexible and elastic, play an important role in the respiratory excursions. When the ribs are raised, the angulated curvatures of the cartilages straighten out, and movements occur at the joints between them and the sternum, after which the cartilages themselves are stretched and twisted. When inspiration induced by muscular action is completed, the ribs are lowered and expiration occurs.

Three zones can be distinguished in the thorax according to its mobility: an upper zone above the level of the fourth thoracic segment characterized by slight mobility of the ribs and thoracic vertebrae; a middle zone (from the fourth to the eighth thoracic segment) marked by highest mobility during respiration; and a lower zone (below the level of the eighth segment), which in its movements is linked with the lumbar region of the spine and the diaphragm. To understand the respiratory excursions of the chest and their disorders in fractures of the ribs, it is important to bear in mind the interaction of the three zones.

## THE SKELETON OF THE HEAD

The head is related to the locomotor system only in part. Its skeleton (the skull, cranium) is primarily the receptacle for the most highly developed part of the nervous system, the brain and the sensory organs connected with it; moreover, it encloses the initial part of the digestive and respiratory tracts communicating with the external environment. In accordance with this, the skull of all vertebrates is divided into two parts: the cerebral cranium (*neurocranium*) and the visceral cranium (*cranium viscerale*). The skull-cap, or vault (*calvaria*) and the base (*basis*) are distinguished in the cerebral cranium.

The human cerebral cranium consists of the unpaired occipital, sphenoid, frontal, and ethmoid bones and the paired temporal and parietal bones (Fig. 42). The visceral cranium is formed by the paired maxilla, inferior turbinate, palatine, zygomatic, nasal, and lacrimal bones and the paired vomer, mandible, and the ethmoid and hyoid bones.

**Development of the skull.** The development of the skull as the skeleton of the head is determined by the organs of animal and vegetable life pointed out above.



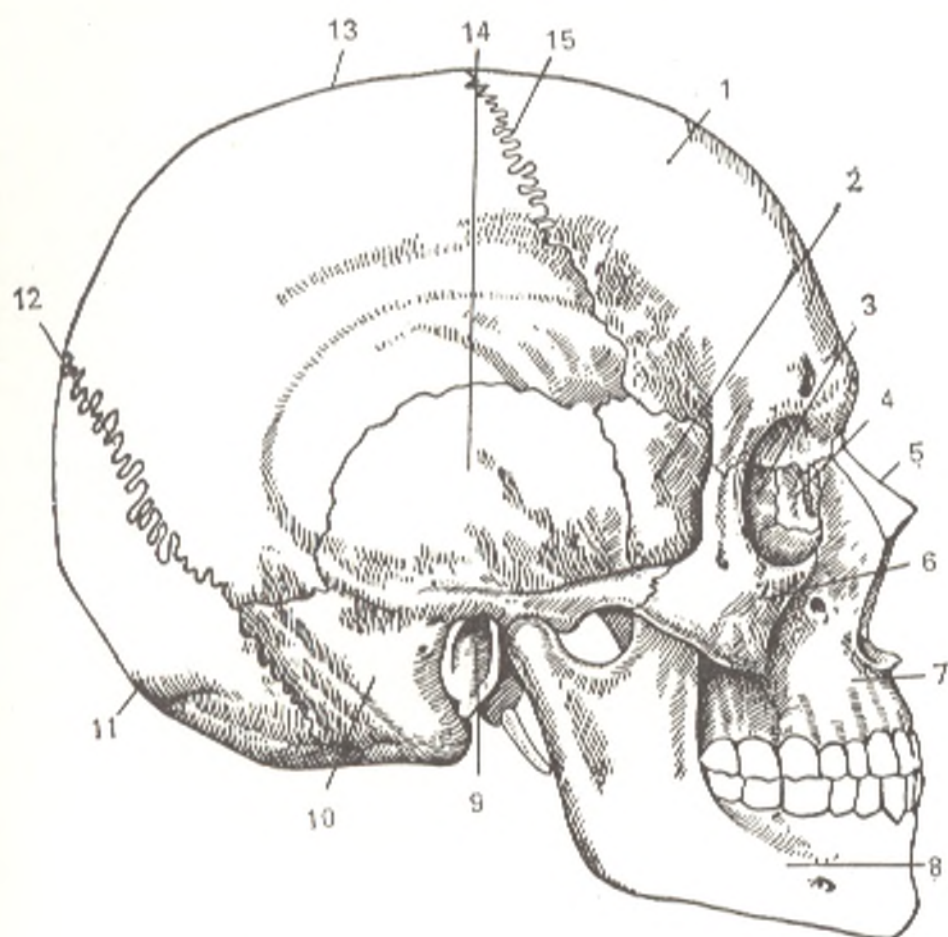


Fig. 42. The skull, cranium.

- |  |   |
|--|---|
| 1, os frontale;                        | 8, mandibula;                                 |
| 2, ala major ossis sphenoidalis;       | 9, porus acusticus externus ossis temporalis; |
| 3, lamina orbitalis ossis ethmoidalis; | 10 and 14, os temporale;                      |
| 4, os lacrimale;                       | 11, os occipitale;                            |
| 5, os nasale;                          | 12, sutura lambdoidea;                        |
| 6, os zygomaticum;                     | 13, os parietale;                             |
| 7, maxilla;                            | 15, sutura coronalis                          |

The *cerebral cranium* develops in connection with the brain and organs of sense. Animals who have no brain also have no skull. The brain of the chordata (lancelot), which is in a rudimentary form, is enclosed in a membrane of connective tissue (membranous skull).

With the development of the brain in fish, a protective receptacle forms around it which in elasmobranch fish (sharks) acquires cartilaginous tissue (cartilaginous skull) and in bony fish, a bony tissue (the beginning of the formation of a bony skull).

When animals begin leaving the water for land (amphibians), the cartilaginous tissue is further replaced by bony tissue which is necessary for protection, support, and movement under conditions of terrestrial existence. In all the other classes of vertebrates, the connective and cartilaginous tissues are almost fully replaced by bony tissue, and a bony skull forms, marked

by great strength. The development of the various skull bones is also determined by the same factors. This explains the relatively simple structure of the calvarial bones (e.g. the parietal bone) and the very complex structure of the base, e.g. the temporal bone which takes part in all functions of the skull and is a receptacle for the organ of hearing and equilibrium. The cerebral cranium of fish is made up of many bones which fuse with the gradual formation of the bony skull. The number of bones in terrestrial animals reduces, therefore, but their structure becomes more complex because some of the bones are the product of fusion of previously independent bone structures. In mammals the cerebral and visceral parts of the skull are closely joined. In man the neurocranium is very large and predominates over the visceral skull because the brain and organs of sense are most highly developed.

The *visceral cranium* develops from the material of the paired visceral arches contained in the lateral walls of the cranial part of the primary gut. In lower aquatic vertebrates, the visceral, or branchial, arches are located metamerically between the branchial clefts, through which water reaches the gills, the respiratory organs of the aquatic phylum.

The first visceral arch, bordering on the mouth, is called the **mandibular arch**. It is made up of two parts: an upper part connected with the cerebral cranium and called the palatoquadrate cartilage (palatoquadrate), and a lower part, Meckel's cartilage. Both parts serve as jaws. The second visceral arch, the **hyoid arch**, is also separated into two parts, the upper hyomandibular and the lower hyoid cartilages. The remaining visceral arches, beginning with the third, are called branchial arches proper: the third visceral arch is called the first branchial arch, the fourth visceral is called the second branchial arch, and so on.

As the animals start leaving water for land, the organs for respiration out of the water, the lungs, develop, whereas the gills lose their importance. In view of this, terrestrial vertebrates, man among others, have gills only in the embryonic period, and the cartilages of the visceral arches are used in the building of the visceral cranium. Thus, the motive forces of the evolution of the skeleton of the head are the change from aquatic to a terrestrial form of life (amphibians), adaptation to environmental conditions on land (all the other classes of vertebrates, mammals in particular), and the highest development of the brain and its tools, the organs of sense, as well as the appearance of the capacity of speech (man).

The principal line of evolution comprises the following:

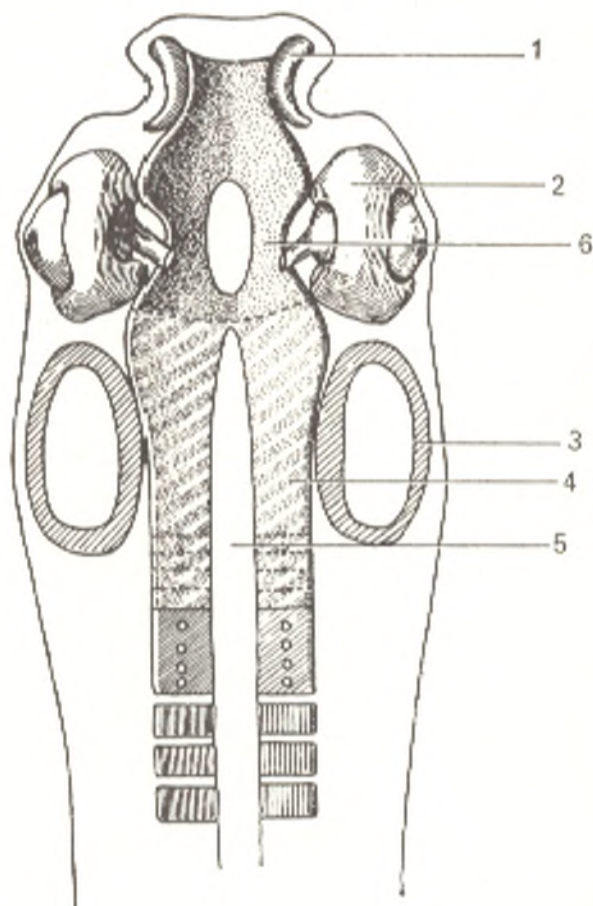
- (1) replacement of the membranous and cartilaginous skull by a bony skull;
- (2) fusion of the bones of the cerebral cranium and a reduction in their number and simultaneous complication of their structure and development as mixed bones;
- (3) conversion of the visceral arch cartilages to bones of the visceral skull;
- (4) union of the cerebral skull with the visceral skull;
- (5) progressive development of the cerebral cranium and its predominance over the visceral skull which is most pronounced in man.

In reflection of this line of evolution, the human skull goes through three developmental stages in ontogenesis: (1) connective-tissue; (2) cartilaginous, and (3) bony. The change from the second to the third stage, i.e. the formation of secondary bones in cartilage, occurs throughout man's life. Remnants of cartilaginous tissue persist between the bones as their cartilaginous joints (synchondroses) even in adults. The calvaria, which serves only for protection of the brain, develops directly from the membranous skull without going through the cartilage stage. The conversion of connective tissue to bony tissue also occurs here throughout man's life. The remnants of unossified connective tissue persist between the skull bones as fontanelles in the newborn and as sutures in children and adults (see below). The cerebral skull is continuous with the vertebral column and develops from the sclerotomes of the cephalic somites three or four pairs of which are laid down in the occipital region around the cranial end of the notochord.

The mesenchyme of the sclerotomes surrounds the cerebral vesicles and the developing organs of sense and forms a cartilaginous capsule (*cranium primordiale*) (early), which, in contrast to the vertebral column, remains unsegmented. The notochord penetrates the skull to the cerebral hypophysis (*hypophysis cerebri*), as a result of which the chordal and prechordal parts are distinguished in the cerebral skull according to their relationship to the notochord. Another pair of cartilages, cranial trabeculae (*trabeculae*

Fig. 43. Development of the skull.

- 1, nasal capsule;
- 2, optic capsule;
- 3, auditory capsule;
- 4, parachordal cartilage;
- 5, notochord;
- 6, trabeculae cranii



*cranii*) is laid down in the prechordal part to the front of the hypophysis; the cartilages are connected to the anteriorly located cartilaginous nasal capsule enveloping the olfactory organ. **Cartilaginous plates** (*parachordalia*) flank the notochord on both sides. The trabeculae cranii fuse later with the parachordalia to form a single cartilaginous plate while the parachordalia fuse with the cartilaginous auditory capsules investing the germs of the organ of hearing (Fig. 43). A recess is formed for the organ of vision between the nasal and auditory capsules on each side of the skull. Traces resembling the fusion of several vertebrae can sometimes be seen in the chordal part in the posterior region of the parachordal cartilages; in contrast, even minimum traces of segmentation cannot be detected in the prechordal part, especially since this part is located beyond the region of the cephalic somites. On the strength of this, the "vertebral theory of the skull" (according to which it is made up of vertebrae fused one to another) advanced first by Goethe and Oken is of importance only in reference to the chordal part of the skull. The absence of segmentation in the cerebral cranium is, of course, explained by its role as a protective accommodation for the brain, which must be absolutely immobile in all its parts.

In reflection of fusion to form larger structures in the process of evolution, the bones of the base of the cerebral cranium arise from separate, previously independent bony structures uniting to form mixed bones. This is discussed below in the description of the different bones of the base.

The cartilages of the visceral arches also undergo changes (see "Bones Developing from the Visceral Arches", and Fig. 44): the palatine part of the palatoquadratic cartilage (the first visceral or mandibular arch) contributes to the formation of the upper jaw. The lower jaw forms on Meckel's cartilage and articulates with the temporal bone by means of the temporomandibular

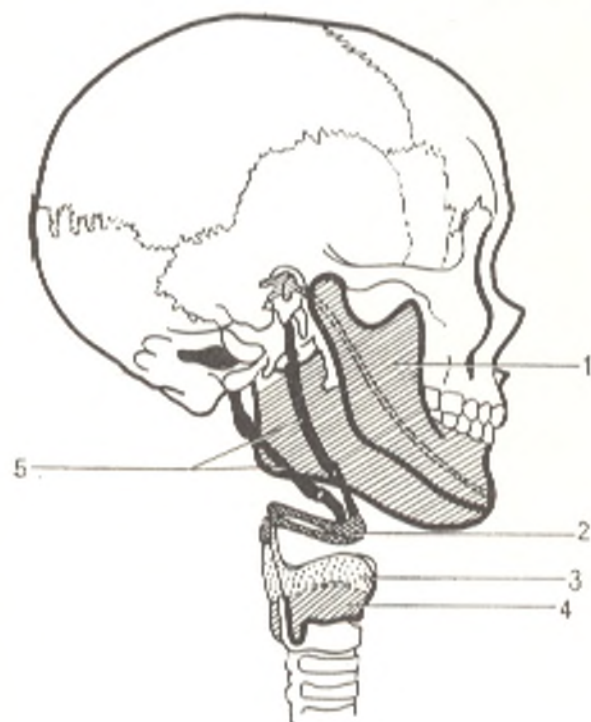


Fig. 44. Interrelationship of derivatives of the visceral and branchial arches represented schematically. Cartilaginous and bony elements arising from the branchial arches in man: lower jaw, hyoid apparatus, and some cartilages of the larynx and pharynx.

- 1, first visceral arch;
- 2, first branchial arch;
- 3, second branchial arch;
- 4, third branchial arch;
- 5, second visceral arch.

joint. The remaining parts of the cartilages of the first visceral arch are converted to the auditory ossicles: the posterior part of Meckel's cartilage (articulare of lowest vertebrates) transforms into the malleus, while the palatoquadratum is converted to the incus. The upper part of the second visceral arch (hyoid arch) gives rise to the third auditory ossicle, the stirrup. All three auditory ossicles are not related to the visceral skull and are located in the tympanic cavity developing from the third branchial cleft (the spiracle of sharks) and forming the middle ear (see "The Organs of Hearing"). The remaining part of the hyoid arch forms the basis for the hyoid bone (the lesser horns and part of the body) and the styloid processes of the temporal bone together with the ligamentum stylohyoideum.

The third visceral (first branchial) arch gives rise to the remaining parts of the body of the hyoid bone and its greater horns. The laryngeal cartilages which are not related to the skeleton are derived from the remaining branchial arches.

The final derivatives of each arch are shown in the table below (derived from data in Braus).

Derivatives of the Branchial Arches and Corresponding Nerves

Visceral broadly defined arches	Primitive state	Derivatives of the human visceral arches	Cranial nerves
First visceral arch	Mandibular arch	Malleus, incus, Meckel's cartilage of lower jaw	Third branch of trigeminal nerve (5th pair)
Second visceral arch	Hyoid arch	Stirrup, styloid process of skull, lesser horns and part of the body of the hyoid bone, ligamentum stylohyoideum	Facial nerve (7th pair)
Third visceral arch	First branchial arch (narrowly defined) of fish	Greater horns and part of the body of the hyoid bone	Glossopharyngeal nerve (9th pair)
Fourth visceral arch	Second branchial arch of fish	Thyroid cartilage of larynx	Superior laryngeal branch of vagus (10th pair)
Fifth visceral arch	Third branchial arch of fish		Recurrent laryngeal branch of vagus (10th pair)

The bones of the human skull may, therefore, be separated into three groups according to their development.

**1. Bones forming the cerebral capsule:**

(a) those developing in connective tissue, the bones of the calvaria, namely the parietal and frontal bones, the squama of the occipital bone, the squamous and tympanic parts of the temporal bone;

(b) bones developing in cartilage, the bones of the base, namely the sphenoid bone (except for the medial plate of the pterygoid process), the body and lateral parts of the occipital bone, the petrous part of the temporal bone.

**2. Bones developing in association with the nasal capsule:**

(a) those developing in connective tissue, namely the lacrimal and nasal bones and the vomer;

(b) bones developing in cartilage, namely the ethmoid and the inferior turbinate bones.

**3. Bones developing from the visceral arches:**

(a) immobile (fixed) bones, namely the upper jaw, the palatine and zygomatic bones;

(b) mobile bones, namely the lower jaw, hyoid bone, and auditory ossicles.

The bones of almost all groups unite to form a single whole, and no movement occurs at their union; the bones of the third group (b), in contrast, are joined to the skull by articulations permitting movements: the lower jaw by a joint and the hyoid bone by ligaments. The bones of the second group delimit the nasal cavity and contribute to the formation of the orbits which contain the organs of vision; the jaw bones carry the dental apparatus. Bones developing from the brain capsule form the **cerebral cranium**, whereas the bones of the other two groups, except for the ethmoid bone, form the **visceral cranium** (bones of the face).

The configuration of the skull is mainly determined by the development of the brain and masticatory apparatus and the relationship between the brain capsule and the masticatory apparatus. The nasal cavity is at first located in front of the cerebral cavity in the skull. In mammals the cerebral cavity, gradually growing with the enlargement of the brain, approaches the nasal cavity; in man, the nasal cavity, together with the facial part of the skull, moves under the brain case not only because the brain is enlarged but also because the masticatory apparatus (the jaws and teeth) reduce. As a result the foramen magnum is displaced. In lowest mammals it is located laterally and faces posteriorly. In monkeys it is in an oblique position. In man it lies almost horizontally and faces downward. The vertical position of the body axis in man is also conducive to the displacement of the foramen magnum. The calvaria of the human skull is raised above the other parts of the skull as a consequence of the powerful development of the brain and is convex and rounded (Fig. 45).

These features sharply distinguish the human skull from the skulls of not only the lowest mammals but also of anthropoid apes; the capacity of the cranial cavity is visual proof of this. Its volume is approximately 1500 cm<sup>3</sup> in man, only 400-500 cm<sup>3</sup> in anthropoid apes, and about 900 cm<sup>3</sup> in the Pithecanthropus. The surface of the human cranium is even and smooth. In anthropoid male apes, in contrast, the cranial surface has sharply

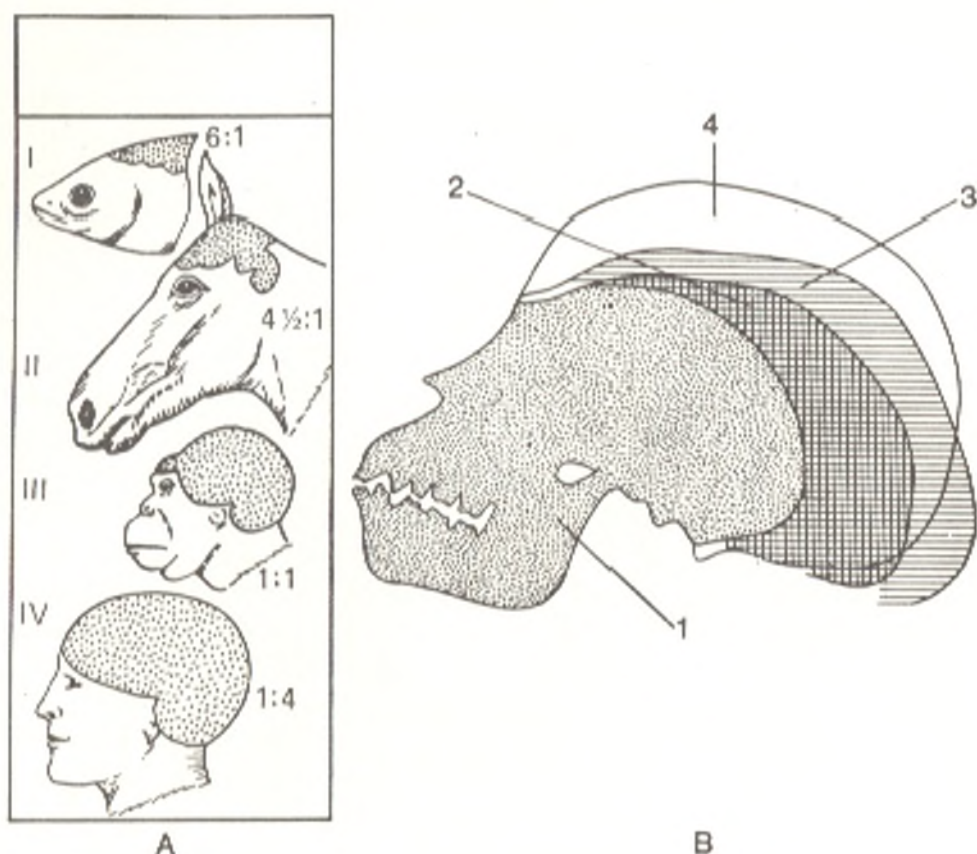


Fig. 45. Increase in the size of the cerebral cranium in the series of vertebrates.

A., the proportion of the visceral skull to the brain case; I, in a fish; II, in a horse; III, in an anthropoid ape; IV, in man. B, 1, a young gorilla; 2, Pithecanthropus; 3, Neanderthal man; 4, European

pronounced ridges consequent upon powerfully developed muscles of mastication. The skull of a very young anthropoid ape is more like the human skull in shape, although it is distinguished by greatly protruding jaws. Moreover, the superciliary elevations stand out noticeably in monkeys but are reduced in man. They still protrude markedly in fossil skulls (of Neanderthal man).

## THE BONES OF THE CEREBRAL CRANIUM

### THE OCCIPITAL BONE

The **occipital bone** (*os occipitale*) forms the posterior and inferior walls of the brain case and is thus a part of the calvaria and a part of the base of the skull (Fig. 46). In accordance with this, it (as a mixed bone) ossifies both as membrane bone in connective tissue (the squama of the occipital bone) and in cartilage (the remaining part of the bone). In man it forms from fusion of several bones that exist independently in some animals. It is thus made up of four parts, which are laid down separately and fuse to form a single bone only between the ages of 3 and 6. These parts, which form the borders of the **foramen magnum** (where the spinal cord is continuous with

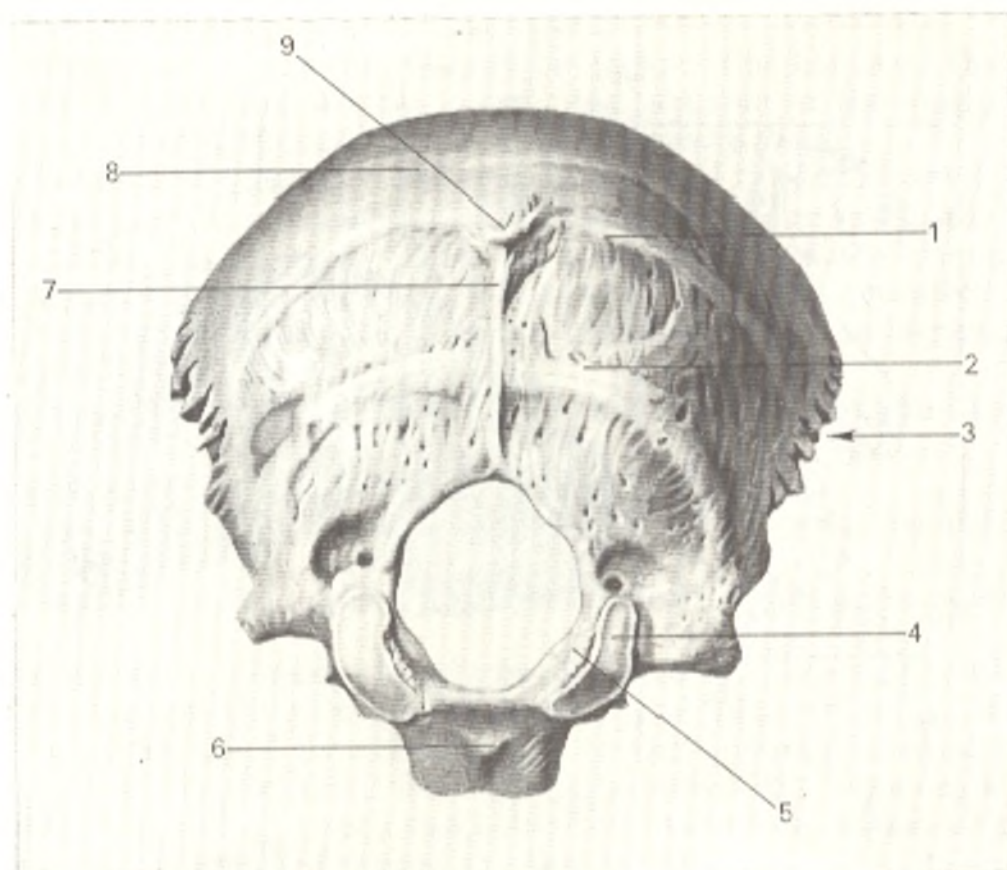


Fig. 46. Occipital bone (os occipitale), external aspect.

- |                                |                                      |
|--------------------------------|--------------------------------------|
| 1, linea nuchae superior;      | 6, tuberculum pharyngeum;            |
| 2, linea nuchae inferior;      | 7, crista occipitalis externa;       |
| 3, squama occipitalis;         | 8, squama occipitalis;               |
| 4, condylus occipitalis;       | 9, protuberantia occipitalis externa |
| 5, canalis (nervi) hypoglossi; |                                      |

the medulla oblongata and passes from the vertebral canal into the cavity of the skull), are as follows: anteriorly, the **basilar part** (*pars basilaris*) (os basilare in animals); laterally, the **condylar parts** (*partes laterales*) (ossa lateralia in animals); and posteriorly, the **squamous part** (*squama occipitalis*) (os superius in animals). The upper part of the squama, which is wedged between the parietal bones ossifies independently and is often separated by a transverse suture throughout life. In some animals, this also reflects the existence of an independent, interparietal bone (os interparietale), as the bone is also called in man.

The **squamous part of the occipital bone** (*squama occipitalis*) as a membrane bone is shaped like a plate, improperly rounded, with a convex external surface and a concave internal surface. The attachment of muscles and ligaments lends it the external relief. The **external occipital protuberance** (*protuberantia occipitalis externa*) (the site of the appearance of the ossification nucleus) is in the centre of the external surface. A curved **superior nuchal line** (*linea nuchae superior*) passes laterally from the protuberance on each side. A less conspicuous **highest nuchal line** (*linea nuchae*



*suprema*) is encountered a little higher. The **external occipital crest** (*crista occipitalis externa*) extends from the occipital protuberance downward on the midline to the posterior edge of the foramen magnum. The **inferior nuchal lines** (*lineae nuchae inferiores*) pass laterally from the middle of the crest. The relief of the internal surface is determined by the shape of the brain and the attachment of its meninges; as a result this surface is divided by two crests intersecting at a right angle into four fossae. These two crests form the **cruciate eminence** (*eminentia cruciformis*) and the **internal occipital protuberance** (*protuberantia occipitalis interna*) at the site of their intersection. The lower half of the longitudinal crest is sharper and is called the **internal occipital crest** (*crista occipitalis interna*) while the upper half of this crest and both halves (or usually the right half) of the transverse crest are supplied with clearly pronounced sulci: **sagittal groove** (*sulcus sinus sagittalis superioris*) and **groove for the transverse sinus** (*sulcus sinus transversi*) (prints of venous sinuses of the same name which are lodged here).

Each **lateral part** (*pars lateralis*) contributes to the union of the skull with the spine and therefore carries on its inferior surface the **occipital condyle** (*condylus occipitalis*), the place of articulation with the atlas. The **anterior condylar canal** (*canalis hypoglossi*) penetrates the bone approximately at the middle of the occipital condyle. Behind the condyle is the **condylar fossa** (*fossa condylaris*) on whose floor an opening of a **posterior condylar canal** (*canalis condylaris*) is sometimes present (for the transmission of a vein). The **jugular process** (*processus jugularis*) projects laterally to the condyle; it is homologous with the transverse processes of the vertebrae. The **sigmoid groove** (*sulcus sinus sigmoidei*) (a mark left by the sigmoid venous sinus), is on the superior surface of *pars lateralis*, next to the jugular process, while the **jugular notch** (*incisura jugularis*) is on its margin.

The **basilar part** (*pars basilaris*) fuses with the sphenoid bone by the age of 18 to form a single bone in the centre of the **cranial base** (*os basilare*). A sloping area, **clivus**, made up of two fused parts, is located on the superior surface of this bone; it lodges the medulla oblongata. The **groove for the inferior petrosal sinus** (*sulcus sinus petrosi inferioris*) is seen on the lateral edges of the basilar part of the occipital bone; it lodges the inferior petrosal sinus. The inferior surface, which is a component of the superior pharyngeal wall, carries the **pharyngeal tubercle** (*tuberculum pharyngeum*) to which the fibrous capsule of the pharynx is attached.

## THE SPHENOID BONE

The **sphenoid bone** (*os sphenoidale*) is an unpaired bone whose structure is even more complex than that of the occipital bone. The sphenoid bone resembles a bat or a flying insect, which explains the names of its parts (wings, pterygoid processes, Gk *pterygoïn* wing). The name "sphenoid" probably appeared by mistake<sup>1</sup>.

<sup>1</sup> In Galen's manuscript this bone was called sphecoid (resembling a wasp), but apparently the copyist made an error and wrote sphenoid (wedged, Gk *sphen* wedge).

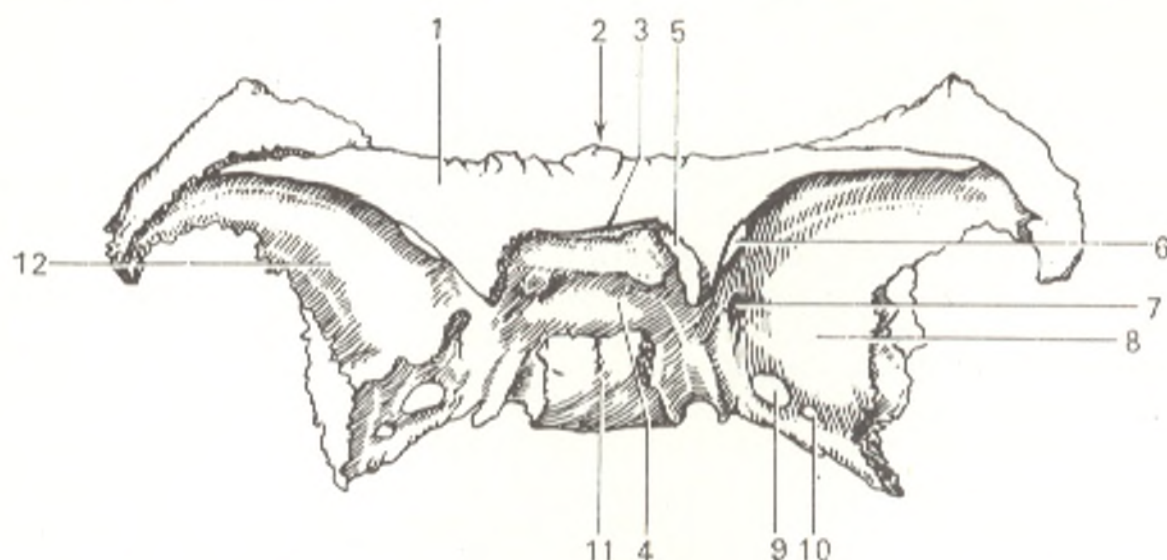


Fig. 47. Sphenoid bone (os sphenoidale) viewed from above.

- |                                |                                 |
|--------------------------------|---------------------------------|
| 1, ala minor;                  | 7, foramen rotundum;            |
| 2, corpus ossis sphenoidalis;  | 8, facies cerebri alae majoris; |
| 3, sulcus chiasmatis;          | 9, foramen ovale;               |
| 4, fossa hypophysialis;        | 10, foramen spinosum;           |
| 5, canalis opticus;            | 11, dorsum sellae;              |
| 6, fissura orbitalis superior; | 12, ala major.                  |

The sphenoid bone forms as the result of fusion of several bones that in animals exist independently. It therefore develops as a mixed bone from several paired and unpaired foci of ossification merging by the time of birth into three parts, which, in turn, fuse to form a single bone by the end of the first year of life. The following parts can be distinguished: (1) the **body** (*corpus*) (in animals, the unpaired basisphenoid and presphenoid); (2) the **greater wings** (*alae majores*) (in animals, the paired alisphenoid); (3) the **lesser wings** (*alae minores*) (in animals, the paired orbitosphenoid) and (4) the **pterygoid processes** (*processus pterygoidei*) (the medial plate of the bone, the former paired pterygoid, develops on the basis of connective tissue whereas the other parts of the bone develop from cartilage).

The **body** (*corpus*) has on the midline of its superior surface a depression, the shape of a Turkish saddle, the **sella turcica**, on the floor of which is a **depression for the cerebral hypophysis** (*fossa hypophysialis*) (Fig. 47). To the front of the depression is an elevation, the **tuberculum sellae**, on which the **sulcus chiasmatis** lodging the crossing (*chiasma*) of the fibres of the optic nerve passes transversely. The **optic foramina** (*canales optici*) transmitting the optic nerves from the orbital cavity into the cranial cavity, are found at the ends of the sulcus chiasmatis. The sella turcica is bounded posteriorly by a bony plate, the **dorsum sellae**. The lateral parts of the dorsum project forward in the form of the **posterior clinoid processes** (*processus clinoidae posteriores*). A curved **carotid groove** (*sulcus caroticus*) lodging the internal carotid artery passes on the lateral surface of the body.

A ridge, the **crest of the sphenoid** (*crista sphenoidalis*) is seen on the anterior surface of the body, which is a part of the superior wall of the nasal

cavity (Fig. 48). The crest continues down to become a pointed vertical prominence, the **rostrum of the sphenoid** (*rostrum sphenoidale*), which fits between the wings of the vomer. The sphenoidal crest articulates in front with the perpendicular plate of the ethmoid bone. Irregularly shaped openings, **apertures of the sphenoidal sinus** (*aperturæ sinus sphenoidalis*) are seen to the sides of the crest. They open into an air cavity, the **sphenoidal sinus** (*sinus sphenoidalis*) located in the body of the sphenoid bone and divided by a **septum of the sphenoidal sinus** (*septum sinuum sphenoidalium*) into two halves. The sinus communicates with the nasal cavity by means of these openings. These sinuses are very small in the newborn and start growing rapidly only at about 7 years of age.

The **lesser wings** (*alae minores*) are two flat triangular plates arising by two roots from the anterosuperior edge of the body of the sphenoid bone and extending forward and laterally. The optic canals mentioned above are located between the roots of the wings. The posterior edges of the lesser wings are free and carry on their medial ends the **anterior clinoid processes** (*processus clinoides anteriores*) formed, just as the posterior clinoid processes, from the attachment of the process of the dura mater. The **superior orbital fissure** (*fissura orbitalis superior*) leading from the cranial into the orbital cavity, is between the lesser and greater wings.

The **greater wings** (*alae majores*) spring from the sides of the body laterally and upwards. A **round opening** (*foramen rotundum*) leading in front into the pterygopalatine fossa (see Fig. 68), is located close to the body, to the back of the superior orbital fissure; it transmits the second branch of the trigeminal nerve, n. trigemini. Posteriorly the greater wing is wedged between the squama and pyramid of the temporal bone as a sharp angle; a sharp projection, the **spine of the sphenoid** (*spina ossis sphenoidalis*) is found on the inferior surface of this angle. Close to it is the **spinous foramen** (*foramen spinosum*) through which the middle meningeal artery passes. A much larger **oval foramen** (*foramen ovale*) is seen to the front of it; it transmits the third branch of the trigeminal nerve.

The greater wings have the following four surfaces: **cerebral** (*facies cerebralis*); **orbital** (*facies orbitalis*); **temporal** (*facies temporalis*), and **maxillary** (*facies maxillaris*). Their names indicate which cranial surface they face. The last two surfaces are separated by the **infratemporal crest** (*crista infratemporalis*).

The **pterygoid processes** (*processus pterygoidei*) (Fig. 49), drop vertically downward from the junction of the greater wings and the body of the sphenoid bone (Fig. 49). Their base is pierced by a **pterygoid canal** (*canalis pterygoideus*) directed sagittally, which transmits the pterygoid nerve and vessels. Its anterior opening communicates with the pterygopalatine fossa.

Each process is made up of two plates, one **medial** and one **lateral** (*lamina medialis* and *lamina lateralis*), between which the **pterygoid fossa** (*fossa pterygoidea*) forms posteriorly. The inferior portion of this fossa is continuous with the **pterygoid fissure** (*fissura pterygoidea*). In the intact skull the pyramidal process of the palatine bone fits into this notch.

The inferior part of the medial plate bends over to form a hook-like

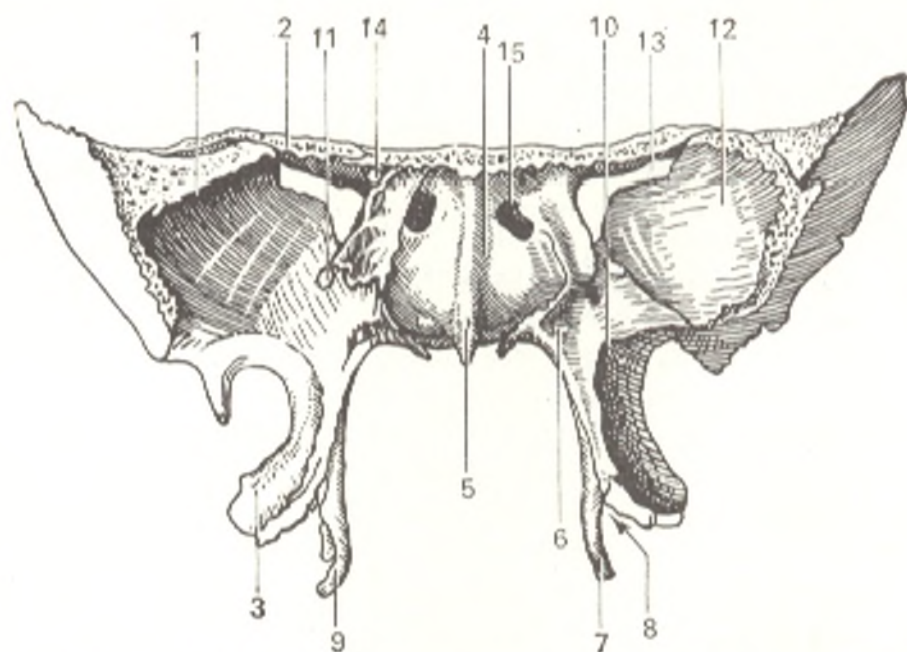


Fig. 48. Sphenoid bone (os sphenoidale), anterior aspect.

1, ala major;  
2, ala minor;  
3, lamina lateralis proc. pterygoidei;  
4, corpus ossis sphenoid.;  
5, crista sphenoidalis;  
6, canalis pterygoideus;  
7, lamina medialis proc. pterygoidei;  
8, incisura pterygoidea;

9, hamulus pterygoideus;  
10, origin of processus pterygoideus;  
11, foramen rotundum;  
12, orbital surface of ala major;  
13, fissura orbitalis sup.;  
14, canalis opticus;  
15, apertura sinus sphenoidalis

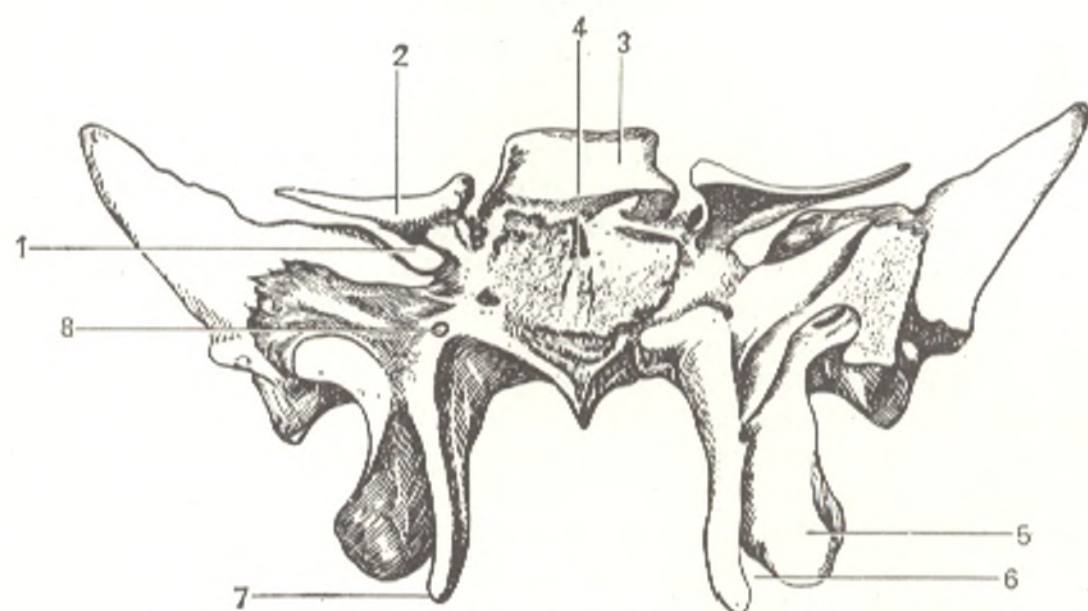


Fig. 49. Sphenoid bone (os sphenoidale), posterior aspect.

1, fissura orbitalis superior;  
2, ala minor;  
3, dorsum sellae;  
4, corpus ossis sphenoidalis;

5, lamina lateralis proc. pterygoidei;  
6, incisura pterygoidea;  
7, lamina medialis proc. pterygoidei;  
8, canalis pterygoideus

process called the **hamulus pterygoideus**. The tendon of *m. tensor palatini* (one of the muscles of the soft palate), which arises here, passes around the hamulus pterygoideus.

## THE TEMPORAL BONE

The temporal bone (*os temporale*) is a paired bone whose structure is very complicated because it is concerned with all three functions of the skeleton and not only forms part of the lateral wall and base of the skull but houses the organs of hearing and equilibrium. It is the product of fusion of several bones (mixed bone), which exist independently in some animals, and therefore consists of three parts: (1) **squamous part** (*pars squamosa*) (in animals, *os squamosum*); (2) **tympanic part** (*pars tympanica*) (in animals, *tympanicum*), and (3) **petrous part** (*pars petrosa*) (in animals, *petrosum*). A fourth part of the temporal bone, mastoid (*pars mastoidea*) was previously distinguished. The mastoid, however, does not have a nucleus for independent ossification and arises from the pars petrosa. In the formed bone these parts are, therefore, united under the common name pars petrosa (PNA), while in the newborn, in whom the three parts of the temporal bone are still not fused, this part is called pars petromastoidea.

Within the first year of life the parts fuse into a single bone and thus form the **external acoustic meatus** (*meatus acusticus externus*) with the squamous part to the top, the petrous part in a medial position, and the tympanic part to the back, bottom, and front. The traces of fusion of the separate parts of the temporal bone persist throughout life in the form of sutures and fissures, namely: **petrosquamous fissure** (*fissura petrosquamosa*) on the border between the squamous and petrous parts on the anterosuperior surface of the latter; the **tympanosquamous fissure** (*fissura tympanosquamosa*) in the depth of the mandibular fossa separated by the process of the petrous part into *fissura petrosquamosa*, and **petrotympanic fissure** (*fissura petrotympanica*) (Fig. 50) (through which the chorda tympani nerve passes).

The **squamous part** (*pars squamosa*) contributes to the formation of the lateral walls of the skull. This membrane bone, which ossifies in connective tissue, has a relatively simple structure of a vertical plate with a rounded edge articulating with the corresponding edge of the parietal bone, *margo squamosa*, like the scales of fish, hence its name (*l. squama scale*)<sup>1</sup>.

The **cerebral surface** (*facies cerebralis*) of the squamous part bears marks of the brain, **impressions for cerebral gyri** (*impressiones digitatae*) and an ascending groove lodging the middle meningeal artery (*a. meningeae media*). The smooth external surface of the squama contributes to the formation of the temporal fossa and is therefore called the **temporal surface** (*facies temporalis*). It gives rise to the **zygomatic process** (*processus zygomaticus*), which passes forward to join the zygomatic bone. The zygomatic process has two

<sup>1</sup> Another explanation for the term is that the membranous bones originate in the skin bones of fishes (scales).

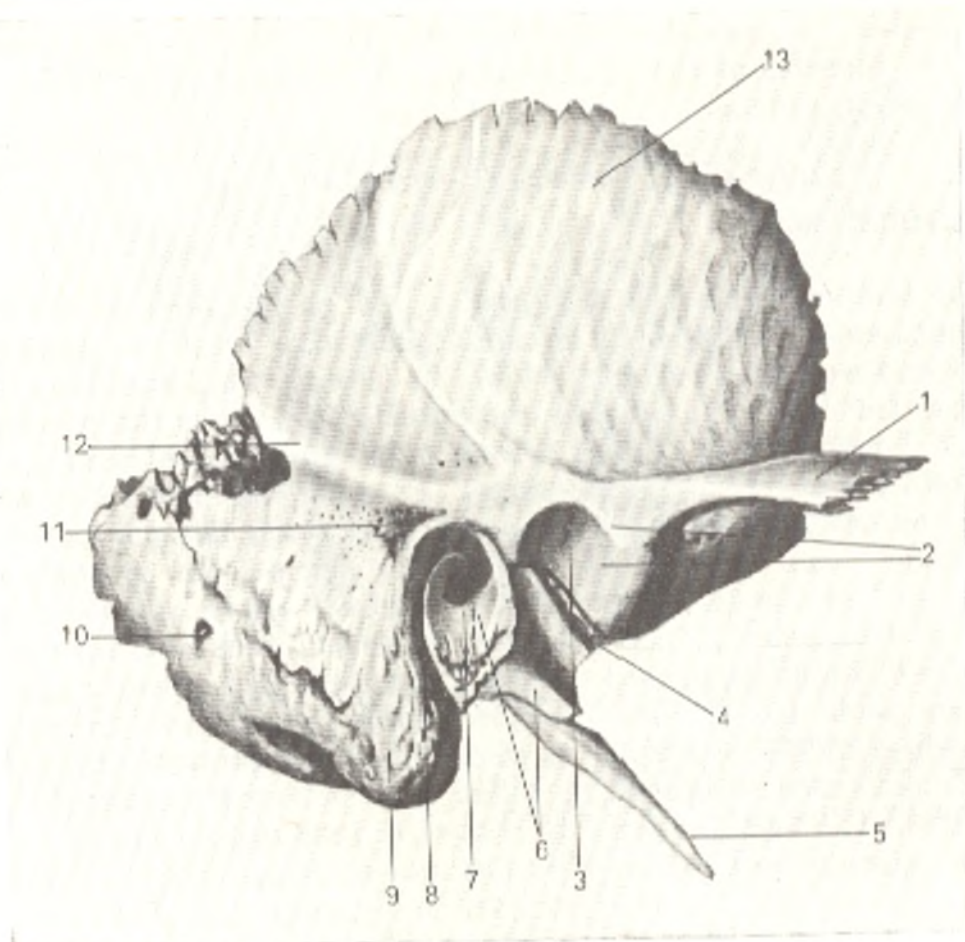


Fig. 50. Right temporal bone (os temporale), lateral aspect.

1, processus zygomaticus;  
2, tuberculum articulare;  
3, fossa mandibularis;  
4, fissura petrotympanica;  
5, processus styloideus;  
6, pars tympanica;  
7, porus acusticus externus;

8, edge of pars tympanica;  
9, processus mastoideus;  
10, foramen mastoideum;  
11, spina suprêmeatum;  
12, linea temporalis;  
13, pars squamosa

roots at its origin, an anterior and a posterior root, with a depression—**articular fossa** (*fossa mandibularis*) for articulating with the lower jaw between them. The inferior surface of the anterior root carries an **articular tubercle** (*tuberculum articulare*), which prevents anterior dislocation of the head of the mandible when the mouth is opened very wide.

The **tympanic part** (*pars tympanica*) of the temporal bone forms the anterior, inferior, and part of the posterior border of the external acoustic meatus. It fuses with the mastoid process laterally and with the petrous part medially. It undergoes endesmal ossification and, as all membrane bones, resembles a plate, although in this case the plate is sharply bent.

The **external auditory meatus** (*meatus acusticus externus*) is a short canal directed medially and somewhat anteriorly and leading into the tympanic cavity. The superior edge of its external opening, **porus acusticus externus**, and part of the posterior edge are formed by the squama of the

temporal bone. The other edges are formed by the tympanic part of the bone.

The external acoustic meatus is incompletely formed in the newborn because the tympanic part is an incomplete ring (anulus tympanicus) closed by the tympanic membrane. Since the tympanic membrane is so near the external environment, newborns and infants often suffer from diseases of the membrane. The tympanic ring grows and is converted to a tube during the first year of life; this tube pushes the petrous part medially and forms most of the bony external acoustic meatus whose roof is the squamous part. The tympanic membrane now moves deeper into the external acoustic meatus and separates it (i.e. the external ear) from the tympanic cavity, *cavum tympani* (and becomes external in relation to the tympanic cavity). The floor of this cavity, just as the floor of the acoustic meatus, is formed by the tympanic part, while the superior and internal walls are formed by the petrous part.

The petrous part (*pars petrosa*) (Gk *petros* stone) is an important component of the temporal bone. It is so named because its bony substance is strong. It is a part of the base of the skull and at the same time is a bony encasement for the organs of hearing and equilibrium, which have a very fine structure and must be protected reliably from injuries. The petrous part develops in cartilage. This part is also called the pyramid because it is shaped like a trihedral pyramid with the base facing externally and the apex facing anteriorly and internally toward the sphenoid bone (Fig. 51).

The pyramid has three surfaces: anterior, posterior, and inferior. The anterior surface is part of the floor of the middle cranial fossa, the posterior surface faces posteriorly and medially and forms part of the anterior wall of the posterior cranial fossa; the inferior surface faces downward and is visible only on the external surface of the base of the skull. The complex external relief of the pyramid is determined by its structure as a receptacle for the middle (the tympanic cavity) and the internal ear (the bony labyrinth made up of the cochlea and the semicircular canals), as well as by the passage of nerves and vessels. The anterior surface of the pyramid has a small depression near its apex. This is the trigeminal impression (*impressio trigemini*), which lodges the ganglion of the trigeminal nerve (n. trigeminus). Lateral to it pass two small grooves, a medial sulcus of the greater petrosal nerve (*sulcus n. petrosi majoris*) and a lateral sulcus of the lesser petrosal nerve (*sulcus n. petrosi minoris*). They lead to two openings of the same name, a medial opening (*hiatus canalis n. petrosi majoris*) and a lateral opening (*hiatus canalis n. petrosi minoris*). The arcuate eminence (*eminentia arcuata*) is lateral to these openings; it forms due to prominence of the vigorously developing labyrinth, particularly the superior semicircular canal. The bone surface between the petrosquamous fissure and the arcuate eminence forms the roof of the tympanic cavity (*tegmen tympani*).

In about the middle of the posterior surface of the pyramid is the porus acusticus internus leading into the internal auditory meatus (*meatus acusticus internus*), which transmits the facial and auditory nerves and the internal auditory artery and veins.

The inferior surface of the pyramid (Fig. 52) that faces the base of the

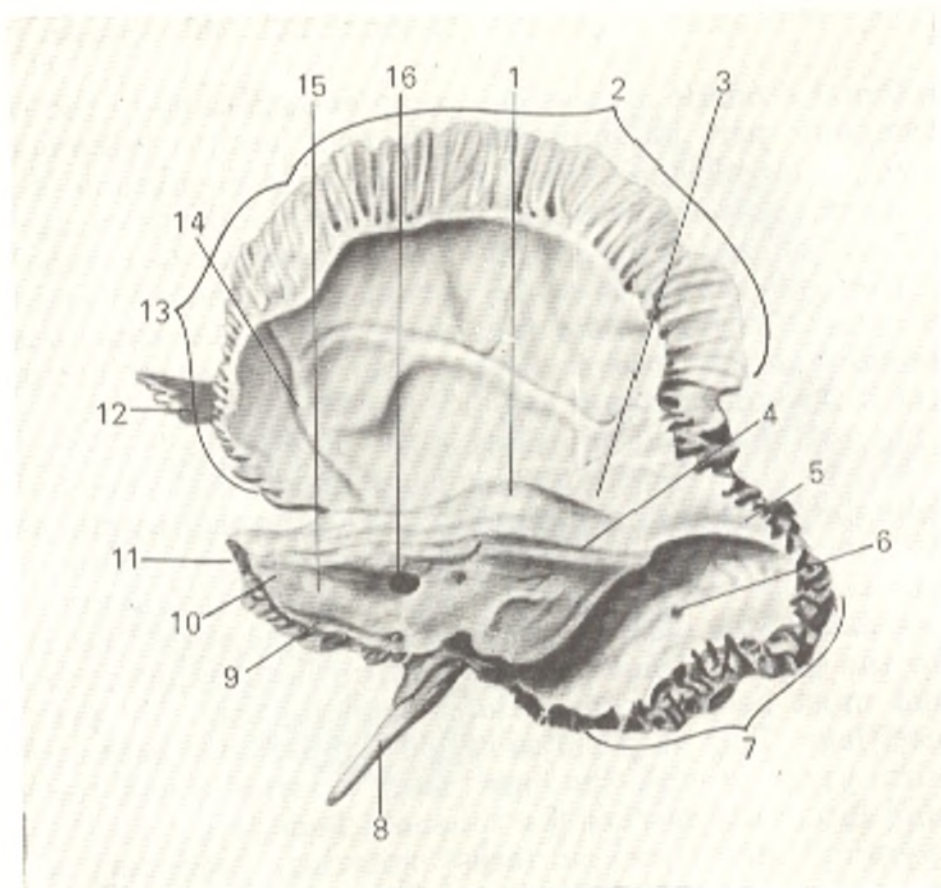


Fig. 51. Right temporal bone (os temporale), seen from the inside and from the back.

- |                                     |                                     |
|-------------------------------------|-------------------------------------|
| 1, eminentia arcuata;               | 9, sulcus sinus petrosi inferioris; |
| 2, margo parietalis;                | 10, apex pyramidis;                 |
| 3, tegmen tympani;                  | 11, pars petrosa s. pyramis;        |
| 4, sulcus sinus petrosi superioris; | 12, processus zygomaticus;          |
| 5, sulcus sinus sigmoidalis;        | 13, margo sphenoidalis;             |
| 6, foramen mastoideum;              | 14, sulcus arteriosus;              |
| 7, margo occipitalis;               | 15, facies posterior pyramidis;     |
| 8, processus styloideus;            | 16, porus acusticus internus        |

skull gives off a slender tapering **styloid process** (*processus styloideus*) for attachment of the muscles forming the "anatomical bouquet" (*m. styloglossus*, *m. stylohyoideus*, *m. stylopharyngeus*) and also the ligaments (*lig. stylohyoideum* and *lig. stylomandibulare*). The styloid process is part of the temporal bone of branchial origin. Together with the stylohyoid ligament, it is a remnant of the second visceral arch, the hyoid arch.

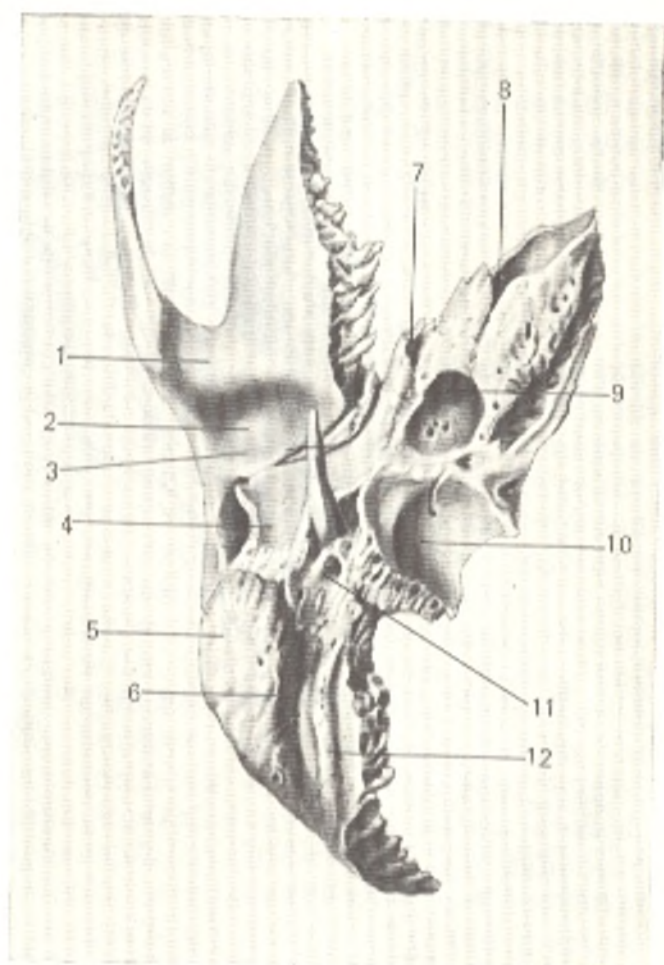
Sometimes the entire length of the stylohyoid ligament ossifies, which results in chronic developmental anomaly of the hyoid arch. Between the styloid and mastoid processes is the **stylomastoid foramen** (*foramen stylomastoideum*) transmitting the facial nerve and one of the arteries. The deep **jugular fossa** (*fossa jugularis*) is medial to the styloid process. To the front of the jugular fossa and separated from it by a sharp ridge is the **external opening of the carotid canal** (*foramen caroticum externum*).

The pyramid has three edges: anterior, posterior, and superior. The short anterior edge forms a sharp angle with the squama, in which



Fig. 52. Right temporal bone (os temporale), inferior aspect.

- 1, tuberculum articulare;
- 2, fossa mandibularis;
- 3, fissura petrotympanica;
- 4, pars tympanica;
- 5, processus mastoideus;
- 6, incisura mastoidea;
- 7, canalis musculotubarius;
- 8, foramen caroticum internum;
- 9, foramen caroticum externum;
- 10, fossa jugularis;
- 11, foramen stylomastoideum;
- 12, sulcus a. occipitalis



is found the **musculotubal canal** (*canalis musculotubarius*) leading to the tympanic cavity. The canal is divided by a septum into two parts: superior and inferior. The superior, smaller semicanal (*semicanalis m. tensoris tympani*) lodges the tensor tympani muscle, while the lower, larger semicanal (*semicanalis tubae auditivae*) is the bony part of the auditory tube for the conduction of air from the pharynx to the tympanic cavity.

The superior edge of the pyramid that separates the anterior and posterior surfaces bears a clearly detectable groove, **groove for the superior petrosal sinus** (*sulcus sinus petrosi superioris*) lodging the superior petrosal venous sinus.

The posterior edge of the pyramid joins the pars basilaris of the occipital bone to the front of the jugular fossa and together with this bone forms the **groove for the inferior petrosal sinus** (*sulcus sinus petrosi inferioris*) lodging the inferior petrosal sinus.

The external surface of the base of the pyramid provides attachment for the muscles; this determines its relief (process, notches, areas of roughness) (see Fig. 50). Its lower end stretches out to form the **mastoid process** (*processus mastoideus*) to which the sternocleidomastoid muscle is attached. This muscle balances the head, which is necessary for maintenance of the vertical posture of the body. The mastoid process is absent, therefore, in quadrupeds and anthropoid apes and develops only in man due to his erect

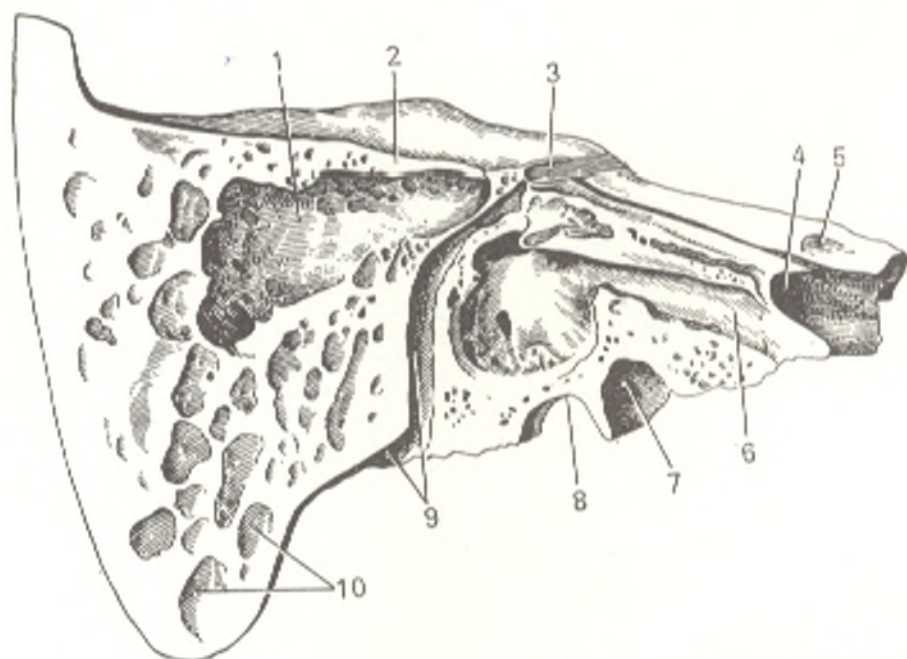


Fig. 53. Right temporal bone (os temporale), vertical section parallel to the pyramid axis.

1, cavum tympani;  
2, tegmen tympani;  
3, canalis facialis;  
4, foramen caroticum internum;  
5, impressio trigemini;  
6, semicanalis tubae auditivae;

7, foramen caroticum externum;  
8, fossa jugularis;  
9, canalis facialis et foramen stylomastoideum;  
10, cellulae mastoideae

posture. The medial surface of the mastoid process bears a deep **mastoid notch** (*incisura mastoidea*), the site of attachment of *m. digastricus*, and, still closer to the midline, a small **occipital groove** (*sulcus a. occipitalis*). A smooth triangle on the external surface of the base of the mastoid process is the operative approach to the air cells of the process when they are filled with pus. The **suprameatal spine** (*spina suprameatum*) projects in front of the triangle (see Fig. 50).

The mastoid process contains compartments or cells (*cellulae mastoidea*), which are air cavities separated by bone trabeculae. They receive air from the tympanic cavity with which they communicate by means of the mastoid antrum (antrum mastoideum). A deep sigmoid groove (*sulcus sinus sigmoidei*) is found on the cerebral surface of the base of the pyramid. The canal of the venous emissary opens into this sulcus; its external opening, **mastoid foramen** (*foramen mastoideum*), varying greatly in accordance with the size of the canal, is near to or in the occipitomastoid suture.

**The canals of the temporal bone.** The largest is the **carotid canal** (*canalis caroticus*), which transmits the internal carotid artery. It begins as the **external carotid foramen** (*foramen caroticum externum*) on the interior surface of the pyramid, then ascends and bends at a right angle and opens by its **internal foramen** (*foramen caroticum internum*) at the apex of the pyramid medial to the canalis musculotubarius. The canal for the facial nerve (*canalis facialis*) (Fig. 53) begins in the depth of porus acusticus internus and

then passes at first forward and laterally to the hiatus in the anterior surface of the pyramid. There the *canalis facialis*, still horizontal, bends at a right angle laterally and backward to form the **geniculum of the facial canal** (*geniculum canalis facialis*); it then descends and ends as the **stylomastoid foramen** (*foramen stylomastoideum*) on the inferior surface of the pyramid of the temporal bone.

### THE PARIETAL BONE

The **parietal bone** (*os parietale*) is a paired bone forming the middle part of the vault of the skull. It is better developed in man than in animals because of the higher development of man's brain. This is a typical membrane bone, which primarily performs a protective function. Its structure, therefore, is relatively simple; it is a quadrangular plate with convex external and concave internal surfaces. Its four borders articulate with the adjoining bones, namely: the **frontal border** (*margo frontalis*) with the frontal bone; the posterior, **occipital border** (*margo occipitalis*) with the occipital bone; the superior, **sagittal border** (*margo sagittalis*) with the contralateral bone, and the inferior, **squamosal border** (*margo squamosus*) with the squama of the temporal bone. The first three borders are serrated, while the last is adapted for the formation of a squamous suture. The four angles are as follows: the **frontal angle** (*angulus frontalis*) unites with the frontal bone; the **sphenoidal angle** (*angulus sphenoidalis*) joins with the sphenoid bone; the **occipital angle** (*angulus occipitalis*) articulates with the occipital bone; and the **mastoid angle** (*angulus mastoideus*) unites with the mastoid process of the temporal bone. The relief of the external convex surface is determined by the attachment of muscles and fasciae. In its centre is a prominence, the **parietal eminence** (*tuber parietalis*) (where ossification begins). Below it are two curved **temporal lines** (*linea temporalis superior* and *inferior*) for attachment of the temporal fascia and muscle. An opening, the **parietal foramen** (*foramen parietale*) for the artery and the venous emissary is seen near to the superior border. The relief of the internal concave surface (*facies interna*) is determined by the brain and especially the dura mater, which fit close to it. The sites of attachment of the dura mater to the bone are marked by a **sagittal groove** (*sulcus sinus sagittalis superioris*) (lodging the superior sagittal sinus) on the superior border, and a **transverse groove** (*sulcus sinus sigmoidei*) (lodging the sigmoid sinus), in the region of the *angulus mastoideus*. The vessels of the dura mater have left imprints forming a pattern of branching grooves on almost the entire internal surface. Pits for **pacchionian granulations** (*foveolae granulares*) (see "Meninges", Vol. II), are seen on either side of the *sulcus sinus sagittalis superioris*.

### THE FRONTAL BONE

The **frontal bone** (*os frontale*) an unpaired, membrane bone, contributes to the formation of the vault of the skull and develops in connective tissue. It is, moreover, associated with the organs of sense (smell and vision). In

accordance with this double function, the frontal bone is made up of two parts: a vertical part, *squama* (*squama frontalis*) and a horizontal part. According to its relation to the organs of vision and smell, the paired **orbital part** (*pars orbitalis*) and an unpaired **nasal part** (*pars nasalis*) are distinguished in the horizontal part. As a result, the following four parts are distinguished in the frontal bone.

1. The **frontal squama** (*squama frontalis*) as any membrane bone, has the shape of a plate, externally convex and internally concave. It ossifies from two ossification points, which are apparent even in an adult as two **frontal tubers** (*tubercula frontalia*) on the **external surface** (*facies externa*). They are pronounced only in man due to the development of the brain. They are absent not only in anthropoid apes but also in extinct forms of man. The inferior border of the squama is called the **supraorbital border** (*margo supraorbitalis*). Approximately at the junction of the medial and middle third of this border is the **supraorbital notch** (*incisura supraorbitalis*) (which transforms sometimes into a **foramen supraorbitale**), transmitting the supraorbital arteries and nerve. Eminences, the **superciliary arches** (*arcus superciliares*) varying greatly in size and length, are seen immediately above the supraorbital border; they are continuous medially on the midline with a more or less prominent area, the **glabella**, the superior part of the bridge of the nose. The glabella is an important feature in distinguishing the skull of modern man from a fossil skull. The lateral end of the supraorbital border stretches out to form the **zygomatic process** (*processus zygomaticus*), which articulates with the zygomatic bone. A clearly detectable **temporal line** (*linea temporalis*) extends upward from the process; this line delimits the **temporal surface** (*facies temporalis*) of the squama. A small groove, **sagittal groove** (*sulcus sinus sagittalis superioris*) runs on the midline of the **internal surface** (*facies interna*) from the posterior border and is continuous at the lower end with the **frontal crest** (*crista frontalis*). These structures provide attachment for the dura mater. Depressions for the pacchionian granulations (arachnoid villi) are seen near the midline.

2 and 3. The **orbital parts** (*partes orbitales*) are two horizontal plates whose inferior concave surface faces the orbit. The superior surface faces the cranial cavity, and the posterior border articulates with the sphenoid bone. The superior cerebral surface bears marks of the brain, namely **cerebral ridges of cranium** (*juga cerebralis*) (BNA) (L *juga* yoke), and **digitate impressions** (*impressiones digitatae*). The **inferior surface** (*facies orbitalis*) forms the superior orbital wall and bears marks of adjacent accessories of the eye: the **lacrimal fossa** (*fossa glandulae lacrimalis*) near the zygomatic process; **trochlear fossa** (*fovea trochlearis*) near the supraorbital notch; and **trochlear spine** (*spina trochlearis*) where the trochlea for the tendon of one of the muscles of the eye is attached. The orbital parts are separated by the **ethmoid notch** (*incisura ethmoidalis*), which in an intact skull is filled by the ethmoid bone (Fig. 54).

4. The **nasal part** (*pars nasalis*) occupies the anterior part of the ethmoid notch on the midline. A projection ending as a sharp process, the **nasal spine** (*spina nasalis*), is found here; it helps to make up the nasal septum. On

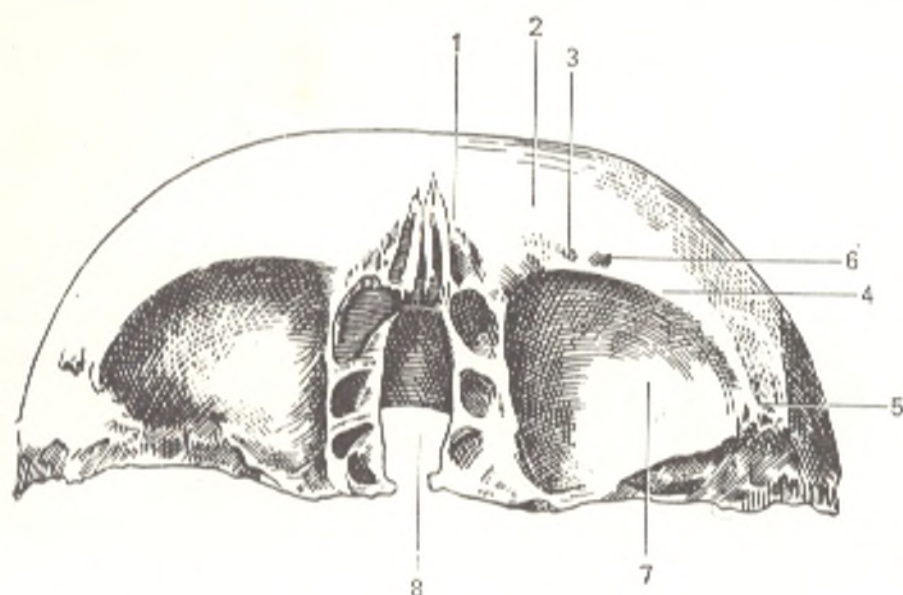


Fig. 54. Frontal bone (os frontale), inferior aspect.

1, glabella;  
2, arcus superciliaris;  
3, 4, and 5, margo supraorbitalis;

6, foramen supraorbitale;  
7, pars orbitalis;  
8, incisura ethmoidalis

either side of the spine are depressions, which serve as the superior wall for the sinuses of the ethmoid bone. To the front of them is an opening leading into the **frontal sinus** (*sinus frontalis*) located in the thickness of the bone to the back of the superciliary arches; the sinus varies greatly in size. The frontal sinus contains air and is separated by the **septum of the frontal sinus** (*septum sinuum frontalem*). Accessory frontal sinuses are sometimes encountered to the back of or between the main sinuses. Among all the skull bones, the frontal bone is most typical of man. It changed most in the process of evolution. In the earliest hominids (as in the anthropoid apes), it was sloped sharply backward, forming a forehead sloping to the back. Beyond the orbital narrowing it was sharply divided into the squama and the orbital parts. A continuous thick elevation stretched on the edge of the orbit from one zygomatic process to the contralateral one. The elevation diminished considerably in modern man, and only the superciliary arches remained. In accordance with the development of the brain, the squama straightened out to a vertical position. The frontal tubers developed at the same time; as the result the shape of the forehead changed from sloping to convex, lending the skull its characteristic appearance.

#### THE ETHMOID BONE

The **ethmoid bone** (*os ethmoidale*) is an unpaired bone usually described in the group of bones of the cerebral cranium, although most of it helps to make up the visceral cranium. The ethmoid bone is located centrally be-

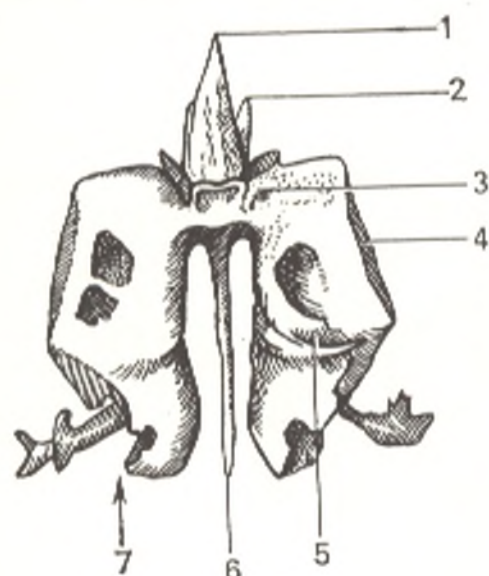


Fig. 55. Ethmoid bone (os ethmoidale), posterior aspect.

1 and 2, crista galli;  
3, lamina cribrosa;  
4, lamina orbitalis;  
5, concha superior;  
6, lamina perpendicularis;  
7, labyrinthi ethmoidales

tween the bones of the face and comes in contact with most of them to form the nasal cavity and orbit. In an intact skull it is covered by them. It develops in connection with the nasal capsule in cartilage. Formed of thin bone plates surrounding the air sinuses, it is light and fragile<sup>1</sup> (Fig. 55).

The bony plates of the ethmoid bone are arranged in the form of the letter "T" in which the vertical line is the **perpendicular plate** (*lamina perpendicularis*) and the horizontal is the **cribriform plate** (*lamina cribrosa*). From the lamina cribrosa, on either side of the perpendicular plate, hang the **ethmoidal labyrinths** (*labyrinthi ethmoidales*). As a result four parts are distinguished in the ethmoid bone.

1. **Lamina cribrosa** is a rectangular plate fitting into the ethmoid notch of the frontal bone. It is perforated by small openings like a sieve, hence its name (Gk *ethmos* sieve, *eidos* form). These perforations transmit the branches of the olfactory nerve (about 30 of them). The crista galli projects upward from the midline of the cribriform plate (for attachment of the dura mater).

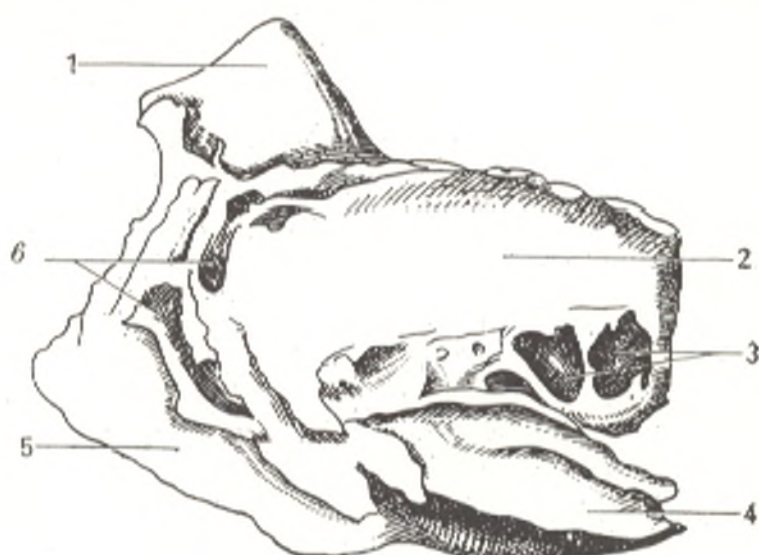
2. **Lamina perpendicularis** is a part of the nasal septum.

3 and 4. **Labyrinthi ethmoidales** make up a paired complex of bony air cells, **cellulae ethmoidales**, covered laterally by a thin **orbital plate** (*lamina orbitalis*), which forms the medial wall of the orbit (Fig. 56). The upper border of the orbital plate articulates with the orbital part of the frontal bone, the anterior border with the lacrimal bone, the posterior border with the orbital process of the palatine bone, and the inferior border with the upper jaw; all these bones cover the laterally located cellulae ethmoidales. On the medial surface of the labyrinth are two **nasal conchae** (*conchae nasales superior* and *media*), although sometimes there is a third, **highest nasal concha** (*concha nasalis suprema*).

<sup>1</sup> The ancient Egyptians made use of these properties when they removed the brain from the skull through the ethmoid bone for embalment.

Fig. 56. Ethmoid bone (os ethmoidale), seen from the left.

- 1, crista galli;  
 2, lamina orbitalis;  
 3, cellulae ethmoidales posteriores;  
 4, concha ethmoidalis media;  
 5, lamina perpendicularis;  
 6, cellulae ethmoidales anteriores;



The **conchae** (Gk *konche* shell) are thin, curved plates; as the result of such a shape, the surface of the nasal mucosa covering them increases.

## THE BONES OF THE VISCERAL CRANIUM

The bones of the visceral cranium form bony receptacles for the organs of sense (vision, olfaction) and for the initial parts of the alimentary (oral cavity) and respiratory (nasal cavity) systems, which determines their structure. They reflect the changes which occurred in the soft tissues of the head in the process of humanization of the ape, i.e. the leading role of labour, the partial transference of the grasping function from the jaws to the hands, which became the tools of work, the development of articulate speech, the development of the brain and its tools, the organs of sense, and, finally, the preparation of food which made the work of the masticatory apparatus easier.

### THE UPPER JAW BONE

The upper jaw bone (*maxilla*) is a paired bone of a complex structure determined by the diversity of its functions: it takes part in the formation of cavities for the organs of sense, the orbit and nose, in the formation of the septa between the cavities of the nose and mouth, and in the work of the masticatory apparatus (Fig. 57).

With the development of man's working activity, the function of grasping was transferred from the jaws (where it is in animals) to the hands, which led to a diminution of the maxilla. The development of the faculty of speech made the structure of the human jaw finer as well. All this determines the structure of the upper jaw (in animals, os maxillare), which develops in connective tissue.

The maxilla consists of a body and four processes.

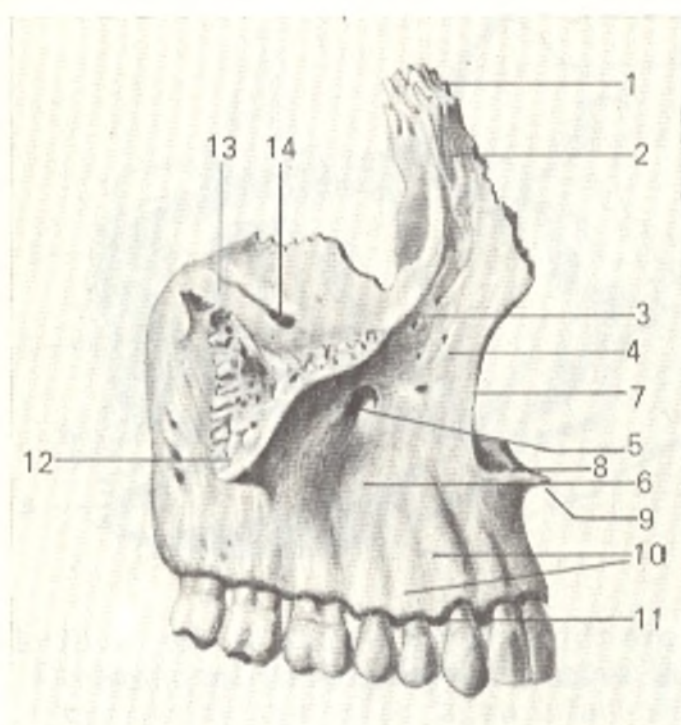


Fig. 57. Right upper jaw (maxilla), lateral view.

- 1, processus frontalis;
- 2, crista lacrimalis anterior;
- 3, margo infraorbitalis;
- 4, facies anterior;
- 5, foramen infraorbitale;
- 6, fossa canina;
- 7, incisura nasalis;
- 8, processus palatinus;
- 9, spina nasalis anterior;
- 10, juga alveolaria;
- 11, processus alveolaris;
- 12, processus zygomaticus;
- 13, facies orbitalis;
- 14, sulcus infraorbitalis continuous with canalis infraorbitalis

A. The body (*corpus maxillae*) contains a large maxillary air sinus (*sinus maxillaris* s. *antrum Highmori*, BNA) (hence highmoritis, inflammation of the maxillary sinus), which communicates with the nasal cavity by a wide opening, the maxillary hiatus (*hiatus maxillaris*). The following four surfaces are distinguished on the body.

The anterior surface (*facies anterior*), which was flat in the Neanderthal man, is concave in modern man since his food is prepared and the function of mastication is consequently weaker. Inferiorly it is continuous with the alveolar process, in which a series of depressions (*juga alveolaria*) between the ridges of the tooth roots are seen. The ridge corresponding to the canine tooth is most pronounced. The canine fossa (*fossa canina*) is above and lateral to it. Superiorly the anterior surface of the maxilla is separated from the orbital surface by the infraorbital margin (*margo infraorbitalis*). Immediately below it is the infraorbital foramen (*foramen infraorbitale*) through which the infraorbital nerve and artery leave the orbit. The medial border of the anterior surface is formed by the nasal notch (*incisura nasalis*) whose edge extends forward to form the anterior nasal spine (*spina nasalis anterior*).

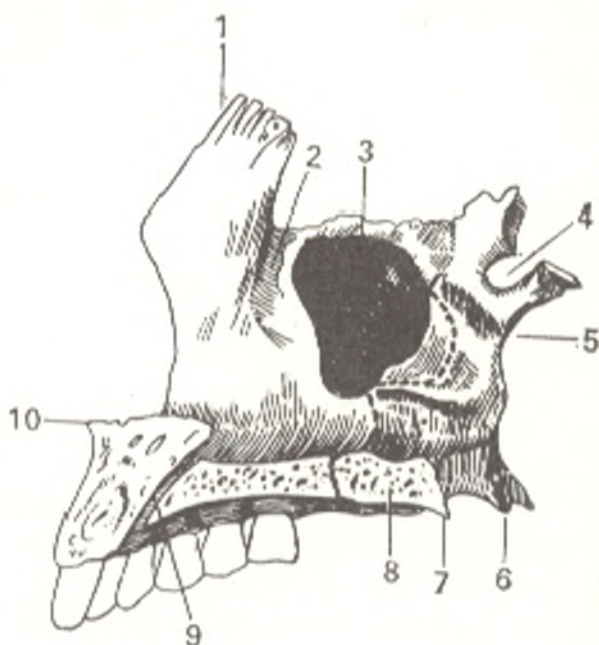
The infratemporal surface (*facies infratemporalis*) is separated from the anterior surface by the zygomatic process and carries several small perforations (transmitting the nerves and vessels to the upper teeth), the maxillary tuber (tuberosity of maxilla) (*tuber maxillae*) and the greater palatine sulcus (*sulcus palatinus major*).

The nasal surface (*facies nasalis*) is continuous inferiorly with the superior surface of the palatine process (Fig. 58). The conchal crest (*crista conchalis*) is seen on it. To the back of the frontal process is the nasolacrimal groove (*sulcus lacrimalis*) which, with the lacrimal bone and the inferior nasal concha, is converted into the nasolacrimal canal (*canalis nasolacrimalis*)



Fig. 58. Palatine bone (os palatinum) and upper jaw (maxilla), medial aspect.

- 1, processus frontalis;
- 2, sulcus lacrimalis;
- 3, hiatus maxillaris;
- 4, incisura sphenopalatina;
- 5, lamina perpendicularis;
- 6, processus pyramidalis;
- 7, spina nasalis posterior;
- 8, lamina horizontalis;
- 9, canalis incisivus;
- 10, spina nasalis anterior



by means of which the orbit communicates with the inferior nasal concha. Still farther back is a large opening that leads to the maxillary sinus. In an intact skull this opening is made somewhat smaller by parts of bones overlapping it, namely the lacrimal, ethmoid, and palatine bones and the inferior concha.

The smooth, flat orbital surface (*facies orbitalis*) is triangular. On its medial border, behind the frontal process, is the lacrimal notch (*incisura lacrimalis*) lodging the lacrimal bone. The infraorbital groove (*sulcus infraorbitalis*) originates near the posterior border of the orbital surface and is converted anteriorly into the infraorbital canal (*canalis infraorbitalis*), which opens onto the anterior surface of the maxilla by means of the infraorbital foramen mentioned above. The alveolar canals (*canales alveolares*) arise from the infraorbital canal; they transmit nerves and vessels passing in the thickness of the anterior maxillary wall to the anterior teeth.

B. Processes. 1. The frontal process (*processus frontalis*) projects upward and joins the pars nasalis of the frontal bone. Its lateral surface is divided into two parts by a vertical lacrimal crest (*crista lacrimalis anterior*), which is continuous downward with the infraorbital margin. The medial surface carries the ethmoidal crest (*crista ethmoidalis*) for attachment of the middle nasal concha.

2. The alveolar process (*processus alveolaris*) carries on its inferior border, alveolar arch (*arcus alveolaris*), dental sockets (*alveoli dentales*) for the eight upper teeth; the sockets are separated by *septa interalveolaria*.

3. The palatine process (*processus palatinus*) forms most of the hard bony palate (*palatum osseum*) by joining the contralateral process in the midline. Where they meet, the nasal crest (*crista nasalis*) rises on the superior surface facing the nasal cavity and articulates with the inferior edge of the vomer. Near the anterior end of the nasal crest on the superior surface is an opening that leads into the incisive canal (*canalis incisivus*). The superior

surface of the process is smooth, whereas the inferior surface, facing the oral cavity, is rough (impressions of the mucosal glands) and carries longitudinal palatine grooves (*sulci palatini*) lodging the nerves and vessels. The incisive suture (*sutura incisiva*) is often seen in the anterior part. It delimits the os incisivum which fuses with the maxilla. In many animals this bone exists as an independent bone (*os intermaxillare*), but in man it is rarely encountered.

4. The zygomatic process (*processus zygomaticus*) articulates with the zygomatic bone to form a thick support through which pressure produced during mastication is transmitted to the zygomatic bone.

### THE PALATINE BONE

The palatine bone (*os palatinum*) is a paired bone. Though it is small, it nevertheless contributes to the formation of some of the cranial cavities, namely the cavities of the nose, mouth, orbits, and the pterygopalatine fossa. This determines its peculiar structure: it is a thin bone consisting of two plates uniting at a right angle and supplementing the maxilla (Figs. 58 and 59).

1. The horizontal plate (*lamina horizontalis*) complements the maxillary palatine process posteriorly to form the hard palate (*palatum osseum*). Its medial border meets the medial border of the contralateral bone to form the

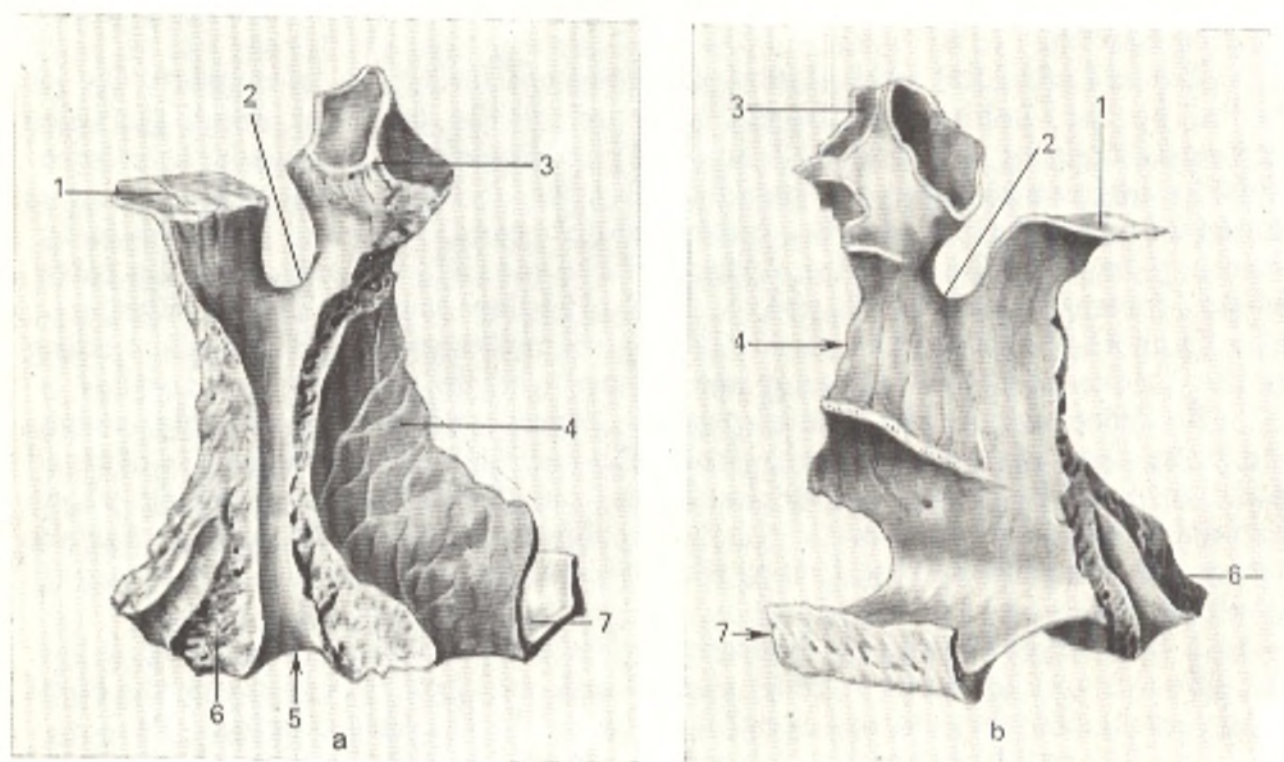


Fig. 59. The right palatine bone (*os palatinum*), external (a) and internal (b) aspects.

- 1, processus sphenoidalis;  
2, incisura sphenopalatina;  
3, processus orbitalis;  
4, lamina perpendicularis;

- 5, sulcus palatinus major;  
6, processus pyramidalis;  
7, lamina horizontalis

**nasal crest** (*crista nasalis*). On the inferior surface of the horizontal plate is the **greater palatine foramen** (*foramen palatinum majus*), through which palatine vessels and nerves leave the canalis palatinus major (see below).

2. The **perpendicular plate** (*lamina perpendicularis*) adjoins the nasal surface of the maxilla. Along its lateral surface runs the **greater palatine sulcus** (*sulcus palatinus major*), which together with the maxillary sulcus of the same name forms the canalis palatinus major. The medial surface has two crests for two nasal conchae, the middle (*crista ethmoidalis*) and the inferior (*crista conchalis*). The palatine bone has three **processes**. One of them, the **pyramidal process** (*processus pyramidalis*) projects backward and laterally from the junction of the horizontal and perpendicular plates. In an intact skull the pyramidal process fits into the pterygoid fissure of the sphenoid bone. Nerves and vessels penetrate it vertically through the **lesser palatine canals** (*canales palatini minores*). The other two processes project from the superior edge of the perpendicular plate and form the **sphenopalatine notch** (*incisura sphenopalatina*), which meets the body of the sphenoid bone to form the **sphenopalatine foramen** (*foramen sphenopalatinum*) transmitting the sphenopalatine vessels and nerves. The anterior process forms the posterior corner of the orbit and is therefore known as the **orbital process** (*processus orbitalis*); the posterior process adjoins the inferior surface of the body of the sphenoid bone and is called the **sphenoid process** (*processus sphenoidalis*).

#### THE INFERIOR NASAL CONCHA

The **inferior nasal concha** or **inferior turbinate bone** (*concha nasalis inferior*) is a paired bone. As distinct from the superior and middle nasal conchae, which are components of the ethmoid bone, the inferior nasal concha is an independent bone. It is a thin, curled plate of bone whose upper edge is attached to the lateral wall of the nasal cavity; it isolates the middle nasal meatus from the inferior meatus. Its inferior edge is free, while the upper edge articulates with the conchal crests of the maxilla and the palatine bone.

#### THE NASAL BONE

The **nasal bone** (*os nasale*) joins the contralateral bone to form the ridge of the nose at its root. In man the nasal bone is underdeveloped in comparison to that in animals.

#### THE LACRIMAL BONE

The **lacrimal bone** (*os lacrimale*), a paired bone (Fig. 60), is a thin plate found in the medial wall of the orbit immediately behind the frontal process of the maxilla. Its lateral surface carries the **crest of the lacrimal bone** (*crista lacrimalis posterior*). To the front of the crest runs the **lacrimal groove** (*sulcus lacrimalis*), which meets the sulcus of the frontal process of the maxil-

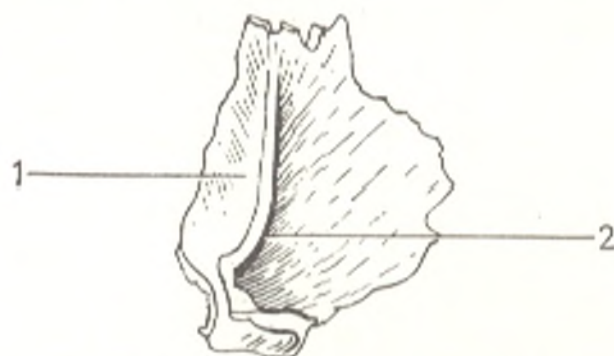


Fig. 60. Left lacrimal bone (*os lacrimale*), external aspect.

1, *sulcus lacrimalis*; 2, *crista lacrimalis posterior*

la to form the **fossa of the lacrimal sac** (*fossa sacci lacrimalis*). The lacrimal bone of man is similar to that of anthropoid apes, which is evidence that these apes are closely related to hominids.

#### THE VOMER

The **vomer** (Fig. 61), an unpaired bone, is an irregularly quadrangular plate, which resembles a plowshare (hence its name: *L vomer* plowshare) and forms part of the bony nasal septum. Its superior border is split into two **wings** (*alae vomeris*), which fit over the rostrum of the sphenoid bone. The upper half of the anterior edge articulates with the perpendicular plate of the ethmoid bone, and the lower part with the cartilaginous nasal septum. The inferior edge articulates with the nasal crests of the maxilla and palatine

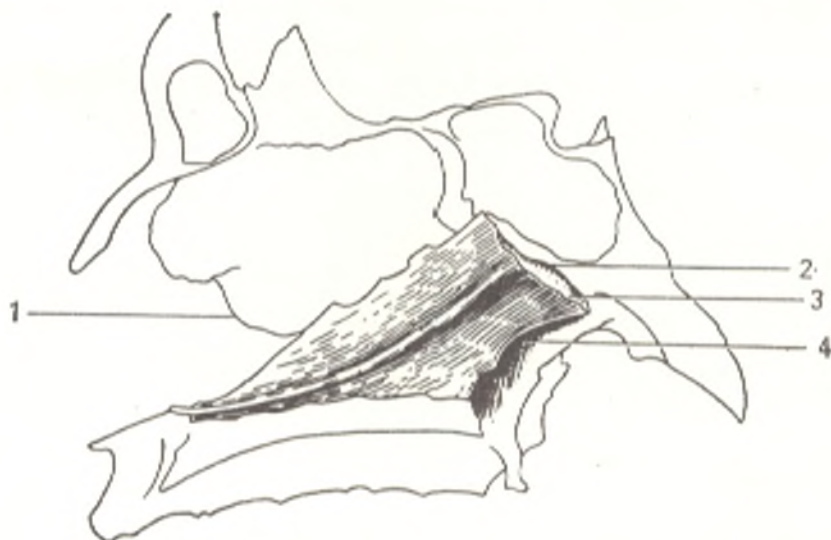

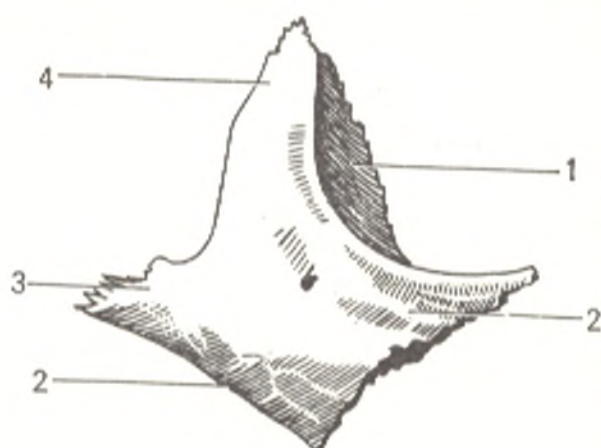
Fig. 61. Vomer.

1, *lamina perpendicularis ossis ethmoidalis*;  
2, *margo superior vomeris*;

3, *alae vomeris*;  
4, *margo posterior vomeris*

Fig. 62. Right zygomatic bone (*os zygomaticum*), lateral aspect.

- 1, *facies orbitalis*;  
2, *facies lateralis*;  
3, *processus temporalis*;  
4, *processus frontalis*



bone. The free, posterior edge is the posterior border of the bony nasal septum separating the posterior openings of the nasal cavity, choanae,<sup>1</sup> by means of which the nasal cavity communicates with the nasopharynx.

### THE ZYGOMATIC BONE

The **zygomatic bone** (*os zygomaticum*) (Fig. 62) is a paired bone, the strongest bone of the skull. The zygomatic bone is important to the architecture of the face because it connects the frontal and temporal bones and the maxilla by articulating with their zygomatic processes and thus strengthening the bones of the visceral skull in relation to the cerebral skull. It is also an extensive surface for the origin of the masseter muscle. According to the location of the bone, three surfaces and two processes are distinguished in it. The **lateral surface** (*facies lateralis*) is shaped like a four-point star and bulges slightly. The smooth posterior surface faces the temporal fossa and is called the **temporal surface** (*facies temporalis*). The third **orbital surface** (*facies orbitalis*) takes part in the formation of the orbital walls. The **superior frontal process** of the zygomatic bone (*processus frontalis*) articulates with the zygomatic process of the frontal bone and the greater wing of the sphenoid bone. An eminence for attachment of the muscles and ligaments of the eyelids is often found on its orbital surface. The **lateral temporal process** (*processus temporalis*) articulates with the zygomatic process of the temporal bone to form the **zygomatic arch**, the site of origin of the masseter muscle.

### THE LOWER JAW BONE

The **lower jaw bone** or the **mandible** (*mandibula*) is a mobile skull bone. Its horseshoe shape is determined both by its function (the most important part of the masticatory apparatus) and by its development from the first visceral (mandibular) arch whose shape it retains to a certain extent. In

<sup>1</sup> L. *choanos* a crucible shaped like a funnel. It was believed in the past that brain secretions flowed into the cavity of the nose through this structure.

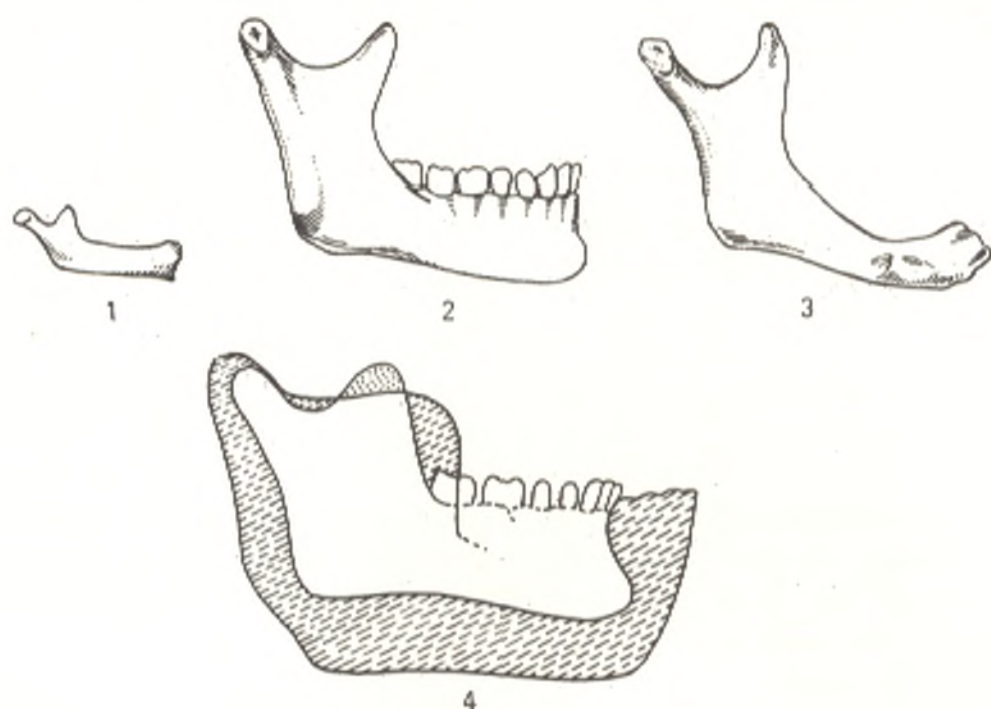


Fig. 63. Mandible.

1, of a newborn;  
2, of a 30-year-old male;  
3, of a 80-year-old male;

4, the mandible of modern man drawn on the mandible of the Heidelberg man. Its diminution with the formation of the chin is evident

mammals, including the lowest primates, the mandible is a paired bone. In accordance with this, in man the mandible develops from two germs which, growing gradually, fuse in the second year after birth into an unpaired bone; the mark of the fusion of the two halves, however, remains (symphysis mandibulae). The bone develops in connective tissue. The masticatory apparatus consists of a passive part, i.e. the teeth, concerned with mastication, and an active part, i.e. the muscles. Accordingly, the mandible consists of a horizontal part or **body** (*corpus mandibulae*), which carries the teeth, and a vertical part in the form of two **rami mandibulae**, which serve for the formation of the temporomandibular joint and for attachment of the muscles of mastication. The horizontal and the vertical parts meet at an angle called the **angle of the mandible** (*angulus mandibulae*), on the external surface of which the masseter muscle is inserted into the **masseteric tuberosity** (*tuberositas masseterica*). On the inner surface of the angle is the **pterygoid tuberosity** (*tuberositas pterygoidea*) for insertion of another muscle of mastication, m. pterygoideus medialis.

The activity of the masticatory apparatus, therefore, has an effect on the size of this angle. It is close to 150 degrees in the newborn, diminishes to 130-110 degrees in an adult, and again increases in old age with the loss of teeth and weakening of the masticating act. Comparison of apes with various hominid species also reveals a gradual increase of the *angulus mandibulae* with weakening of the act of mastication: 90 degrees in the anthropoid ape,

95 degrees in the Heidelberg man, 100 degrees in the Neanderthal man, and 130 degrees in modern man (Fig. 63).<sup>1</sup>

The structure and relief of the body of the mandible are determined by the teeth and by the fact that the mandible takes part in the formation of the mouth. For instance, the upper, **alveolar part** of the body (*pars alveolaris*) bears teeth as a consequence of which its border, the **alveolar arch** (*arcus alveolaris*) has sockets for the teeth (*alveoli dentales*), with **interalveolar septa** (*septa interalveolaria*) and corresponding depressions on the external surface (*juga alveolaria*). The rounded massive and thick inferior border of the body forms the **base of the mandible** (*basis mandibulae*). At old age when the teeth are lost, the alveolar part atrophies and the whole body of the mandible becomes thin and low. The ridge on the symphysis on the midline of the body is continuous with a triangular **mental protuberance** (*protuberantia mentalis*), the presence of which is characteristic of modern man. Among all mammals only man, and modern man at that, has a pronounced **chin**. The anthropoid ape, the Pithecanthropus man, and the Heidelberg man have no mental protuberance; their jaw instead has a border that curves to the back. The Neanderthal man also lacks a protuberance, but the mandibular border here is rectangular. A true chin forms only in modern man.

On each side of this protuberance is a **mental tubercle** (*tuberculum mentale*). On the lateral surface of the body, in the space between the first and second premolars, is the **mental foramen** (*foramen mentale*), which is an opening of the **mandibular canal** (*canalis mandibulae*), transmitting a nerve and vessels. An **oblique line** (*linea obliqua*) runs to the back and upward from the mental tubercle. Two **mental spines** (*spinae mentales*) project from the inner surface of the symphysis; these are the sites of attachment of the tendon of the genioglossus muscle. In anthropomorphic apes the spine here is replaced by a fossa because the genioglossus muscle is attached not by a tendon but by muscular tissue. All transient forms were found in a series of fossil skulls, from those with a fossa typical of the skull of apes (due to muscular attachment of *m. genioglossi*) and without a chin to those with a spine determined by attachment of the muscle by means of a tendon and with a protruding chin. A change in the means of attachment of the genioglossus muscle from muscular to tendinous thus caused the formation of a spine and the consequent development of a chin. Since the tendinous method of attachment of the tongue muscles was conducive to the development of articulate speech, the transformation of the bone relief in the region of the chin, a purely human feature, should, therefore, also be associated with the faculty of speech. On both sides of the mental spine, nearer to the inferior border of the mandible is the site for attachment of the digastric muscle, the **digastric fossa** (*fossa digastrica*). Further to the back is the **mylohyoid line** (*linea mylohyoidea*), running backward and upward; it serves for attachment of the mylohyoid muscle (Fig. 64).

<sup>1</sup> The brief anthropological information cited in this book was taken from the textbooks of M. A. Gremyatsky and V. V. Ginzburg (in Russian).

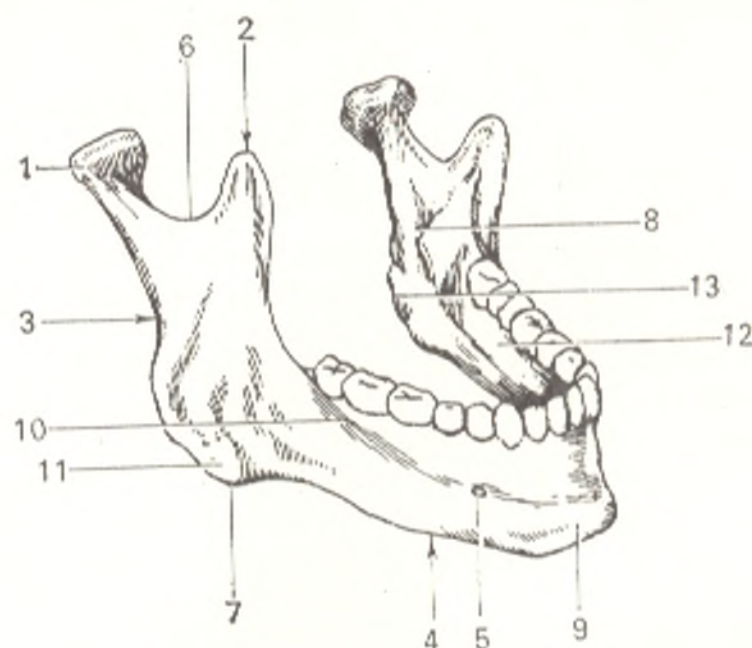


Fig. 64. Mandible (mandibula).

- |                           |                              |
|---------------------------|------------------------------|
| 1, processus condylaris;  | 8, foramen mandibulae;       |
| 2, processus coronoideus; | 9, protuberantia mentalis.   |
| 3, ramus mandibulae;      | 10, linea obliqua;           |
| 4, corpus mandibulae;     | 11, tuberositas masseterica; |
| 5, foramen mentale;       | 12, linea mylohyoidea;       |
| 6, incisura mandibulae;   | 13, tuberositas pterygoidea  |
| 7, angulus mandibulae;    |                              |

The **ramus of the mandible** (*ramus mandibulae*) rises on each side from the posterior part of the body of the mandible. On its inner surface is the **mandibular foramen** (*foramen mandibulae*), leading into the mandibular canal mentioned above. The medial edge of this foramen projects as the **lingula of the mandible** (*lingula mandibulae*), to which is attached the sphenomandibular ligament; the lingula is developed more in man than in apes. The **mylohyoid groove** (*sulcus mylohyoideus*) originates behind the lingula and runs downward and forward; it lodges the mylohyoid nerve and vessels. Superiorly the ramus of the mandible terminates as two processes, anterior **coronoid process** (*processus coronoideus*) (it forms under the effect of traction exerted by the strong temporal muscle) and a posterior **condylar process** (*processus condylaris*). A crest for the attachment of the buccinator muscle (*crista buccinatoria*) runs on the inner surface of the ramus upward from the surface of the alveoli of the last molars towards the coronoid process.

The **condylar process** has a **head** (*caput mandibulae*) and a **neck** (*collum mandibulae*). On the anterior surface of the neck is the **pterygoid pit** (*fovea pterygoidea*) for attachment of the lateral pterygoid muscle. The head of the condylar process is stretched out in the transverse direction, but the medial end of its axis slants to the back so that the longitudinal axes of both heads, when continued, intersect at the anterior border of the foramen magnum at an angle of 140-150 degrees.



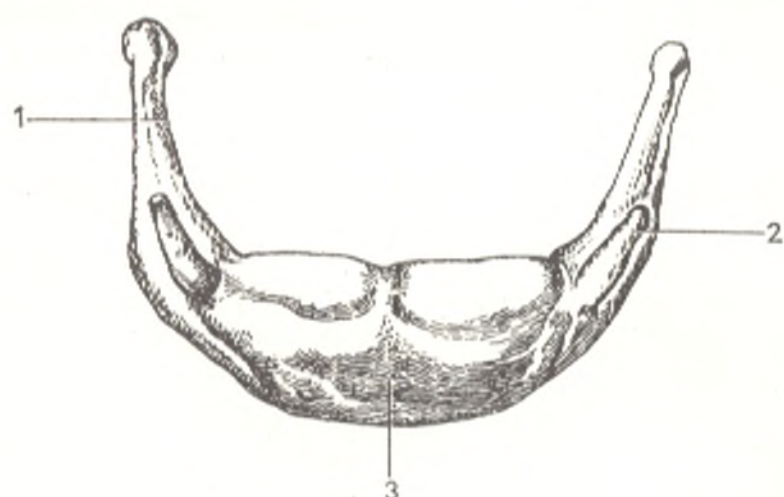


Fig. 65. Hyoid bone (os hyoideum), anterior aspect.

1, cornu majus;  
2, cornu minus;  
3, corpus

In summary of the description of the mandible, it should be pointed out that its shape and structure characterize modern man. During the process of labour, which was responsible for the transformation of the ape into a human being, the function of grasping changed from the jaws to the hands which became organs of labour. Man's diet of prepared food made the work of his masticatory apparatus easier. All this led to diminished activity of the teeth and sharp reduction of the lower jaw, as compared with that of anthropoid apes and even with the lower jaw of fossil humans, for instance, with that of the Heidelberg man. At the same time, articulate speech developed in man; it was associated with increased and fine work of the tongue muscles attached to the mandible. The mental region of the mandible which is connected with these muscles, functioned intensely and withstood the factors of regression. Spines and a protuberance formed on it. Their formation was also promoted by distension of the mandibular arch as a consequence of the increased transverse dimension of the cerebral cranium under the effect of the growing brain. Thus, the shape and structure of man's lower jaw formed under the effect of the development of labour, articulate speech, and the brain, i.e. properties characteristic of man.

#### THE HYOID BONE

The hyoid bone (*os hyoideum*) is situated at the base of the tongue, between the mandible and the larynx (Fig. 65). It belongs to the visceral skull and develops from the hyoid and first branchial arches. In accordance with this development, it acquires the shape of an arch. It consists of a body (*corpus*) and two pairs of horns (*cornua*). The greater horns (*cornua majora*) are continued from both ends of the body and extend backwards and somewhat laterally; they are at first joined to the body by cartilage which later is replaced by bone. The lesser horns (*cornua minora*) arise from the junction of the body and the greater wings and project upward and backward. The lesser horns ossify only in the elderly and fuse with the body after the age of 50. The hyoid bone is suspended from the base of the

skull by means of two long fibrous cords, **stylohyoid ligaments** (*lig. stylohyoideum*), stretching from the lesser horns to the styloid processes of the temporal bones.

## ARTICULATIONS OF THE SKULL BONES

The bones of the skull articulate mainly by **syndesmosis**: manifested by **sutures** on the skulls of adults and **interosteal membranes** (*fontanelles*) on the skull of the newborn, which reflects the development of the bones of the vault in connective tissue and its principal function of protection. Almost all bones forming the vault of the skull, with the exception of the squama of the temporal bone, articulate by means of a **serrate suture** (*sutura serrata*). The squama of the temporal bone joins with the squamous border of the parietal bone by means of a **squamous suture** (*sutura squamosa*). The bones of the visceral skull fit together at relatively smooth borders to form a **plane suture** (*sutura plana*). The difference in the type of the sutures is associated with the different mechanisms of the actions exerted on the separate parts of the skull (the traction or pressure of muscles, the weight of the visceral skull, etc.). The sutures are designated by the names of the two articulating bones, e.g. *sutura sphenofrontalis*, *sphenoparietalis*, etc. The base of the

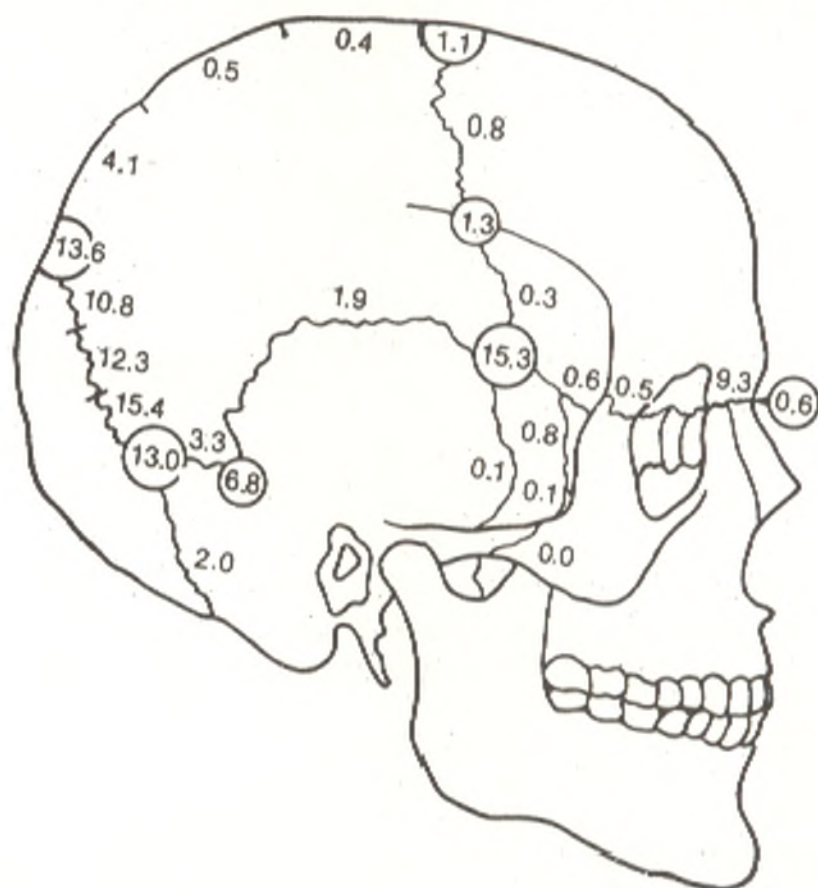


Fig. 66. Irregularly encountered bones of the fontanelles and sutures of the skull (after V. S. Speransky) (the figures designate the incidence, per cent)

skull has **synchondroses** of fibrous cartilage lodged in the fissures between the bones: **synchondrosis petrooccipitalis** in the petrooccipital fissure between the pyramid of the temporal bone and the basilar part of the occipital bone; **synchondrosis sphenopetrosa** is the sphenopetrosal fissure. The **sphenooccipital synchondrosis** (*synchondrosis sphenooccipitalis*) between the body of the sphenoid bone and the basilar part of the occipital bone and synchondroses between the four parts of the occipital bone are encountered at early age. The synchondroses in the base of the skull are remnants of cartilaginous tissue in which the bones of the base develop, which is associated with its functions of support, protection, and movement. Besides the sutures and synchondroses always found in man's skull some persons have accessory sutures: a **frontal suture** (*sutura metopica*) (Gk *metopon* forehead of L *glabella*), in non-fusion of both halves of the squama of the frontal bone (in 9.3 per cent); sagittal and transverse sutures in the squama of the occipital bone, sometimes (0.55 per cent) with full separation of the squama into an upper and lower part, in which case the upper part is called the **interparietal bone** (*os interparietale*) on account of its position; separation of the parietal bone at the squama of the temporal bone (0.1 per cent) or at the greater wing of the sphenoid bone (1.1 per cent); synchondrosis between the squama and the lateral parts of the occipital bone (4 per cent); and a mastosquamous synchondrosis (0.5 per cent).

Skull bones are sometimes encountered in the sutures; these are the bones of the fontanelles and bones of the sutures, sutural (wormina) bones, *ossa suturarum Wormiana*, the incidence and location of which are shown in Fig. 66. During X-ray examination all these irregular bones and articulations of bones must be distinguished from injuries to the skull bones.

The paired temporomandibular articulation joining the mandible with the base of the skull is the only diarthrosis of the skull.

## THE TEMPOROMANDIBULAR JOINT

The **temporomandibular joint** (*articulatio temporomandibularis*) is formed by the head of the mandible and the mandibular fossa of the temporal bone (Fig. 67). The articulating surfaces are complemented by a fibrous **articular disc** (*discus articularis*) located between them. The edges of the disc are joined to the articular capsule as a result of which the joint cavity is separated into two isolated compartments. The articular capsule is attached along the border of the mandibular fossa up to the petrotympanic fissure and thus encloses the articular tubercle and embraces the neck of the mandible inferiorly. Near the temporomandibular joint are three ligaments only one of which, the **lateral ligament** (*lig. laterale*), is directly related to the joint. It passes obliquely backward on the lateral side of the joint from the zygomatic process of the temporal bone to the neck of the condylar process of the mandible. The lateral ligament prevents excessive movement of the articular head to the back. The remaining two ligaments (*lig. sphenomandibulare* and *lig. stylomandibulare*) are at a distance from the joint and are actually not

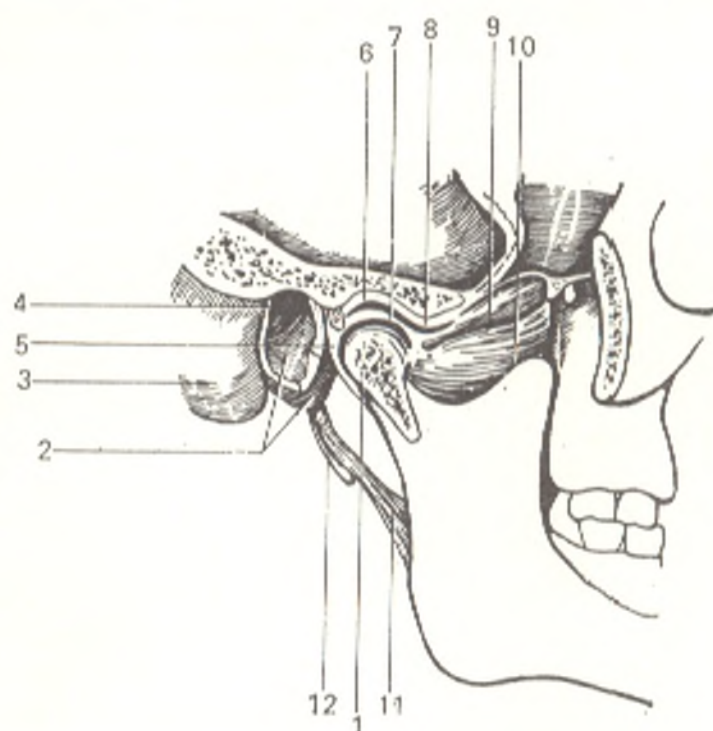


Fig. 67. Temporomandibular joint (articulatio temporomandibularis) (sagittal section through the cavity of the joint).

- 1, proc. condylaris;
- 2, pars tympanica ossis temporalis;
- 3, processus mastoideus;
- 4, porus et meatus acusticus externus;
- 5, capsula articularis (opened);
- 6, fossa mandibularis;
- 7, discus articularis;
- 8, tuberculum articulare;
- 9 and 10, m. pterygoideus lateralis;
- 11, lig. stylomandibulare;
- 12, processus styloideus

ligaments but artificially separated areas of fascia, which form a loop-like structure to help to suspend the mandible.

Both temporomandibular joints function simultaneously and are therefore a single combined articulation from the mechanical standpoint. The temporomandibular articulation is a condyloid joint (Davies), but because of the articular disc, it permits movements in three directions. The mandible makes the following movements: (1) downward and upward movements with opening and closure of the mouth; (2) forward and backward movements; (3) lateral movements (rotation of the mandible to the right and to the left as it occurs in chewing). The first of these movements is made in the lower compartment of the joint, between the articular disc and the articular head. When the mandible moves downward, its heads first glide together with the discs (first phase) and then rotate on the transverse axis passing through both heads (second phase). To open the mouth wide, the heads glide forward and downward with the discs onto the articular tubercles that prevent dislocation of the jaw.

Movements of the second type occur in the upper compartment of the joint, also in two phases: the head glides forward with the disc to the articular tubercle (phase one) and then glides on the tubercle and at the same time rotates about the transverse axis (phase two). In lateral movements (third type) the articular head and disc of only one side leave the articular fossa and approach the articular tubercle, while the contralateral head remains in the articular fossa and rotates on the vertical axis.

*Vessels and nerves.* The joint is supplied with nutrients by a. maxillaris. The venous blood drains into the venous network (*rete articulare mandibulae*), surrounding the temporomandibular joint and from there into v. retromandibularis.

*Lymph* drains along the deep lymphatics into *nodi lymphatici parotidei* and then into the deep cervical nodes. *Innervation* is accomplished by *n. auriculotemporalis* (from the third branch of *n. trigeminus*).

## THE SKULL AS A WHOLE

The **external surface of the skull**. Part of the external surface of the skull examined from the front (*norma facialis s. frontalis*) consists of the forehead superiorly and two orbits, with the piriform aperture of the nose between them; below the orbits and lateral to the opening of the nose is the anterior surface of the upper jaw with the upper teeth. The orbit is bounded laterally by the zygomatic bone, which articulates both with the frontal bone and with the maxilla. Below is attached the mobile lower jaw carrying the lower teeth on its superior border.

The **orbits, or eyesockets (*orbitae*)** contain the organ of vision and are cavities in the shape of somewhat rounded, four-sided pyramids. The base of the pyramid corresponds to the **opening into the orbit (*aditus orbitae*)**, while the apex is directed backward and medially. The **medial orbital wall (*paries medialis*)** is formed by the frontal process of the maxilla, the lacrimal bone, the orbital plate of the ethmoid bone, and the body of the sphenoid bone to the front of the optical canal. The orbital surfaces of the zygomatic bone and greater wings of the sphenoid bone form the **lateral wall (*paries lateralis*)**. The **superior wall (*paries superior*)** or the roof of the orbit is formed by the orbital part of the frontal bone and lesser wings of the sphenoid bone; the **inferior wall (*paries inferior*)** or floor of the orbit is made up of the zygomatic bone and maxilla, and in the posterior portion by the orbital surface of the orbital process of the palatine bone. Two openings are seen at the apex of the pyramid: a large lateral opening, the **superior orbital fissure (*fissura orbitalis superior*)**, and a smaller round medial opening, the **optic canal (*canalis opticus*)**; by means of both openings the orbit communicates with the cranial cavity. In the corner formed by the lateral and inferior orbital walls is the **inferior orbital fissure (*fissura orbitalis inferior*)**, which is bounded laterally by the greater wing of the sphenoid bone and medially by the edge of the maxilla; its posterior end leads into the pterygopalatine fossa and the anterior end into the infratemporal fossa. The **fossa of the lacrimal sac (*fossa sacci lacrimalis*)** is in the anterior part of the medial wall; it is bounded by the frontal process of the maxilla in front and by the lacrimal bone in the back and leads into the **nasolacrimal canal (*canalis nasolacrimalis*)**. The other end of the lacrimal canal opens into the inferior nasal meatus. Further to the back, in the suture between the frontal and ethmoid bones, are two openings, the **anterior and posterior ethmoidal foramina (*foramina ethmoidale anterius and posterius*)**, transmitting the anterior and posterior ethmoidal vessels and nerves. The anterior foramen leads into the cranial cavity, the posterior foramen into the nasal cavity.

The **anterior bony aperture of the nose (*apertura piriformis nasi*)** is below and partly between the orbits. Laterally and inferiorly it borders on the maxilla and superiorly and partly laterally on the free edges of the nasal

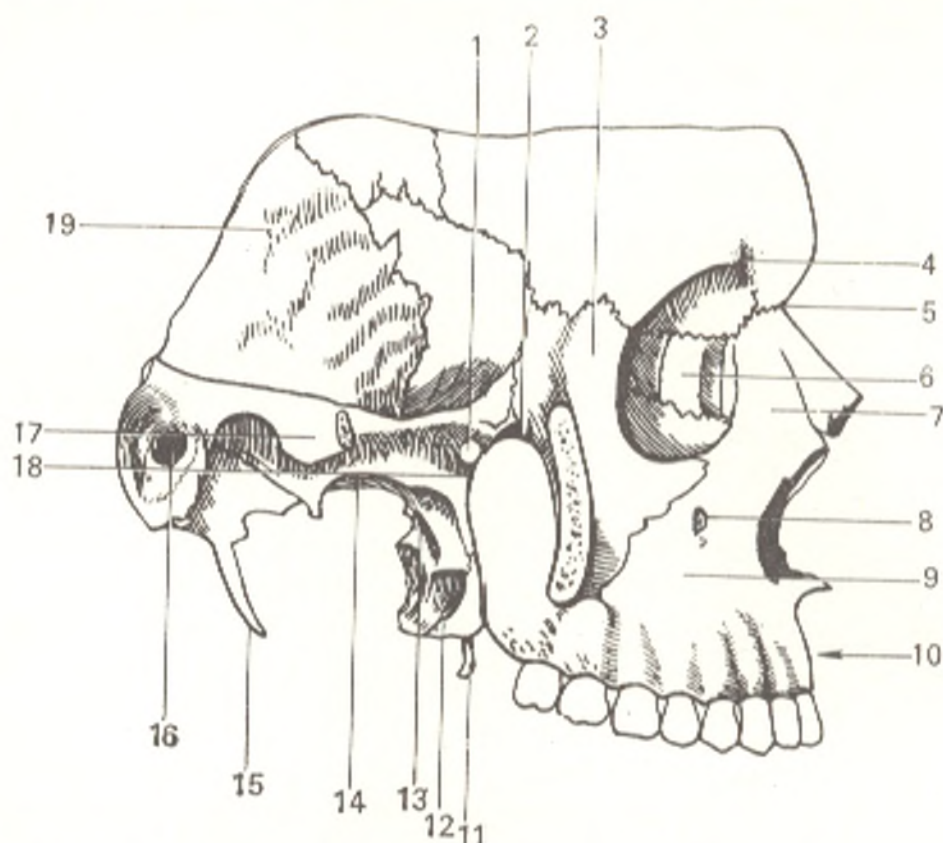


Fig. 68. Temporal, infratemporal, and pterygopalatine fossae (fossa temporalis, fossa infratemporalis, fossa pterygopalatina), seen from the right (with the zygomatic arch removed).

- |  |   |
|--|---|
| 1, foramen sphenopalatinum;              | 12, processus pyramidalis ossis palatini; |
| 2, fissura orbitalis inferior;           | 13, lamina lateralis proc. pterygoidei;   |
| 3, processus frontalis ossis zygomatici; | 14, foramen ovale;                        |
| 4, incisura supraorbitalis;              | 15, proc. styloideus;                     |
| 5, pars nasalis ossis frontalis;         | 16, meatus acusticus externus;            |
| 6, os lacrimale;                         | 17, proc. zygomaticus ossis temporalis;   |
| 7, fossa sacci lacrimalis;               | 18, fossa pterygopalatina;                |
| 8, foramen infraorbitale;                | 19, pars squamosa ossis temporalis        |
| 9, fossa canina;                         |   |
| 10, proc. alveolaris;                    |   |
| 11, hamulus proc. pterygoidei;           |   |

bones. The **anterior nasal spine** (*spina nasalis anterior*) projects forward on the midline on the inferior margin of the piriform aperture. It is continuous posteriorly with the bony septum of the nose.

On examination of the skull from the side (*norma lateralis*), the **temporal lines** (*lineae temporales*) (*superior* and *inferior*), strike the eye first of all. Each line rises at the zygomatic process of the frontal bone, curves upward and to the back to intersect the coronary suture, and then passes over to the parietal bone on which it runs in the direction of the mastoid angle and, curving anteriorly, extends to the temporal bone. It marks the attachment of temporal muscle and fascia.

The following depressions merit special description because of their important topographical relations: (1) the **temporal fossa** (*fossa temporalis*);

(2) the **infratemporal fossa** (*fossa infratemporalis*); and (3) the **pterygopalatine fossa** (*fossa pterygopalatina*) (Fig. 68).

The **temporal fossa** (*fossa temporalis*) is bounded superiorly and posteriorly by the temporal line, inferiorly by the infratemporal crest and the inferior margin of the zygomatic arch, and anteriorly by the zygomatic bone. Thus the frontal and parietal bones, the greater wing of the sphenoid bone, the squama of the temporal bone, and the zygomatic bone take part in its formation. The temporal fossa lodges the temporal muscle.

The **infratemporal fossa** (*fossa infratemporalis*) is continuous downward with the temporal fossa, and their borderline is the infratemporal crest of the greater wing of the sphenoid bone. The *medial wall* of the infratemporal fossa is formed by the lateral plate of the pterygoid process. The *anterior wall* is formed by the infratemporal surface of the maxilla and the lower part of the zygomatic bone. The *superior wall* is formed by the inferior surface of the greater wing of the sphenoid bone and the oval and spinous foramina in it, as well as by a small area of the squamous part of the temporal bone. The infratemporal fossa is covered partly on the external surface by the mandibular ramus. It communicates with the orbit through the inferior orbital fissure and with the pterygopalatine fossa through the pterygomaxillary fissure.

The **pterygopalatine fossa** (*fossa pterygopalatina*) is located between the back of the maxilla (anterior wall) and the front of the pterygoid process (posterior wall). Its medial wall is the vertical plate of the palatine bone isolating the pterygopalatine fossa from the cavity of the nose.

The following five openings are found in the pterygopalatine fossa: (1) a medial opening, the **sphenopalatine foramen** (*foramen sphenopalatinum*) leading into the nasal cavity and transmitting the sphenopalatine nerve and vessels; (2) a round **posterosuperior opening** (*foramen rotundum*) leading into the middle cranial fossa and transmitting the second branch of the trigeminal nerve which leaves the cranial cavity; (3) anterior opening, the **inferior orbital fissure** (*fissura orbitalis inferior*) leading into the orbit and transmitting the nerves and vessels; (4) an inferior opening, the **greater palatine canal** (*canalis palatinus major*) leading into the oral cavity; it is formed by the maxilla and the greater palatine sulcus of the palatine bone and is a funnel-shaped narrowing of the lower part of the pterygopalatine fossa and transmits the nerves and vessels leaving this fossa; (5) a posterior opening, the **pterygoid canal** (*canalis pterygoideus*) transmitting the vegetative nerves (n. canalis pterygoidei) and leading to the base of the skull.

On examination of the skull from above (*norma verticalis*), its roof and the sutures are seen: the **sagittal suture** (*sutura sagittalis*) between the medial border of the two parietal bones; the **coronal suture** (*sutura coronalis*) between the frontal and the two parietal bones; and the **lambdoid suture** (*sutura lambdoidea*) (from its resemblance to the Greek letter lambda) between the two parietal bones and the occipital bone.

The **external surface of the base of the skull** (*basis cranii externa*) is made up of the inferior surfaces of the visceral (without the mandible) and the cerebral cranium (Fig. 69). It extends from the incisors anteriorly to

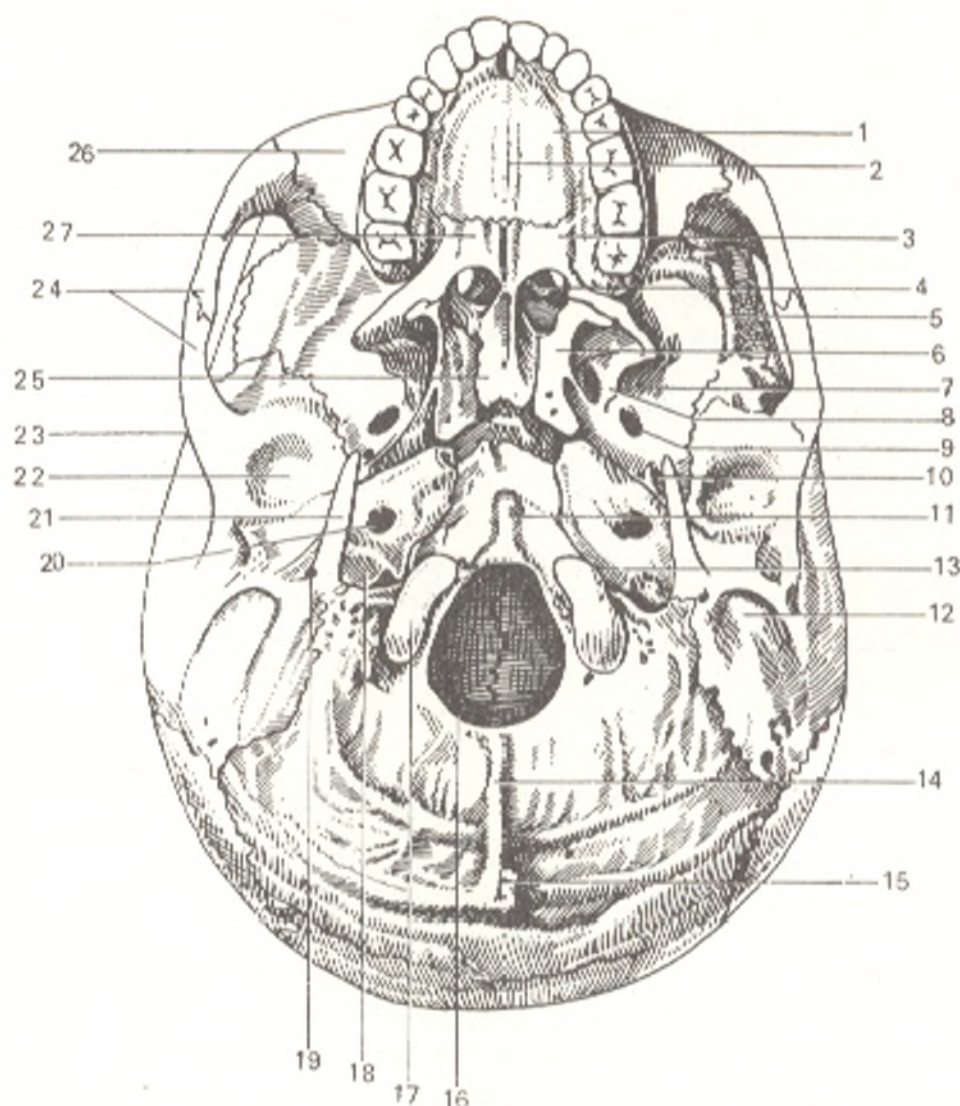


Fig. 69. External surface of base of the skull.

- |  |  |
|--|--|
| 1, palatum osseum;                         | 15, protuberantia occipitalis externa; |
| 2, processus palatinus maxillae;           | 16, foramen magnum;                    |
| 3, lamina horizontalis ossis palatini;     | 17, condylus occipitalis;              |
| 4, choana;                                 | 18, fossa jugularis;                   |
| 5, crista infratemporalis;                 | 19, foramen stylomastoideum;           |
| 6, lamina medialis processus pterygoidei;  | 20, foramen caroticum externum;        |
| 7, fossa infratemporalis;                  | 21, processus styloideus;              |
| 8, lamina lateralis processus pterygoidei; | 22, fossa mandibularis;                |
| 9, foramen ovale;                          | 23, tuberculum articulare;             |
| 10, foramen spinosum;                      | 24, arcus zygomaticus;                 |
| 11, tuberculum pharyngeum;                 | 25, vomer;                             |
| 12, processus mastoideus;                  | 26, maxilla;                           |
| 13, fissura petrooccipitalis;              | 27, sutura palatina transversa         |
| 14, crista occipitalis externa;            |  |

the superior nuchal line (*linea nuchae superior*) posteriorly; its lateral border stretches from the infratemporal crest to the base of the mastoid process. Three parts are distinguished in the external surface of the base of the skull: anterior, middle, and posterior. The anterior part is formed of the **hard palate** (*palatum osseum*) and the alveolar arch of the maxilla; a **transverse suture** (*sutura transversa*) is seen in the posterior part of the hard palate at the junction of its components, the palatine process of the maxilla and



the horizontal plate of the palatine bone. A **median palatine suture** (*sutura mediana*) joining the paired parts of the hard palate runs on the midline and its anterior end is continuous with the incisive foramen. In the posterior part of the hard palate, near to the alveolar arch, is the **greater palatine foramen** (*foramen palatinum majus*), the exit from the greater palatine canal; still further to the back, on the inferior surface of the pyramidal process, are the openings of the lesser palatine canals.

The middle part extends from the posterior edge of the hard palate to the anterior margin of foramen magnum. On the anterior border of this part are openings, *choanae*. They are isolated from each other by the vomer; they are bounded above by the body of the sphenoid bone, below by the horizontal plates of the palatine bones, and laterally by the medial plates of the pterygoid processes. In the posterior part of the base of the skull is the **jugular foramen** (*foramen jugulare*), formed by the jugular fossa of the temporal bone and the jugular notch of the occipital bone. The jugular foramen transmits the ninth, tenth, and eleventh cranial nerves, and the jugular vein originates here.

The **upper surface of the base of the skull** (*basis cranii interna*) can be examined only on a horizontal or sagittal section of the skull (Fig. 70). The internal or superior surface of the base of the skull is separated into three fossae. The anterior and middle fossae lodge the cerebrum, while the posterior fossa lodges the cerebellum. The posterior edges of the lesser wings of the sphenoid bone are the borderline between the anterior and middle fossae, and the superior edge of the pyramids of the temporal bones is the borderline between the middle and posterior fossae.

The **anterior cranial fossa** (*fossa cranii anterior*) is formed by the orbital part of the frontal bone, the cribriform plate of the ethmoid bone, and the lesser wings of the sphenoid bone. It is distinguished by pronounced digitate impressions and cerebral ridges (*juga cerebralia*).

The **middle cranial fossa** (*fossa cranii media*) is located deeper than the anterior fossa. Its median part is formed by the sella turcica. The lateral parts are made up of the greater wings of the sphenoid bone, the squamous part of the temporal bones, and the anterior surface of their pyramids. The openings of the middle fossa are as follows: the optic canal, the superior orbital fissure, foramen rotundum, the oval foramen, and the spinous foramen.

The **posterior cranial fossa** (*fossa cranii posterior*) is the deepest and largest of the three fossae. Its components are the occipital bone, the posterior parts of the body of the sphenoid bone, the petrous part of the temporal bone, and the inferoposterior angle of the parietal bone. The following openings are found in it: foramen magnum, hypoglossal canal, jugular foramen, condylar canal (sometimes absent), mastoid foramen (occurring most regularly), porus acusticus internus (on the posterior surface of the pyramid).

**A sagittal section of the skull.** Examination of a cranial section made in the midsagittal plane or, better, in the direct vicinity of this plane (so as to leave the bony septum of the nose intact in one of the cranial halves) allows study of certain structures that are less visible on other bone specimens. In the region of the frontal bone, it can be seen that the external

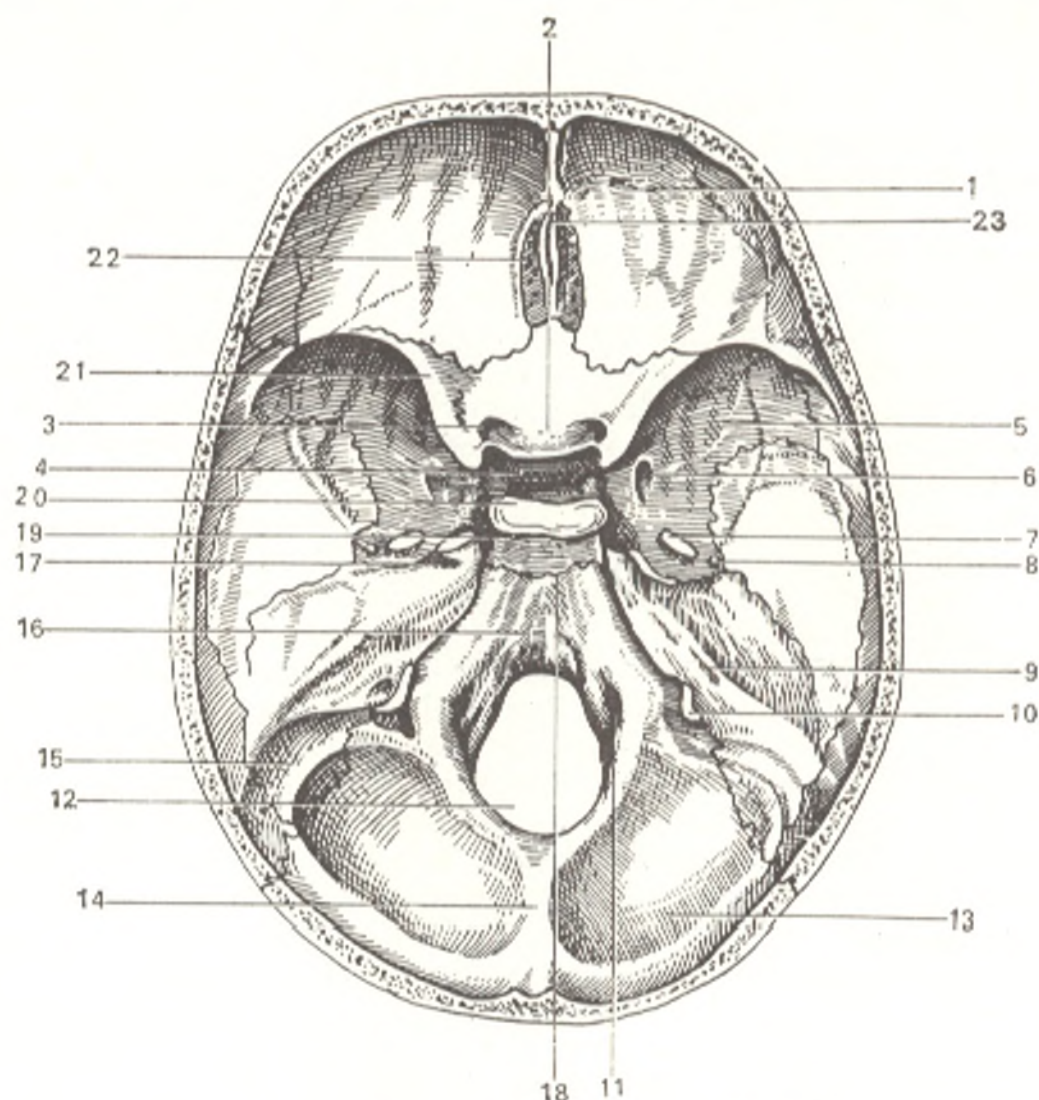


Fig. 70. Internal surface of base of skull.

- |                                    |  |
|------------------------------------|--|
| 1, pars orbitalis ossis frontalis; | 13, squama ossis occipitalis;          |
| 2, tuberculum sellae;              | 14, crista occipitalis interna;        |
| 3, canalis opticus;                | 15, sulcus sinus sigmoidei;            |
| 4, fossa hypophysialis;            | 16, clivus;                            |
| 5, ala major ossis sphenoidalis;   | 17, impressio trigemini;               |
| 6, foramen rotundum;               | 18, synostosis sphenoccipitalis;       |
| 7, foramen ovale;                  | 19, sulcus caroticus;                  |
| 8, foramen spinosum;               | 20, dorsum sellae;                     |
| 9, porus acusticus internus;       | 21, ala minor;                         |
| 10, foramen jugulare;              | 22, lamina cribrosa ossis ethmoidalis; |
| 11, canalis (nervi) hypoglossi;    | 23, crista galli                       |
| 12, foramen magnum;                |  |

and internal plates of the compact substance separate and form an air-filled space, the frontal sinus (sinus frontalis), which opens on each side into the middle nasal meatus. The sphenoidal sinus (sinus sphenoidalis) is found in the body of the sphenoid bone. Vascular sulci, impressions of the vessels of the dura mater, are easily detectable on the inner surface of the parietal and frontal bones and the squama of the temporal bone.

A sagittal section shows the striking predominance of the size of the cranium lodging the brain over the size of the visceral cranium, in contrast

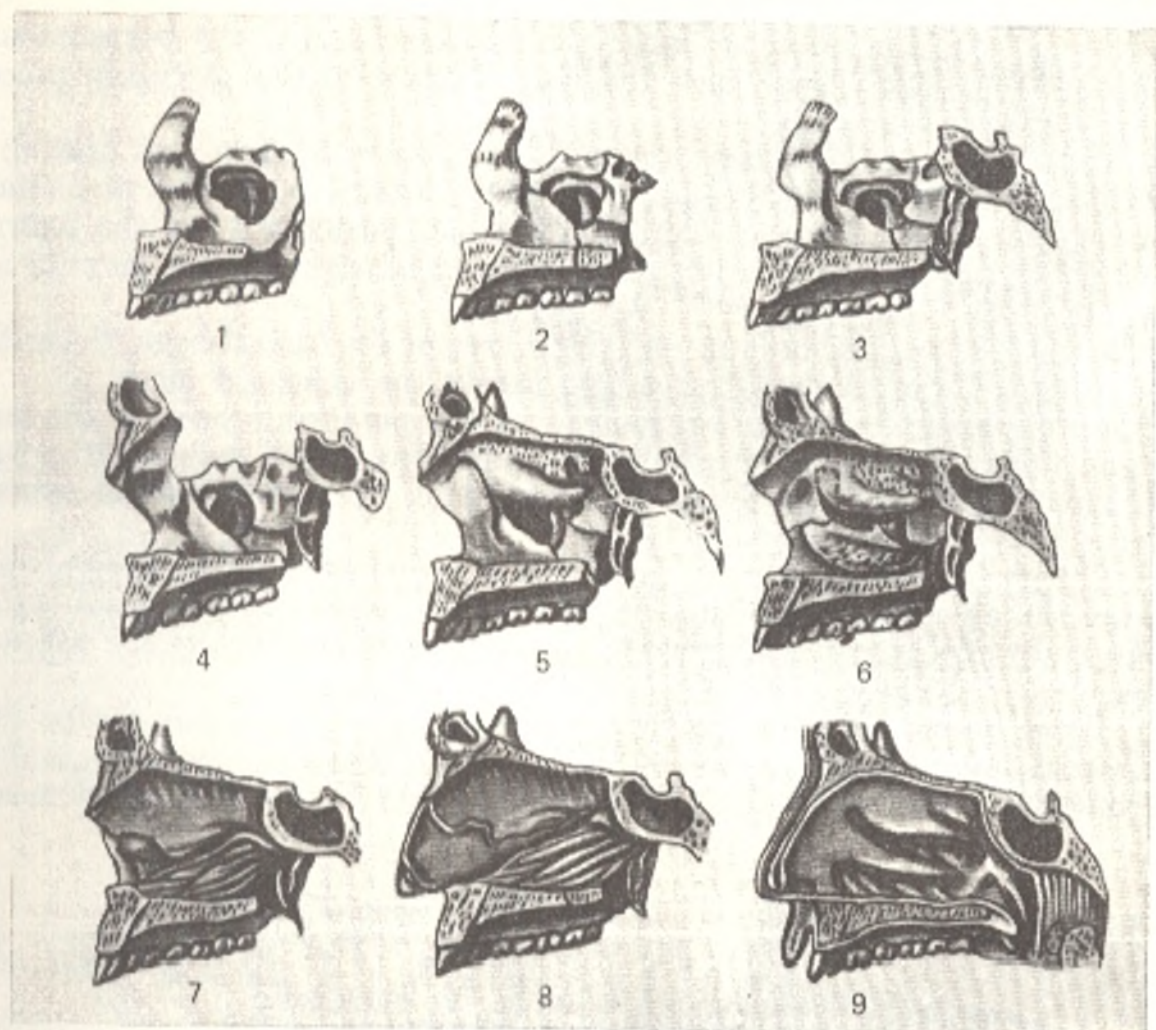


Fig. 71. Components of the nasal cavity.

Maxilla (1)  
to which are added the palatine bone (2),  
body and pterygoid process of sphenoid  
bone (3),  
nasal part of frontal bone (4),  
ethmoid bone with superior and middle  
conchae (5),

inferior concha (6),  
perpendicular plate of ethmoid bone and  
vomer (7),  
cartilaginous part of nasal septum (8),  
mucous membrane (9)

to the opposite situation in the skull of animals. The bony foundation of the nasal cavity can also be examined more closely on a sagittal section.

The cavity of the nose (*cavum nasi*) is the initial part of the respiratory tract and lodges the organ of olfaction. The piriform aperture leads into the cavity in front, and the paired openings, the choanae, connect it with the cavity of the pharynx. The bony septum of the nose (*septum nasi osseum*) divides the nasal cavity into two halves, which are not quite symmetrical, in most cases the septum deviates to one of the sides from the sagittal plane. Each half of the nasal cavity has five walls: superior, inferior, lateral, medial, and posterior.

The *lateral wall* is the most complex in structure; it is formed of the following (from front to back) bones (Fig. 71): the nasal bone, the nasal surface of the body and frontal process of the maxilla, the lacrimal bone,

the labyrinth of the ethmoid bone, the inferior concha, the perpendicular plate of the palatine bone, and the medial plate of the pterygoid process of the sphenoid bone.

The *medial wall*, or the *osseous nasal septum* (*septum nasi osseum*) is formed by the perpendicular plate of the ethmoid bone and the vomer, above by the nasal spine of the frontal bone, posteriorly by the rostrum of the sphenoid bone, and inferiorly by the nasal crests of the maxilla and palatine bone.

The *superior wall* is made up of a small area of the frontal bone, the cribriform plate of the ethmoid bone, and partly the sphenoid bone.

The *inferior wall*, or floor, is formed by the palatine process of the maxilla and the horizontal plate of the palatine bone which make up the bony hard palate (*palatum osseum*); the opening of the incisive canal (*canalis incisivus*) is seen in its front part.

The *posterior wall* is very short and is found only in the superior part because the choanae are located below it. It is formed by the nasal surface of the body of the sphenoid bone with the paired aperture of the sphenoid sinus.

Three nasal conchae project downward into the nasal cavity from the lateral wall; they separate the three nasal meatuses — superior, middle, and inferior—from each other (Figs. 72 and 174). The superior nasal meatus

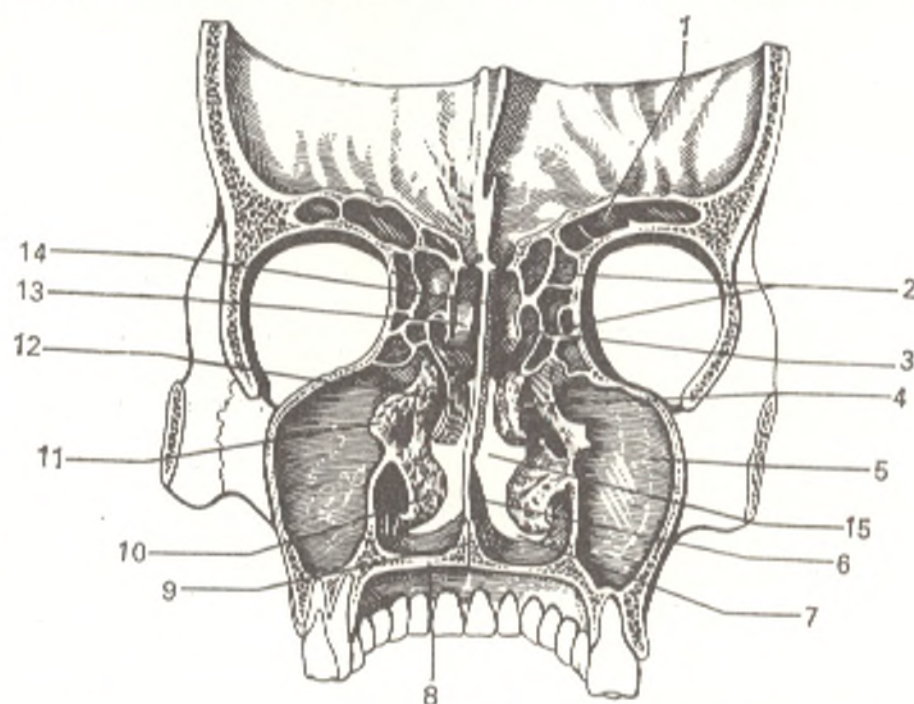


Fig. 72. Frontal section through the skull (after Sinelnikov).

- |                                  |   |
|----------------------------------|---|
| 1, sinus frontalis;              | 9, crista nasalis maxillae;                   |
| 2, cellulae ethmoidales;         | 10, concha nasalis inferior;                  |
| 3, meatus nasi superior;         | 11, ethmoid bone;                             |
| 4, meatus nasi medium;           | 12, concha nasalis media;                     |
| 5, sinus maxillaris;             | 13, concha nasalis superior;                  |
| 6, vomer;                        | 14, lamina perpendicularis ossis ethmoidalis; |
| 7, meatus nasi inferior;         | 15, meatus nasi communis                      |
| 8, processus palatinus maxillae; |   |

Fig. 73. Radiograph of adult skull, anteroposterior view.

- 1, margo supraorbitalis;
- 2, facies externa basis cranii;
- 3, sinus maxillaris;
- 4, base of nasal cavity;
- 5, protuberantia mentalis;
- 6, angulus mandibulae;
- 7, ramus mandibulae;
- 8, base of sinus maxillaris;
- 9, processus mastoideus;
- 10, facies externa basis cranii;
- 11, ala major ossis sphenoidalis;
- 12, fissura orbitalis superior

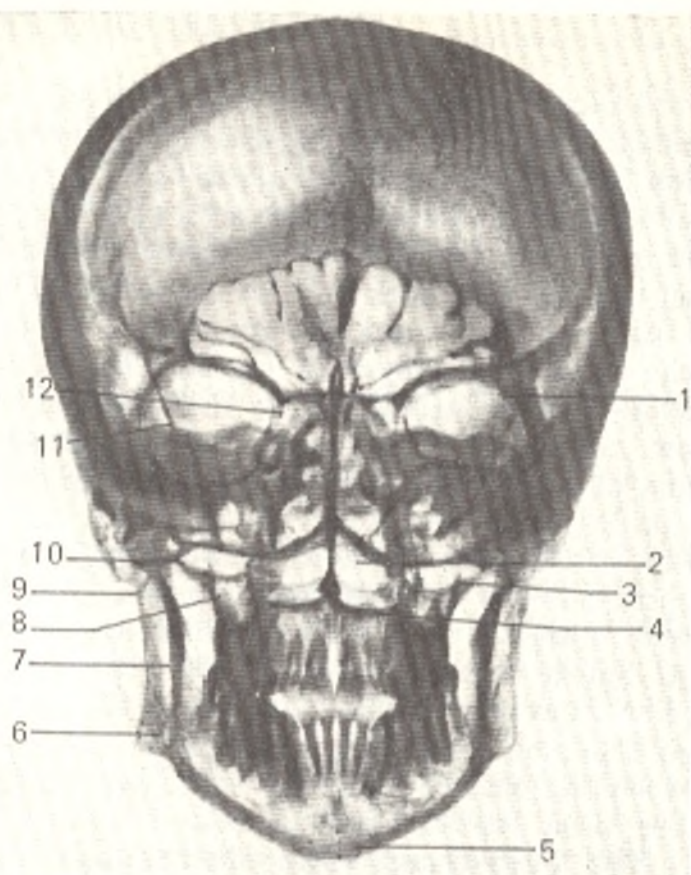
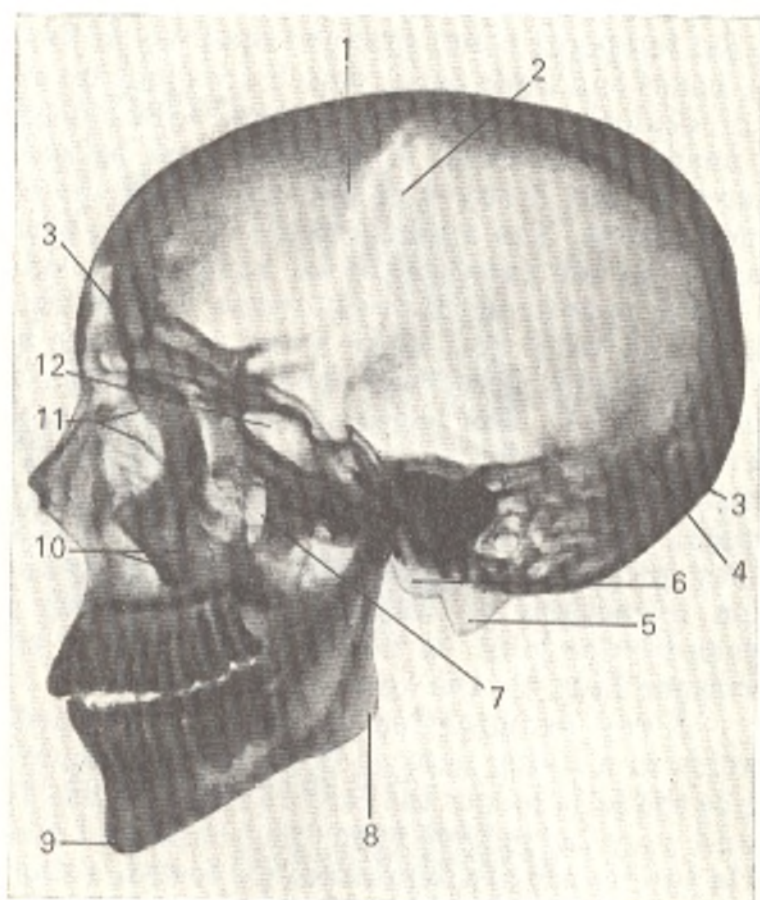


Fig. 74. Radiograph of adult skull, lateral view.

- 1 and 2, sutura coronalis;
- 3, protuberantia occipitalis externa;
- 4, sutura lambdoidea;
- 5, processus mastoideus;
- 6, condylus occipitalis;
- 7, fossa pterygopalatina;
- 8, angulus mandibulae;
- 9, protuberantia mentalis;
- 10, processus zygomaticus maxillae;
- 11, labyrinthus ossis ethmoidalis;
- 12, sinus sphenoidalis;
- 13, sinus frontalis (on the left)



(*meatus nasi superior*) is between the superior and middle conchae of the ethmoid bone; it is half the length of the middle meatus and is found only in the posterior part of the nasal cavity; it communicates with the sphenoid sinus and sphenopalatine foramen and the posterior air cells of the ethmoid bone open into it. The **middle nasal meatus** (*meatus nasi medius*) passes between the middle and inferior conchae. The anterior and middle cells of the ethmoid bone and the maxillary sinus open into it and a projection of the **ethmoidal labyrinth** (*bullae ethmoidalis*) (a rudiment of an accessory concha) is seen lateral to the middle concha. To the front of and a little below the bulla is a funnel-shaped passage (*infundibulum ethmoidale*) by means of which the middle nasal meatus communicates with the anterior ethmoidal cells and the frontal sinus. These anatomical communications explain the spread of the inflammatory process to the frontal sinus (frontitis) in rhinitis. The **inferior nasal meatus** (*meatus nasi inferior*) is between the inferior nasal concha and the floor of the nasal cavity. The nasolacrimal canal opens into its anterior part; through this canal the tears flow into the nasal cavity. That is the reason the amount of nasal discharge increases when a person cries and, conversely, the eyes "water" in rhinitis. The space between the conchae and the nasal septum is known as the **common meatus of the nose** (*meatus nasi communis*).

**The X-ray image of an adult skull.** To understand the superimpositions of the skull bones on the radiograph, the following circumstances must be borne in mind: (1) the cranial bones and their parts formed of bone substance that is more compact than other bone substance (e.g. the petrous part of the temporal bone) produce shadows on the radiograph of greater density; (2) bones and their parts, which are made up of substance that is less compact (e.g. diploe), produce shadows of lesser density; (3) air cavities are seen as unshadowed areas; (4) shadows cast by parts of the skull bones that are nearer to the X-ray film are contrasted more sharply than the shadows of remote parts. The anterior parts of bones, therefore, are more sharply contrasted on an anteroposterior radiograph, and vice versa.

An *anteroposterior radiograph* demonstrates dense shadows of the skull bones and teeth and clear areas at the site of the air sinuses (Fig. 73).

A *lateral radiograph* shows different parts of the cerebral and visceral skull (Fig. 74). The bones of the vault are separated by sutures from which wave-like bands of low density corresponding to the canals of the diploic veins must be distinguished. These bands do not have the serrate character typical of the sutures and stretch in other directions. Knowledge of the X-ray picture of sutures and vascular canals helps to differentiate them from infractions of the skull. The "X-ray joint cavity" of the temporomandibular joint is demonstrated clearly as a curved band of low density corresponding to the intra-articular disc.

X-ray examination is the only method of examination of the sella turcica in a living person. It is clearly demonstrated on a lateral radiograph. Since the sella lodges the cerebral hypophysis, the dimensions of this endocrine gland may be judged from the shape and size of the sella. Three types of sella turcica are distinguished: (1) foetal, a small sella in the form of a "prone"

oval; (2) infantile, a large sella the shape of a "standing" oval; (3) adult, a large sella in the form of a "prone" oval. The process of pneumatization of the sphenoid sinus is also important. It begins from the age of 3 or 4 years in the anterior part of the body of the sphenoid bone and spreads from front to back with age with involvement of the dorsum sellae at old age.

#### AGE FEATURES OF THE SKULL

The skull of the newborn is characterized by a small visceral cranium as compared to the cerebral part.

The fontanelles (*fonticuli*) are another characteristic feature of a newborn's skull (Fig. 75).

The skull of a newborn infant carries traces of the three stages of ossification which are not yet completed. The fontanelles are remnants of the first, membranous stage; they occur at the intersection of sutures where remnants of non-ossified connective tissue are found. Their presence is of high functional importance because they permit the bones of the vault of the skull to be displaced considerably as the skull adapts to the shape and size of the birth canal during delivery. The following fontanelles are distinguished: (1) a rhomboid **anterior fontanelle** (*fonticulus anterior*) located on the midline at the intersection of four sutures (sagittal, frontal, and two halves of the coronary sutures); it closes in the second year of life; (2) a triangular **posterior fontanelle** (*fonticulus posterior*), at the posterior end of the

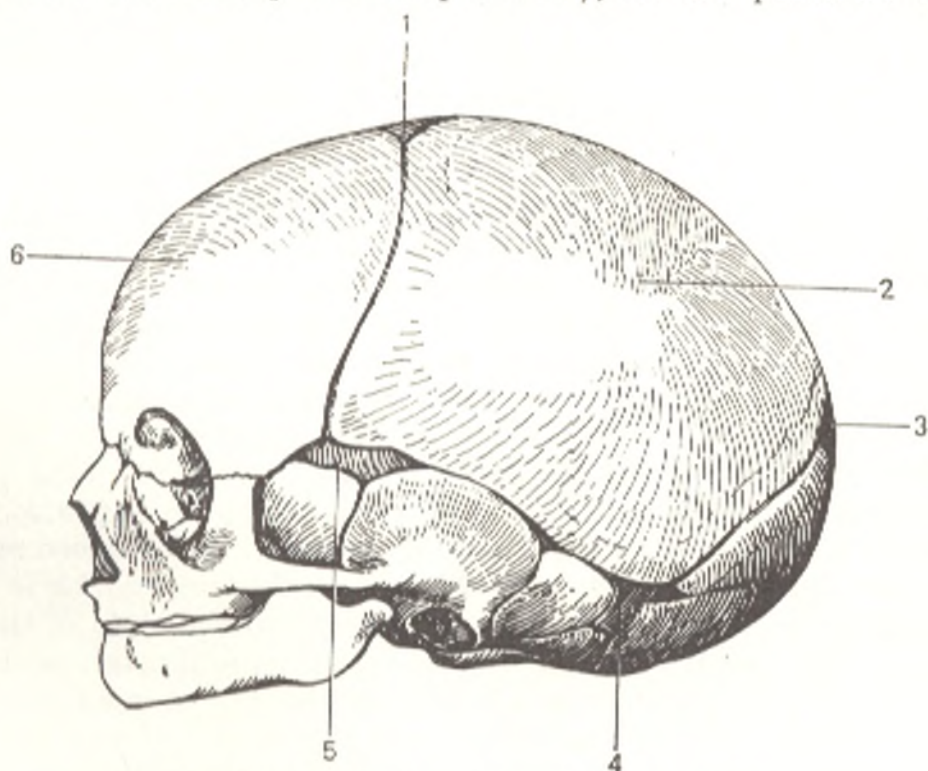


Fig. 75. Skull of newborn, lateral aspect.

1, fonticulus anterior;  
2, tuber parietale;  
3, fonticulus posterior;

4, fonticulus mastoideus;  
5, fonticulus sphenoidalis;  
6, tuber frontale

sagittal suture between the two parietal bones in front and the squama of the occipital bone at the back; it closes in the second month after birth; (3) paired lateral fontanelles, two on each side; the anterior one is called **sphenoidal** (*fonticulus sphenoidalis*) and the posterior one is called **mastoid** (*fonticulus mastoideus*). The sphenoidal fontanelle is at the junction of the mastoid angle of the parietal bone, the greater wing of the sphenoid bone, and the squama of the temporal bone; it closes in the second or third month of life. The mastoid fontanelle is between the mastoid angle of the parietal bone, the base of the pyramid of the temporal bone, and the squama of the occipital bone. The sphenoidal and mastoid fontanelles are mostly found in premature infants; some full-term infants may also have no occipital (posterior) fontanelle.

Remnants of the second, cartilaginous stage of the development of the skull are the cartilaginous layers between some parts of the bones of the base which have not yet fused. As a result the number of these bones is greater in the newborn than in an adult. The air sinuses in the skull bones are still not developed. The different muscular tuberosities, crests, and lines are not pronounced because the muscles do not function yet and are therefore weakly developed. Weakness of the muscles due to absence of the masticating function causes weak development of the jaws: the alveolar processes are hardly formed and the mandible consists of two non-united halves. As a result the visceral cranium is less prominent in relation to the cerebral skull and is only one-eighth the size of the latter, whereas in an adult their ratio is 1 : 4.

Three periods are distinguished in the *growth of the skull*: the first period (the first 7 years) is characterized by intensive growth, mainly of the posterior part; the second (from the age of 7 to the beginning of puberty) is the period of relative rest; the third period, from the beginning of puberty (13-16 years of age) to the end of skeletal growth (20-23 years of age), is again one of intensive growth, but now mainly of the anterior part. The skull grows slowly later, too, which makes the sutures very important because they make it possible for the plane of the cranial bones to increase.

At **mature age**, the cranial sutures disappear (*obliterate*) because the syndesmoses between the bones of the vault are converted to synostosis. At **old age**, the bones of the skull are often thinner and lighter. As the result of the loss of teeth and the atrophy of the alveolar margins of the jaw bones, the face becomes shorter and the lower jaw protrudes forward, while the angle formed by the ramus and the body increases. The described age changes of the skull are demonstrated well by **X-ray examination**, which is important from the standpoint of diagnosis. The radiograph of the skull of the newborn shows, for instance, that: (1) some of the bones (the frontal, occipital, and the mandible) are not fused into a single whole; (2) pneumatization of the air bones is absent; (3) the spaces between the bones of the vault, in the region of the fontanelles in particular, are wide. An anteroposterior radiograph shows a clear space in place of the frontal suture, which separates the frontal bone into two parts, as well as evidence of incomplete union of both halves of the mandible. A posteroanterior radiograph demonstrates



spaces between the interparietal bone and the inferior part of the squama of the occipital bone, and between the lateral parts and squama of this bone. A clear space corresponding to sphenoccipital synchondrosis is seen on a lateral radiograph. The age changes found on radiographs later are as follows.

1. Fusion of separate parts of bones to form a single whole, namely: (a) union of both halves of the mandible (1-2 years of age); (b) fusion of both halves of the frontal bone at the site of the frontal suture (2 years); (c) fusion of all parts of the occipital bone; (d) synostosis between the body of the occipital bone and the sphenoid bone to form a single os basilare at the site of the sphenoccipital synchondrosis; with the development of this synostosis (between the ages of 18 and 20) growth of the base of the skull in length ceases.

2. Disappearance of the fontanelles and the formation of sutures with typical serrated contours (2-3 years of age).

3. Appearance and further development of pneumatization.

X-ray examination is the only method for studying the developing air sinuses of the skull in a living person: (a) the frontal sinus is detectable on a radiograph at the end of the first year of life, after which it grows gradually. In some cases it is small and does not extend beyond the medial segment of the superciliary arch; in others it extends along the entire supra-orbital margin, while in still others it may be absent completely; (b) the bony cells of the ethmoid bone are already discernible in the first years of life; (c) the maxillary sinus is demonstrated on the radiograph of the skull at birth as an elongated clear space the size of a pea. It reaches full development in the period of replacement of deciduous teeth by the permanent teeth and is distinguished by great variability; (d) the sphenoidal sinus is discussed above (p. 200).

4. Replacement and loss of teeth.

5. Disappearance of the sutures and fusion of bones beginning at mature age.

#### SEX DIFFERENCES OF THE SKULL

The skull of a man is larger than the skull of a woman on the average; its capacity is greater than that of the female skull by approximately 10 per cent, which is determined by the sex difference in the body dimensions. The surface of the female skull is smoother because the roughnesses at the sites of muscle attachment are less pronounced. The superciliary arches are less prominent, the forehead more vertical, and the vertex flatter. In some cases, however, the sex signs on the skull are so indistinct that the sex of the individual cannot be determined from them, especially since in approximately 20 per cent of cases the capacity of the female skull is no less than the average capacity of the male. The smaller size of the female skull does not signify poorer development of the brain but corresponds to the smaller dimensions and proportions of the female body.

#### CRANIOLOGY AND CRITICISM OF THE RACIST "THEORY"

The skull is one of the most important objects of anthropological research because of its proximity to such significant organs as the brain, the organs of sense, and the initial parts of the alimentary and respiratory systems.

Fossil skulls, moreover, remain intact for long periods of time and serve as sources of information about races long extinct. The human skull generally takes one of three main shapes, although the shape of the individual skull may vary greatly. Skulls are classified according to the cephalic index (the ratio of the maximum diameter to the maximum length of the skull), obtained by the formula (Fig. 76):

- (1) short or brachycephalic (cephalic index above 80);
- (2) average or mesocephalic (cephalic index of 79-76);
- (3) long or dolichocephalic (cephalic index less than 75).

Proceeding from the tendentious idea that a long skull indicates a more highly developed brain, reactionary scientists in the capitalist countries advanced a racist "theory" concerning the alleged existence of "highly developed" and "poorly developed" skull types characteristic of different human races. According to this "theory", European skulls were considered the "most highly developed", whereas non-Caucasian skulls were considered the "most poorly developed". Some believed, for example, that the skulls of bushmen (smooth and high with a small, steep forehead) and the skulls of native Australians (with a sharply pronounced relief, slanting forehead, and powerful jaws) were primitive since they resembled the skull of Neanderthal man. Research of unbiased scientists showed, however, that the craniofacial index of the Australian skulls differed significantly from the Neanderthal skull. Furthermore, Neanderthal features themselves, according to some authors, are found among all modern races. An interesting illustration of this is the skull of the American paleontologist Cope, which (as the French anthropologist P. Boule demonstrated) bore striking resemblance to the Neanderthal skull found at la Chapelle-aux-sainte.

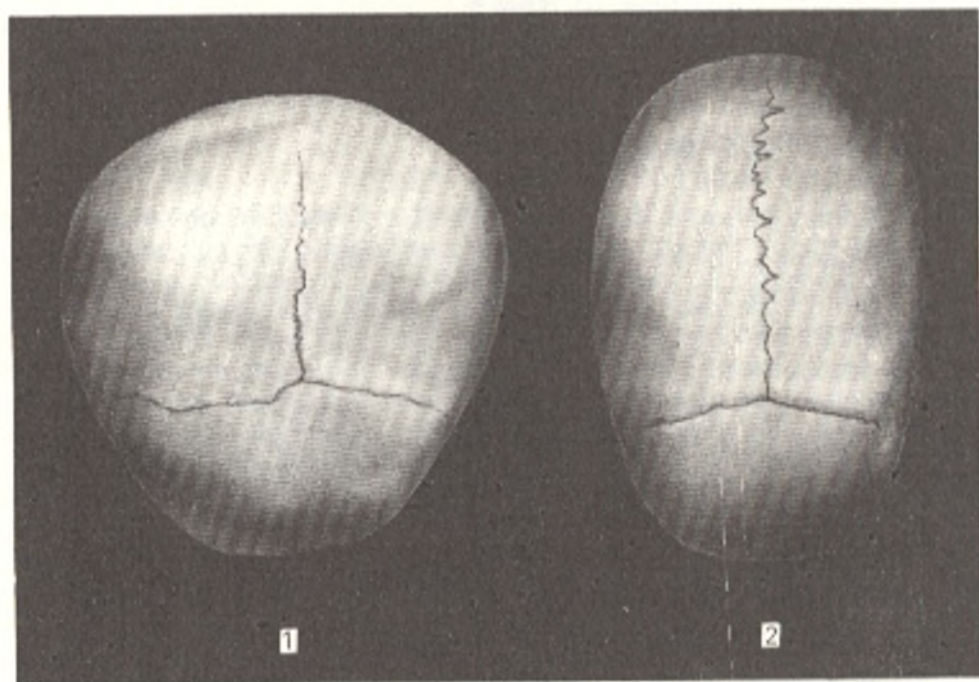


Fig. 76. Short (1) and long (2) skulls

Just before and during World War II, fascist anthropologists in Hitler's Germany endeavoured to prove that the dolichocephalic skull, supposedly an exclusive feature of the Nordic (North) race (which the anthropologists erroneously called the Aryan race), was a biological indication of the racial superiority of the Germans. This assumed superiority allegedly gave them the right to conquer other nations and gain world supremacy.

To solve the question of the significance of racial characteristics, however, it is necessary to differentiate the concept of "race" from that of "nation". Race, a natural, historical category, can be defined as the aggregate of inherited morphological traits common to a group of people living on a definite territory. Although all of modern humanity is currently at the same stage of development, different races develop throughout history as the result of the settlement patterns of individual groups. Different standards of living, that is, varying material conditions, also played an important role in the development of different races. Increasing contact among various groups, however, leads to mingling of the races and effacement of sharp racial distinctions. Therefore, there is no scientific substantiations for distinguishing "higher" and "lower" races.

The concept of race also differs from such special subdivisions as "nation", "tribe", and "people". Since nation, for example, is a social category, racial or biological characteristics cannot be used to justify claims of political or social priority. Anatomical facts also provide evidence of this. Research of foreign and Soviet scientists shows, for instance, that an elongated skull is encountered in all modern races. The presence of long and short skulls and Neanderthal features in all races testifies to their similarity and common origin rather than to their differences. The circumference of the head also varies in all races (from 53 to 61 cm). The circumference of some men of genius, Leibnitz and Kant, for example, was very small (55 cm); the circumference of Dante's head measured 54 cm. In the course of human evolution, the capacity of the average skull is steadily increasing from 900 cm<sup>3</sup> in the Pithecanthropus to 1500 cm<sup>3</sup> in modern man.

The different levels of social and cultural development of various modern societies is thus explained by social rather than biological (racial) factors. Flourishing cultures of formerly "backward" people in the USSR and in other countries advancing towards communism testify to this. National liberation movements against imperialism in the colonial and dependent countries also indicate the falseness of anti-scientific racist assertions about "lower" human types, one of the signs of which is allegedly a certain shape, structure, and size of the skull.

## THE SKELETON OF THE LIMBS

Locomotion of most vertebrates is primarily associated with the limbs, which attain full development in the terrestrial forms and raise the body erect above the earth.

The prototype for the limbs of vertebrates is the paired *fins* of fish, which consist of cartilaginous radial beams and are a simple, flexible lever formed by movement in

a fluid environment. Environmental conditions transform the fin into a five-fingered limb in the terrestrial forms. The limb is modeled after a complex lever made up of several joints and permitting movement on land.

The skeleton of the limbs consists of two parts: the skeleton of the free limb and that of the shoulder and pelvic girdles serving for attachment of the limbs to the trunk. The *shoulder girdle* of the sharks is the simplest form. It consists of a cartilaginous arch whose lateral parts fuse together on the abdominal aspect of the body. Ultimately (in higher fishes and terrestrial vertebrates), the cartilaginous girdle is replaced by bones, some of which develop within the girdle, others are attached to it as membrane bones. In terrestrial animals, beginning with the amphibians, the shoulder girdle is connected to the breast bone which gives it support. Of the many bones in the shoulder girdle, we shall deal only with those preserved in one form or another in the higher vertebrates and in man.

The shoulder blade carrying the fossa for articulating with the free upper limb develops from the dorsal part of the primary shoulder girdle; the ventral part gives rise to the coracoid which in amphibians, reptilia, and fishes adjoins the breast bone. Cranially to the coracoid is another process, the procoracoid, which is supplanted by a membrane bone, the collar bone. The latter is joined to the breast bone and is thus connected with the shoulder blade. In viviparous mammals, the coracoid reduces, loses its connection with the breast bone, and fuses with the shoulder blade in the form of the coracoid process, *processus coracoideus*. The shoulder blade in these animals has a crest continuous with the acromial process to which the collar bone is attached. The collar bone is developed in those mammals whose limbs make movements in all directions (many rodents, bats, apes, and man). In mammals whose limbs make unvarying movements in a single plane when running, swimming, and so on (hoofed animals, carnivores, cetaceans), the collar bones undergo total reduction. A shoulder girdle which is joined to the skeleton of the trunk only at one point (articulation of an existing collar bone with the breast bone) or is not joined to the trunk at all when the collar bone is absent, is distinguished by mobility and is fastened in place mainly by the muscles.

The *pelvic girdle* in its primitive form in lower fishes is represented by a plate on the abdominal aspect of the body, to which both posterior fins are attached. The dorsal part of the lateral half of the pelvic girdle, corresponding to the shoulder blade of the shoulder girdle, forms the iliac bone, the ilium, in terrestrial vertebrates; the ventral part gives rise to the ischial bone, the ischium, and the pubic bone, the pubis, which are homologous to the coracoid and procoracoid. All three parts are not separated, but are connected by cartilage in which they develop. At their junction is an articular fossa for articulating with the first link of the free limb (the femur).

In adult mammals, the three bones of the pelvic girdle fuse to form a single hip bone, *os coxae*. The hip bones are joined to each other ventrally by means of symphysis, in which in the higher forms, particularly in monkeys and man, only the pubic bones participate. As a result an immobile bony ring is formed together with the sacrum, the *pelvis*, serving as a support for the hind (in man, the inferior) pair of limbs. The supporting role of the pelvis is particularly important in man because of his upright position.

The *skeleton of the free limbs* of terrestrial vertebrates changes considerably as a consequence of the change in the mode of life. Although the radial structure typical of fishes is preserved, it is reduced to five radii. Each limb consists of three consecutive links. The first link, the stylopodium, called the humerus on the front limbs and the femur on the hind limbs, is joined to the girdle of the limb. It is followed by the second link, the zeugopodium, formed of two components, the radius and ulna on the front limb and the tibia and fibula on the hind limb. The third link, the autopodium (hand, foot) is made up of small components in the proximal part, the basiopodium, and forms in the distal part, the acropodium, five rays separated from one another, whose free segments are called the digits proper.

All parts of the skeleton of both pairs of limbs may be represented as follows:

Front limb (upper limb in man)		Hind limb (lower limb in man)
humerus	Stylopodium	femur
radius, ulna	Zeugopodium	tibia, fibula
	Autopodium	
radiale, intermedium, ulnare, centralia: I, II, III, IV, V carpalia	Basiopodium (carpus, tarsus)	tibiale, intermedium, fibulare, centralia: I, II, III, IV, V tarsalia
I, II, III, IV, V metacarpalia, phalanges	Acropodium (metacarpus, metatarsus, fingers and toes)	I, II, III, IV, V metatarsalia, phalanges

The species changes in man and mammals closely related to man consist in the following. An additional bone, the knee cap, or patella, which is a sesamoid bone, appears on the lower limb at the junction of the first and second links. An additional sesamoid pisiform bone, os pisiforme, develops in the first row of the carpus. On the foot (Fig. 77), the tibiale and intermedium fuse to form a single bone, the talus. The centralia on the hand fuse with the adjacent bones, while the centralia on the foot form a particular, navicular bone, os naviculare. The fourth and fifth carpalia fuse to form the hamate bone, os hamatum, on the hand, while the fourth and fifth tarsalia unite to form the cuboid bone, os cuboideum, on the foot. This fusion of two bony components is linked with the changed character of locomotion, in which the limbs that had formerly been used simply to push the body forward along the ground (ancient reptiles) now become capable of raising it from the ground. Types of locomotion which developed later, namely running and tree climbing (antique mammals), caused changes in the extremely located fingers (radial and ulnar). The development of fingers on the radial side made it easier to grasp branches and cling to them, while the development of

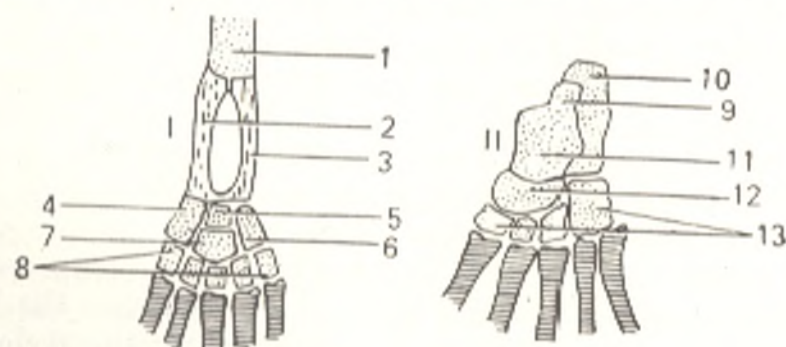


Fig. 77. Evolutionary transformation of bones of the human foot, represented schematically.

I, initial arrangement of bone components of hind limb of a terrestrial vertebrate:  
1, femur;  
2, tibia;  
3, fibula;  
4, tibiale;  
5, intermedium;  
6, fibulare;  
7, centrale;

8, five bones of distal tarsal row;  
II, fate of tarsal components in the human foot:  
9, intermedium, talus;  
10, fibulare, calcaneus;  
11, tibiale, talus;  
12, centrale, navicular bone (of foot);  
13, other tarsal bones

fingers on the ulnar side facilitated support and pressing to the ground. This process was responsible for the fusion of some bones of the primary basiopodium. To strengthen the ulnar margin of the hand and the fibular margin of the foot in leaning for support on the ground, the carpal bones fused, as did the tarsal bones, to form the cuboid and hamate bones, respectively. The *homology between the carpal and tarsal bones* in association with the common type may be represented as follows:

Carpus		Tarsus
os scaphoideum ←	Radiale	} → os talus
os lunatum ←	resp. tibiale	
os triquetrum ←	Intermedium	
	Ulnare	
Absent ←	resp. fibulare →	os calcaneum
os trapezium ←	Centrale →	os naviculare
	Carpale I	
os trapezoideum ←	resp. tarsale →	os cuneiforme I
	Carpale II	
os capitatum ←	resp. tarsale →	os cuneiforme II
	Carpale III	
	resp. tarsale →	os cuneiforme III
os hamatum ←	{ Carpale resp.	} → os cuboideum
	tarsale IV	
	Carpale resp.	
os pisiforme ←	tarsale V	
	sesamoid	

The bones of the metacarpus (metacarpalia) and metatarsus (metatarsalia) and the phalanges of the fingers and toes are absolutely homologous on both limbs.

As to the *position of the limbs*, the proximal link of both limbs, the stylopodium, is primarily set in the lower terrestrial species (amphibia and reptiles) at a right angle to the lateral surface of the body; the bends at the junction of the stylopodium and zeugopodium (the elbow and knee joints) form an angle open medially. As a consequence, these joints permit movement on an axis parallel to the spine. Under such conditions, the animal can only crawl by dragging the abdominal surface of its body on the ground. More energetic movements are accomplished either by jumping, as in the frog, or by twisting the whole body to either side along with movements of the limbs. Rearrangement occurs in the highest forms: the limbs are positioned in the sagittal plane in relation to the body; the stylopodium of the front limb (humerus) turns to the back while the stylopodium of the hind limb (femur) turns to the front; as a result, the apex of the elbow joint faces to the back, whereas the knee joint faces to the front. The axes of movement at the joints take a transverse position which is most expedient for translational movement. If the palmar surface of the distal part (autopodium) of the front limb set in this position is to face the ground, crossing of the radius and ulna (pronation) is inevitable. In this position, the thumb, just as the great toe on the hind limb, faces medially (Fig. 78).

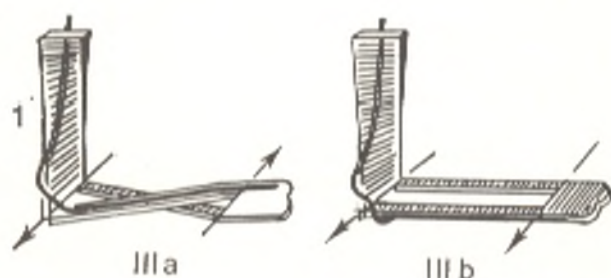
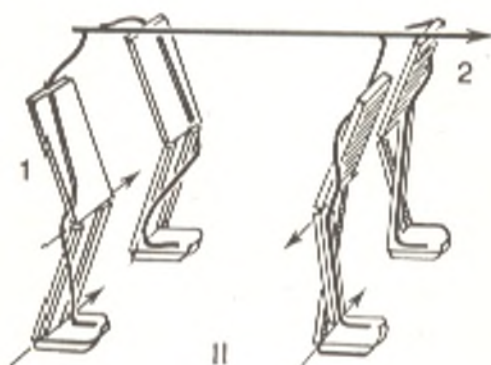
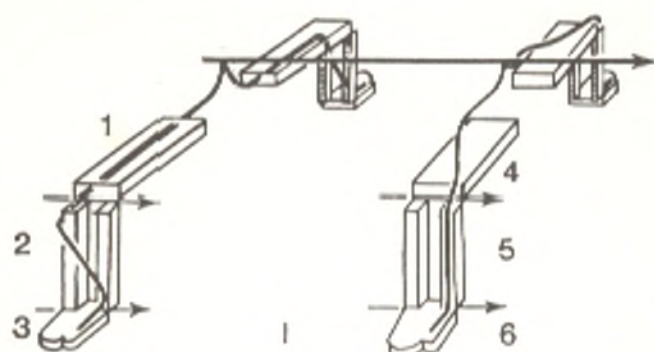


Fig. 78. Different position of limbs of animals and man.

*I*, amphibians and reptiles;

*II*, mammals;

*III*, man.

Thick arrow shows direction of body length toward the head; thin arrows show pivotal axes of joints; black lines designate nerves. Torsion of the humerus occurred in man and pronation (*IIIa*) and supination (*IIIb*) are possible;

*I*, 1, thigh;

2, leg;

3, foot;

4, arm;

5, forearm;

6, hand;

*II*, 1, thigh;

2, arm;

*III* (a, b). 1, arm

As a result of these rearrangements the animal raises itself from the ground, stands on all four limbs and can use its limbs in walking and running. In walking, some animals rest on the whole inferior surface of their paws (plantigrades); others whose distinctive feature is fast running, rest on their digits (digitigrades). A grasping limb develops in climbing mammals; it is characterized by opposition of the thumb in relation to the other fingers. The four limbs of the monkey serve in illustration. Man is the only primate who walks erect resting only on the hind limbs, which are now the lower limbs and which are on the axis continuous with the vertical body axis.

The *front limbs*, which have become the upper limbs in man because of his upright position, have lost their locomotor function. Because of labour, which distinguished man from animals, they transformed to a peculiar grasping organ adapted to the performance of various fine movements necessary during work. The hands became the organs of labour. In accordance with this, the bones of the upper limbs are thinner and lighter than those of the lower limbs, and their articulations permit great freedom of movements. Pronation (rotation of the radius so that the back of the hand

faces upward) and supination (rotation of the forearm so that the back of the hand faces downward) are particularly developed. Besides mobility of the joints, the presence of the collar bone, which sets the limb aside to the periphery, determines to a great measure the freedom of movement of the upper limb. Torsion of the humerus due to the upright position of the body is another feature of the skeleton of the upper limb specific in man; since the thoracic cage in man is compressed from front to back and not from the sides as is the case in the quadruped animals, the shoulder blade fits to the posterior surface of the thorax so that its articular fossa faces laterally (in the quadrupeds it faces downwards). As a result, the articular surface of the humeral head uniting with the shoulder blade faces medially almost at an angle of 90 degrees in relation to the distal epiphysis of the humerus. Torsion of the humerus occurs gradually during the individual development of man.

The hand is particularly adapted to labour. The carpal bones become small. The fingers, in contrast, become elongated and freely movable. The thumb diverges to the side and can be opposed to the other fingers, even to the little finger. Monkeys cannot do this; some can oppose the thumb only up to the third finger, and their thumb, moreover, is short. Owing to this structure, the human hand can not only grasp an object (as is the case in anthropoid apes) but clench it, which is very important in the "grasping" function of the hand during work. All these specific features in the structure of the upper limb of man were acquired as the result of improvement of the hand in the process of labour. "Thus the hand is not only the organ of labour, it is also the product of labour"<sup>1</sup>.

The *lower limbs* of man are concerned with movement of the body and at the same time serve as supports on which the whole weight of the body rests. Their bones are, therefore, thicker and more massive than the bones of the upper limbs and are less mobile at their articulations. The same can be said of the muscles, which are stronger and larger on the lower than on the upper limbs. The difference between the upper and lower limbs is particularly obvious on the autopodia, the hand and foot, in which the influence of work performed by each limb is predominantly manifested.

The foot as the end support of the body has lost the property of the grasping limb of monkeys, as a consequence of which the toes, not concerned with weight-bearing, are much shorter. The big toe stands in one row with the other toes and is not distinguished by the free mobility typical of the thumb. The foot acquired the shape of an arch, absorbing, like a spring, the jolts and shakes experienced in walking and running.

The *first limb buds in man* appear in the third week of embryonic life as horizontal ridges resembling fins on the sides of the embryo. The ridges expand to form a rounded plate (the bud of the hand and foot) in which digits cannot yet be distinguished. These are marked out on the plate later as five rays connected by means of thin skin folds. The folds gradually dis-

<sup>1</sup> F. Engels. *Dialectics of Nature*. Foreign Languages Publishing House, Moscow, 1954, p. 230.



appear, and the digits become free. After that the components of the forearm and leg and, finally, those of the arm and thigh develop. The separate links of the limb arise, therefore, in the following order: first, the distal, then, the middle, and, finally, the proximal links, as if, in development of the upper limb, first the hand grows out of the trunk, then the forearm and after that the arm, and in development of the lower limb, first the foot, then the leg, and finally the thigh.

## THE SKELETON OF THE UPPER LIMB

### THE SHOULDER GIRDLE

The shoulder girdle (*cingulum membri superioris*) consists of two paired bones, the clavicle (collar bone) and the scapula (shoulder blade).

### THE CLAVICLE

The clavicle (*clavicula*) is the only bone fastening the upper limb to the skeleton of the trunk. It is of high functional importance because it holds the shoulder joint at the needed distance from the thoracic cage and thus permits greater freedom of movement of the limb. As pointed out above, the clavicle is well developed in mammals capable of various movements of the front (upper) limbs. In contrast, it is insufficiently developed in animals with limbs specialized in movement in one (sagittal) plane. The shoulder joint of a person with a fractured clavicle is pressed to the thoracic cage by the action of the muscles, and movements of the upper limb become very limited, as in animals who lack the clavicle. Comparison of the clavicle in the different hominid forms shows that it increases gradually in size and is developed best in modern man, which is linked with his work activity. The clavicle develops before all the other bones. It is a membrane bone transposed from the trunk and ossifies, therefore, partly in connective tissue (middle segment) and partly in cartilage (the ends); an independent ossification nucleus is laid down only in one (sternal) epiphysis (monoepiphyseal bone). According to some data, the clavicle undergoes both perichondral and enchondral ossification. The clavicle is a tubular bone, and a body (shaft) and two ends, medial and lateral, are distinguished in it. The thickened medial, or **sternal end** (*extremitas sternalis*) carries a saddle-shaped articular surface for uniting with the sternum. The lateral, or **acromial end** (*extremitas acromialis*) has a flat articular surface for articulating with the acromial process of the scapula. On the inferior surface of the acromial end is the **conoid tubercle** (*tuberculum conoideum*) (the site of attachment of ligaments). The shaft of the clavicle is curved so that its medial part which is nearer to the sternum is convex anteriorly, while the lateral part is convex posteriorly.

**Ossification.** The clavicle is the first bone to receive an ossification point, on the sixth week of intrauterine development. A bony nucleus appears in the sternal end (epiphysis) in the 16th-18th year of life and fuses between the ages of 20 and 25. That is why radiographs of the shoulder

girdle of persons between the ages of 16 and 25 show multiple islands of ossification, which fuse to form a flat disc. An anteroposterior radiograph of an adult produces a clear image of the whole clavicle with properties of a tubular bone curved slightly in the shape of the letter S. The conoid tubercle often seen on the inferior surface of the clavicle above the coracoid process of the scapula may simulate the picture of inflammation of the periosteum in this segment of the clavicle.

## THE SCAPULA

The **shoulder blade** or **scapula** is a flat triangular bone lying on the posterior surface of the thoracic cage in the space between the second and seventh ribs. According to the shape of the bone, three borders are distinguished in it: the **medial border** (*margo medialis*), facing the spine, the **lateral border** (*margo lateralis*), and the **superior border** (*margo superior*), on which is the **scapular notch** (*incisura scapulae*). The three borders meet at three angles, one of which, the **inferior angle** (*angulus inferior*) is directed downward, while the other two, the **superior angle** (*angulus superior*) and **lateral angle** (*angulus lateralis*) are at the ends of the superior border of the scapula. The lateral angle is greatly thickened and supplied with a shallow depression, a laterally positioned articular **glenoid cavity** (*cavitas glenoidalis*). The edge of the cavity is separated from the rest of the scapula by a constriction, the **neck of the scapula** (*collum scapulae*). Above the superior edge of the cavity is the **supraglenoid tubercle** (*tuberculum supraglenoidale*), which provides attachment for the tendon of the long head of the biceps. A similar **infraglenoid tubercle** (*tuberculum infraglenoidale*) for attachment of the long head of the triceps is found at the inferior edge of the fossa. The **coracoid process** (*processus coracoideus*) (the former coracoid) arises from the superior border of the scapula in the vicinity of the glenoid cavity. The anterior, **costal surface** of the scapula (*facies costalis*) forms a hollow depression called the **subscapular fossa** (*fossa subscapularis*) which gives attachment to the subscapular muscle. The **spine of the scapula** (*spina scapulae*) projects from the **dorsal surface** of the scapula (*facies dorsalis*) and divides it into two recesses of unequal size, the **supraspinous** and **infraspinous fossae** (*fossa supraspinata* and *fossa infraspinata*). The spine of the scapula stretches laterally and is continuous with the **acromion** overhanging the glenoid cavity at the back and above. The acromion carries the **articular facet** (*facies articularis acromii*) for articulation with the clavicle.

A posteroanterior radiograph of the scapula demonstrates a characteristic triangular structure with three borders, angles, and processes. A notch, *incisura scapulae*, can sometimes be detected on the superior border at the base of the coracoid process; it can be mistaken for a focus of bone destruction, particularly when it is converted into a foramen as a consequence of the age calcification of the superior transverse ligament of the scapula.

**Ossification.** Only the body and spine of the scapula consist of bony tissue at birth. Radiographs made in the first year of life show an ossification focus in the coracoid process (synostosis occurs between the ages of 16 and

17). Radiographs taken between the ages of 11 and 18 demonstrate accessory foci in the body of the scapula, in the epiphyses (glenoid cavity, acromion), and in the apophyses (coracoid process, medial border, inferior angle). Before synostosis takes place, the inferior angle seems to be separated from the body by a line of low density which should not be mistaken for a line of fracture. The acromion ossifies from multiple ossification points, one of which may persist throughout life as an independent bone, *os acromiale*, and which may be mistaken for a bone fragment. Synostosis of all ossification nuclei of the scapula is completed between the ages of 18 and 24.

#### THE JOINTS OF THE SHOULDER GIRDLE

1. The **sternoclavicular joint** (*articulatio sternoclavicularis*) (Fig. 79) is formed by the sternal end of the clavicle and the clavicular notch of the sternum. The articular surfaces are complemented by an **intra-articular disc** (*discus articularis*). The articular cavity is fastened by ligaments: the **anterior and posterior sternoclavicular ligaments** (*ligamenta sternoclaviculare anterius* and *posterius*) in front and behind; the **costoclavicular ligament** (*lig. costoclaviculare*) below (to the cartilage of the first rib); and the **interclavicular ligament** (*lig. interclaviculare*) above (between the clavicles, above the jugular notch). The articulation resembles a spheroid joint to a certain measure. The main *movements* are made on the sagittal (anteroposterior) axis, on raising and lowering the clavicle, and on the vertical axis, in forward and backward movements of the clavicle. Rotation of the clavicle on its long axis is also possible. The scapula moves together with the clavicle, and, consequently, the whole shoulder girdle on the respective side swings

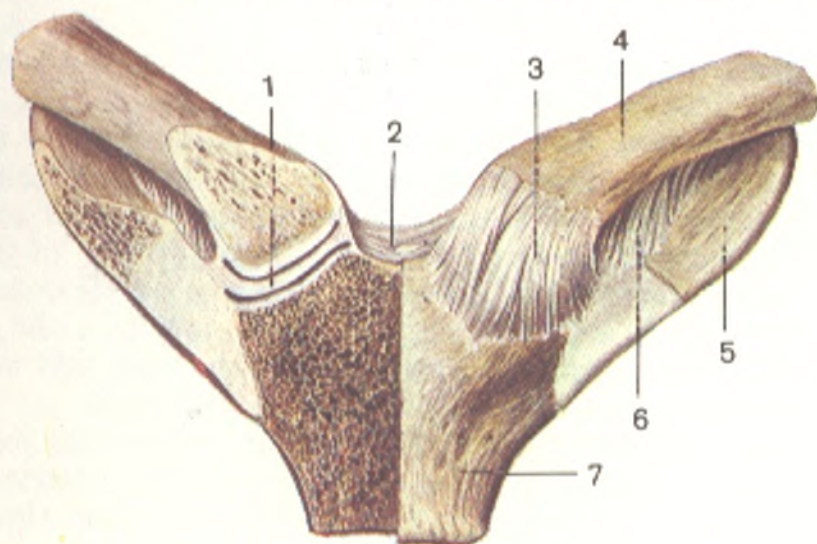


Fig. 79. The sternoclavicular joints (*articulationes sternoclaviculares*), anterior aspect (frontal section through the right joint).

1, discus articularis;  
2, lig. interclaviculare;  
3, lig. sternoclaviculare anterius;  
4, clavícula;

5, first rib;  
6, lig. costoclaviculare;  
7, manubrium sterni

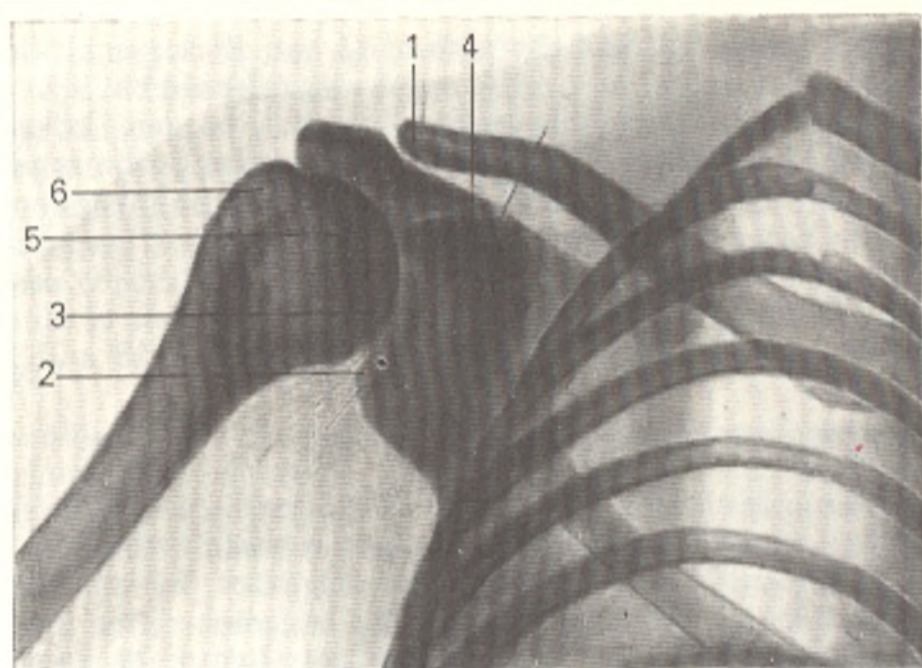


Fig. 80. Radiograph of the shoulder joint.

1 clavicle;  
2, glenoid cavity of scapula;  
3, joint space of shoulder joint;

4, coracoid process;  
5, head of humerus;  
6, greater tubercle

into movement. The *scapula* in this case *moves* upward and downward, and forward and backward; finally, it can rotate on the anteroposterior axis with its inferior angle being displaced laterally as occurs when the arm is raised above the shoulder.

2. The **acromioclavicular joint** (*articulatio acromioclavicularis*) joins the acromial process of the scapula with the acromial end of the clavicle whose flat articular surfaces are often separated by an **intra-articular disc** (*discus articularis*). The articular capsule is reinforced by the **acromioclavicular ligament** (*lig. acromioclavicularis*), and the whole joint is strengthened by a powerful **coracoclavicular ligament** (*lig. coracoclavicularis*) stretching between the inferior surface of the clavicle and the coracoid process of the scapula. A synovial bursa is often found in a depression of this ligament filled with loose cellular tissue. The coracoclavicular ligament bears the weight of the upper limb and the scapula suspended from the clavicle. As a result the acromioclavicular joint itself is relieved from this weight, which explains the rare occurrence of dislocations of the joint.

The X-ray image of the cavity of the acromioclavicular joint (Fig. 80) is clearly demarcated by the contours of the articulating parts of the clavicle and scapula, which have a very thin cortical layer on the radiograph. The articular end of the clavicle is larger than the corresponding end of the acromion as a consequence of which the superior surface of the clavicle is set higher than the analogous surface of the acromion. The inferior surfaces of the clavicle and acromion lie on the same level. The normal relations of the components of the acromioclavicular joint are therefore judged from the contours of the inferior surfaces, which are normally set

on one level (in subluxation or luxation they are at different levels, and the distance between the articular ends is increased).

3. **The ligaments of the scapula.** In addition to the ligaments connecting the clavicle to the scapula, the scapula has three ligaments of its own, which have no relation to the joints. One of them, the **coracoacromial ligament** (*lig. coracoacromiale*) extends as a vault above the shoulder joint between the anterior edge of the acromial process and the coracoid process. Another, the **superior transverse scapular ligament** (*lig. transversum scapulae superius*), stretches above the scapular notch and converts it into a foramen. Finally, a third ligament, the **inferior transverse scapular ligament** (*lig. transversus scapulae inferius*) is weaker and passes from the base of the acromial process through the scapular neck to the posterior border of the glenoid cavity; the suprascapular artery runs under it.

#### THE SKELETON OF THE FREE UPPER LIMB AND ITS ADAPTATION TO LABOUR

The skeleton of the free upper limb consists of the humerus, two forearm bones, and the bones of the hand.

#### The Humerus

The **humerus** is a long lever of movement, which develops like a typical long tubular bone. In conformity with this function and development, it is made up of a diaphysis, metaphyses, epiphyses, and apophyses. Its upper end is supplied with a spherical **head** (*caput humeri*) (the proximal epiphysis), which articulates with the glenoid cavity of the scapula. The head is separated from the rest of the bone by a narrow groove called the **anatomical neck** (*collum anatomicum*). Directly below it are two tubercles for attachment of the muscles. The **greater tubercle** (*tuberculum majus*) is on the lateral side; the **lesser tubercle** (*tuberculum minus*) is a little to the front of it (apophyses). Bony crests (for attachment of the muscles) run downward from the tubercles, the **lateral lip of the bicipital groove** (*crista tuberculi majoris*) and the **medial lip of the bicipital groove** (*crista tuberculi minoris*). The **intertubercular groove** (*sulcus intertubercularis*) passes between both tubercles and crests and lodges the tendon of the long head of the biceps muscle. The part of the humerus directly below the tubercles at the junction with the diaphysis is called the **surgical neck** (*collum chirurgicum*) (where fractures often occur). The upper part of the **body** (shaft) of the humerus has cylindrical outlines, but its lower part has a distinctly trihedral shape, in which a **posterior surface** (*facies posterior*), an **anterolateral surface** (*facies anterior lateralis*), and an **anteromedial surface** (*facies anterior medialis*) are distinguished. The two anterior surfaces are separated from the posterior surface by **lateral and medial borders** (*margo lateralis* and *margo medialis*). About the middle of the shaft, on its anterolateral surface, is the **deltoid tuberosity** (*tuberositas deltoidea*), to which the deltoid muscle is attached. A sloping spiral, **shallow groove of the radial nerve** (*sulcus nervi radialis*, s. *sulcus spiralis*) passes

behind the tuberosity on the posterior surface of the body from the medial to the lateral border.

The widened distal part of the humerus, the **condyle** (*condylus humeri*) is bent slightly forward and has two rough projections on its sides, the *medial* and *lateral epicondyles* (*epicondylus medialis* and *epicondylus lateralis*), which are continuous with the medial and lateral borders of the bone and provide attachment for the muscles and ligaments (apophyses). The medial epicondyle is more prominent than the lateral one and has on its posterior surface a *groove for the ulnar nerve* (*sulcus nervi ulnaris*). An articular surface for uniting with the forearm bones (distal epiphysis) is situated between the epicondyles. Two parts are distinguished in it. Medially is the pulley-shaped **trochlea** grooved in the middle; it articulates with the ulna and is embraced by its *notch* (*incisura trochlearis ulnae*). Above the trochlea are two fossae, one, the *coronary fossa* (*fossa coronoidea*) in front, and the other, the *olecranon fossa* (*fossa olecrani*) behind. These fossae are so deep that the bony septum separating them is thin enough to be transparent and may even be perforated. Laterally of the trochlea is an articular surface the shape of a segment of a sphere, the **capitulum of the humerus** (*capitulum humeri*) for articulation with the radius. A small *radial fossa* (*fossa radialis*) lies above it in front.

**Ossification.** The proximal epiphysis of the humerus is still cartilaginous at birth so that the head of the bone is hardly discernible on the radiograph.

Three nuclei appear in succession later: (1) in the medial part of the head (shortly after birth and until 12 months of life, though it may also be found in the newborn); (2) in the greater tubercle and lateral part of the head (between the ages of 2 and 3); (3) in the lesser tubercle (between the ages of 3 and 4). These nuclei fuse to form the head of the humerus between the ages of four and six, while synostosis of the whole proximal epiphysis with the diaphysis occurs only between the ages of 20 and 22. The **radiographs** of the shoulder joint of children and adolescents show, therefore, areas of diminished density at the site of cartilage according to the ages indicated above; they separate the parts of the proximal humeral end which have not yet fused. These areas, which are signs of normal age changes, must not be mistaken for infractions or fractures of the humerus. Ossification of the distal end of the humerus is described below.

### The Shoulder Joint

The **shoulder joint** (*articulatio humeri*) connects the humerus, and through it, the whole free upper limb, with the shoulder girdle, the scapula in particular (Fig. 84). The head of the humerus contributing to the formation of the joint is spherical. The glenoid cavity of the scapula articulating with it is shallow. On the circumference of the cavity is a **cartilaginous glenoid lip** (*labrum glenoidale*), which increases its depth without limiting the range of movements and also absorbs the jerks and shocks during movement of the head. The **articular capsule** of the shoulder joint is free and

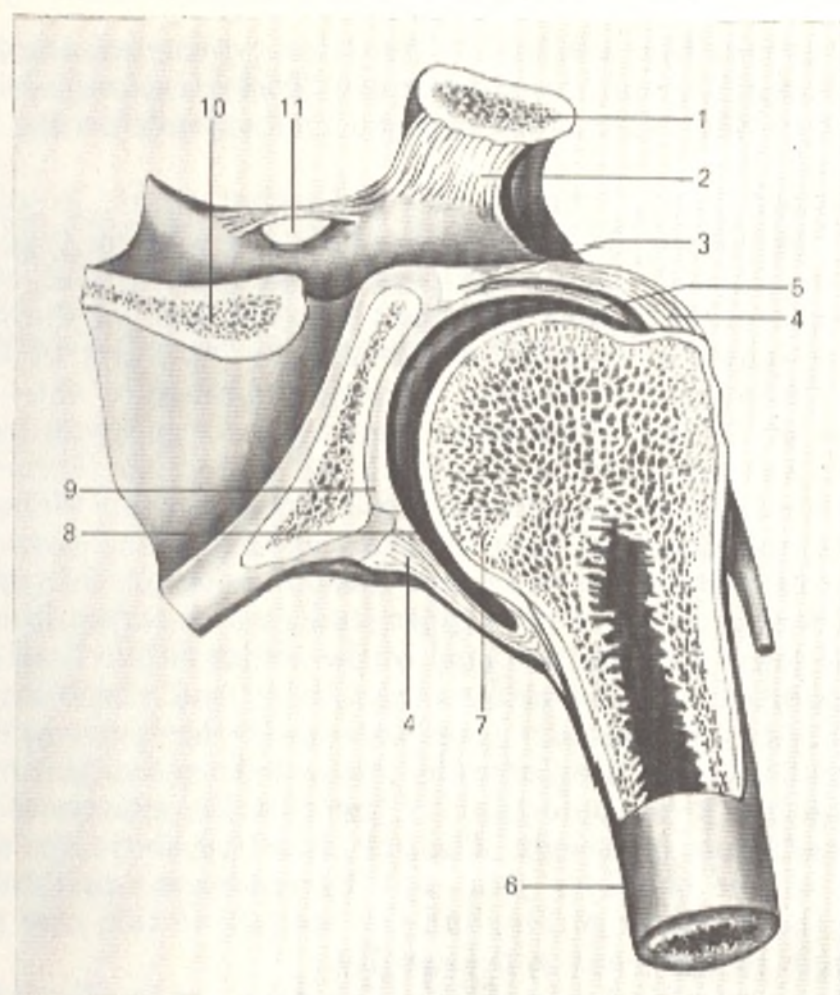


Fig. 81. Shoulder joint (frontal section, after Kiss and Szentagóthai).

- |                             |   |
|-----------------------------|---|
| 1, clavicle;                | 8, joint cavity;                              |
| 2, lig. coracoclaviculare;  | 9, articular cartilage lining glenoid cavity; |
| 3, labrum glenoidale;       | 10, spina scapulae;                           |
| 4, articular capsule;       | 11, lig. transversum scapulae superius;       |
| 5, tendon of biceps muscle; |   |
| 6, corpus humeri;           |   |
| 7, caput humeri;            |   |

thin; it is attached to the bony edge of the scapular glenoid cavity, embraces the humeral head, and terminates on the anatomical neck; it bridges the intertubercular groove with the long head of the biceps muscle lodged here. The **coracohumeral ligament** (*lig. coracohumerale*), stretching from the root of the coracoid process to the greater tubercle of the humerus, is a slightly thicker bunch of fibres serving as an accessory ligament. All in all, the shoulder blade has no true ligaments and is held in place by the muscles of the shoulder girdle. This circumstance is, on the one hand, conducive to the wide range of movement at the shoulder joint necessary for the functioning of the limb as an organ of labour. On the other hand, the weak fixation of the shoulder joint is the cause of frequent dislocations.

The synovial membrane lining the capsule of the joint has two extra-articular protrusions. The first, the *intertubercular synovial sheath* (*vagina synovialis intertubercularis*) encompasses the long head of the biceps muscle

passing in this groove like a cylinder; the other protrusion, the *subtendinous bursa of the subscapularis muscle* (*bursa subtendinea m. subscapularis*) is above the upper part of the subscapular muscle and extends to the root of the coracoid process.

The shoulder joint, typical ball-and-socket joint, is distinguished by freedom of movement. As with all joints of this general type, movement at the shoulder joint takes place on three main axes: frontal, sagittal, and vertical. Circumduction is also possible. In movement on the frontal axis, anterior flexion (anterior raising) of the arm to the level of the shoulder and posterior flexion, or extension, occurs; the range of extension is less than the range of flexion. Abduction (raising the arm away from the side of the trunk to the level of the shoulder) and adduction (lowering the arm back to the side of the trunk) take place in movement on the sagittal axis. Medial and lateral rotation of the arm occurs on the vertical axis. The pivotal axis does not coincide with the axis of the humerus but corresponds to the so-called *constructional axis* of the upper limb, which passes from the centre of the shoulder joint through the head of the radius to the head of the ulna.

As was pointed out above, forward raising and abduction of the arm are possible only to the shoulder level because further movement is stopped by tightening of the articular capsule and abutment of the upper end of the humerus against a vault formed by the acromial process of the scapula and the coracoacromial ligament. The arm is raised above the shoulder not by movement at the shoulder joint but by movement of the whole limb together with the shoulder girdle, and the scapula in this case rotates with its inferior angle to the front and laterally.

The human upper limb possesses a high degree of freedom of movement. The freeing of the upper limb was the decisive step in man's evolutionary process. The shoulder joint, as a consequence, became the freest articulation of the human body, and as a result we can reach any part of our body with the hand and manipulate with the hands in all directions. This capacity is extremely important in everyday life and work.

A posteroanterior radiograph of the shoulder joint (see Fig. 80) demonstrates the glenoid cavity, which is shaped like a convex lens with two outlines: a medial outline, corresponding to the anterior semicircumference of the cavity, and a lateral outline corresponding to its posterior semicircumference. On the X-ray, the medial outline appears thicker and sharper, and an impression of a semicircle is produced, which indicates a normal shoulder joint. (In some diseases the lateral outline is also conspicuous, and the semicircle of the glenoid cavity is replaced by an abnormal "ring").

On a posteroanterior radiograph the inferomedian part of the humeral head is superimposed on the glenoid cavity. The outline of the head is even and distinct but thin. An X-ray joint space of the shoulder joint is seen as a curved band of diminished density between the clearly demonstrated outlines of the medial (anterior) border of the glenoid cavity and the head of the humerus. To recognize luxation or subluxation of the shoulder joint, it is very important to know the normal relations between the articulating surfaces. A radiograph made in the proper posteroanterior view with the



upper limb extended along the trunk is characterized by superimposition of the inferomedian part of the humeral head on the glenoid cavity. The inferomedian part of the head will always project above the superior border of the cavity.

The shoulder joint receives *nutrients* from the rete articulare formed by the anterior and posterior circumflex humeral arteries and the thoraco-acromial artery (from the axillary artery). *Venous blood* is drained along veins of the same name into the axillary vein. *Lymph flows* in the deep lymphatic vessels into the axillary lymph nodes. The joint capsule is *innervated* by branches of the axillary nerve.

## BONES OF THE FOREARM

The forearm bones (Fig. 82) belong to the group of long tubular bones. There are two of them, the *ulna*, which is the medial bone, and the *radius*, the lateral bone. The shafts of both bones are trihedral with three surfaces and three borders. The surfaces are as follows: posterior, anterior, and lateral in the radius and medial in the ulna. One of the three borders is sharp. It separates the anterior from the posterior surface and faces the neighbouring bone, thus delimiting the interosseous space; hence its name, the *interosseous border* (*margo interossea*). The anterior surface of the shaft has a *vascular foramen* (*foramen vasculosum*) leading into the vascular canal for the vessels. Besides these signs common to both bones, there are some features characteristic of each bone separately.

### The Ulna

The *ulna* (s. *cubitus*). The upper (proximal) thickened end of the ulna (epiphysis) is separated into two processes: the thicker, posterior process, **olecranon** and the smaller anterior, **coronoid process** (*processus coronoideus*). Between these two processes is the *trochlear notch* (*incisura trochlearis*) for articulation with the trochlea of the humerus. The radial side of the coronoid process has a small *radial notch* (*incisura radialis*), the site of articulation with the head of the radius; in front, under the coronoid process, there is the *tuberosity of the ulna* (*tuberositas ulnae*), to which attaches the tendon of the brachial muscle. The lower (distal) end of the ulna carries a spherical **head** with a flat inferior surface (*caput ulnae*) (epiphysis) from the medial surface of which the **styloid process** (*processus styloideus*) (apophysis) projects. The head carries on its circumference an articular surface (*circumferentia articularis*), by means of which it articulates with the adjacent radius.

### The Radius

The **radius**, in contrast to the ulna, has a distal end that is thicker than the proximal end. The proximal end forms a rounded **head** (*caput radii*) (epiphysis), which has a concave surface for articulation with the head of the humerus. One third or one half of the head circumference is also occupied by an *articular surface* (*circumferentia articularis*) articulating with the

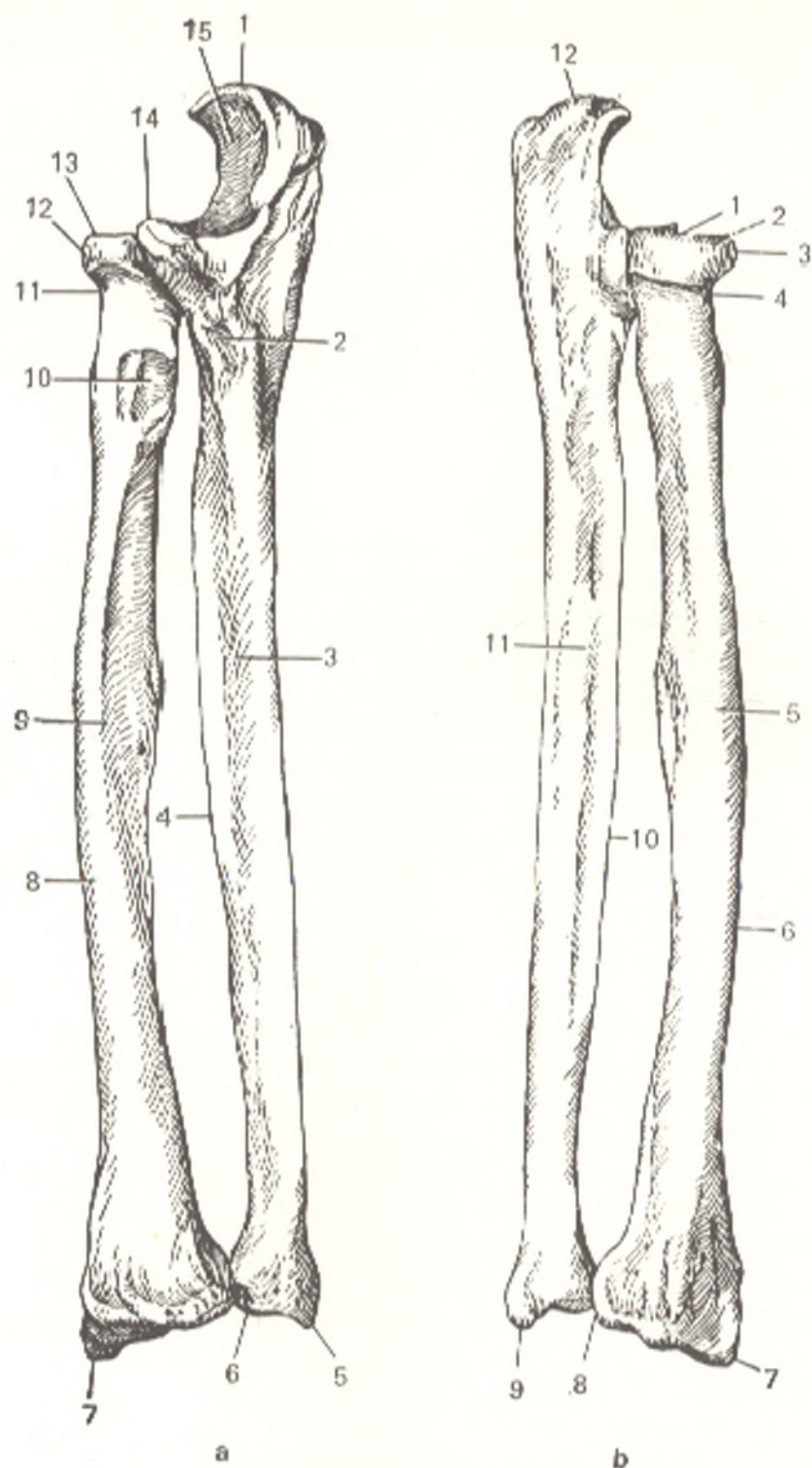


Fig. 82. Bones of the forearm.

*a*, Right radius and ulna, palmar aspect:

- 1, olecranon;
- 2, tuberositas ulnae;
- 3, facies anterior;
- 4, margo interossea;
- 5, processus styloideus ulnae;
- 6, circumferentia articularis ulnae;
- 7, processus styloideus radii;
- 8, facies lateralis;
- 9, facies anterior radii;
- 10, tuberositas radii;
- 11, collum radii;
- 12, circumferentia articularis radii;
- 13, caput radii;
- 14, processus coronoideus;

15, incisura trochlearis.

*b*, Right ulna and radius, dorsal aspect:

- 1, articular surface of radial head;
- 2, caput radii;
- 3, circumferentia articularis radii;
- 4, collum radii;
- 5, facies posterior;
- 6, margo posterior;
- 7, processus styloideus radii;
- 8, incisura ulnaris radii;
- 9, processus styloideus ulnae;
- 10, margo interossea;
- 11, facies posterior ulnae;
- 12, olecranon

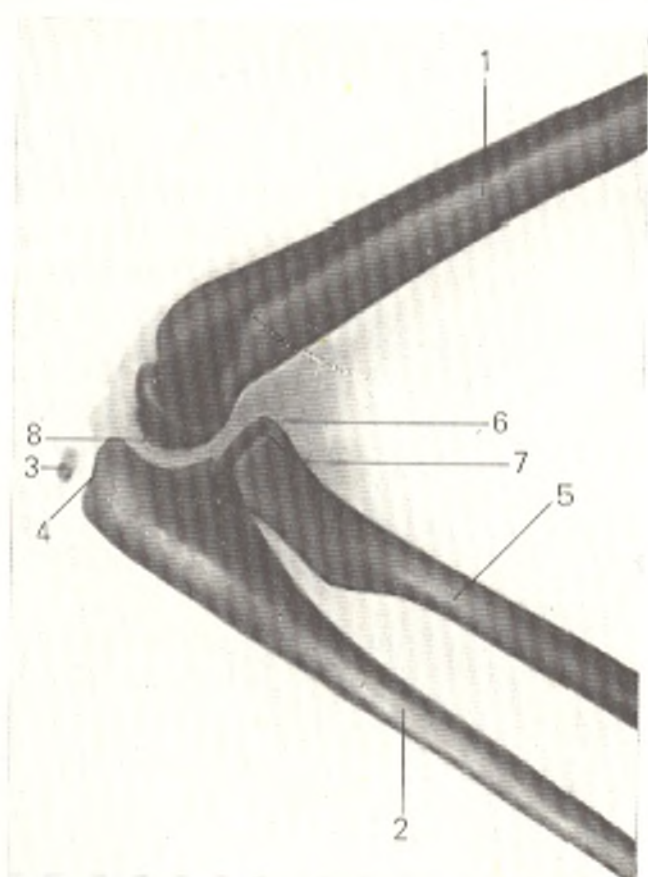


Fig. 83. Lateral radiograph of elbow joint of a 9-year-old girl.

- 1, humerus;
- 2, ulna;
- 3, ulnar epiphysis;
- 4, meta-epiphyseal cartilage;
- 5, radius;
- 6, radial epiphysis;
- 7, meta-epiphyseal cartilage;
- 8, joint space

radial notch of the ulna. The head of the radius is separated from the rest of the bone by a neck (*collum radii*) directly below which on the antero-ulnar side is the *radial tuberosity* (*tuberositas radii*) (apophysis), providing attachment for the biceps muscle of the arm. The lateral border of the distal end of the radius (epiphysis) is continuous with the *styloid process* (*processus styloideus*) (apophysis). The *carpal articular surface* (*facies articularis carpea*) on the distal epiphysis is concave and serves for articulation with the scaphoid and lunate carpal bones. The medial border of the distal radial end has a small *ulnar notch* (*incisura ulnaris*) for articulation with the *circumferentiā articularis* of the ulnar head.

**Ossification.** The distal segment of the humerus and the proximal parts of the forearm bones develop from separate ossification points occurring at six sites: in the epiphyses (humeral head in the second year, radial head in the fifth to sixth years, olecranon in the eighth to eleventh years, and the trochlea in the ninth to tenth years) and in the apophyses (medial epicondyle between the ages of six and eight and the lateral epicondyle in the 12th to 13th years) (Fig. 83). Multiple ossification points may be found in the trochlea and olecranon. As a consequence, a radiograph of the elbow joint of a child or adolescent shows many bone fragments whose presence makes differential diagnosis between a normal and pathological condition difficult. In view of this, knowledge of the specific features of ossification in the region of the elbow joint is obligatory. Synostoses occur by the age of 20. An inconstant *os sesamoideum cubiti*, or *patella cubiti*, may remain in an adult when the bone nucleus of the olecranon fails to fuse

with the ulna. The radiograph may demonstrate, among other developmental variations, a supracondylar process proximal to the medial epicondyle of the humerus and a supracondylar foramen of the humerus formed as the result of fusion of this process with the epicondyle. Ossification of the distal ends of the forearm bones is described below.

### The Elbow Joint

The **elbow joint** (*articulatio cubiti*). Three bones articulate in the elbow joint (Fig. 84): the distal end of the humerus and the proximal ends of the ulna and radius. The articulating bones form three joints invested in a common capsule (a compound joint): the **humeroulnar articulation** (*articulatio humeroulnaris*), the **humeroradial articulation** (*articulatio humeroradialis*), and the **proximal radioulnar articulation** (*articulatio radioulnaris proximalis*). The latter functions with the distal radioulnar articulation, thus forming a complex joint.

The **humeroulnar articulation** is a hinge joint with spirally deviating articular surfaces. The articular surface of the humerus is the trochlea; the groove (guiding) in it is not perpendicular to its axis but forms a certain angle with it, which facilitates spiral movements. The trochlea is joined with the ulnar trochlear notch, which has a guiding crest corresponding to a similar notch on the trochlea of the humerus.

The **humeroradial articulation** is formed by union of the humeral head with the concave surface of the radial head. Although this articulation is a ball-and-socket joint in shape, it actually permits movement on only

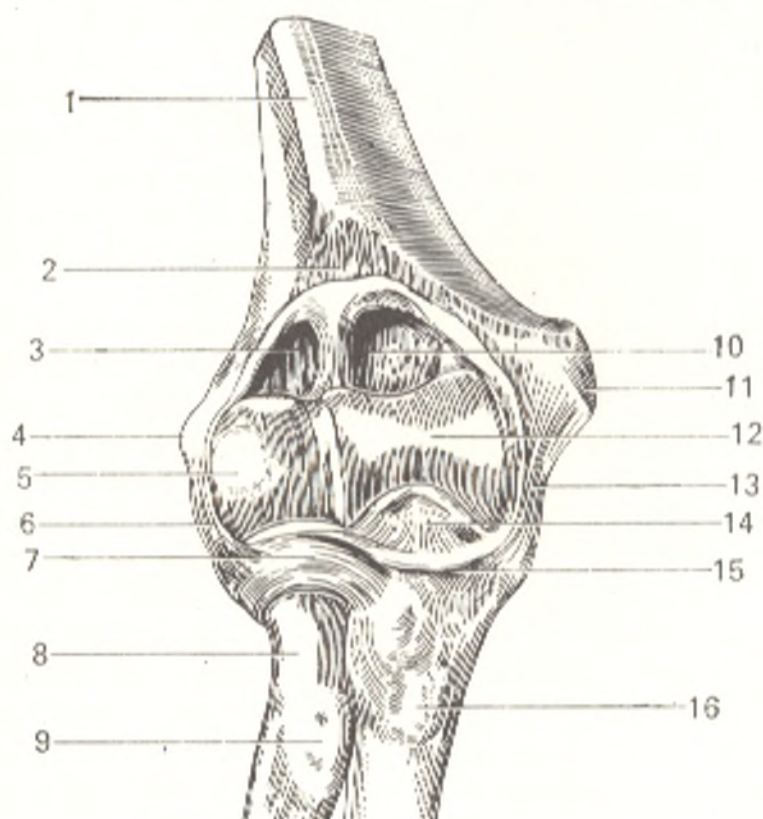


Fig. 84. Elbow joint (*articulatio cubiti*) with opened capsule, viewed from the front.

- 1, humerus;
- 2, articular capsule (cut away);
- 3, *cavum articulare*;
- 4, *epicondylus lateralis*;
- 5, *capitulum humeri*;
- 6, *lig. collaterale radiale*;
- 7, *lig. anulare radii*;
- 8, *collum radii*;
- 9, *tuberositas radii*;
- 10, *fossa coronoidea*;
- 11, *epicondylus medialis*;
- 12, *trochlea*;
- 13, *lig. collaterale ulnare*;
- 14, *processus coronoideus ulnae*;
- 15, *capsula articularis* (cut away);
- 16, *tuberositas ulnae*

two axes at the elbow joint since it is merely a part of this joint and is connected to the ulna, which limits its movement.

The **proximal radioulnar articulation** is formed by the articulating surfaces, the *circumferentia articularis radii* and the *incisura radialis ulnae*, and is cylindrical (type 1 pivot joint, Davies, 1961). The **articular capsule** embraces the cubital fossa on the posterior surface of the humerus and the coronary and radial fossae on the anterior surface but leaves the epicondyles free. It is attached on the ulna to the edge of the trochlear notch and on the radius to the neck and forms a protrusion of the **synovial membrane** (*recessus sacciformis*) in front. In front and behind the capsule is free, but on its sides are accessory ligaments, the **ulnar collateral** (lateral) and the **radial collateral** (medial) ligaments (*lig. collaterale ulnare* and *lig. collaterale radiale*), which run on the ends of the frontal axis and are perpendicular to it. The ulnar collateral ligament originates at the medial epicondyle of the humerus, spreads fan-like, and attaches to the whole medial margin of the trochlear notch on the ulna. The radial collateral ligament stretches from the lateral epicondyle of the humerus, embraces in front and behind the head of the radius with two bands, and attaches to the anterior and posterior margins of the radial notch on the ulna. The space between the two bands is filled with fibrous fibres which encircle the neck and head of the radius but do not fuse with them. These fibres are called the **anular ligament of the radius** (*lig. anulare radii*). Because of the position of the anular ligament in the horizontal plane perpendicular to the vertical pivotal axis, it directs the movement of the radius along this axis and holds it in position without hindering rotation.

Movements at the elbow joint are of two kinds. Firstly, flexion and extension of the forearm on the frontal axis occur; these movements take place at the articulation of the ulna with the trochlea of the humerus. The radius moves at the same time, sliding on the capitulum. Flexion can proceed until the forearm forms a sharp angle with the arm and is then arrested because the coronary process of the ulna abuts on the coronoid fossa on the humerus. In full extension, the arm and forearm are on a single straight line, and the olecranon abuts on the olecranon fossa on the humerus (180 degrees). Overextension is possible when the ligaments are weak, and the olecranon is small, as in some females and children. The range of movement on the frontal axis (flexion and extension of the forearm) is 140 degrees.

The second movement consisting in rotation of the radius on the longitudinal axis occurs in the humeroradial articulation as well as in the proximal and distal radio-ulnar articulations, which are thus a combined pivotal joint from the mechanical standpoint. Since the hand is joined to the lower end of the radius it follows this bone in movement. The movement during which the rotating radius crosses the ulna at an angle while the hand turns so that its dorsal surface faces upward (with the limb extended forward) is called *pronation* (the state of being prone). The opposite movement, in which the forearm bones are parallel while the hand is turned with the palm facing upward, is called *supination* (a position on the back). The range of movement in pronation and supination of the forearm is approx-

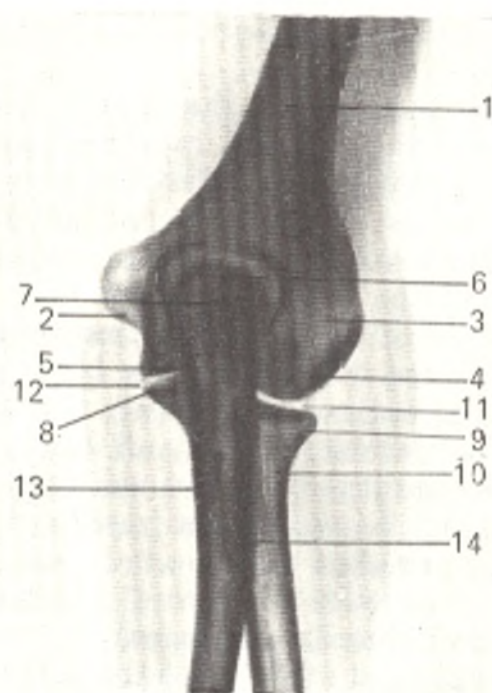


Fig. 85. Posteroanterior radiograph of elbow joint of a 25-year-old female.

- 1, diaphysis of humerus;
- 2, medial epicondyle;
- 3, lateral epicondyle;
- 4, capitulum humeri;
- 5, trochlea;
- 6, olecranon fossa;
- 7, olecranon;
- 8, coronoid process of ulna;
- 9, head of radius;
- 10, neck of radius;
- 11, humeroradial articulation;
- 12, humeroulnar articulation;
- 13, diaphysis of ulna;
- 14, tuberosity of radius

imately 140 degrees. The movements of pronation and supination take place on a diagonal forearm axis passing from the proximal end of the radius to the head of the ulna on the continuation of the constructional axis of the upper limb. When the forearm is in extension, pivotal movements of the whole limb occur, therefore, on the constructional axis. Pronation and supination of the forearm, which occurs in a rudimentary form in animals, improved in primates who climbed trees and used their limbs for grasping more actively, but attained highest development only in man as the result of labour.

**Radiographs** of the elbow joint (Fig. 85) produce an image of the distal segment of the humerus and the proximal segments of the forearm bones. All the details of these segments, which are described above, are demonstrated on posteroanterior and lateral radiographs. On a lateral radiograph the trochlea and capitulum of the humerus overlap as a result of which their shadows are seen as concentric rings. The "X-ray joint spaces" of the humeroulnar, humeroradial, and proximal radioulnar articulations are seen clearly.

The joint space of the humeroradial articulation is demonstrated particularly distinctly on a posteroanterior radiograph, while the joint space of the humeroulnar articulation can be traced for its entire distance on a lateral radiograph.

The elbow joint is supplied with *arterial blood* by the rete articulare formed by the superior and inferior ulnar collateral arteries (from the brachial artery), the middle collateral artery, the radial collateral artery (from the deep brachial artery), the radial recurrent artery (from the radial artery), the interosseous recurrent artery (from the interosseous artery), and the anterior and posterior ulnar recurrent artery (from the ulnar artery).

*Venous blood* drains along the veins of the same name into the deep veins of the upper limb, the radial, ulnar, and brachial veins. *Lymph* drains along the deep lymphatics into the cubital lymph nodes. *Innervation* of the capsule of the joint is provided by the median, radial, and ulnar nerves.

### Articulations between the Forearm Bones

These bones are joined to each other at the ends by the distal and proximal radioulnar articulations which permit movement. They are joined along the rest of the distance by the interosseous membrane. The proximal radioulnar articulation is enclosed in the capsule of the elbow joint and is described above.

The **distal radioulnar articulation** is formed by the circumferential articularis of the ulnar head and the ulnar notch on the radius. The **cartilaginous plate** (*discus articularis*) also contributes to the formation of this articulation; it is triangular and its wide base is attached to the inferior margin of the ulnar notch whereas the apex is attached to the styloid process of the ulna. The distal radioulnar articulation is a trochoid joint with a vertical pivotal axis and forms a functionally single complex joint with the similar proximal articulation.

The **interosseous membrane** (*membrana interossea*) is a strong shiny, fibrous sheet (syndesmosis) stretched between the interosseous borders of the radius and ulna and is the foundation for the attachment of the forearm bones. A separate fibrous **oblique cord** (*chorda obliqua*) passes above the superior border of the membrane. Under the cord, in the membrane, is a foramen transmitting the posterior interosseous artery. There are also several vascular foramina in the lower part of the membrane. The largest one transmits the anterior interosseous artery.

### THE BONES OF THE HAND

The bones of the hand are subdivided into the carpal and metacarpal bones and the bones which are the components of the fingers, the phalanges.

#### The Carpus

The **carpus** (Fig. 86) is an aggregate of eight short, spongy bones, **carpal bones** (*ossa carpi*) arranged in two rows of four bones each.

The **proximal**, or **first row**, nearest to the forearm, is made up of the following bones (named from the thumb): the **scaphoid bone** (*os scaphoideum*), the **lunate bone** (*os lunatum*), the **triquetral bone** (*os triquetrum*), and the **pisiform bone** (*os pisiforme*). The first three bones unite to form an ellipsoid convex surface facing the forearm for articulation with the distal end of the radius. The pisiform bone does not take part in this articulation and is attached to the triquetral bone separately. It is a sesamoid bone developing in the tendon of the ulnar flexor muscle of the wrist.

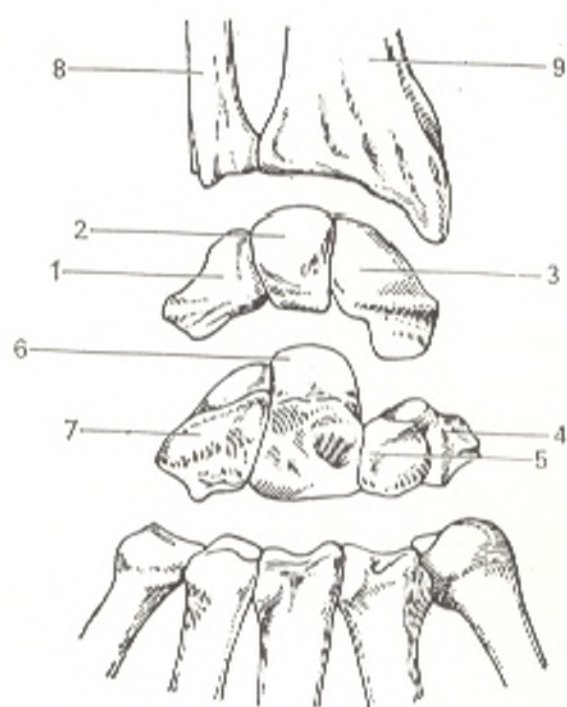


Fig. 86. Carpal bones (ossa carpi) of right hand, dorsal surface.

- 1, os triquetrum;
- 2, os lunatum;
- 3, os scaphoideum;
- 4, os trapezium;
- 5, os trapezoideum;
- 6, os capitatum;
- 7, os hamatum;
- 8, ulna;
- 9, radius

The *distal* or *second carpal row* consists of the following bones: the **trapezium**, or **larger multangular bone** (*os trapezium*, s. *os multangulum majus*) [BNA], the **trapezoid**, or **smaller multangular bone** (*os trapezoideum* s. *os multangulum minus*) [BNA], the **capitate bone** (*os capitatum*), and the **hamate bone** (*os hamatum*). The names of the bones reflect their shape. Each bone carries facets on its surfaces for articulation with the neighbouring bones. Besides, tubercles providing attachment of muscles and ligaments project from the palmar surface of some of the carpal bones, namely: *tuberculum ossis scaphoidea* on the scaphoid bone, *tuberculum ossis trapezii* on the trapezium bone, and a hook-shaped projection, *hamulus ossis hamati*, on the hamate bone (that is why it is so named). The carpal bones form collectively a vault-like convexity on the dorsal aspect and a trough-shaped concavity on the palmar surface. The **carpal sulcus** (*sulcus carpi*) is bounded on the radial side by a *prominence* (*eminentia carpi radialis*) formed by the tubercles on the scaphoid and trapezium bones; on the ulnar side it is bound by another *eminence* (*eminentia carpi ulnaris*) consisting of the hamulus of the hamate bone and the pisiform bone.

In the process of the evolution of man, the carpal bones underwent progressive development as the result of labour. The capitate bone, for instance, was 20-25 mm long in the Neanderthals but is 28 mm long in modern man. The carpus, relatively weak in the anthropoid apes and Neanderthals, is reinforced in modern man, in whom its bones are fastened so tightly by ligaments that their mobility diminishes although their strength increases in compensation. Since a blow suffered by one of the carpal bones is consequently distributed equally among the other bones and thus weakened, fractures of the carpus are rare.



### The Metacarpus

The **metacarpus** consists of five **metacarpal bones** (*ossa metacarpalia*), which are related in type to short tubular bones with one true epiphysis (monoepiphyseal bones) and are numbered in sequence, beginning with the thumb: first, second, third, fourth, and fifth. Each carpal bone has a **base** (*basis*), a **diaphysis** (body, shaft) (*corpus*) and a rounded **head** (*caput*). The bases of the second to fifth metacarpals carry shallow articular facets on their proximal ends for articulation with the second row of carpal bones and facets on their sides for articulation with each other. The base of the first metacarpal has a saddle-shaped articular surface receiving the trapezium bone, and there are no facets on the sides. The base of the second metacarpal forms an angle-like notch which embraces the trapezoid bone. The base of the fifth metacarpal has an elevation on its ulnar side, *tuberositas ossis metacarpi V*. The heads of the metacarpals carry convex articulation surfaces for uniting with the proximal phalanges of the fingers. On the sides of the heads are roughened depressions for attachment of the ligaments. The metacarpal of the thumb is the shortest but, at the same time, the strongest bone. Together with the thumb it diverges from the row of the other metacarpals. The second metacarpal is the longest, the next in length are the third, fourth and fifth bones.

### Bones of the Fingers

The **bones of the fingers** (*ossa digitorum manus*), called phalanges, are small, short, consecutive, tubular bones with one true epiphysis (monoepiphyseal bones). Each finger, with the exception of the thumb, is made up of three phalanges: **proximal** (*phalanx proximalis*), **middle** (*phalanx media*), and **distal** (*phalanx distalis*) or unguis phalanx. The thumb has only two phalanges, the proximal and the distal phalanx. In all animals the thumb is less developed than the other fingers; it is highly developed only in man. The base of each proximal phalanx carries a solitary facet for articulation with the spherical head of the corresponding metacarpal bone; the base of the middle and proximal phalanges each have two hollow facets at their base, which are separated by a ridge. These facets articulate with the heads of the proximal and middle phalanges, respectively; the heads are pulley-shaped with a groove in the middle. The distal end of the unguis phalanx is flattened and carries a *tuberosity* (*tuberositas phalangis distalis*). *Sesamoid bones* are found constantly in the metacarpophalangeal and interphalangeal joints of the thumb and inconstantly in these joints of the other fingers.

**Ossification.** The hand is the most suitable object for X-ray study of the development of the bone system in a living person. It can be seen on the **radiograph** of the newborn's hand that only the diaphyses of the tubular bones have undergone ossification; they developed from the principal ossification points during intrauterine life (from the second month). The epiphyses of the tubular bones and the carpal bones are still in the cartilaginous stage of development and are therefore not demonstrated on the radiograph.

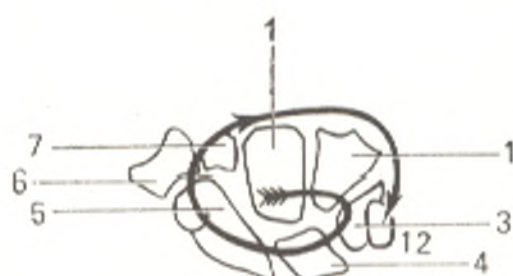


Fig. 87. Sequence of ossification of carpal bones; the figures show age in years

The following age changes in the skeleton of the hand are disclosed later.

I. Consecutive appearance of ossification points in the carpals and the epiphyses of the tubular bones.

The following method may be used to memorize more easily the terms and sequence of ossification of the carpal bones: if the radiograph is held with the fingers directed downward and the radial border to the right, the order in which the points of ossification appear in the carpals will be clockwise, starting from the hamate bone (Fig. 87). It should be borne in mind, moreover, that the time of appearance of the bone nucleus of the triquetral bone corresponds to the number of its borders (three years); it is then sufficient to add one year for each neighbouring (clockwise) bone to find the term of its ossification. As a result, the order in which the carpals ossify is as follows: capitate bone (2 months), hamate bone (3 months), triquetral bone (3 years), lunate bone (4 years), scaphoid bone (5 years), trapezium and trapezoid bones (5 and 6 years) (Figs 88 and 89).

The presence of bone nuclei of the capitate and hamate bones on the radiograph of a newborn infant is one of the signs of a full-term baby. Ossification nuclei appear in the true epiphyses of short tubular bones in the second or third year of life. Independent ossification of pseudoepiphyses is sometimes seen in the other ends of these bones. In the distal epiphyses of long tubular bones, ossification nuclei appear in the first or second year (radius) and seventh or eighth year (ulna). Ossification points appear in the sesamoid bones in the prepubertal period: in the pisiform bone between the ages of 7 to 12 in girls and 10 to 15 in boys; in the metacarpophalangeal sesamoid bones of the thumb between the ages of 10 and 15 in girls and 13 and 17 years in boys. In some cases the sesamoid bones develop from two ossification points existing separately, and are then called *ossa sesamoidea bipartita*.

II. Synostosis in the tubular bones occurs between the ages of 19 and 23 in males and 17 and 21 in females. Knowledge of the time and sequence of ossification makes it possible to recognize different diseases of the endocrine glands and other body systems attended by distorted ossification.

III. Ageing of the hand skeleton is characterized by signs common to the ageing of the bone system.

Thus the skeleton of the hand, consisting of many bones, undergoes significant age changes and X-ray examination shows many morphological details, which help to establish the "bone" age.

Fig. 88. Radiograph of hand of a 6-year-old boy.

- 1, diaphysis of ulna;
- 2, diaphysis of radius;
- 3, epiphysis of radius;
- 4, ossification nucleus of scaphoid bone;
- 5, lunate bone;
- 6, triquetral bone;
- 7, trapezium bone;
- 8, epiphysis of first metacarpal bone;
- 9, capitate bone;
- 10, hamate bone;
- 11, trapezoid bone;
- 12, epiphyses of second to fifth metacarpal bones;
- 13, epiphyses of proximal phalanges;
- 14, epiphyses of middle phalanges;
- 15, epiphyses of distal phalanges

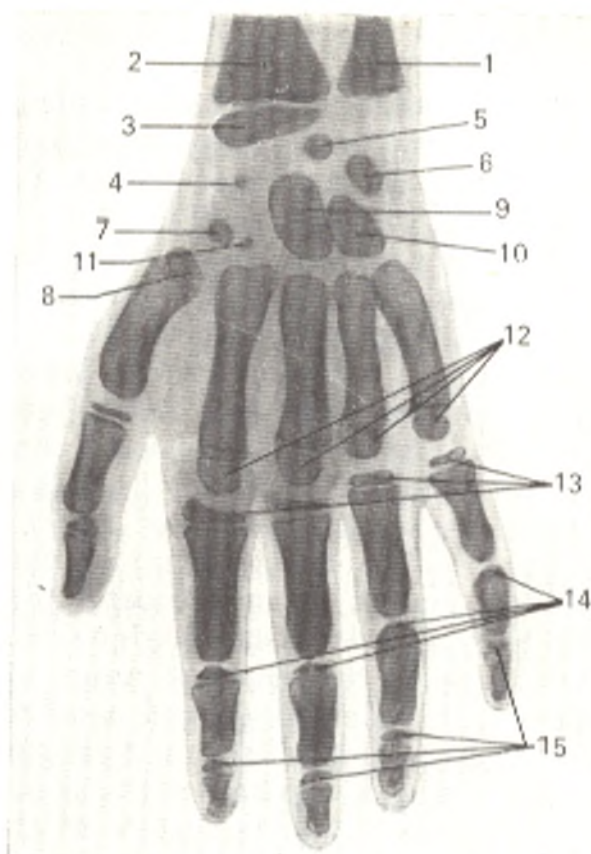
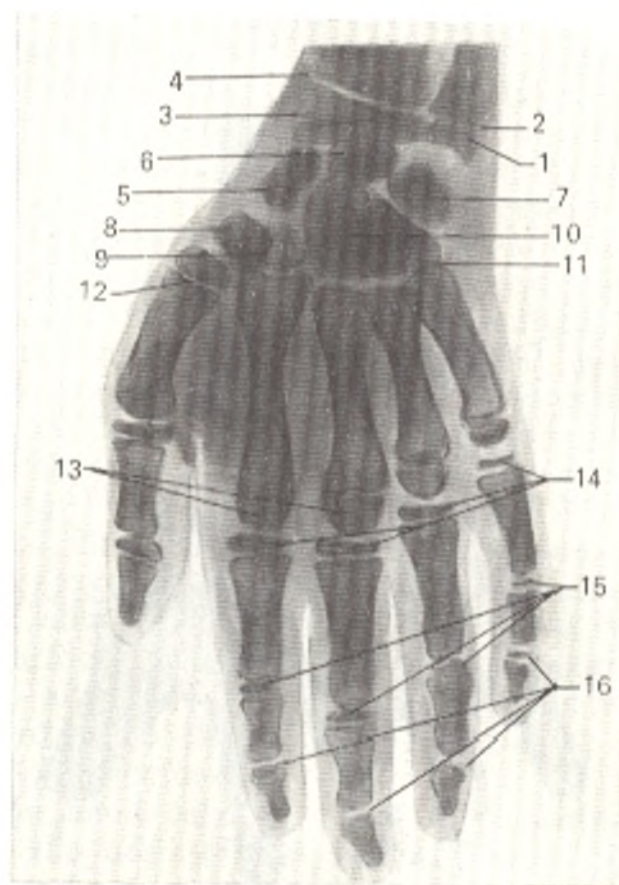


Fig. 89. Radiograph of hand of a 9-year-old boy.

- 1, epiphysis of ulna;
- 2 and 4, metaepiphyseal cartilage;
- 3, epiphysis of radius;
- 5, scaphoid bone;
- 6, lunate bone;
- 7, triquetral bone;
- 8, trapezium bone;
- 9, trapezoid bone;
- 10, capitate bone;
- 11, hamate bone;
- 12, epiphysis of first metacarpal bone;
- 13, epiphyses of metacarpal bones;
- 14, epiphyses of proximal phalanges;
- 15, epiphyses of middle phalanges;
- 16, epiphyses of distal phalanges



### Joints of the Hand Bones

1. The **joints of the hand** (*articulationes manus*) join the forearm with the hand. They are a complex joint consisting of two parts, proximal and distal, which are separated by the first row of carpal bones playing the role of a bony meniscus (Fig. 90).

A. The proximal part, the **radiocarpal**, or **wrist joint** (*art. radiocarpea*). In most mammals it is pulley-shaped, and the ulna and radius contribute equally to its formation. With the gradual development of pronation and supination, a separate joint develops between the radius and ulna, the **distal radioulnar joint** (*art. radioulnaris distalis*). Together with the proximal radioulnar joint, it forms a single complex articulation with a vertical pivotal axis (see Fig. 86). In this complex joint, the radius moves about the ulna, as a consequence of which the distal radial epiphysis becomes much larger. The development of the distal ulnar epiphysis, in contrast, is delayed, and it becomes shorter than the radial epiphysis, but, to make up for this, a special cartilaginous disc (*discus articularis*) appears on it. In man, due to the greatest range of supination and pronation, the disc becomes highly developed and acquires the shape of a triangular fibrocartilaginous plate (*fibrocartilago triangulare*). Its apex fuses with the styloid process of the ulna, the base with the medial border of the radius, and together with the carpal articular surface of the radius, the triangular fibrocartilaginous plate forms the articular concave surface of the proximal part of the hand joints. The ulna, therefore, participates in the wrist joint only by means of this cartilaginous disc and is not directly related to it. The prox-

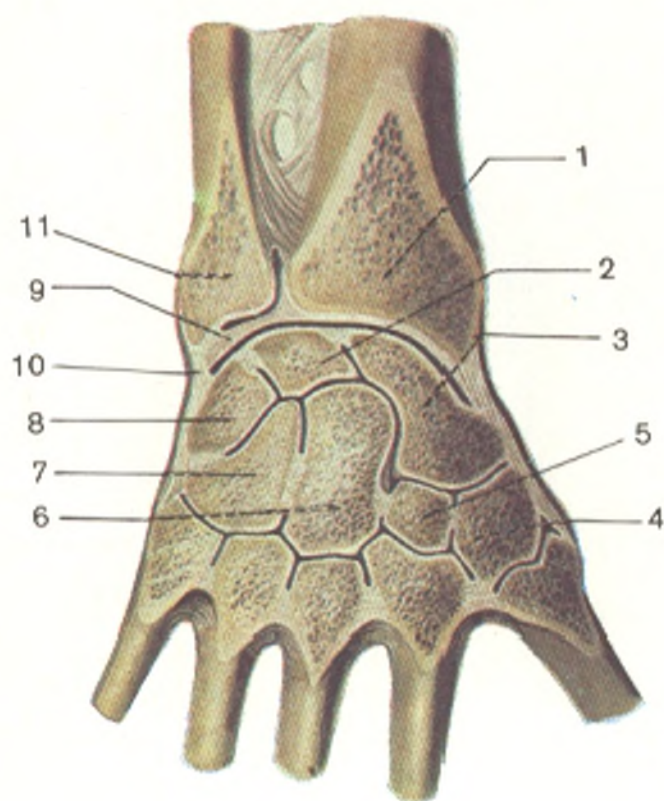


Fig. 90. Frontal section through radiocarpal joint (*articulatio radiocarpea*) and joints of hand.

- 1, radius;
- 2, os lunatum;
- 3, os scaphoideum;
- 4, os trapezium;
- 5, os trapezoidium;
- 6, os capitatum;
- 7, os hamatum;
- 8, os triquetrum;
- 9, discus articularis;
- 10, lig. collaterale carpi ulnare;
- 11, ulna

imal part of the hand joints is, consequently, called the radiocarpal and not the antebrachium carpal joint.

Accordingly, the concave articular surface of the radiocarpal joint is formed by the carpal articular surface of the radius and the triangular disc, while the articular head is formed by the proximal surface of the first row of carpals, the scaphoid and triquetral bones, which are united by intercarpal ligaments (*ligamenta intercarpea*). According to the number of bones forming it, the joint is complex, while according to the shape of the articular surfaces, it is an ellipsoid joint with two pivotal axes (sagittal and frontal).

B. The distal part, the **mediocarpal** or **midcarpal joint** (*art. medio-carpea*) is located between two rows of carpal bones, with the exception of the pisiform bone which is a sesamoid bone. The concave articular surface of this joint is formed by the distal surface of the first row of carpals. The proximal surface of the second row of carpals consisting of the trapezium, trapezoid, capitate, and hamate bones forms the articular head.

Both carpal joints (radiocarpal and midcarpal) possess their own articular capsules attached to the margins of the articular surfaces. Accessory ligaments reinforce the capsule of the radiocarpal joint on the radial and ulnar sides. These are the **lateral ligament** (*lig. collaterale carpi radiale*) passing from the styloid process of the radius to the scaphoid bone, and the **medial ligament** (*lig. collaterale carpi ulnare*) stretching from the styloid process of the ulna to the triquetral and pisiform bones. On the palmar surface of the radiocarpal joint is the **anterior radiocarpal ligament** (*lig. radiocarpeum palmare*), a broad band originating at the styloid process and the border of the articular surface of the radius and attached in the form of several bands to the scaphoid, lunate, triquetral, and capitate bones. On the dorsal surface, the capsule of the radiocarpal joint is reinforced by the **posterior radiocarpal ligament** (*lig. radiocarpeum dorsale*) passing from the radius to the bones of the first carpal row (Fig. 91). Blood vessels and nerves enter bones at the sites of attachment of the ligaments of the radiocarpal joint to them. Injury inflicted to these vessels and nerves during operations leads to pathological changes in the bones. The capsule of the midcarpal joint also encompasses the four last carpometacarpal joints, which communicate. Besides the midcarpal joint, there are **intercarpal joints** (*articulationes intercarpeae*), formed by some of the carpal bones interconnected by **interosseous intercarpal ligaments** (*ligamenta intercarpea interossea*) and articulating with one another by contiguous articulation surfaces.

The intercarpal joints are strengthened by various short ligaments (see Fig. 91) passing, for the most part, transversely from one bone to another—on the dorsal surface by **posterior intercarpal ligaments** (*ligamenta intercarpea dorsalia*) and on the palmar surface by **anterior intercarpal ligaments** (*ligamenta intercarpea palmaria*). In addition, fibrous bands spread from the capitate bone on the palmar surface to the neighbouring bones; this is the **radial carpal ligament** (*lig. carpi radiatum*).

**Movements** at the joints of the hand take place on two, mutually perpendicular axes passing through the head of the capitate bone; upon

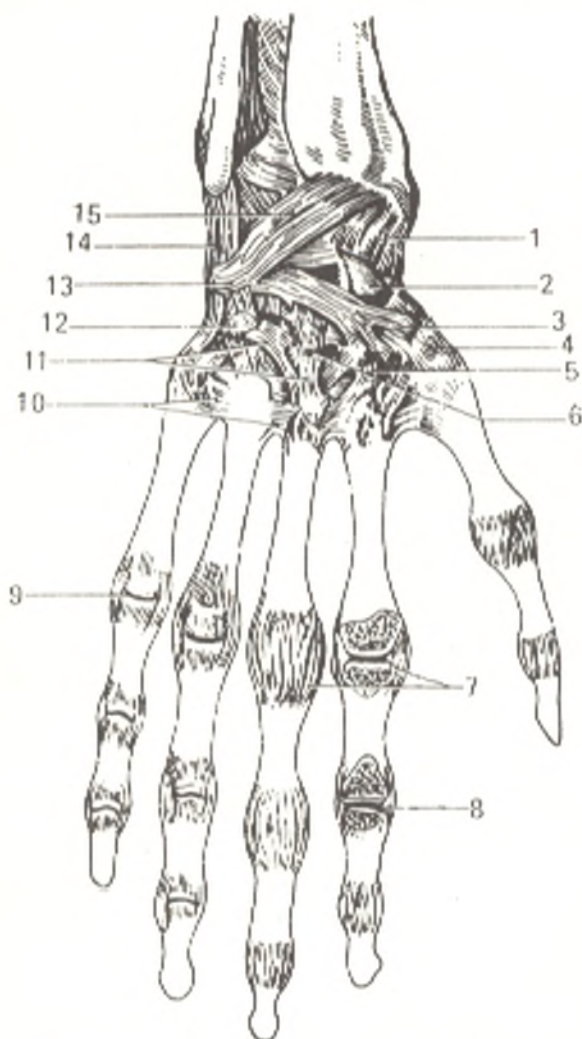


Fig. 91. Joints of hand, dorsal surface (cavities of metacarpophalangeal and interphalangeal joints of index finger are opened by a cut made parallel to dorsal surface of hand; after R. D. Sinenikov).

- 1, lig. collaterale carpi radiale;
- 2, os scaphoideum;
- 3, os trapezium;
- 4, art. carpometacarpea pollicis;
- 5, os trapezoideum;
- 6, os capitatum;
- 7, ligamenta collateralia;
- 8, art. interphalangea (opened);
- 9, art. metacarpophalangea;
- 10, ligamenta metacarpea dorsalia;
- 11, ligamenta carpometacarpea dorsalia;
- 12, os hamatum;
- 13, os triquetrum;
- 14, lig. collaterale carpi ulnare;
- 15, lig. radiocarpeum dorsale

the frontal axis (palmar flexion and extension, or dorsal flexion) and on the sagittal axis (radial abduction and adduction, or ulnar abduction). These movements are restricted by ligaments stretching perpendicular to and at the ends of the pivotal axes, namely, the collateral ligaments on the ends of the frontal axis and the dorsal and palmar ligaments on the ends of the sagittal axis. The first, therefore, restrict abduction and adduction on the sagittal axis, whereas the second ligaments restrict flexion and extension on the frontal axis. The total degree of mobility in flexion and extension measures 170 degrees. Adduction is possible to an angle of 40 degrees, abduction to 20 degrees. As in all biaxial joints, circumduction occurs here, too, when the tips of the fingers describe a circle.

The radiocarpal joint is supplied with *nutrients* by the rete articulare formed by the branches of the radial, ulnar, and anterior and posterior interosseous arteries. *Venous blood drains* into veins of the same name which convey it to the deep veins of the forearm, the ulnar, radial, and interosseous veins. The *lymph drains* along the deep lymphatics into the cubital lymph nodes. *Innervation* is accomplished by the radial, ulnar, and median nerves.

2. The **pisiform joint** (*articulatio ossis pisiformis*) is a separate joint in which the pisiform bone articulates with the triquetral bone. Two liga-

ments stretch from the pisiform bone; the **pisohamate ligament** (*lig. pisohamatum*) to the hamate bone and the **pisometacarpal ligament** (*lig. pisometacarpeum*) to the base of the third to fifth metacarpals. These ligaments are an extension of the flexor ulnar muscle of the wrist, in whose thickness this sesamoid bone is lodged.

3. The **flexor retinaculum** (*retinaculum flexorum*, s. *lig. carpi transversum*) [BNA], bears no direct relation to the hand joints; it stretches between the eminentia carpi radialis and the eminentia carpi ulnaris and thus bridges the carpal sulcus and converts it into the **carpal tunnel** (*canalis carpi*). This canal transmits the median nerve and the tendons of the finger flexors; hence the name, flexor retinaculum (retainer of the tendons of the flexors).

4. The **carpometacarpal joints** (*articulationes carpometacarpeae*) are formed by the second row of carpal bones and the bases of the metacarpals. With the exception of the carpometacarpal joint of the thumb, all these joints are plane articulations and are strengthened from both the dorsal and the palmar surfaces by the tightly stretched **dorsal and palmar carpometacarpal ligaments** (*ligamenta carpometacarpea dorsalis* and *palmaris*), as a result of which they permit a very small range of movement. Sliding to an angle of 5-10 degrees to either side can occur. Since the carpometacarpal joints are very flat, possess many facets, and have a strong articular capsule and ligaments, they are included in the group of amphiarthroses, which reinforce the root of the hand and increase the resistance of the palm during the force movements of the multiarticular muscles, the finger flexors. The four bones of the distal carpal row and the four metacarpal bones (second to fifth), which are firmly joined by articulations permitting little movement, form a whole *firm base of the hand* from the mechanical standpoint.

The carpometacarpal joint of the little finger permits somewhat greater freedom of movement. The articular surface of the base of the fifth metacarpal is almost saddle-like, as a result of which the little finger can be opposed to the thumb, but within a very limited range. The common cavity of the carpometacarpal joints is encompassed by a capsule and is shaped like a transverse cleft communicating with the midcarpal articulation and the **intermetacarpal joints** (*articulationes intermetacarpeae*). These are unions between the adjacent bases of the last four metacarpals; the articulating surfaces of the bases of these bones are connected by means of strong ligaments, the **interosseous metacarpal ligaments** (*ligamenta metacarpea interossea*). The capsules of the intermetacarpal joints are reinforced by transversely passing **dorsal and palmar metacarpal ligaments** (*ligamenta metacarpea dorsalis* and *palmaris*).

The **carpometacarpal joint of the thumb** (*art. carpometacarpea pollicis*) is absolutely isolated from the other carpometacarpal joints and differs from them sharply in structure and movements. It is formed by the saddle-shaped articular surfaces of the trapezium bone and the base of the first metacarpal, which are invested in a wide articular capsule. Since it is a typical joint, it permits movements on two mutually perpendicular axes: a transverse axis passing through the trapezium bone and an anteroposterior axis passing through the base of the first metacarpal. Flexion and extension of the

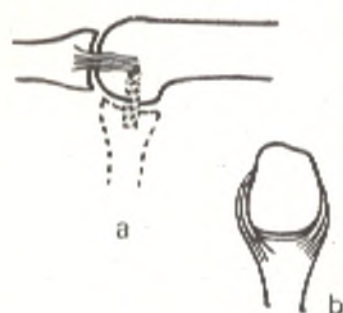


Fig. 92. Position of ligaments on the sides of interphalangeal joint.

a, seen from the side (in extension and flexion);  
b, seen from below (in flexion)

thumb together with the metatarsal occurs about the first axis, but since the axis is not absolutely transverse, the thumb is displaced toward the palm in flexion and set in opposition to the little finger and the other fingers. This movement is called *opposition*. Movement in the opposite direction is called *reposition*. Movements on the anteroposterior axis consist in abduction and adduction of the thumb to the index finger. The range of movement is 45-60 degrees in abduction and adduction and 35-40 degrees in opposition and reposition. Circumduction also takes place. The saddle joint of the thumb has evolved in the process of man's evolution as a result of work performed. In the Neanderthals, for instance, it was evidently flattened and therefore permitted a lesser range of movement than that possible in modern man.

5. The **metacarpophalangeal joints** (*articulationes metacarpophalangeae*), between the convex heads of the metacarpals and the facets on the base of the proximal phalanges, are rather ellipsoid in character. The ligament apparatus consists of a loose capsule and two accessory **collateral ligaments** (*ligamenta collateralia*) passing obliquely from the depressions on the radial and ulnar surfaces of the metacarpal heads to the sides of the base of the proximal phalanges. On the palmar aspect of the capsule is a thickening containing a fibrous cartilage, the **palmar ligament** (*lig. palmare*). Connected with this thickening are strong fibrous ligaments, the **deep transverse metacarpal ligaments** (*ligamenta metacarpea transversa profunda*), stretched between the heads of the second to fifth metacarpals on the palmar surface.

**Movements** at the metacarpophalangeal joints take place on two axes: flexion and extension of the whole finger with a range of movements of 90-100 degrees occur on the transverse axis, abduction and adduction of the finger (a range of 45-50 degrees) occur on the anteroposterior axis. The last type of movement is possible only when the fingers are in extension, when the collateral ligaments are relaxed (in flexion they are tightened and prevent side movements). Circumduction of the finger in a quite wide range is also possible.

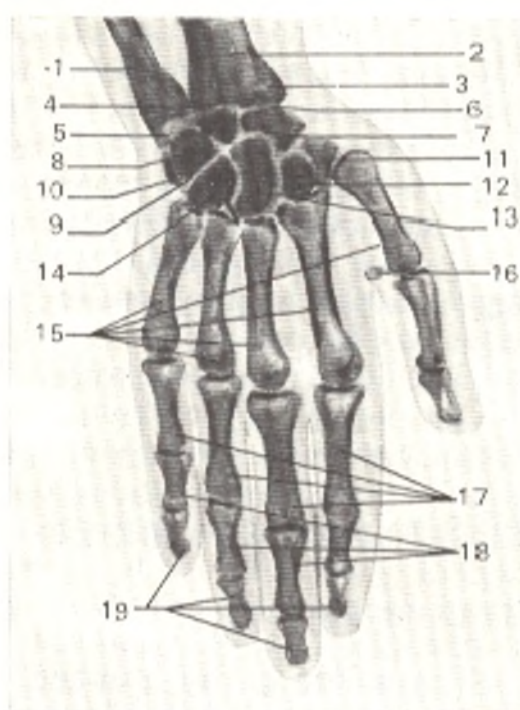
6. The **interphalangeal joints** (*articulationes interphalangeae manus*) between the head and base of the adjoining phalanges are typical hinge joints allowing flexion and extension on a transverse (frontal) axis. The range of movements is 110-112 degrees at the proximal interphalangeal joints and 80-90 degrees at the distal joints. Accessory **collateral ligaments** (*ligamenta collateralia*) pass on the sides of the joints (Fig. 92).

A palmar-view **radiograph** of the hand demonstrates all the bones forming it and their details (Fig. 93). The "X-ray joint spaces" are seen



Fig. 93. Radiograph of hand of 38-year-old male (palmar view).

- 1, ulna;
- 2, radius;
- 3, styloid process of radius;
- 4, distal radioulnar articulation;
- 5, fibrocartilago triangulare;
- 6, radiocarpal joint space;
- 7, scaphoid bone;
- 8, lunate bone;
- 9, triquetral bone;
- 10, pisiform bone;
- 11, trapezium bone;
- 12, trapezoid bone;
- 13, capitate bone;
- 14, hamate bone;
- 15, metacarpal bones;
- 16, sesamoid bone of thumb;
- 17, proximal phalanges;
- 18, middle phalanges;
- 19, distal phalanges



as bands of diminished density between the articular surfaces of the respective bones. The "joint space" of the radiocarpal joint is expanded in the medial part corresponding to the localization of the triangular fibrocartilage which is penetrable to X-rays.

Besides the main bones of the hand skeleton, a radiograph may demonstrate *accessory*, or supernumerary, inconstant bones: (1) *os centrale carpi*, a rudiment of the bone of this name in the front limbs of animals; it is found between the trapezium, capitate, and scaphoid bones; (2) *os styloideum*, an independently developed styloid process of the third metacarpal bone; (3) *os trapezoideum secundarium*, as if a duplication of the trapezoid bone; (4) *os triangulare*, part of the styloid process, which failed to fuse. These inconstant bones may be the cause of diagnostic errors.

The hand joints are *vascularized* from the deep palmar arterial arcus and the palmar and dorsal carpal rete. *Venous blood drains* into the deep veins of the hand and from there into the ulnar, radial, and interosseous veins. *Lymph is drained* along the deep lymphatics into the cubital lymph nodes. The capsules of the joints are *innervated* by branches of the median, radial, and ulnar nerves.

The skeleton of the hand inherited by the ancient hominids from animal ancestors changed in the process of evolution of man under the effect of labour. As a result the following *features characteristic of modern man* appeared in it.

1. Enlargement of absolute and relative (as compared to the other fingers) dimensions of the thumb bones.
2. A saddle shape of the first carpometacarpal joint.
3. Transposition of the thumb from the plane of the other fingers toward the palm, as a consequence of which its opposition to the other fingers, taking place in the saddle joint, increased in range.
4. Displacement in the same direction of the carpals, the trapezium, and lunate bones, which are joined to the thumb.

5. As a consequence of the displacement of these bones, deepening of "Diogenes cup", a concavity under the flexor retinaculum, which lodges the tendons, nerves, and vessels.

6. Shortening and straightening out of the phalanges of the index, middle, ring, and little fingers, which facilitates a variety of movements of the hand and its different parts.

Besides this reorganization of the bones and joints, there are also changes in the neuromuscular apparatus of the hand. The general development of the central nervous system in association with labour and the acquisition of articulate speech led to the upper limb, and its most important part, the hand, in particular, becoming the organ of work, the organ of tactile sense, and partly a means of communication (gesticulation).

## THE SKELETON OF THE LOWER LIMB

### THE PELVIC GIRDLE

The pelvic girdle is made up of the paired hip or innominate bone. The **hip bone** (*os coxae*) is a flat bone concerned with the function of movement (takes part in articulations with the sacrum and femur), protection (shields the pelvic organs), and support (transfers the weight of the whole proximal part of the body to the lower limbs). The latter function prevails, and this determines the complex structure of the hip bone and its formation from fusion of three separate bones, the **ilium** (*os ilium*), the **pubis** (*os pubis*) and the **ischium** (*os ischii*). These bones fuse in the region bearing the greatest weight, namely, in the region of the acetabulum, the articular cavity of the hip joint, by means of which the pelvic girdle is connected to the free lower limb. The ilium is above the acetabulum, the pubis below and to the front of it, and the ischium is below and to the back of the acetabulum. In individuals under 16 years of age these bones are separated one from another by layers of cartilage which in an adult undergo ossification, i.e. synchondrosis changes to synostosis. As a result the three bones fuse to form a single bone possessing great strength necessary for bearing the weight of the whole trunk and head. The **acetabulum** ("vinegar curet" from *L acetum* vinegar) is on the lateral surface of the hip bone and serves for articulation with the head of the femur. It is a rather deep, cup-shaped cavity with a high rim, in the medial side of which is a **notch** (*incisura acetabuli*). The smooth **articular surface** of the acetabulum (*facies lunata*) is crescent-shaped; the centre, the **acetabular fossa** (*fossa acetabuli*) and the part nearest to the notch are rough.

### THE ILIUM

The **ilium** fuses by means of its short, thick, inferior part, called the **body** (*corpus ossis ilii*), with the other parts of the hip bone in the region of the acetabulum; the superior fan-shaped and fairly thin part of the ilium forms the **wing or ala** (*ala ossis ilii*). The relief of the bone is mainly deter-

mined by the muscles under the effect of which crests, lines, and spines formed at the sites of tendon attachment, and fossae formed where the muscles originated. The superior free border of the wing, for instance, is a sinuous crest (*crista iliaca*) to which three broad abdominal muscles are attached. The crest ends anteriorly as the **anterior superior iliac spine** (*spina iliaca anterior superior*) and posteriorly as the **anterior posterior iliac spine** (*spina iliaca posterior superior*). Below each of these spines are another two spines on the anterior and posterior iliac borders, the **anterior and posterior inferior iliac spines** (*spina iliaca anterior inferior* and *spina iliaca posterior inferior*). The inferior spinae are separated from the superior spinae by notches. Below and to the front of the anterior inferior spine at the junction of the ilium with the pubis is the **iliopubic eminence** (*eminentia iliopectinea*) and below the posterior inferior spine is the deep **greater sciatic notch** (*incisura ischiadica major*), continuous downward with the **ischial spine** (*spina ischiadica*), which is on the ischium. The inner (medial) surface of the iliac wing is smooth, slightly concave, and forms the **iliac fossa** (*fossa iliaca*) produced from supporting the viscera in vertical posture of the body. Posterior to and below the fossa is an ear-shaped articular surface, **auricular surface** (*facies auricularis*) the site of articulation with the corresponding surface of the sacrum. Behind and above the auricular surface is the **iliac tuberosity** (*tuberositas iliaca*) giving attachment to the interosseous sacro-iliac ligaments. The iliac fossa is separated from the medial surface of the distally located iliac body by an arched edge, the **arcuate line** (*linea arcuata*). Occasionally conspicuous rough lines, marks of the origin of the gluteal muscles, are seen on the external (lateral) surface of the iliac wing.

#### THE PUBIS

The **pubic bone** (*os pubis*) has a short thickened **body** (*corpus ossis pubis*) adjoining the acetabulum, and the **superior and inferior rami** (*ramus superior* and *ramus inferior ossis pubis*) forming an angle. At the apex of the angle facing the midline is an oval **symphyseal surface** (*facies symphysialis*) for articulation with the contralateral pubic bone. A small **pubic tubercle** (*tuberculum pubicum*) lies 2 cm lateral of this surface; the **pectineal line** (*pecten ossis pubis*) runs from the tubercle along the posterior border of the superior surface of the superior ramus and is continuous posteriorly with the arcuate line on the ilium described above. The inferior surface of the superior **pubic ramus** carries a small groove, the **obturator groove** (*sulcus obturatorius*) transmitting the obturator vessels and nerve.

#### THE ISCHIUM

The **ischium** (*os ischii*) has, like the pubis, a **body** (*corpus ossis ischii*), which forms part of the acetabulum, and a **ramus** (*ramus ossis ischii*). The body and the ramus meet at an angle, the apex of which is greatly thickened and is the **ischial tuberosity** (*tuber ischiadicum*). On the posterior border of the body, upward from the ischial tuberosity, is the **lesser sciatic notch** (*incisura ischiadica minor*) separated from the **greater sciatic notch** (*incisura*

*ischiadica major*) by the **ischial spine** (*spina ischiadica*). The ischial ramus branching from the ischial tuberosity fuses with the inferior pubic ramus. As a result the rami of the pubis and ischium surround the **obturator foramen** (*foramen obturatum*) which is located inferior and medial to the acetabulum and is triangular with rounded angles.

**Ossification.** A radiograph of the pelvis at birth demonstrates the three parts of the hip bone separated by wide spaces corresponding to the cartilage which is not visible. No area of diminished density is seen in the region of the acetabulum between the bodies of the pubis and ischium because the projections of these bones here are superimposed and are demonstrated as a single bone structure resembling the claws of a lobster. The obturator foramen is still incompletely formed. By the eighth year the rami of the pubis and ischium fuse to form a single os ischiopubicum, while at the age of 14-16 this bone fuses in the region of the acetabulum with the ilium to form the hip bone. Accessory points appear almost at all sites of muscle and ligament attachment (between 12 and 19 years of age) and fuse with the main bulk of the bone between the ages of 20 and 25. It should be pointed out that the sex differences in the pelvis become apparent after the age of ten. Until that time the pelvis retains the shape of a high funnel typical of children. Synostosis in the region of the acetabulum is produced with the participation of accessory bony structures resembling the intercalated bones of the skull. If such bones persist for a long time, they are called ossa acetabuli. On a radiograph they may be mistaken for fragments.

#### JOINTS OF THE PELVIC BONES

The **joints of the pelvic bones** in man (Fig. 94) reflect the development of these bones in association with the changing functional conditions in the process of phylogenesis. As mentioned above, the pelvis of quadrupedal vertebrates is not subjected to a heavy load because of the horizontal position of the animals. With the change to an upright position the human pelvis became a support for the viscera and the place where the weight is transferred from the trunk to the lower limbs, as a consequence of which it has to sustain a great load. The separate bones united by cartilage fuse to form a single bone structure, the hip bone, so that the synchondrosis is converted to synostosis. The synchondrosis between both pubic bones, however, does not develop into a synostosis but becomes a hemiarthrosis (Fig. 95).

The articulation of both pelvic bones with the sacrum requiring a combination of mobility and strength acquires the form of a true joint, diarthrosis, strengthened reliably by ligaments (syndesmosis).

As a result all types of joints reflecting the successive developmental stages of the skeleton are encountered in the human pelvis: synarthroses in the form of syndesmoses (ligaments); synchondroses (between the separate parts of the hip bone) and synostoses (after their fusion to form the hip bone); hemiarthroses (the pubic symphysis) and diarthroses (the sacro-iliac joint). The total range of movements between the pelvic bones is very small (4 to 10 degrees).

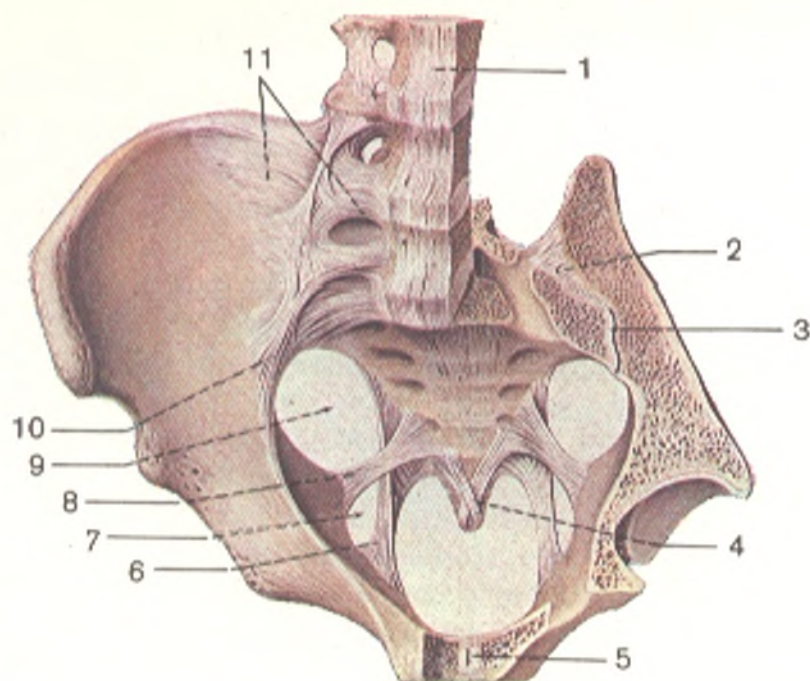


Fig. 94. Ligaments and joints of pelvis seen from above (ligaments and joints of lower limb girdle; after R. D. Sinelnikov).

Part of left innominate bone, left parts of sacrum and third, fourth and fifth lumbar vertebrae are removed by section through horizontal and sagittal planes.

1, lig. longitudinale anterius;  
2, ligamenta sacroiliaca interossea;  
3, art. sacroiliaca (cavum articulare);

4, lig. sacrococcygeum ventrale;  
5, symphysis pubica;  
6, lig. sacrotuberale;  
7, foramen ischiadicum minus;  
8, lig. sacrospinale;  
9, foramen ischiadicum majus;  
10, ligamenta sacroiliaca ventralia;  
11, lig. iliolumbale

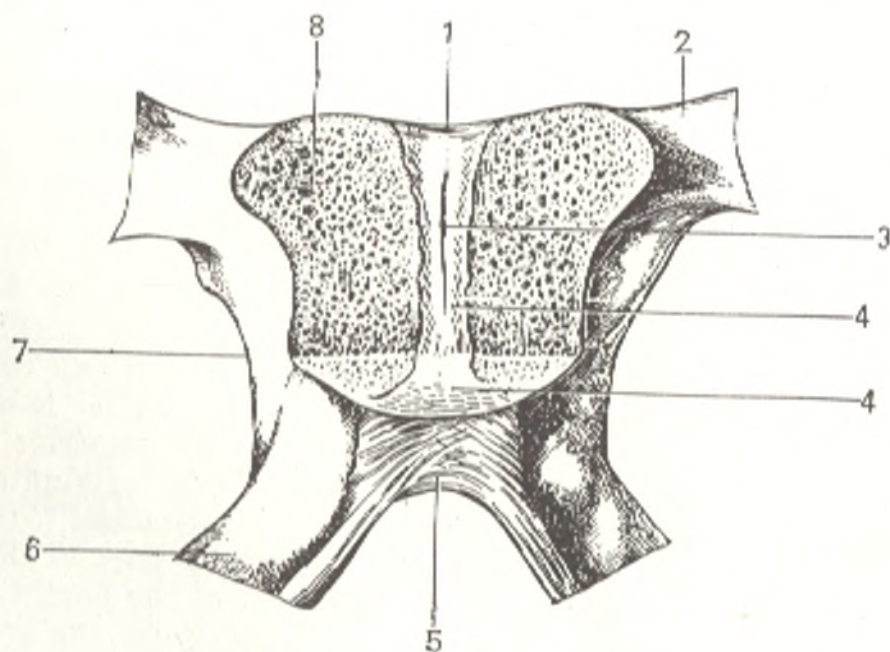


Fig. 95. Pubic symphysis, frontal section.

1, lig. pubicum superius;  
2, ramus superior ossis pubis;  
3, cavum symphyseos;  
4, discus interpubicus;

5, lig. arcuatum pubis;  
6, ramus ossis ischii;  
7, ramus inferior ossis pubis;  
8, spongy bone substance

1. The **sacro-iliac joint** (*art. sacroiliaca*) is formed by the contiguous auricular surfaces of the sacrum and ilium. These surfaces are congruous and covered by a thin layer of fibrous cartilage. The sacrum is wedged between the two iliac bones, as a result of which it cannot be displaced anteriorly and downward by the weight of the trunk until the bracings of the pelvic vault are separated; the sacrum is therefore the *key of the pelvis* (Lesgaft). This key is strengthened by the **interosseous sacro-iliac ligaments** (*ligamenta sacroiliaca interossea*) stretching in the form of short bundles between the iliac tuberosity and the sacrum; they are the strongest ligaments in the human body. They serve as an axis on which movement at the sacro-iliac joint occurs. The joint is strengthened also by other ligaments connecting the sacrum to the ilium: anteriorly by the **anterior sacro-iliac ligaments** (*ligamenta sacroiliaca ventralia*) (which are tightly fused with the capsule) and posteriorly by the **posterior sacro-iliac ligaments** (*ligamenta sacroiliaca dorsalia*) running downward from the superior and inferior posterior iliac spine to the sacral vertebrae, and by the **iliolumbar ligament** (*lig. iliolumbale*) stretched between the transverse process of the fifth lumbar vertebra and the iliac crest.

The sacro-iliac joint is *vascularized* from the lumbar, iliolumbar, and lateral sacral arteries. *Venous blood drains* into the corresponding veins. *Lymph is drained* along the deep lymphatics into the sacral and lumbar lymph nodes. *Innervation* of the joint is provided by the branches of the lumbar and sacral plexus.

2. The **pubic symphysis** (*symphysis pubica*) is on the midline and joins the pubic bones. A fibrocartilaginous plate, the **interpubic disc** (*discus interpubicus*) is lodged between the facies symphysialis of these bones, which face each other and are covered with hyaline cartilage. A narrow synovial slit-like cavity is seen in this disc nearer to its posterior surface (hemiarthrosis) usually from the age of 7 years. The pubic symphysis is strengthened by thick periosteum and ligaments, above by the **superior pubic ligament** (*lig. pubicum superius*) and below by the **arcuate ligament** (*lig. arcuatum pubis*), which rounds off the **subpubic angle** (*angulus subpubicus*).

3. The **sacrotuberous** and **sacrospinal ligaments** (see Fig. 94) are two strong interosseous ligaments connecting on each side the hip bone with the sacrum. The **sacrotuberous ligament** (*lig. sacrotuberale*) stretches from the ischial tuberosity to the lateral borders of the sacrum and coccyx and is partly continuous with the vertically stretched superficial bundles, the dorsal sacro-iliac ligaments, with which it reaches the superior posterior iliac spine. The **sacrospinal ligament** (*lig. sacrospinale*) originates at the ischial spine, crosses the sacrotuberous ligament, and is attached to the lateral border of the lower part of the sacrum and the upper part of the coccyx. The ligaments described contribute to the formation of the bony framework of the pelvis in the posteroinferior segment and transform the greater and lesser sciatic notches to the **greater and lesser sciatic foramina** (*foramen ischiadicum majus* and *minus*).

4. The **obturator membrane** (*membrana obturatoria*) is a fibrous plate closing the obturator foramen of the pelvis except in its superolateral part.

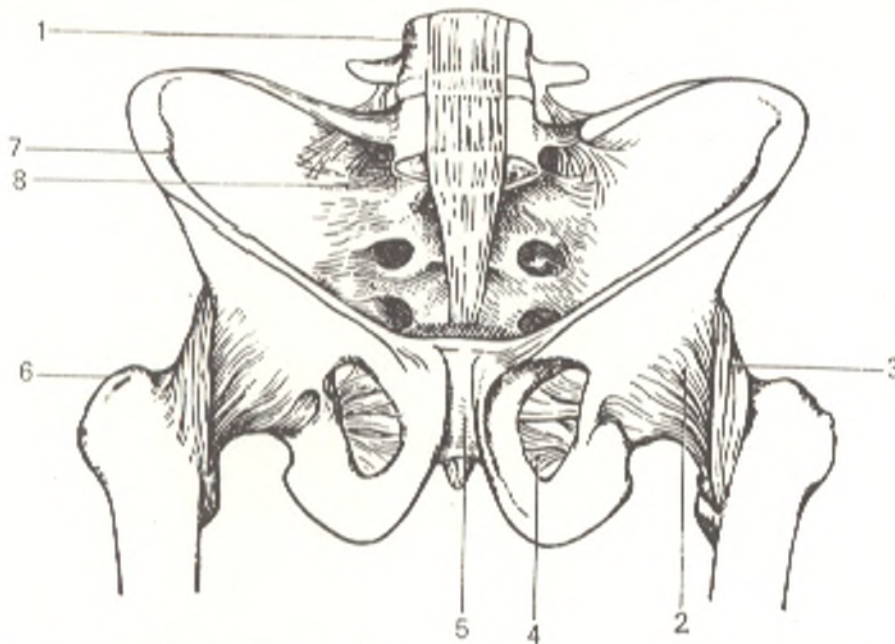


Fig. 96. Male pelvis and hip joint (art. coxae), anterior aspect.

1, fourth lumbar vertebra;  
2, capsula articularis;  
3, lig. iliofemorale;  
4, membrana obturatoria;

5, symphysis pubica;  
6, trochanter major;  
7, spina iliaca anterior superior;  
8, ligamenta sacroiliaca ventralia

It is attached to the edges of the obturator sulcus of the pubis found here and thus converts this sulcus to the **obturator canal** (*canalis obturatorius*) transmitting the obturator vessels and nerves (Fig. 96).

#### THE PELVIS AS A WHOLE

Both hip bones unite with each other and with the sacrum to form a bony ring, the **pelvis** (Fig. 96), which connects the trunk with the free lower limbs and at the same time, encloses a cavity containing the viscera. The bony ring is divided into two parts: a wider upper part, the **greater, false pelvis** (*pelvis major*) and a narrower lower part, the **lesser, true pelvis** (*pelvis minor*). The greater pelvis is bounded only laterally by ilia, which are rather widely spread out. It has no bony walls in front and the deficiency in its posterior boundary is filled by the lumbar vertebrae. The superior boundary of the lesser pelvis, separating it from the greater pelvis is the **terminal line** (*linea terminalis*) formed by the promontorium, arcuate line of the ilia, the pectines of the pubic bones, and the superior border of the pubic symphysis. The opening thus bounded is called the *pelvic inlet* (*apertura pelvis superior*). The *cavity of the true pelvis* (*cavum pelvis*) is below the inlet. Anteriorly, the wall of the pelvic cavity, formed by the pubic bones and their articulation, is very short. In contrast, posteriorly the wall is long and is formed by the sacrum and coccyx. The lateral walls of the true pelvis are formed by areas of the hip bones corresponding to the acetabuli and by the ischiac bones together with the ligaments reaching them from the sacrum. Below the pelvic cavity ends as the *pelvic outlet* (*apertura pelvis inferior*)

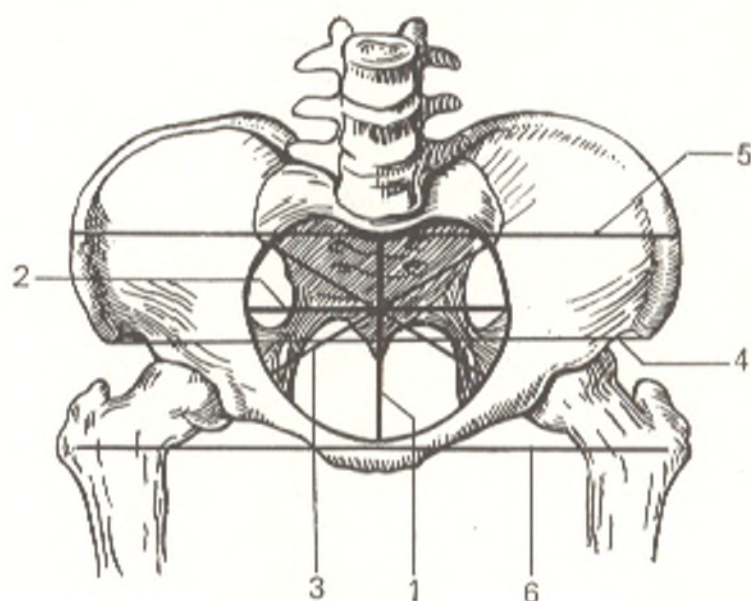


Fig. 97. Lines of female pelvis measurements.

- |   |  |
|---|--|
| 1, anteroposterior diameter, diameter recta ( <i>conjugata anatomica</i> ); | anterior spines of iliac bones, <i>distantia spinarum</i> ;                            |
| 2, transverse diameter, diameter transversa;                                | 5, maximum distance between iliac crests, <i>distantia cristarum</i> ;                 |
| 3, oblique diameter, diameter obliqua ( <i>distantia obliqua</i> );         | 6, distance between greater trochanters of both femurs, <i>distantia trochanterica</i> |
| 4, distance between superior  |  |

bounded by the rami of the pubic and ischiac bones, ischial tuberosities with the ligaments stretching from the sacrum to the ischiac bones, and, finally, by the coccyx. The size and shape of the pelvis is determined by measurements on cadavers and on live subjects. We mention here only measurements used by obstetricians for prognosticating labour. On a live subject the pelvis is measured with a pair of compasses. The following three transverse measurements are made in the greater pelvis (Fig. 97).

1. The distance between the two superior anterior iliac spines, the *interspinous diameter* (*distantia spinarum*), measuring 25-27 cm.

2. The distance between the two *cristae iliaca*, the *intercristal diameter* (*distantia cristarum*), measuring 28-29 cm.

3. The distance between the two greater trochanters, *intertrochanteric diameter* (*distantia trochanterica*), measuring 30-32 cm.

After that the external anteroposterior diameter is measured.

4. The distance from the symphysis to the depression between the last lumbar and first sacral vertebrae (20-21 cm). To determine the true anteroposterior diameter of the pelvis (*conjugata vera*), 9.5-10 cm are subtracted from the value of the external anteroposterior diameter. The result will be the obstetric conjugate diameter (*conjugata vera s. gynecologica*), which is usually 11 cm (Fig. 98).

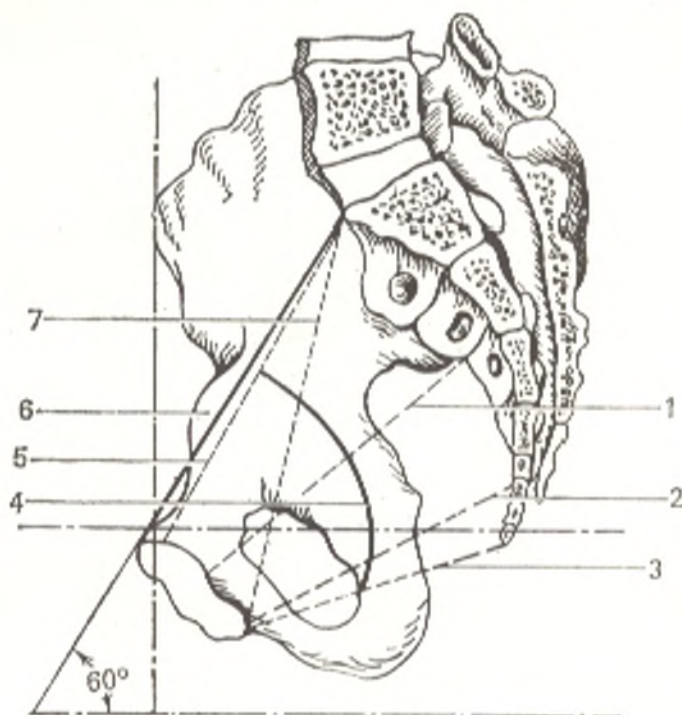
Finally, the external oblique diameter is measured.

5. The distance between the anterior and postero-superior spinae of the iliac bones (lateral conjugate); it measures 14.5-15 cm



Fig. 98. Sagittal diameters of true pelvis of female (sagittal section).

- 1, anteroposterior diameter of middle part of cavity of true pelvis;
  - 2, anteroposterior diameter of lower part of cavity of true pelvis;
  - 3, anteroposterior diameter of pelvic outlet;
  - 4, axis of pelvis;
  - 5, obstetric, or available, conjugate, conjugata gynecologica s. vera;
  - 6, anatomic conjugate, conjugata anatomica;
  - 7, diagonal conjugate, conjugata diagonalis;
- 60°, angle of pelvic inclination



6. To determine the transverse diameter of the pelvic inlet (13.5-15 cm), the intercrystal diameter (29 cm) is divided by 2 or 14-15 cm are subtracted from its value.

7. To measure the transverse diameter of the pelvic outlet (11 cm), the compasses are set on the medial borders of the ischial tuberosities, and 1.0-1.5 cm are added to the value obtained (9.5 cm) for the thickness of the soft tissues.

8. To measure the anteroposterior diameter of the pelvic outlet (9-11 cm), the compasses are set on the apex of the coccyx and the inferior border of the symphysis. From the value obtained (12.-12.5 cm), we subtract 1.5 cm to compensate for the thickness of the sacrum and soft tissues.

By connecting the central points of the anteroposterior diameters of the pelvis, including the outlet and inlet, the *axis of the pelvis* is drawn in the form of an anteriorly concave line passing through the centre of the pelvic cavity. In its natural position, the pelvis is markedly inclined anteriorly (*inclinatio pelvis*) so that the plane of the pelvic inlet, or the anatomical conjugate, meets the horizontal plane at an angle which is larger in females than in males. Inclination of the pelvis is due to the upright position of the human body. This erect position also causes the curving of the spine, with which the pelvis is directly connected. The angle of inclination of the pelvis ranges between 75 and 55 degrees. When a person is sitting, the pelvis takes an almost horizontal position as a consequence of which the angle measures only 7 degrees.

The *shape and size of the pelvis* reflect its function. In quadrupeds the pelvis, which does not have to bear the weight of the whole superincumbent body and support the viscera, is relatively small and has a narrow elongated form with a sharply predominant anteroposterior diameter of the true

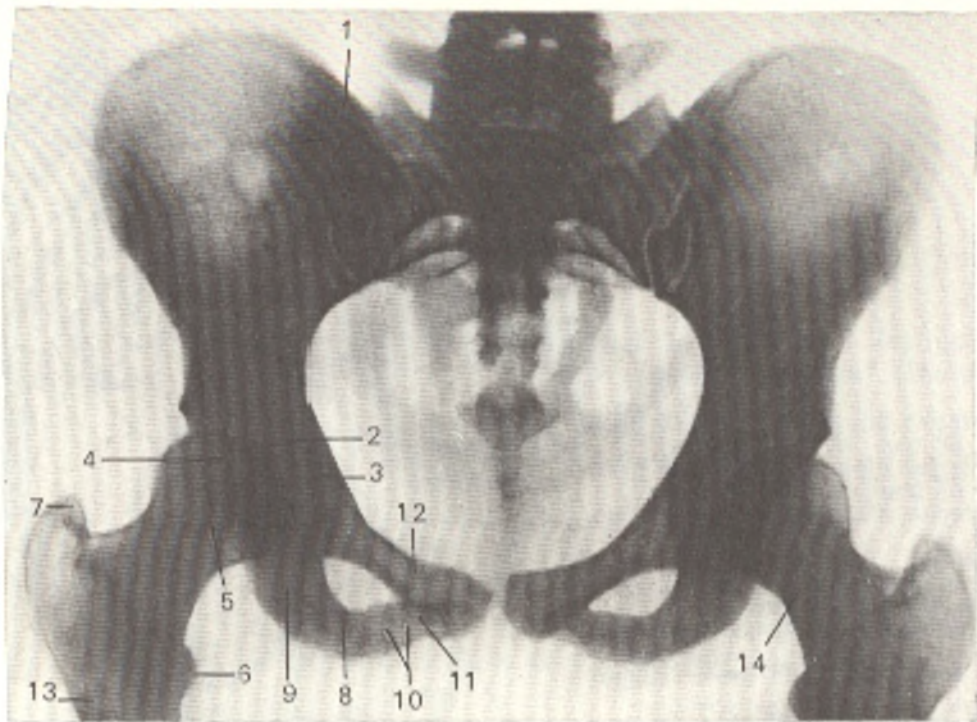


Fig. 99. Radiograph of pelvis and hip joint of female.

- |  |                              |
|--|------------------------------|
| 1, sacro-iliac joint;                    | 9, body of ischium;          |
| 2, hip joint cavity;                     | 10, ramus of ischium;        |
| 3, anterior contour of acetabulum;       | 11, inferior ramus of pubis; |
| 4, posterior contour of acetabulum;      | 12, superior ramus of pubis; |
| 5, head of femur;                        | 13, femur;                   |
| 6 and 7, lesser and greater trochanters; | 14, neck of femur            |
| 8, ischial tuberosity;                   |                              |

pelvis. In anthropoid apes, in whom the upper and the lower limbs are distinguished, the pelvis is much wider and shorter, but the anteroposterior diameter still predominates over the transverse diameter. As a result the contours of the pelvic inlet resemble the ace of hearts or, as it is generally expressed, is heart-shaped (*cordate pelvis*). Finally, in the erect human being, the pelvis is shorter and wider so that both diameters are almost equal in males, whereas in females the transverse diameter is even larger than the anteroposterior diameter because the pelvis performs a special function associated with childbearing and the act of labour. The pelvis of the Neanderthals exhibits all the human features, which indicates they walked erect; however, it is somewhat narrower than the pelvis of modern man. In reflection of this evolutionary process and of man's ontogenesis, the pelvis in the embryo is narrow, like that of quadrupeds. In the newborn it resembles the pelvis of anthropoids (*anthropoid pelvis*), and, finally, with the mastery of walking erect, it gradually acquires the shape characteristic of the human pelvis.

*Sex differences* begin to be manifested most sharply with the onset of puberty. They consist in the following. The bones of the female pelvis are generally thinner and smoother than those of the male pelvis. The iliac wings are spread out more widely in females as a result of which the distance between the spines and crests is greater. The inlet of the pelvis is transversely

oval in females and rather longitudinally oval in males. The promontory projects farther forward in a male pelvis. The male sacrum is relatively narrow and more concave; the female sacrum, in contrast, is relatively wider but at the same time flatter. The outlet of the pelvis is much narrower in males. In females the ischial tuberosities are further apart, and the protrusion of the coccyx to the front is less. The junction of the inferior pubic rami has the shape of an arc (*arcus pubis*) in a well-developed female pelvis but forms an acute angle (*angulus subpubicus*) in a male pelvis. The cavity of the true pelvis is definitely funnel-shaped in males but less funnel-shaped and more cylindrical in females. In general the male pelvis is higher and narrower, while the female pelvis is shorter, wider, and roomier.

Posteroanterior radiographs of the pelvis (Fig. 99) demonstrate all the main parts of the innominate or hip bone. The posterior part of the iliac crest and superior posterior iliac spine are superimposed on the shadow of the sacrum. Areas of diminished density are often seen in the lower part of the iliac wing; they correspond to the vascular canals and must not be mistaken for a focus of bone destruction. The "X-ray joint space" is seen between the pubic bones as a narrow band of diminished density corresponding to the interpubic disc. The outlines of the joint space are not absolutely regular. The articular surfaces of the sacro-iliac joint are mutually superimposed as a result of which the joint space on a posteroanterior radiograph has a complex shape; it usually consists of two curved bands of diminished density connected above and below (as if diamond-shaped).

#### THE SKELETON OF THE FREE LOWER LIMB AND ITS ADAPTATION TO WALKING ERECT

The skeleton of the lower limb consists of the femur, or thigh bone, two leg bones, and the bones of the foot. Besides, a small (sesamoid) bone, the patella, adjoins the thigh bone.

#### The Femur

The femur, or thigh bone, is the largest and thickest long tubular bone. Like all such bones it is a long lever of movement and has a diaphysis, metaphyses, epiphyses, and apophyses in accordance with its development. The upper (proximal) end of the femur carries a spherical articular head (*caput femoris*) (epiphysis); a little downward from the centre of the head is a small rough depression (*jovea capitis femoris*), where the ligament of the head is attached. The head is connected with the rest of the bone by a neck (*collum femoris*) (metaphysis), which meets the axis of the femoral shaft at an obtuse angle (about 130 degrees); in the wider female pelvis this angle is closer to 90 degrees. Two bony prominences called trochanters (apophyses) are found at the junction of the neck with the shaft of the femur. The greater trochanter (*trochanter major*) is the upper end of the femoral shaft. On its medial surface, facing the neck, is the trochanteric fossa (*fossa trochanterica*). The lesser trochanter (*trochanter minor*) is at the inferior margin

of the neck on the medial surface and a little to the back. Both trochanters are joined on the posterior surface of the femur by an oblique **intertrochanteric crest** (*crista intertrochanterica*) and on the anterior surface by the **intertrochanteric line** (*linea intertrochanterica*). All these structures, the trochanters, crest, line, and fossa, developed as a result of the attachment of muscles.

The *body* (shaft) of the femur is slightly convex forward and has a rounded trihedral shape; its anterior and lateral surfaces are smooth, while the posterior surface bears a mark of attachment of the thigh muscles, *linea aspera* (a rough line) which has two lips: *lateral* (*labium laterale*) and *medial* (*labium mediale*). Both lips bear marks of muscle attachment in their proximal part: *tuberositas glutea* on the lateral lip for attachment of the gluteus maximus muscle and *linea pectinea* on the medial lip for attachment of the pectineus muscle. Below the lips diverge and enclose a smooth triangular *popliteal surface* (*facies poplitea*) on the posterior surface of the femur.

The lower (distal) thickened end of the femur forms two rounded, posteriorly turned **medial** and **lateral condyles** (*condylus medialis* and *condylus lateralis*) (epiphysis); the medial condyle protrudes downward more than the lateral. Despite the difference in the size of these two condyles, however, they are located on the same level because the femur in its natural position stands obliquely with its lower end closer to the midline than the upper end. Anteriorly the articular surfaces of the condyles blend with each other to form a small concavity in the sagittal direction. This common part of the articular surfaces is called *facies patellaris* because the posterior surface of the patella abuts against it in extension at the knee joint. On the posterior and inferior surfaces, the condyles are separated by a deep **intercondylar fossa**, or **notch** (*fossa intercondylaris*). Rough prominences are found on the sides of each condyle above the articular surface. These are the *medial* and *lateral epicondyles* (*epicondylus medialis* and *epicondylus lateralis*) (apophyses).

**Ossification.** Radiographs of the proximal end of the femur at birth demonstrate only the diaphysis because the epiphysis, metaphysis, and apophyses (greater and lesser trochanters) are still in the cartilaginous developmental stage. The X-ray picture of the later changes is determined by the appearance of ossification nuclei in the femoral head (epiphysis) at the age of one, in the greater trochanter (apophysis) between the ages of three and four, and in the lesser trochanter between the ages of 9 and 14. Fusion occurs in the reverse order between the ages of 17 and 19.

### The Patella

The **patella**, or **knee-cap**, is none other than a large sesamoid bone lodged in the tendon of the quadriceps femoris muscle stretching over the anterior surface of the knee joint. A superior wide end, the **base** (*basis patellae*), and a pointed inferior end or **apex** (*apex patellae*) are distinguished. The anterior surface of the patella is rough, while the posterior surface has smooth *articular surface* (*facies articularis*) by which the patella comes into contact with the patellar surface of the femur described above.

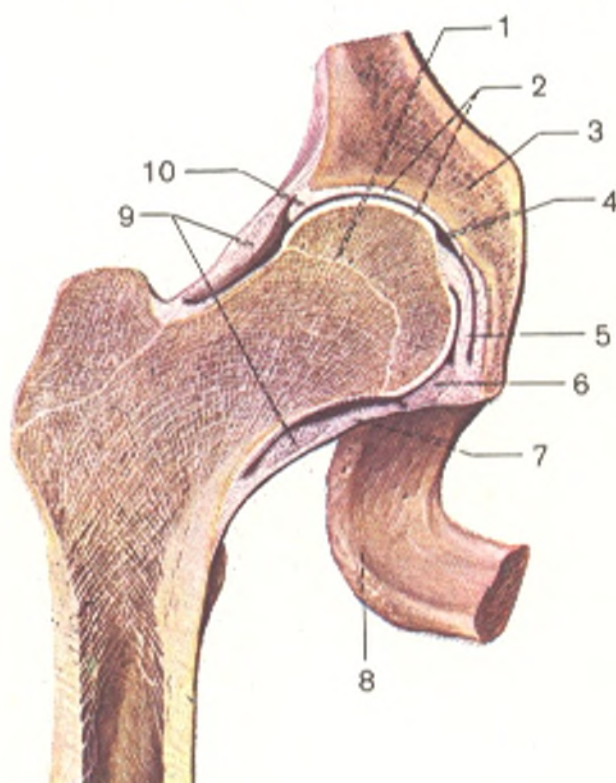
## The Hip Joint

The hip joint (*art. coxae*) is formed by the cup-like acetabulum of the hip bone, by its *facies lunata* to be more precise, and the femoral head fitting into it (Fig. 100). A fibrocartilaginous ring (*labrum acetabulare*) is attached to the whole rim of the acetabulum and makes the cavity deeper so that its depth is more than half a spheroid. The fibrocartilaginous rim bridges the acetabular notch and forms the **transverse ligament of the acetabulum** (*lig. transversum acetabuli*). The acetabulum is covered with hyaline articular cartilage only in the area of the lunate surface, while the acetabular fossa is filled with loose fatty tissue and the base of the ligament of the femoral head. The surface of the femoral head articulating with the acetabulum forms in general two-thirds of a spheroid. It is covered with hyaline cartilage with the exception of the *fovea capitis* giving attachment to the ligament of the head.

The **articular capsule** of the hip joint is attached along the whole rim of the acetabulum. In the region of the acetabular notch it fuses with the transverse ligament of the acetabulum, leaving a free opening between this ligament and the edges of the notch. Air-tightness of the joint here is provided by the synovial membrane covering the ligament of the head. The articular capsule is attached to the femur in front along the entire distance of the intertrochanteric line and behind to the femoral neck parallel to and medial of the intertrochanteric crest. As a result of such a line of attachment of the capsule on the femur, most of the neck is enclosed in

Fig. 100. Right hip joint (the cavity has been opened by frontal section; after R. D. Sinelnikov).

- 1, metaepiphyseal cartilage;
- 2, articular cartilages;
- 3, os coxae;
- 4, joint cavity;
- 5, lig. capitis femoris;
- 6, lig. transversum acetabuli;
- 7, articular capsule;
- 8, tuber ischiadicum;
- 9, zona orbicularis;
- 10, labrum acetabulare



the cavity of the joint. The hip joint has two other intra-articular ligaments, the above-mentioned transverse ligament of the acetabulum and the **ligament of the head** (*lig. capitis femoris*) whose base is attached to the edges of the acetabular notch and to the transverse ligament of the acetabulum. The apex is attached to the fovea capitis femoris. The ligament of the head is covered by a synovial sheath rising over it from the floor of the acetabulum. It is an elastic padding which absorbs the shocks experienced by the joint and transmits the vessels to the femoral head. That is why the head does not necrotize in fractures of the femoral neck if the synovial sheath remains intact, and vice versa.

The hip joint is a ball-and-socket joint of the limited type (cotyloid joint) and therefore permits **movement**, though not as freely as a free ball-and-socket joint, on three main axes: frontal, sagittal, and vertical. Circumduction is also possible.

Flexion (to the front) and extension (to the back) of the lower limb occur on the frontal axis. The freest of these two movements is forward flexion because there is no tension of the fibrous capsule, which has no attachment to the femoral neck at the back. Flexion is greatest (118-121 degrees) when the knee is bent so that the thigh can be brought against the anterior abdominal wall; when the knee is in extension, flexion of the limb is limited (84-87 degrees) by tension of the muscles on the posterior surface of the thigh; when the knee is bent these muscles are relaxed. Extension of a flexed limb is possible to a vertical position. Further movement to the back (posterior flexion) is greatly limited (to about 19 degrees) by tension of the iliofemoral ligament: if, despite this, we extend the limb still further, this is accomplished through movement at the contralateral hip joint. Movement about the sagittal axis consists in abduction of the limb (or limbs when they are drawn apart at the same time laterally) and in adduction when the limb moves to the midline. Abduction is possible to 70-75 degrees. Medial and lateral rotation of the limb on the vertical axis has a range of 90 degrees. The external ligaments of the joint are arranged in accordance with the three main pivotal axes: three longitudinal ligaments (ligamenta iliofemorale, pubofemorale and ischiofemorale), which pass perpendicular to the horizontal axes (frontal and sagittal), and one circular (*zona orbicularis*), which is perpendicular to the vertical axis.

1. The **iliofemoral (Bertin's) ligament** (*lig. iliofemorale*) is on the anterior aspect of the joint. Its apex is attached to the anterior inferior iliac spine and its widened base to the trochanteric line. It resists extension and prevents the body from falling backward when walking erect. This explains the high development of Bertin's ligament in man. It is the strongest ligament in the human body and can withstand a load of 300 kg.

2. The **pubofemoral ligament** (*lig. pubofemorale*) is on the inferomedial aspect of the joint; it stretches from the pubis to the lesser trochanter and blends with the capsule. It resists abduction and checks lateral rotation.

3. The **ischiofemoral ligament** (*lig. ischiofemorale*) begins on the posterior aspect of the joint at the acetabular rim in the region of the ischium,

passes laterally and upward over the femoral neck, blends with the capsule, and attaches to the anterior edge of the greater trochanter. It limits medial rotation of the thigh and together with the lateral part of Bertin's ligament resists adduction.

4. The **orbicular zone** (*zona orbicularis*) consists of circular fibres in the deep layers of the articular capsule under the longitudinal ligaments described above (see Fig. 100). These fibres embrace the femoral neck like a loop and attach above to the bone under the anterior inferior iliac spine. The circular arrangement of the orbicular zone corresponds to the rotational movements of the thigh.

In a living person the ligaments do not stretch maximally because movements are checked to a certain degree by the tension of the muscles around the joint. All the described movements of the lower limb at the hip joint may take place when the limb is relieved of the weight of the body, as occurs, for example, when a person is standing on the other limb. Forward and backward flexion of the limb also occurs in walking or running, when the body is supported by alternating limbs, while the limb that is freed of the weight makes a forward motion. When the lower limbs are fastened, i.e. stand fast in one spot, movement of the hip bone at the hip joint may take place only with movement of the whole upper part of the body, as it occurs, for instance, when a person bends the body in a bow and unbends it while the limbs rest on the ground. The same happens when a person rises from a supine position: the lower limbs lie on a plane, while the pelvis with the trunk rises and moves at the hip joints.

The great number of ligaments and the more pronounced curvature and congruence of the articulating surfaces of the hip joint, as compared to the shoulder joint, make movements at the hip joint less free than those at the shoulder. This is linked with the function of the lower limb, which requires greater stability in this joint. Because of this limitation and the strength of the hip joint, dislocations there are rarer than in the shoulder joint.

**Radiographs** of the hip joint (Fig. 101) made at different views produce detailed images of the pelvic bones and femur simultaneously.

The floor and roof are distinguished in the acetabulum roentgenologically. The floor is bounded medially by a funnel-shaped area of diminished density ("star figure") corresponding to the anterior part of the body of the ischium. The roof (upper border of the acetabulum) is normally round but sharpens in pathological cases. The articular, femoral, head has a spherical shape and even contours on the radiograph, with the exception of the fovea capitis femoris which produces a depression with irregular contours; the latter must not be mistaken for a focus of bone destruction. An "X-ray joint space"<sup>1</sup> is seen between the femoral head sunken into the acetabulum and the roof of the acetabulum.

<sup>1</sup> The normal relations between the articular head and the acetabulum are characterized by the sinking of the head into the acetabulum and by Nelaton's line drawn from the medial contour of the femoral head to the upper border of the obturator foramen. It is arched normally but broken in subluxation.

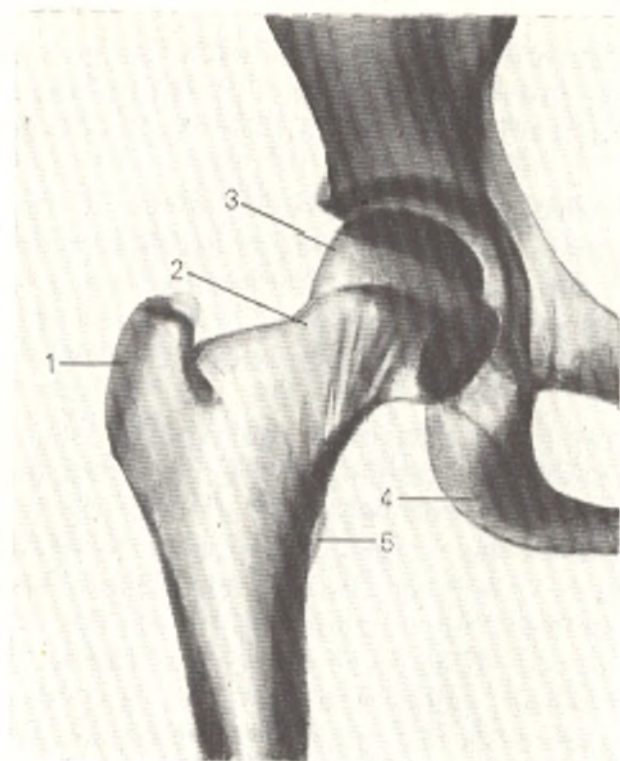


Fig. 101. Radiograph of right hip joint.

- 1, greater trochanter;  
 2, neck of femur;  
 3, head of femur;  
 4, ischial tuberosity;  
 5, lesser trochanter

In judging sex, age, and constitutional features, it is important to take into consideration the angle formed by the femoral neck and the diaphysis. In a living person this angle can be determined only by X-ray. It ranges between 130 and 135 degrees in adult males. It is larger in children and smaller in old people, and it is smaller in females than in males.

The hip joint is supplied with *arterial blood* from the rete articulare formed by branches of the medial and lateral circumflex femoral arteries (from the deep femoral artery) and the obturator artery. The latter gives origin to the acetabular branch, which passes through the ligament of the head of the femur to the femoral head. *Venous blood drains* into the deep veins of the thigh and pelvis, the deep femoral, femoral, and internal iliac veins. *Lymph drains* along the deep lymphatics into the deep inguinal lymph nodes. The articular capsule is *innervated* by the obturator, femoral, and sciatic nerves.

#### THE SKELETON OF THE LEG

The skeleton of the leg (Fig. 102) consists of two bones of unequal thickness, the **tibia** and the **fibula**. The first is on the medial and the second on the lateral side. Only the tibia articulates with the femur by means of the knee joint. The vertical, also called the *mechanical*, axis of the whole lower limb, along which the weight of the trunk is transmitted to the supporting area passes from the centre of the femoral head, through the middle of the knee joint, and to the middle of the ankle joint. It coincides distally with the longitudinal axis of the tibia which thus bears the whole weight of the body and is therefore thicker than the fibula. In some cases, the tibia deviates medially or laterally from the mechanical axis, as a result of which the lateral angle formed by the thigh and leg is more acute or more obtuse. When



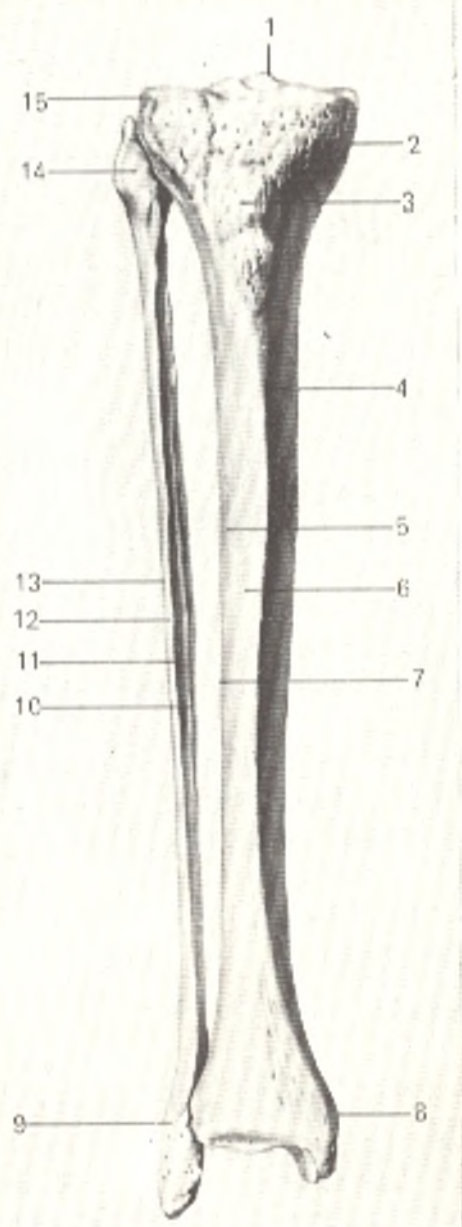


Fig. 102. Bones of the right leg, anterior aspect: tibia on the right, fibula on the left.

- 1, eminentia intercondylaris;
- 2, condylus medialis;
- 3, tuberositas tibiae;
- 4, facies medialis;
- 5, facies lateralis;
- 6, margo anterior;
- 7, margo interossea tibiae;
- 8, malleolus medialis;
- 9, malleolus lateralis;
- 10, margo interossea fibulae;
- 11, facies medialis;
- 12, margo anterior;
- 13, facies lateralis;
- 14, caput fibulae;
- 15, condylus lateralis

these deviations are very conspicuous, the lower limbs are X-shaped with the knees abnormally close together, a condition called **genu valgum**, or O-shaped with the knees abnormally separated, a condition called **genu varum**.

### The Tibia

The proximal end of the **tibia** (epiphysis) forms two **condyles**, **medial** (*condylus medialis*) and **lateral** (*condylus lateralis*). On the surface facing the femur the condyles are supplied with shallow **articular surfaces** (*facies articularis superior*) for articulation with the condyles of the femur. The articular surfaces of the tibial condyles are separated one from the other by an **intercondylar eminence** (*eminentia intercondylaris*), which has two **intercondy-**

**lar tubercles** (*tuberculum intercondylare mediale* and *tuberculum intercondylare laterale*). The eminence has two small intercondylar depressions on its ends: *area intercondylaris anterior* on the anterior end and *area intercondylaris posterior* on the posterior end (all these structures formed from attachment of the intra-articular ligaments). The articular surfaces are surrounded by a thickened rim (a mark of attachment of the articular capsule, metaphysis). A little below the rim, but on the anterior surface of the tibia, there is a rather massive, roughened convexity called **tuberosity of the tibia** (*tuberositas tibiae*) for attachment of the patellar ligament (apophysis). A small *flat articular surface* (*facies articularis fibularis*) is in the posterolateral part of the lateral condyle. It is the site of articulation with the head of the fibula. The **body** (shaft) of the tibia is trihedral. Three margins, or borders are therefore distinguished in it: the *anterior border* (*margo anterior*), the *medial border* (*margo medialis*), and *lateral border*, facing the fibula and providing attachment for the interosseous membrane; it is called for that reason the *interosseous border* (*margo interossea*). Between the three borders are the following three surfaces: *posterior* (*facies posterior*); *medial* (*facies mediales*); *lateral* (*facies lateralis*). The **medial surface** and the anterior (the sharpest) border are easily palpated under the skin. The lower, distal end of the tibia (epiphysis) has a strong process, the **medial malleolus** (*malleolus medialis*) below on its medial side. Behind the malleolus is a flat bony *groove* (*sulcus malleolaris*) made by tendons. The lower end of the tibia carries adjustments for articulation with the bones of the foot, *facies articularis inferior*, and on the lateral side of the medial malleolus, *facies articularis malleoli*. The **fibular notch** (*incisura fibularis*) for articulation with the fibula is on the lateral border of the distal end.

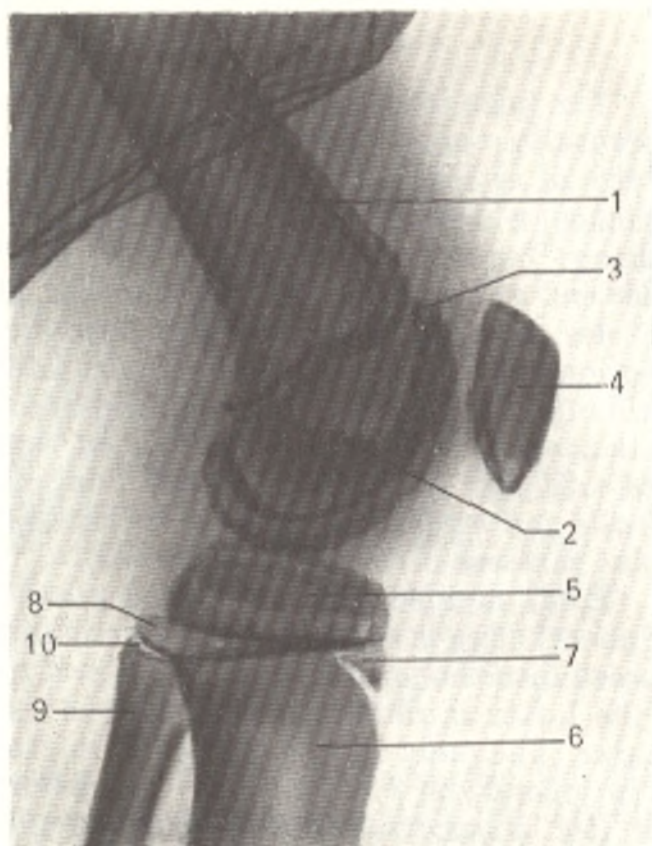
### The Fibula

The **fibula** (Gk *perone*) is a long thin bone with thickened ends. The upper (proximal) epiphysis forms the **head** (*caput fibulae*) which articulates with the lateral condyle of the tibia by means of a hollow rounded articular facet (*facies articularis capitis fibulae*). A little to the back and lateral of this surface the **apex of the head** (*apex capitis fibulae*) projects upward. The **body** of the fibula is trihedral and twisted somewhat on its longitudinal axis. The *anterior* (*margo anterior*), *interosseous* (medial) (*margo interossea*) and *posterior* (*margo posterior*) borders are distinguished. The three surfaces between the borders are slightly concave. The lower (distal) fibular epiphysis thickens to form the **lateral malleolus** (*malleolus lateralis*), which carries a smooth articular facet (*facies articularis malleoli*). On the posterior surface of the lateral malleolus is a distinct hollow *malleolar fossa* (*fossa malleoli lateralis*) lodging the tendons of the peroneal muscles.

**Ossification.** The X-ray picture of ossification in the region of the knee joint is determined by the appearance of ossification nuclei in the distal femoral epiphysis and proximal tibial epiphysis shortly before or soon after birth and in the proximal fibular epiphysis in the third to fifth year. The

Fig. 103. Lateral radiograph of knee joint of a 13-year-old boy.

- 1, femoral diaphysis;
- 2, femoral epiphysis;
- 3, metaepiphyseal cartilage;
- 4, patella;
- 5, tibial epiphysis;
- 6, tibial diaphysis;
- 7, epiphyseal "proboscis";
- 8, fibular epiphysis;
- 9, fibular diaphysis;
- 10, metaepiphyseal cartilage



presence of bone nuclei in the distal femoral epiphysis and the proximal tibial epiphysis on the radiograph at birth may serve, along with other signs, as evidence of a full-term infant.

It should be pointed out that the patella develops from several ossification points that fuse to form a single structure (3 to 5 years). If they fail to fuse, the knee-cap remains separated into two (*patella bipartita*) or three (*patella tripartita*) parts.

The tuberosity of the tibia is marked by peculiar ossification; it develops from many ossification points, which appear between the ages of 11 and 13 in girls and between the ages of 12 to 15 in boys. A bone nucleus appearing very proximally, i.e. directly at the epiphysis, fuses with it rapidly to form a "proboscis" of the epiphysis (Fig. 103). The remaining ossification nuclei (apophyseal) appear some time after and fuse with the epiphysis to form a single structure. Synostosis of this bone structure (i.e. the epiphysis and apophysis) with the metaphysis and diaphysis of the tibia occurs 6-9 years later. Synostoses between the epiphyses and metaphyses form in 20-24 years in the femur, in 19-24 years in the tibia, and in 22-24 years in the fibula. Ossification of the distal ends of the leg bones is described on p. 248.

An inconstant sesamoid bone, *fabella*, is sometimes demonstrated on the radiograph. It forms in the tendon of the lateral head of the *gastrocnemius* muscle and is easily identified.

## The Knee Joint

The knee joint (*art. genus*) is the largest and, at the same time, the most structurally complicated joint in the body. This is due to the fact that it is the site of articulation of the longest levers of the lower limb (the femur and leg bones) which are characterized by the largest range of movements made in walking. Three bones form the knee joint: the lower end of the femur, the upper end of the tibia, and the patella. The articular surfaces of the femoral condyles, uniting with the tibia, are convex in the transverse and sagittal directions and are segments of an ellipsoid (Fig. 104). The tibial facies articularis superior articulating with the femoral condyles consists of two shallow facets covered with hyaline cartilage; these facets are complemented by two intra-articular cartilages, lateral and medial semilunar cartilages (*menisci lateralis* and *medialis*) interposed between the femoral condyles and the articular surfaces of the tibia (Fig. 105).

Each meniscus is a trihedral plate bent along the edge; the thickened peripheral edge is attached to the articular capsule, while the sharpened edge directed into the joint is free. The lateral meniscus is bent more than the medial; the latter is rather crescent-shaped, while the lateral meniscus is nearly circular. The ends of both menisci are attached anteriorly and posteriorly to the intercondylar eminence. A fibrous bundle, the transverse ligament of the knee (*lig. transversum genus*) stretches in front between the menisci.

The articular capsule is attached at some distance from the edges of the femoral, tibial and patellar articular surfaces. On the femur, therefore, it

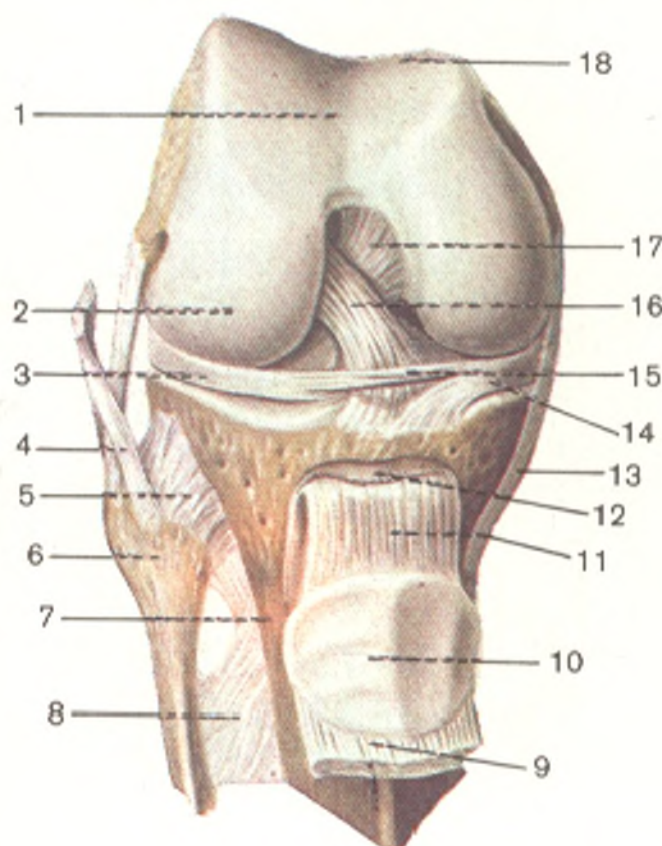


Fig. 104. Right knee joint (*articulatio genus*), anterior aspect. The articular capsule has been removed; the patella with the tendon of the quadriceps muscle is drawn downwards.

- 1, facies patellaris;
- 2, condylus lateralis;
- 3, meniscus lateralis;
- 4, lig. collaterale fibulare;
- 5, lig. capitis fibulae anterior;
- 6, fibula;
- 7, tibia;
- 8, membrana interossea cruris;
- 9, tendo m. quadriceps femoris;
- 10, facies articularis patellae;
- 11, lig. patellae;
- 12, bursa infrapatellaris profunda;
- 13, lig. collaterale tibiae;
- 14, lig. transversum genus;
- 15, meniscus medialis;
- 16, lig. cruciatum anterior;
- 17, lig. cruciatum posterior;
- 18, femur

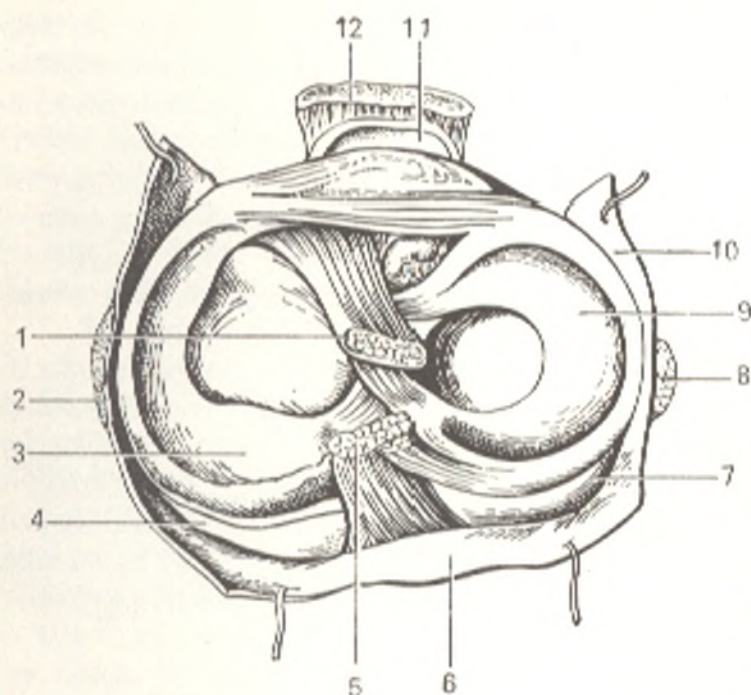


Fig. 105. Inferior surface of right knee joint.

- 1, lig. cruciatum anterius;
- 2, lig. collaterale tibiale;
- 3, meniscus medialis;
- 4, condylus medialis tibiae;
- 5, lig. cruciatum posterius;
- 6 and 10, capsula articularis;
- 7, condylus lateralis tibiae;
- 8, lig. collaterale fibulare;
- 9, meniscus lateralis;
- 11, bursa infrapatellaris profunda;
- 12, lig. patellae

stretches in front upward, by passing the *facies patellaris*. On the sides it passes between the condyles and epicondyles with the latter left outside the capsule for attachment of muscles and ligaments, and at the back it descends to the edges of the condylar articular surface. In addition, in front the synovial membrane forms a large recess, the **suprapatellar bursa** (*bursa suprapatellaris*), extending rather high between the femur and the quadriceps muscle of the thigh. Sometimes the suprapatellar bursa may not communicate with the knee joint and may be separated from it (Fig. 106). On the tibia the capsule is attached to the edges of the articular surfaces of the condyles. On the patella it is attached to the edges of the cartilaginous surface, and as a result seems to be inserted into a "frame" formed by the anterior part of the capsule. (Precise knowledge of the boundaries of attachment of the articular capsule to the bones makes it possible to determine the character of a fracture, whether extra-articular or intra-articular). The **medial** and **lateral ligaments** stretch on the sides of the joint perpendicular to their frontal axis: **ligamentum collaterale tibiale** stretches on the medial side from the medial epicondyle of the femur to the edge of the tibia and fuses with the capsule and the medial meniscus; **ligamentum collaterale fibulare** passes on the lateral side between the lateral epicondyle and the fibular head. The fibular collateral ligament has the shape of a round cord which is not attached to the articular capsule but is separated from it by a pad of fat. On the posterior aspect of the knee-joint capsule are two ligaments merging with its posterior wall, the **arcuate ligament of the knee** (*lig. popliteum arcuatum*) and the **oblique ligament of the knee** (*lig. popliteum obliquum*) (one of the three end bundles of the tendon of the semimembranous muscle).

The tendon of the quadriceps muscle of the thigh is on the anterior aspect of the knee joint. It encloses the patella as a sesamoid bone and is then continuous with a thick and strong **patellar ligament** (*lig. patellae*), which

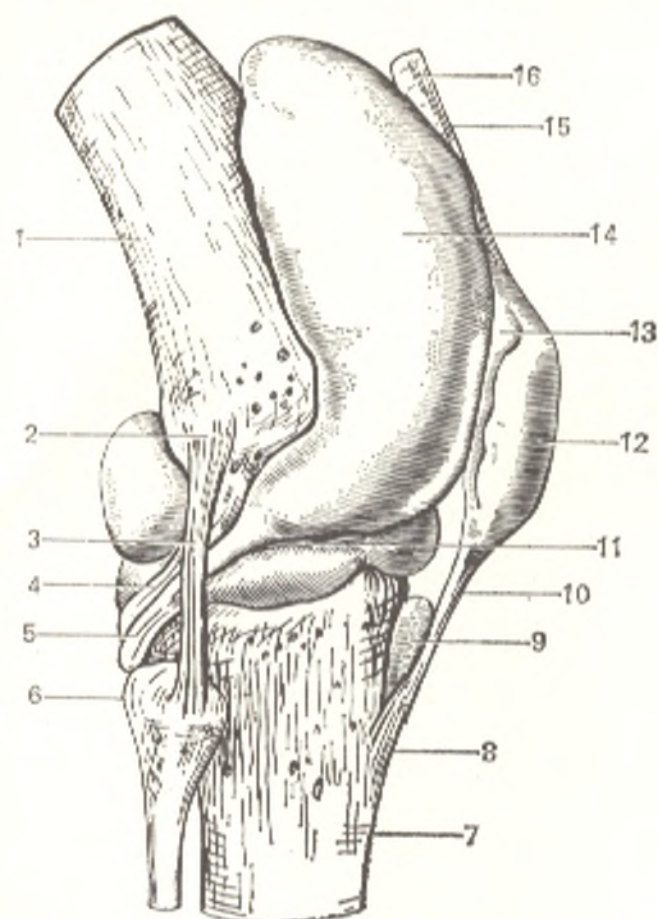


Fig. 106. Synovial capsule of right knee joint, lateral aspect.

- 1, femur;
- 2, epicondylus lateralis;
- 3, lig. collaterale fibulare;
- 4, tendo m. poplitei;
- 5, bursa m. poplitei;
- 6, caput fibulae;
- 7, tibia;
- 8, tuberositas tibiae;
- 9, bursa infrapatellaris profunda;
- 10, lig. patellae;
- 11, meniscus lateralis;
- 12, bursa prepatellaris subcutanea;
- 13, patella;
- 14, bursa suprapatellaris;
- 15 and 16, tendo m. quadricipitis femoris

passes downward from the apex of the patella and is attached to the tuberosity of the tibia. This ligament is separated from the articular capsule by a certain amount of fatty tissue, which also serves as the foundation for the *alar folds* (*plicae alares*) of the synovial membrane described below. On the sides of the patella, expansions of the tendon of the quadriceps muscle form the *lateral* and *medial patellar retinacula* (*retinacula patellae laterale* and *mediale*) made up of vertical and horizontal bundles; the vertical bundles are attached to the tibial condyles, the horizontal to both femoral epicondyles. These bundles hold the patella in place during movement.

Besides the extra-articular ligaments described above, the knee joint has two intra-articular ligaments called *cruciate ligaments* (*ligamenta cruciata genus*). One of them, the *anterior ligament* (*lig. cruciatum anterius*), connects the medial surface of the lateral condyle of the femur with the area intercondylaris anterior tibiae. The other, the *posterior ligament* (*lig. cruciatum posterius*) passes from the lateral surface of the medial femoral condyle to the area intercondylaris posterior of the tibia. The synovial membrane lining the capsule covers the cruciate ligaments projecting into the joint and forms two fat-containing *alar folds* (*plicae alares*) on the anterior wall of the joint below the patella. These folds become adjusted to the articular surfaces with each position of the knee joint by filling the spaces between them. Converging below they are continuous with the unpaired *infrapatellar synovial fold* (*plica synovialis infrapatellaris*) which is attached to the

anterior edge of the intercondylar notch on the femur. In some cases the infrapatellar fold and the cruciate ligaments divide the joint cavity, though not completely, into the right and left compartments. These ligaments also divide the cavity of the knee joint into the anterior and posterior parts and thus prevent, for a certain time, the spread of pus from one part to the other in case of inflammation. The menisci inserted between the femur and tibia divide, in turn, the joint into the superior and anterior parts (*articulationes meniscofemorales* and *meniscotibiales*).

In the vicinity of the joint are numerous other **synovial bursae**, some of which communicate with it. Up to three bursae are found on the anterior surface of the patella: these are the **subcutaneous prepatellar bursa** (*bursa subcutanea prepatellaris*); the **subfascial prepatellar bursa** (*bursa prepatellaris subfascialis*), located deeper under the fascia and, finally, the **subtendineous prepatellar bursa** (*bursa subtendinea prepatellaris*), under the aponeurotic expansion of the quadriceps muscle. The **deep infrapatellar bursa** (*bursa infrapatellaris profunda*) which does not communicate with the joint is always found at the lower attachment of the patellar ligament between this ligament and the tibia. In the posterior region of the joint, bursae are encountered under the sites of attachment of almost all muscles.

Two types of **movement** occur at the knee joint: flexion and extension and then rotation. The knee is a typical condylar joint. Flexion and extension take place on the frontal axis passing through the femoral condyles. The range of flexion is considerable and is possible to an angle of 40 degrees. Extension occurs until the thigh and leg are on one line (180 degrees), after which it is arrested because the condyles of the femur abut against the tibia. As a result the menisci are compressed, the collateral and cruciate ligaments strongly tightened, and the leg and the thigh locked in a single structure. In flexion the menisci straighten out, while the collateral ligaments relax because the points of their attachment come closer to each other; as a consequence, rotation on the longitudinal axis becomes possible when the knee is flexed. The cruciate ligaments restrict medial rotation of the leg, but, on the contrary, relax in lateral rotation, in which instance movement is limited by the lateral ligaments. In rotation, the greatest range of movements takes place in the region of the lateral condyle because the collateral fibular ligament, which does not merge with the articular capsule, relaxes more than the collateral tibial ligament. During rotation the menisci glide on the articular surface of the tibia. In addition to the indicated role of the cruciate ligaments in rotational movements, they also effect flexion and extension by holding the bones in a definite position and at the same time limiting movement. The structure and arrangement of the ligaments of the knee joint in man facilitate the maintenance of an upright position for a long period of time. (The ligaments of the knee joint of monkeys, in contrast, make it difficult to hold a vertical posture but facilitate squatting.)

**Radiographs** of the knee joint (Fig. 107) produce an image of the distal part of the femur, proximal segments of the leg bones, the patella, and the tibiofibular joint. The "X-ray joint space" of the knee is the widest of all the joint spaces in the human osteo-articular apparatus because it corresponds to

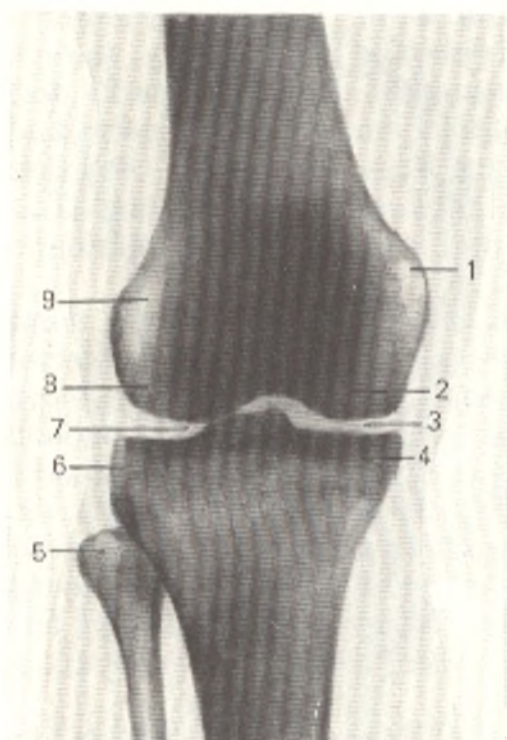


Fig. 107. Radiograph of knee joint.

- 1, medial epicondyle of femur;
- 2, medial condyle of femur;
- 3, X-ray joint space of knee;
- 4, medial condyle of tibia;
- 5, head of fibula;
- 6, lateral condyle of tibia;
- 7, intercondylar eminence;
- 8, lateral condyle of femur;
- 9, lateral epicondyle of femur

the natural anatomical joint cavity and articular cartilages and in addition to the cartilaginous menisci. All the anatomical details of the distal femur and proximal parts of the leg bones are identifiable on the radiograph. On lateral radiographs, the picture of the knee joint is reproduced in profile, as a result of which the images of the epicondyles and the condyles of the femur and leg bones are superimposed on each other.

The knee joint is supplied with *nutrients* from the rete articulare formed by the medial and lateral superior genicular arteries, the medial and lateral inferior genicular arteries, the middle genicular artery (from the popliteal artery), the descending genicular artery (from the femoral artery), and the anterior and posterior tibial recurrent arteries (from the anterior tibial artery). The *venous blood drains* along the veins of the same name as the arteries into the deep veins of the lower limb, namely, the anterior tibial, popliteal, and femoral veins. The *lymph drains* along the deep lymphatics into the popliteal lymph nodes. The articular capsule is *innervated* by branches of the tibial and common peroneal nerves (Gk *perone* the fibula).

### Joints between the Leg Bones

Both leg bones are connected proximally by a joint and distally by a joint or connective-tissue articulation (syndesmosis). On the remaining distance the bones are also joined by a syndesmosis (interosseous membrane).

The **proximal union** of the tibia and fibula, the **superior tibiofibular joint** (*art. tibiofibularis*) is formed by the flat articular facet on the head of the fibula and a similar facet on the surface of the lateral tibial condyle (*art. plana*). The tightly stretched articular capsule attached to the edges of both articular facets is strengthened by dense **anterior** and **posterior ligaments of the superior tibiofibular joint** (*ligamenta capitis fibulae anterioris* and *pos-*



terius). The joint cavity communicates with the knee joint in almost 20 per cent of all cases.

The **interosseous membrane** of the leg (*membrana interossea cruris*) is stretched between the interosseous borders of both bones. It closes almost the entire space between the bones but has an opening in the upper part through which the vessels and the nerve pass. Small openings are also found in its lower part.

The **distal union** of the ends of the tibia and fibula is formed by syndesmosis or by a joint, **syndesmosis (articulatio) tibiofibularis**. This articulation is strengthened by **anterior** and **posterior tibiofibular ligaments** (*ligamenta tibiofibularis anterior* and *posterior*) passing from the lateral malleolus to the distal end of the tibia.

One difference between the joints of the forearm bones and those between the leg bones is striking. The mobility of the leg bones is extremely limited because the lower limb is concerned with the function of weight-bearing and is a strong support for the body. This may be contrasted to the variety of movements made by the bones of the forearm as an organ of labour.

#### THE BONES OF THE FOOT

The tarsus, metatarsus, and the bones of the toes are distinguished in the foot.

##### The Tarsus

The tarsus (Fig. 108) is made up of seven short **spongy bones** (*ossa tarsi*), which are arranged in two rows similar to the carpal bones. The posterior, or **proximal**, row is formed of two comparatively large bones, the talus and the calcaneus lying below it. The anterior, or **distal**, row consists of a medial and lateral part. The medial part is formed by the navicular and three cuneiform bones, the lateral part by a single cuboid bone. Because of the erect position of the human body, the foot bears the weight of the whole body. As a consequence the tarsal bones of the human foot have a peculiar structure, different from that of these bones in animals.

The calcaneus, for instance, located at one of the principal points of support of the foot, has acquired in man its large size and strength, as well as an elongated shape in the anteroposterior direction. Its posterior end is thickened to form the tuberosity of the calcaneus, *tuber calcanei*.

The talus has acquired accommodations for articulation with the leg bones (proximally) and the navicular bone (distally) and is therefore large, has a peculiar shape and carries articular surfaces. The remaining tarsal bones, which also carry a heavy load, have become comparatively massive and adapted to the arched shape of the foot.

1. The **talus (ankle bone)** consists of a **body** (*corpus tali*), which extends anteriorly as a constricted **neck** (*collum tali*). The neck is continuous with an oval convex **head** (*caput tali*), carrying a surface for articulation with the **navicular bone** (*facies articularis navicularis*). The body of the talus has a **trochlea tali** on its superior surface for articulation with the leg bones. The

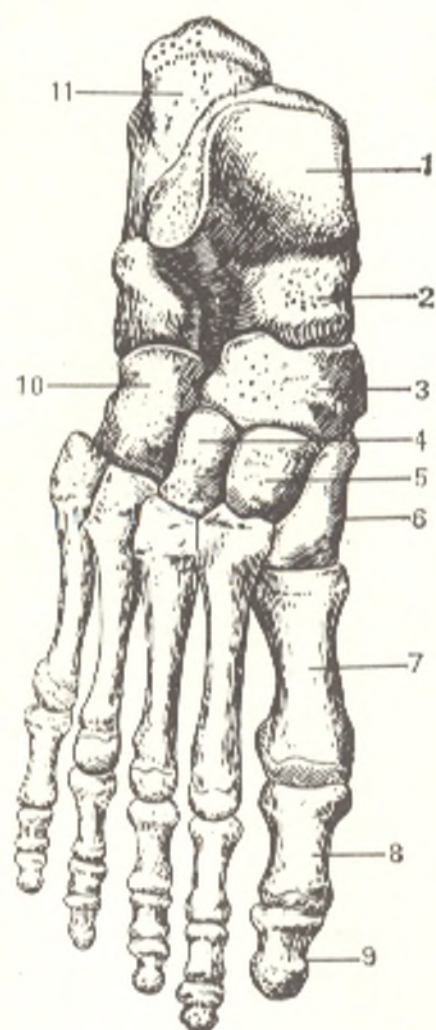


Fig. 108. Bones of right foot (ossa pedis), seen from above.

- 1, talus;
- 2, collum tali;
- 3, os naviculare;
- 4, 5, and 6, ossa cuneiformia laterale, intermedium, and mediale;
- 7, os metatarsale I;
- 8, phalanx proximalis;
- 9, phalanx distalis;
- 10, os cuboideum;
- 11, calcaneus

superior articular surface of the trochlea (*facies superior*), the site of articulation with the distal articular surface of the tibia, is convex from front to back and slightly concave in the frontal direction. The trochlea has two articular surfaces on its sides, the *medial* and *lateral malleolar facets* (*facies malleolares medialis* and *lateralis*) for articulation with the malleoli. The *facet of the lateral malleolus* (*facies malleolaris lateralis*) curves downward onto a projecting *lateral tubercle of the talus* (*processus lateralis tali*). Behind the trochlea, the body of the talus gives rise to a *posterior tubercle of the tali* (*processus lateralis tali*), which is separated by a groove lodging the tendon of the *m. flexor hallucis longus*. On the inferior surface of the talus are two (anterior and posterior) articular facets for union with the calcaneus. A deep rough *groove* (*sulcus tali*) passes between them.

2. The **calcaneus** (**heel bone**) has two articular surfaces (anterior and posterior) on its superior surface, which correspond to the inferior articular facets on the talus. The calcaneus gives off a medial process called the *sustentaculum* (L support) *tali*, so called because it supports the head of the talus. The articular facets on the anterior part of the calcaneus are separated from the posterior articular surface of this bone by a *groove* (*sulcus calcanei*), which adjoins a similar sulcus on the talus and forms together with it the

bone canal (*sinus tarsi*) opening on the lateral surface of the dorsal surface of the foot. A groove for the tendon of the long peroneal muscle passes on the lateral surface of the calcaneus. On the distal (anterior) surface of the calcaneus, facing the second row of the tarsal bones, is a saddle-shaped *cuboid articular surface* (*facies articularis cuboidea*) for articulation with the cuboid bone. Posteriorly the body terminates as a rough *posterior surface of the calcaneum* (*tuber calcanei*), from which two processes, *lateral* and *medial* (*processus lateralis* and *processus medialis tuberis calcanei*) project toward the sole.

3. The **navicular bone** (*os naviculare*) is situated between the head of the talus and the three cuneiform bones. On its proximal surface it has an oval concave articular surface, which receives the head of the talus. Its distal surface is slightly convex and is separated by two crests into two smooth facets for articulation with the three cuneiform bones. A rough *tuberosity of the navicular bone* (*tuberositas ossis navicularis*) projects from the medial surface downwards and can be easily felt through the skin. A small articular area for the cuboid bone is often found on the lateral surface.

4, 5, and 6. The **three cuneiform bones** (*ossa cuneiformia*) are so called because they are wedge-shaped. They are designated **os cuneiforme mediale**, **intermedium** and **laterale**, or the first, second, and third cuneiform bones (BNA), numbered from the medial border of the foot. The medial bone is the largest. The intermediate bone is the smallest, while the lateral cuneiform bone is of average size. They carry articular facets on the corresponding surfaces for articulation with the neighbouring bones.

7. The **cuboid bone** (*os cuboideum*) is placed on the lateral border of the foot between the calcaneus and the bases of the fourth and fifth metatarsal bones. In accordance with this, articular surfaces are found on the corresponding sites. On the plantar surface of the bone is a projecting transverse ridge (*tuberositas ossis cuboidei*) in front of which is a *sulcus of the tendon of the peroneus longus muscle* (*sulcus tendinis m. peronei longi*).

### The Metatarsus

The **metatarsus** (Fig. 108) consists of five metatarsal bones (*ossa metatarsalia*) related to the short (monoepiphyseal) tubular bones and resembling the carpals of the hand. Just as in the hand, a proximal end, or **base** (*basis*), a middle part, or **body** (*corpus*), and a distal end, or **head** (*caput*), are distinguished in each metatarsal. They are arranged one next to the other and are separated by **interosseous spaces** (*spatia interossea metatarsi*). They are numbered from the medial border of the foot. The metatarsals articulate by their bases with the distal row of the tarsal bones so that the first, second, and third metatarsals each unite with the corresponding cuneiform bone, while the fourth and fifth metatarsals articulate with the cuboid bone. The base of the second metatarsal protrudes considerably to the back because the intermediate cuneiform articulating with it is short. In addition to the articular surfaces on the proximal ends (for articulation with the tarsals), the bases of the metatarsals have narrow facets on their sides for articulating

with one another: the second metatarsal bone carries on its sides articular surfaces for receiving the neighbouring medial and lateral cuneiform bones; the third and fourth metatarsals have articular facets on both sides, while the fifth metatarsal has one only on the medial side of the base (for the fourth tarsal bone). The base of the fifth metatarsal has a projection (*tuberositas ossis metatarsalis V*) on its lateral side. The base of the first metatarsal also has a protuberance (*tuberositas ossis metatarsalis I*) projecting toward the sole. The heads are flattened on the sides and, like the heads of the metacarpals, have facets on their sides for attachment of the ligaments. The first metatarsal is the shortest and thickest, the second metatarsal the longest.

### The Bones of the Toes

The bones of the toes, the **phalanges** (*phalanges digitorum pedis*) are short tubular monoepiphyseal bones distinguished from the finger phalanges by their small size (Fig. 108). The toes, like the fingers, consist of three phalanges, with the exception of the great toe, which has two phalanges differing from the phalanges of the other toes in their relatively large size. The unguis phalanges have a raised bony mass on their distal end (*tuberositas phalangis distalis*), which is their main distinguishing feature.

**Sesamoid bones** are found in the metatarsophalangeal joints (always in that of the big toe) and in the interphalangeal joint of the big toe.

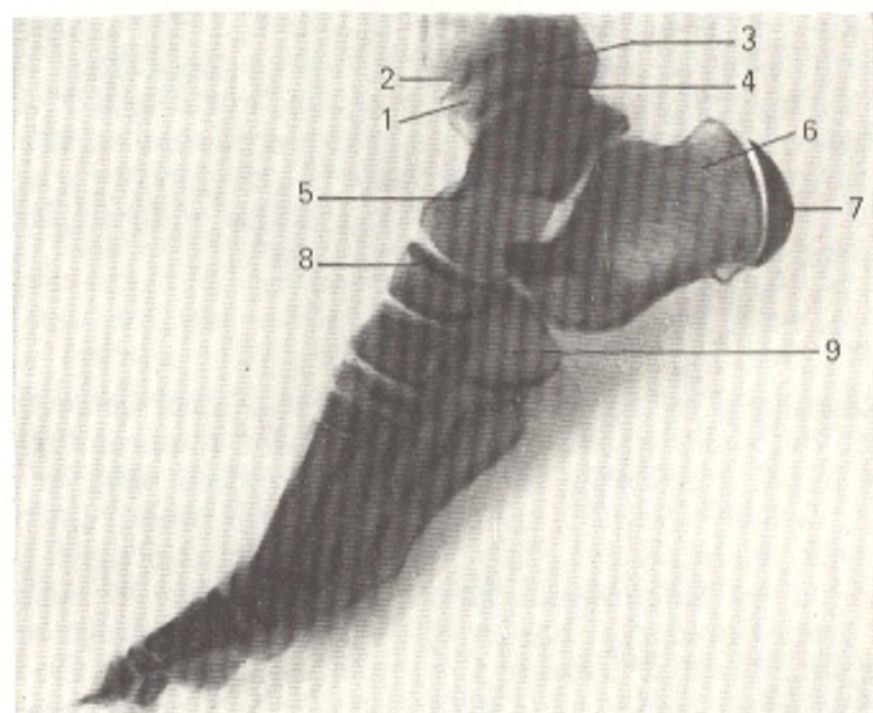


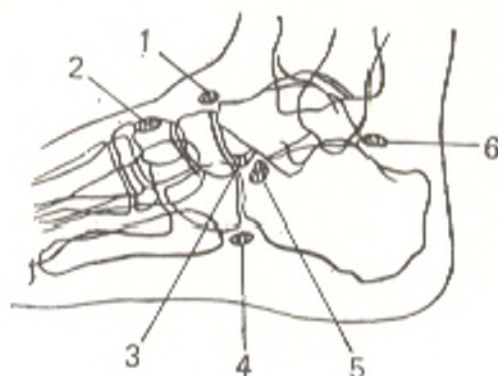
Fig. 109. Lateral radiograph of foot of a 10-year-old girl.

1, epiphysis of tibia;  
2, metaepiphyseal cartilage of tibia;  
3, epiphysis of fibula;  
4, metaepiphyseal cartilage of fibula;  
5, talus;

6, calcaneus;  
7, apophysis which has failed to fuse  
with calcaneus;  
8, navicular bone;  
9, cuboid bone

Fig. 110. Schematical representation of true supernumerary (inconstant) bones of foot (after Rokhlin, Maikova-Stroganova, and Finkelshtein).

- 1, os supranaviculare;
- 2, os intercuneiforme;
- 3, os calcaneum secundarium;
- 4, os sesamoideum peroneum;
- 5, os tibiale externum;
- 6, os trigonum



**Ossification.** The X-ray picture of the age changes in the skeleton of the foot and in the region of the ankle joint correspond to the successive appearance of ossification nuclei in the calcaneus in the sixth month of intrauterine life, in the talus in the seventh or eighth month, in the cuboid bone in the ninth month, in the lateral cuneiform bone in the first year after birth, in the distal tibial epiphysis at the age of two years (synostosis between the ages of 16 to 19), in the distal fibular epiphysis between the ages of two and three (synostosis between the ages of 20 and 25), in the medial cuneiform bone (ages two to four), in the intermedium cuneiform bone in the third or fourth year, and in the navicular bone in the fourth or fifth year. A few specific features of the ossification of the foot skeleton should be pointed out (Fig. 109): the calcaneus has an apophysis, tuberosity of the calcaneus, developing from several ossification points which appear between the ages of seven and nine and fuse with the body of the bone between the ages of 12 and 15; separate bone nuclei are encountered in the posterior process of the talus, in the apophysis and the tuberosity of the navicular bone, in the apophysis and the tuberosity of the fifth metatarsal. While they exist, these bone nuclei may be mistaken for bone fragments. In this respect, the presence of sesamoid bones in the big toe must also be borne in mind; they appear between the ages of 8 and 12 in girls and between the ages of 11 and 13 in boys. Often only two phalanges are found in the little toe as the result of reduction.

The possible existence of *accessory*, supernumerary, or, rather, inconstant bones of the foot must be borne in mind. True supernumerary bones are those which reflect the specific features of phylogenetic and ontogenetic development. There are nine such bones in the foot. They are located between the medial and intermediate cuneiform bones (os intercuneiforme), between the first and second metatarsals (os intermetatarsium), above the navicular bone (os supranaviculare), above the talus (os supratalus), and where the peroneus muscle curves over the cuboid bone (os sesamoideum peroneum). The remaining three bones are unfused ossification nuclei in the tuberosity of the navicular bone (os tibiale externum), the posterior process of the talus (os trigonum), and the medial malleolus (os subtibiale).

Knowledge of these bones helps to differentiate between a normal and pathological condition (Fig. 110).

### Joints of the Bones of the Foot

According to the union of the foot with the leg bones and the union of its parts, all joints of the foot (Fig. 111) may be separated into four groups: (1) joint of the foot with the leg bones (articulatio talocruralis); (2) joints

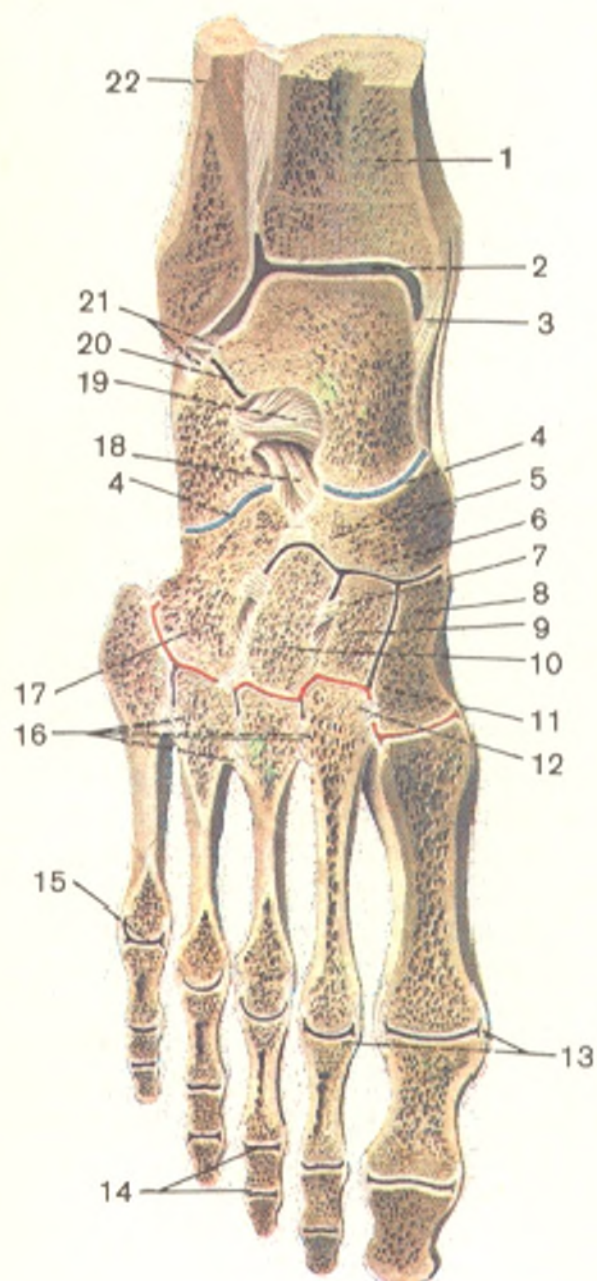


Fig. 111. Joints and ligaments of right foot (section made through ankle joint and joints of foot; after R. D. Sinelnikov).

- 1, tibia;
- 2, art. talocruralis;
- 3, lig. mediale (deltoideum);
- 4, art. tarsi transversa;
- 5, os naviculare;
- 6, art. cuneonavicularis;
- 7, lig. intercuneiforme interosseum;
- 8, os cuneiforme mediale;
- 9, os cuneiforme intermedium;
- 10, os cuneiforme laterale;
- 11, articulationes tarsometatarsae;
- 12, lig. cuneometatarsium interosseum;
- 13, ligamenta collateralia;
- 14, articulationes interphalangeae pedis;
- 15, art. metatarsophalangea;
- 16, ligamenta metatarsae interossea;
- 17, os cuboideum;
- 18, lig. bifurcatum;
- 19, lig. talocalcaneum interosseum;
- 20, art. subtalaris;
- 21, lig. talofibulare posterius;
- 22, fibula

between the bones of the tarsus (articulationes intertarsae); (3) joints between the tarsus and metatarsus (articulationes tarsometatarsae) and between the bones of the tarsus (articulationes intermetatarsae); and (4) joints of the toe bones (articulationes metatarsophalangeae and interphalangeae pedis).

1. The talocrural or ankle joint (*art. talocruralis*) is formed by the articular surfaces of the distal ends of both leg bones, which fit over the trochlea of the talus like a fork; the lower articular surface of the tibia articulates with the facies articularis superior of the trochlea, while the articular surface of the malleoli articulate with the articular surfaces on the sides of the talus. The articular capsule is attached to the cartilaginous margin of the arti-

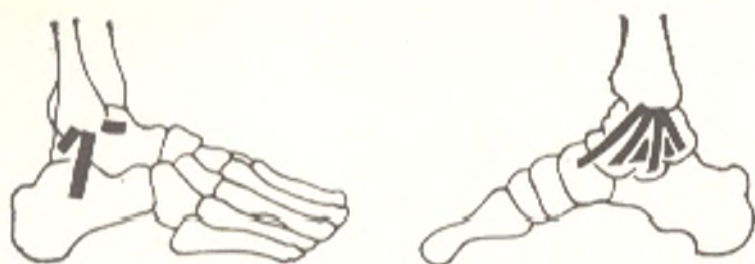

Fig. 112. Ligaments of ankle joint represented schematically.  
Left, fibular aspect; right, tibial aspect

cular surfaces and covers part of the neck of the talus in front. Accessory ligaments run on the sides of the joint from the malleoli to the adjacent tarsal bones (Fig. 112). The **medial (deltoid) ligament** (*lig. mediale* [deltoideum]) has the appearance of a plate resembling the Greek letter delta in shape; the **lateral ligament** is formed by three bundles passing from the lateral malleolus into three different directions: forward, the **anterior talofibular ligament** (*lig. talofibulare anterius*), downward, the **calcaneofibular ligament** (*lig. calcaneofibulare*), and backward, the **posterior talofibular ligament** (*lig. talofibulare posterius*). In the character of its structure, the ankle joint is a hinge joint. **Movement** takes place on the frontal axis passing through the trochlea of the talus, during which the foot is now raised with the toes upward (dorsiflexion), now lowered (plantar flexion). The movements occur in a range of 63-66 degrees. Slight side movements can also be made in plantar flexion because in this position the narrower posterior part of the trochlea of the talus is not grasped as tightly by the fork formed by the leg bones. In dorsiflexion, in contrast, these movements are absolutely impossible because the trochlea is held securely by the fork formed by the malleoli. Tension of the Achilles tendon on the posterior surface of the joint and frequent abutment of the tibia against the neck of the talus also contribute to limitation of dorsiflexion. The posterior border of the tibia may also push against the posterior process of the talus in the last moment of plantar flexion.

The ankle joint receives *nutrients* from the medial and lateral malleolar retia formed by the malleolar branches of the anterior and posterior tibial and the peroneal arteries. *Venous blood drains* into the deep veins of the leg, the anterior and posterior tibial and peroneal veins. *Lymph drains* along the deep lymphatics into the popliteal lymph nodes. The articular capsule is *innervated* by branches from the tibial and deep peroneal nerves.

2. The following four joints are distinguished in the articulations between the tarsal bones, the **intertarsal joints** (*art. intertarseae*): (a) the **subtalar (talocalcanean) joint** (*art. subtalaris*); (b) the **talocalcaneonavicular joint** (*art. talocalcaneonavicularis*); (c) the **calcaneocuboid joint** (*art. calcaneocuboida*); and (d) the **cuneonavicular joint** (*art. cuneonavicularis*).

A. The **subtalar joint** (*art. subtalaris*) is formed by the posterior articular facets of the talus and calcaneus which represent segments of a cylindrical surface. They are surrounded by an articular capsule strengthened on the sides by accessory ligaments. The cavity does not communicate with any other joint.

B. The **talocalcaneonavicular joint** (*art. talocalcaneonavicularis*) is to the front of the subtalar joint and is formed by an almost spherical talus and a corresponding articular socket formed by the navicular bone, the articular facet on the sustentaculum tali of the calcaneus, and the **plantar calcaneonavicular ligament** (*lig. calcaneonaviculare plantare*) filling the space between the sustentaculum and the posterior margin of the navicular bone and containing in its thickness a layer of fibrous cartilage, fibrocartilago navicularis. The articular capsule is attached directly to the edge of the articular surfaces and is strengthened on the dorsal surface by the **talonavicular ligament** (*lig. talonaviculare*). The plantar calcaneonavicular ligament mentioned above serves as an accessory ligament on the plantar aspect.

Between the two joints mentioned, there is a bony canal, sinus tarsi, which lodges a strong **interosseous talocalcaneal ligament** (*lig. talocalcaneum interosseum*) stretching between the talus and the calcaneus. Besides the ligament, the sinus also contains some loose fat in which an inconstant synovial bursa sinus tarsi may be found.

C. The **calcaneocuboid joint** (*art. calcaneocuboidea*) is formed by the articular facets on the opposed surfaces of the calcaneus and the cuboid bone. It has a tightly stretched capsule strengthened by ligaments binding the articulating bones on the dorsal and plantar aspects. The cavity does not communicate with any other joint. The calcaneocuboid joint takes part in movements occurring at the subtalar and talocalcaneonavicular joints by increasing their range. The calcaneocuboid joint together with the talonavicular joint are often described under the common name **transverse tarsal joint** (*art. tarsi transversa*) or **Chopart's joint**. An examination of a section of the common line of Chopart's joint shows it to resemble a Latin letter S placed transversely, with the medial curvature of the letter (corresponding to the convexity of the head of the talus) more conspicuous than the lateral curvature (corresponding to the less marked concavity of the calcaneus). In addition to ligaments strengthening the calcaneocuboid and talonavicular joints separately, Chopart's joint has a ligament common to both these joints which is of great practical importance. This is the **bifurcate ligament** (*lig. bifurcatum*), which arises posteriorly on the superior border of the calcaneus and then separates into two parts one of which, the **calcaneonavicular ligament** (*lig. calcaneonaviculare*), is attached to the posterolateral border of the navicular bone, while the other, the **calcaneocuboid ligament** (*lig. calcaneocuboideum*), is attached to the dorsal surface of the cuboid bone. This short but strong ligament is the "key" to Chopart's joint since only when this ligament has been cut can the articular surfaces be drawn widely apart in an operation for the exarticulation of the foot at this joint.

D. The **cuneonavicular joint** (*art. cuneonavicularis*) is formed by articulation of the posterior articular surfaces of the cuneiform bones with the three facets on the distal articular surface of the navicular bone. All these articular surfaces are enclosed in a single common capsule, and the joint cavity extends between the opposed surfaces of the cuneiform bones. Between the medial and intermediate cuneiform bones, the cavity often communicates with the second and third tarsometatarsal joints.



The cuneonavicular joint is strengthened on the dorsal and plantar surfaces by ligaments which stretch between the bones forming this joint and are designated accordingly.

Movements at the intertarsal joints consist firstly in rotation of the calcaneus together with the navicular bone and the anterior (distal) end of the foot on the sagittal axis within a range of 55 degrees (this axis passes obliquely, entering the head of the talus on the dorsal surface and leaving through the side of the calcaneus on the plantar surface). In medial rotation of the foot (pronation), its lateral border is raised, while the dorsal surface faces medially; in contrast, in lateral rotation (supination) the medial border is raised, and the dorsal surface of the foot faces laterally. In addition, abduction and adduction on the vertical axis can take place, with the tip of the foot displaced medially or laterally from the midline. Finally, dorsal and plantar flexion can occur on the frontal axis. Movement on all the axes also takes place at the talocalcaneonavicular joint, which is a complex spheroid joint. The extent of movement is slight, and the movements are usually combined so that during supination, the anterior part of the foot is also adducted and slight plantar flexion occurs, or, on the contrary, pronation is attended by abduction and dorsiflexion.

On the whole, the ankle joint, together with the intertarsal joints, permits freedom of movement of the foot as a multi-axial joint.

3. The tarsometatarsal joints (*articulationes tarsometatarsee*), known in the aggregate as Lisfranc's joint, unite the second row of the tarsal bones with the metatarsals. They are formed by the articular surfaces on the distal aspect of the three cuneiform bones and the cuboid bone, with which the corresponding articular surfaces of the bases of the five metatarsal bones articulate. The tarsometatarsal joints are typical tight joints, the slight movement at which lends elasticity to the arch of the foot. Articulations of the first metatarsal with the medial cuneiform bone, articulations of the second and third metatarsals with the corresponding cuneiform bones, and articulation of the fourth and fifth metatarsals with the cuboid have their own articular capsules. In general, the line of the articulations composing Lisfranc's joint forms an arch with a quadrangular projection to the back corresponding to the base of the second metatarsal bone. The tarsometatarsal joints are strengthened by dorsal, plantar, and interosseous ligaments (*ligamenta tarsometatarsee dorsalia, plantaria* and *cuneometatarsee interossea*).

The intermetatarsal joints (*articulationes intermetatarsee*) are formed by the opposed surfaces of the metatarsal bones; their joint cavities often communicate with the cavity of the tarsometatarsal joints. The joints are strengthened by transverse *ligamenta metatarsee dorsalia, plantaria* and *interossea*.

4. Joints of the toe bones. A. Metatarsophalangeal joints (*articulationes metatarsophalangeae*) between the heads of the metatarsals and the basis of the proximal phalanges resemble the analogous joints of the hand in their structure and in the ligamentous apparatus. Movements at the joints are in general the same as those at the corresponding joints of the hand, but they are limited. Except for the slight adduction and abduction of the toes, only dorsal and plantar flexion of all the toes together occurs. The range of dorsi-

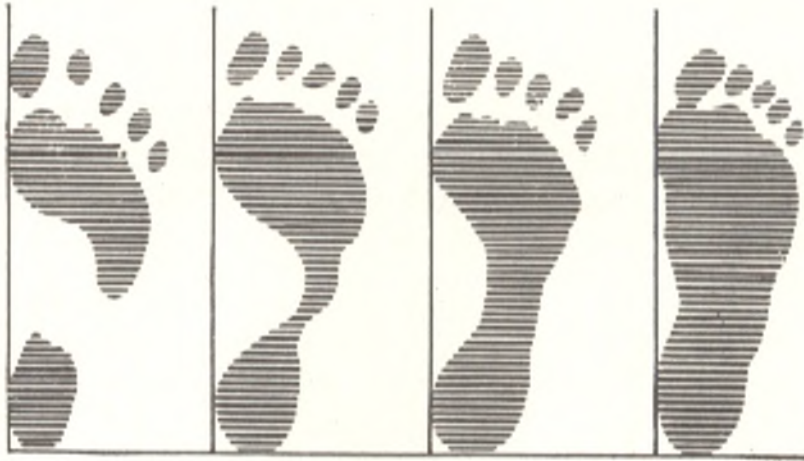

Fig. 113. Footprints (extreme right—in flatfoot)

flexion in the foot is larger than the range of plantar flexion. This is the opposite of the situation in the hand.

B. The **interphalangeal joints** (*articulationes interphalangeae pedis*) do not differ in structure from the similar joints on the hands. It should be pointed out that synostosis of the distal and middle phalanges of the little toe is often encountered.

The joints of the foot are *vascularized* by branches of the *arcus plantaris* and *rete plantaris profundus a. dorsalis pedis*. The *venous blood drains* into the deep veins of the lower limb, *vv. tibiales anterior and posterior* and *v. peronea*. *Lymph drains* along the deep lymphatics into the popliteal lymph nodes. *Innervation* of the articular capsules is supplied by branches of the medial and lateral plantar nerves and the musculocutaneous and anterior tibial nerves.

**Radiographs** of the ankle joint and foot produce images of the distal segments of the leg bones and all the bones of the foot. On a posteroanterior radiograph the region of the fibular notch on the tibia is demonstrated as a projection and is, therefore, called, the **third malleolus** (*malleolus tertius*). The distal segment of the fibula is superimposed on this region, as a result of which an impression of a fragment is produced.

**The foot as a whole.** The foot is constructed and functions as a resilient mobile arch. The foot of all animals, including anthropoids, is devoid of the arched structure that characterizes man as a result of his erect position (Fig. 113). This structure developed as the result of the new functional requirements made of the human foot: the increased load experienced by the foot in the upright position of the body and the reduced surface of support in combination with the economy of building material and the strength of the whole construction.

The complex of the foot bones connected by tight joints, which permit almost no movement, forms the *hard foundation of the foot* consisting of ten bones: the navicular bone, the medial, intermediate, and lateral cuneiform bones, the cuboid bone, and the first, second, third, fourth, and fifth metatarsal bones.

Among the ligaments, the long plantar ligament (*lig. plantare longum*) plays the decisive role in strengthening the arch of the foot. It arises from the inferior surface of the calcaneus, stretches forward, and attaches by its deep fibres to the tuberosity of the cuboid bone and by superficial fibres to the base of the metacarpals.

Bridging the sulcus in the cuboid bone, the long peroneal ligament converts it to an osteofibrous canal through which the tendon of the long peroneal muscle passes.

Five *longitudinal arches* and one *transverse arch* are distinguished in the whole arched structure of the foot. The longitudinal arches begin from one point on the calcaneus and diverge anteriorly along the upwardly convex rays corresponding to the five rays of the foot. Each longitudinal arch is therefore made up of one metatarsal bone (the first in the first arch, the second in the second arch, etc.) and parts of the carpal bones located between it and the tuberosity of the calcaneus. The sustentaculum tali plays an important role in the formation of the first (medial) arch. The second arch is the longest and highest of all the longitudinal arches. The longitudinal arches, joined in the anterior part in the form of a parabola, form the *transverse arch* of the foot. The bony arches are maintained by the shape of the bones forming them and by the muscles and fasciae. The muscles are active "tightening devices" holding the arches. The transverse arch is held, in particular, by the transverse ligaments of the sole, the obliquely stretched tendons of the long peroneal and posterior tibial muscles, and the transverse head of the adductor muscle of the great toe.

The longitudinally arranged muscles shorten the foot, while the oblique and transverse muscles make it narrower. Such a two-way effect exerted by the tightening muscles preserves the arched form of the foot which acts as a spring and lends elasticity to the gait. When the apparatus described loses its strength, the foot becomes flat. The resulting faulty structure called flat-foot is painful. According to some data, the role of the passive factors (bones and ligaments) in maintaining the arch is no less and may even be greater than the role of the active factors (muscles).

# THE ACTIVE LOCOMOTOR APPARATUS MYOLOGY

## GENERAL INFORMATION

The muscles of the body should be considered from the standpoint of their development and function as well as the topography of the systems and groups composed of them.

## MUSCLE DEVELOPMENT

The muscles of the trunk develop from the dorsal part of the mesoderm found on the sides of the notochord and neural tube; this part of the mesoderm is divided into primary segments, or somites. After the *sclerotome*, which gives rise to the spinal column, is separated, the remaining laterodorsal part of the somite forms the *myotome* whose cells (myoblasts) become elongated in the longitudinal direction and transform later into symplasts of the muscle fibres. Some myoblasts differentiate into special cells, myosatellites, located next to the symplasts. The myotomes grow ventrally and are divided into the *dorsal* and *ventral* parts. The dorsal part gives rise to the dorsal musculature (on the back of the trunk), the ventral part to the ventral musculature on the anterior and lateral surfaces of the trunk (Figs. 114, 115, and 116).

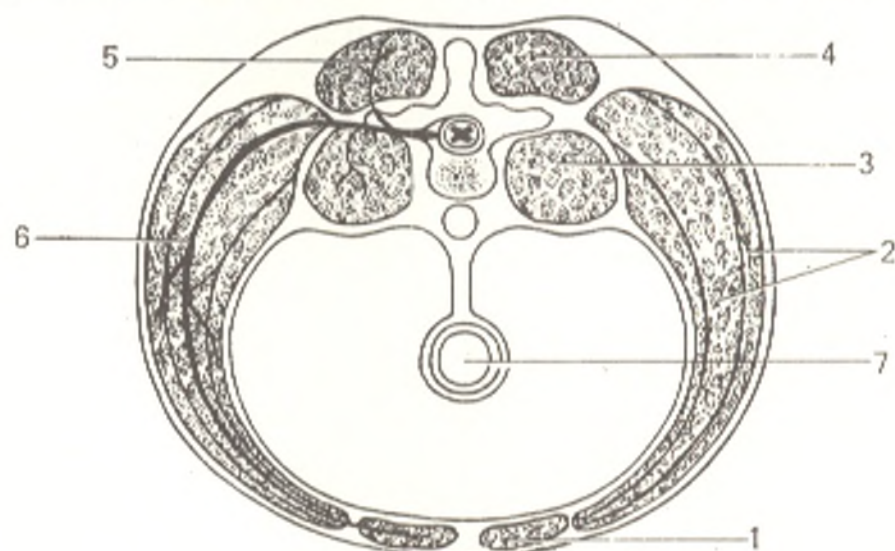


Fig. 114. Division of musculature of the trunk.

1, straight muscles;  
2, wide (lateral) muscles;  
3, prevertebral muscles;  
4, dorsal musculature;

5, posterior branch of spinal nerve;  
6, anterior branch of spinal nerve;  
7, intestine

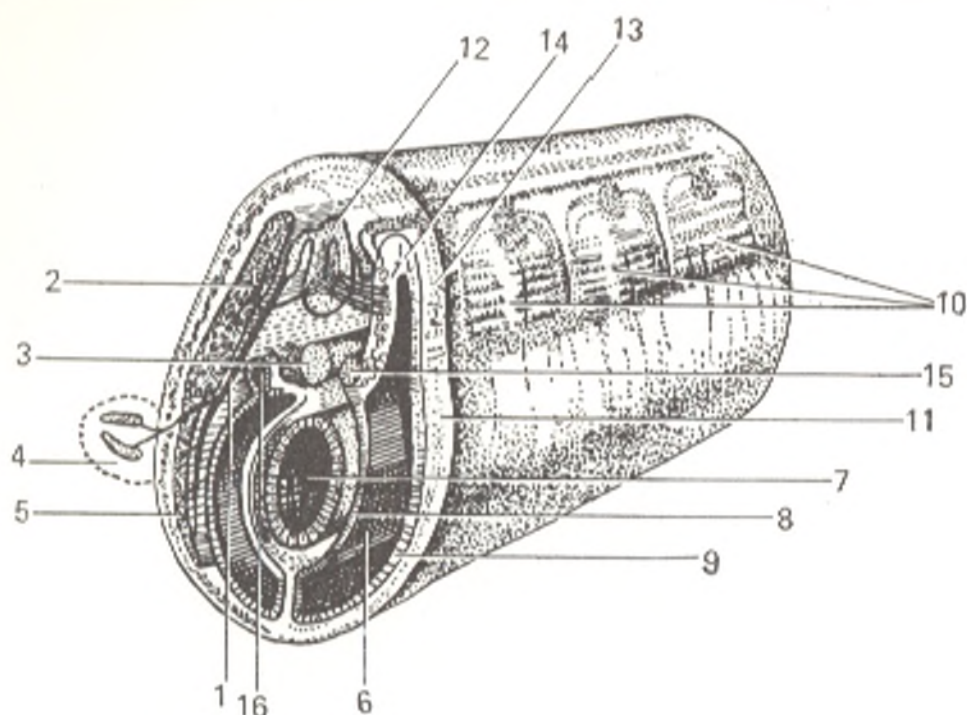


Fig. 115. Section through trunk of vertebrate embryo (schematic representation).

- |                                     |                                     |
|-------------------------------------|-------------------------------------|
| 1, ramus ventralis n. spinalis;     | 9, parietal sheet of lateral plate; |
| 2, ramus dorsalis n. spinalis;      | 10, primary segments;               |
| 3, chorda dorsalis;                 | 11, ectoderm;                       |
| 4, limb bud;                        | 12, spinal tube;                    |
| 5, ventral process of mesoderm;     | 13, dermatome;                      |
| 6, body cavity;                     | 14, myotome;                        |
| 7, gut;                             | 15, sclerotome;                     |
| 8, visceral sheet of lateral plate; | 16, nephrotome                      |

Branches of the corresponding spinal nerve (neuromere) penetrate each myotome (myomere). In accordance with the division of the myotome into two parts, the nerve gives off two branches, a dorsal (posterior) branch, which enters the dorsal part of the myotome, and a ventral (anterior) branch, which enters the ventral part. All muscles derived from one and the same myotome are supplied with one and the same spinal nerve. Adjacent myotomes may merge, but each of the merged myotomes retains the nerve related to it. Muscles originating from several myotomes (e.g. the rectus abdominis muscle) are therefore innervated by more than one nerve. The myotomes on each side are primarily separated one from the other by transverse connective-tissue septa, *myosepta* (Fig. 117). This segmented arrangement of the muscles of the trunk remains throughout life in lower animals. The more elaborate differentiation of the muscular mass in higher vertebrates and man smoothes away the segmentation considerably, though traces of it remain both in the dorsal (the short muscles between the vertebrae) and in the ventral musculature (the intercostal muscles and the rectus abdominis muscle) (Fig. 118). Some of the muscles remain in the place of their formation on the trunk and form the local, native, *autochthonous* musculature (Gk *autos* self, *chthon* earth). Others move from the trunk to the limbs in the process of development. These muscles are called *truncifugal* (trunc + L *fugero* flee). Finally,

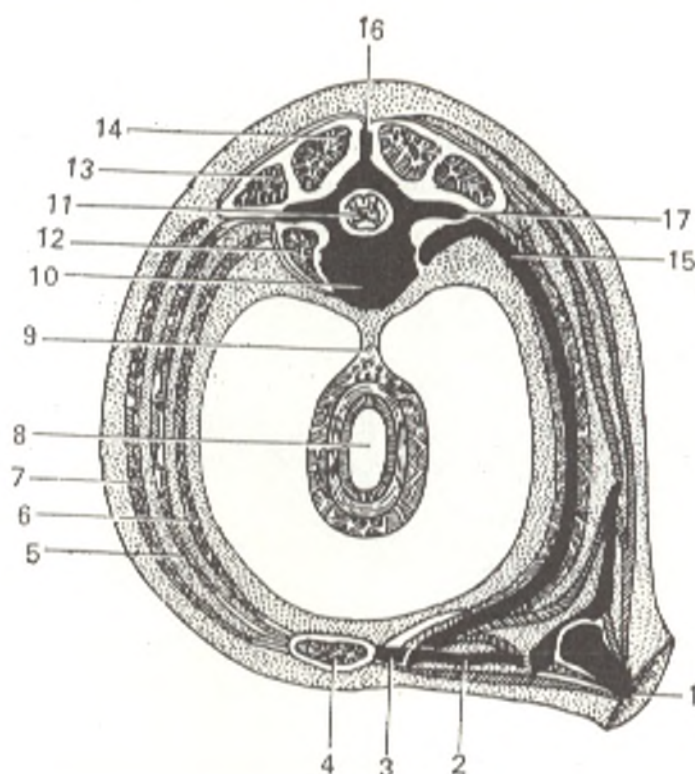


Fig. 116. Transverse schematical section through an adult body (left, abdomen; right, thorax).

- |  |  |
|--|--|
| 1, femur;                              | 10, chorda dorsalis (notochord) in vertebral body;           |
| 2, clavicle;                           | 11, neural tube;   |
| 3, sternum;                            | 12, loin muscle;   |
| 4, straight muscle of abdomen;         | 13 and 14, lateral and medial tracts of muscles of the back; |
| 5, internal oblique muscle of abdomen; | 15, rib;   |
| 6, transverse muscle of abdomen;       | 16, spinous process of vertebra;                             |
| 7, external oblique muscle of abdomen; | 17, transverse process of vertebra                           |
| 8, intestine;                          |  |
| 9, mesentery;                          |  |

a third group of muscles arises on the limbs and migrates to the trunk; these are *truncipetal* muscles (L *petere* to go, to seek). Autochthonous muscles (i.e. those developing in the given place) can always be differentiated, according to innervation, from the new muscles which moved there.<sup>1</sup>

The musculature of the limbs is a derivative of the ventral trunk musculature and is supplied with nerves from the ventral branches of the spinal nerves through the brachial and lumbosacral plexuses. In lower fish (Selachii) muscle buds grow from the myotomes of the trunk, which are divided into two layers, one lying on the dorsal and the other on the ventral side of the skeleton of the fin. Similarly, in terrestrial vertebrates the muscles are primarily arranged dorsally and ventrally (extensors and flexors) in relation to the germ of the limb skeleton. In further differentiation the muscle buds of the anterior limb also grow proximally (truncopetal muscles) and cover

<sup>1</sup> The relation of the muscles to the nerve segments (neuromeres) is very important in neurology and surgery and in the description of the separate muscles. Therefore, we shall indicate below their innervation according to the cervical (C), thoracic (Th), lumbar (L), and sacral (S) segments and nerves.

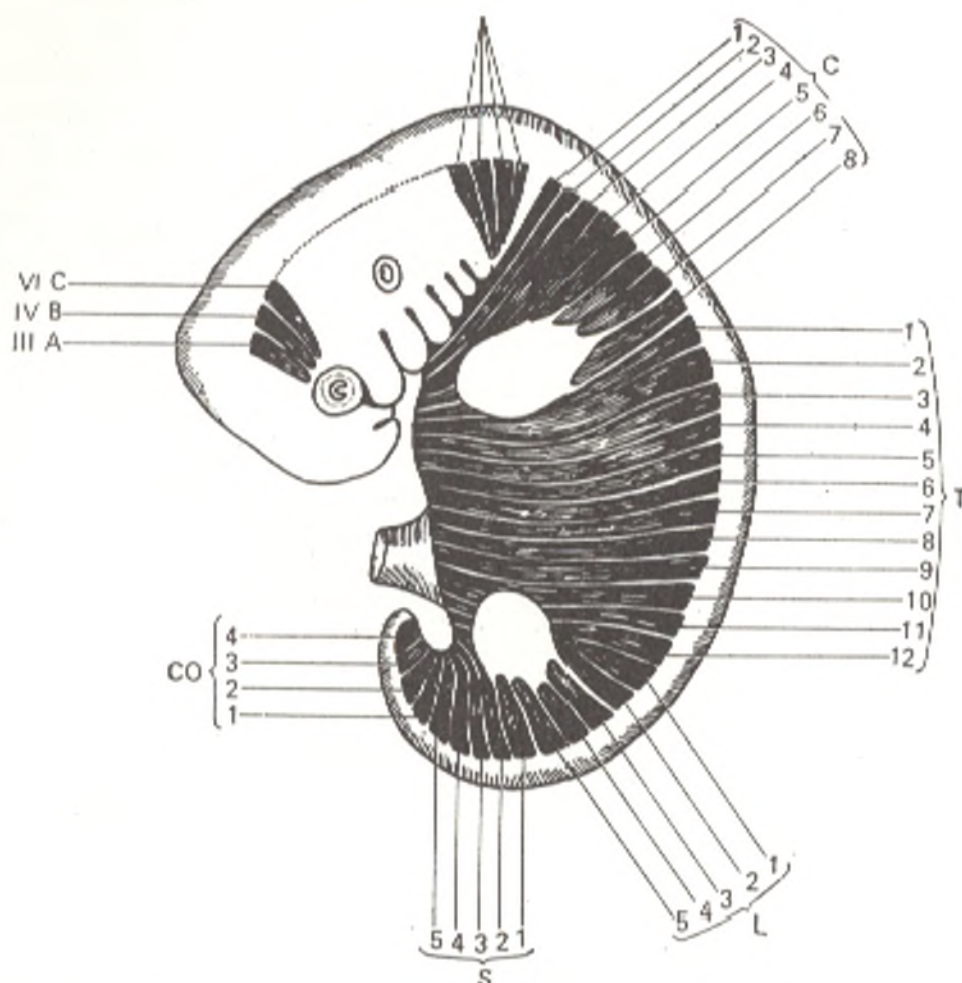


Fig. 117. Arrangement of head and trunk myotomes of embryo.

IIIA, IVB, VIC, pre-auricular myotomes giving rise to ocular muscles innervated by the third, fourth, and sixth pairs of cranial nerves;

XII, occipital myotomes innervated by 12th pair of cranial nerves; C<sub>1-8</sub>, T<sub>1-12</sub>, L<sub>1-5</sub>, S<sub>1-5</sub>, and CO<sub>1-4</sub>, myotomes of different parts of trunk

the autochthonous musculature of the trunk on the chest and back (the pectoralis major and minor muscles, the latissimus dorsi muscle). Besides this primary musculature of the anterior limb, truncofugal muscles join the shoulder girdle; these are derivatives of the ventral musculature which are concerned with locomotion and fixation of the shoulder girdle and have moved to the shoulder girdle from the head (the trapezius and sternocleidomastoid muscles) and trunk (the rhomboid, levator scapulae, anterior serratus, subclavius, and omohyoid muscles). Secondary muscles do not develop at the girdle of the posterior (hind) limb because the joint between it and the spine does not allow any movement. The complicated differentiation of the limb muscles in terrestrial vertebrates, particularly in the highest forms, is explained by the functions of the limbs, which are transformed into complex levers to accomplish different types of movements.

The muscles of the head arise partly from the cephalic somites, but mainly from the mesoderm of the visceral apparatus. The visceral apparatus in the lower fish consists of an entire muscular layer (a common constrictor),

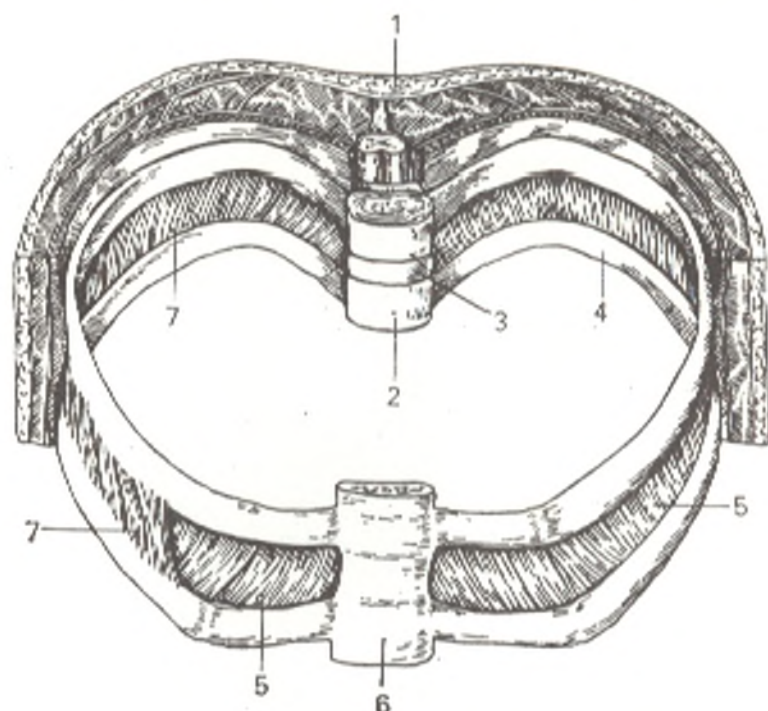


Fig. 118. Segmental structure of muscles of trunk (schematical representation).

1, skin;  
2, vertebra;  
3, discus intervertebralis;  
4, rib;

5, mm. *intercostales interni* (mm. *intercostales externi* have been removed);  
6, sternum;  
7, mm. *intercostales externi*

which, according to innervation, is separated into areas coinciding with the metameric arrangement of the visceral arches: the fifth pair of cranial nerves (the trigeminal nerve) corresponds to the first visceral (mandibular) arch; the seventh pair (the facial nerve) to the second visceral (hyoid) arch; and the ninth pair (the glossopharyngeal nerve) to the third visceral (first branchial) arch. The remaining part of the common constrictor is supplied with the branches of the tenth pair (the vagus nerve). Behind the common constrictor a bundle is set apart which is attached to the shoulder girdle (the trapezius muscle). When the lower vertebrates stopped living in water and adapted to life on dry land, they lost their ability to breathe branchially, an adaptation to aquatic life. The muscles of the visceral apparatus (visceral muscles), therefore, spread to the skull where they transformed into the muscles of mastication and facial expression although they retained their connection with those parts of the skeleton which had developed from the visceral arches. The masticatory muscles, arising from the mandibular arch, and the muscles of the floor of the mouth are thus located on and attached to the mandible and are innervated by the trigeminal nerve (fifth pair). The musculature corresponding to the second visceral (hyoid) arch mainly gives rise to the subcutaneous muscles of the neck and head, which are innervated by the facial nerve (seventh pair).

Muscles derived from the material of both visceral arches are marked by double attachment and double innervation, for instance, the digastric



muscle whose anterior belly is attached to the mandible (innervated from the trigeminal nerve) and the posterior belly to the hyoid bone (innervated from the facial nerve). The visceral musculature innervated by the ninth and tenth pairs of the cranial nerves is partly reduced in terrestrial vertebrates and partly gives rise to the muscles of the pharynx and larynx. The trapezius muscle loses all connection with the visceral arches and becomes exclusively a muscle of the shoulder girdle. The independent sternocleidomastoid muscle separates from it in mammals. The posterior branch of the vagus innervating the trapezius muscle transforms in highest vertebrates to an independent cranial nerve, the accessory nerve (eleventh pair). Since the cerebral cranium is immobile in all its parts, no development of muscles can be expected on it. Therefore, only some remnants of musculature formed from the cephalic somites are found on it. Among these are the ocular muscles derived from the preauricular myotomes (innervation from the third, fourth, and sixth pairs of cranial nerves) (see Fig. 117).

The occipital myotomes and the anterior truncal myotomes usually form by their ventral processes a special sub-branchial or hypoglossal musculature located under the visceral skeleton. In terrestrial vertebrates this musculature, penetrating anteriorly to the mandible, gives rise to the muscles of the tongue, which, because of their origin from the occipital somites, are supplied with a complex of nerves forming the hypoglossal nerve, which has become a true cranial nerve only in the highest vertebrates. The remainder of the hypoglossal musculature (below the hyoid bone) is a continuation of the ventral musculature of the trunk innervated by the anterior branches of the spinal nerves. Thus, to understand the arrangement and attachment of muscles, it is necessary to take into account both their function and their development (see Figs. 114, 115, and 116).

## THE MUSCLE AS AN ORGAN

A muscle is formed of bundles of striated fibres. These fibres run parallel to each other and are bound by loose connective tissue (*endomysium*) into bundles of the first order. Several such primary bundles unite and in turn form bundles of the second order, and so on. The muscle bundles of all orders are united by a connective-tissue sheath, *perimysium*, to form the muscle belly. The connective-tissue layers between the muscle bundles are continuous at the ends of the belly with the tendon of the muscle.

Since a muscle contracts when it receives an impulse from the central nervous system, each muscle must be connected to it via a set of nerves. There are two types of these: afferent nerves which convey impulses from the muscles to the nervous system and thus conduct "muscle perceptions" (Pavlov called them motor analysers); and efferent nerves which convey impulses to the muscles and thus conduct the excitations to the muscle. Besides, the muscle receives sympathetic nerves, which keep the muscle in a living organism in a constant state of constriction called tone or tonus. Vigorous metabolism takes place in the muscles, and they are consequently supplied richly with vessels. According to the law of the shortest distance, the muscles are

supplied with arteries from the nearest vessels, which give off muscle branches, *rami musculares*. The accompanying veins drain into analogous venous trunks. The intervacular veins anastomose extensively and each artery is attended by two veins. The vessels penetrate the muscle from the medial side at one (the belly of the muscle) or more points called the *porta of the muscle*. Nerves enter the porta with the vessels and branch out together with them in the thickness of the muscle correspondingly to the bundles (longitudinally and transversely).

Each muscle has an actively contracting part, i.e. the fleshy central part or *belly (body)*, and a passive part, the *tendon*, by which it is attached to a bone. A tendon consists of dense connective tissue and is a shiny, light gold colour, sharply differing from the reddish-brown colour of the belly. A tendon is usually found on both ends of a muscle, but when the tendon is very short, the muscle seems to arise from the bone or to be attached to it directly by the belly. A tendon has a lower metabolism and so is less richly supplied with vessels than the belly. Thus, a skeletal muscle consists of striped (striated) muscle tissue, as well as of different types of connective tissue (perimysium, tendon), nervous tissue (nerves of the muscle), endothelium, and smooth (unstriated) muscle fibres (vessels of the muscle). Striated muscle tissue prevails, however, and it is its property (contractility) that determines the function of the muscle as an organ of contraction. Each muscle is a separate organ, i.e. an integral structure with its own distinctive shape, structure, function, development, and location in the body.

## THE WORK OF MUSCLES (ELEMENTS OF BIOMECHANICS)

*Contractility* is the principal property of muscular tissue on which the work of the muscles is based.

When the muscle contracts the two points of its attachment are drawn closer together. The *mobile point* of attachment (*punctum mobile*) is pulled toward the fixed point (*punctum fixum*) and as a result a movement occurs in that part of the body.

In this manner, the muscle exerts traction of a certain force and moving a load (e.g. the weight of a bone), accomplishes a definite, mechanical, task. The force of the muscle depends on the number of muscle fibres composing it and is determined by the size of the physiological cross-section, i.e. the size of the section at the site through which all the fibres of the muscle pass. The range of the contraction depends on the length of the muscle. The bones moving at the joints under the effect of the muscle form levers, from the mechanical standpoint, i.e. the simplest machine, as it were, for moving weights (Fig. 119).

The point at which the lever rests (fulcrum), the load point, and the effort point which is where the force for overcoming the load is applied (to move the weight) are distinguished in a lever. The distance between the fulcrum and the point of resistance is called the "arm of load", while the distance between the fulcrum and the point of application of the force is called the "arm of effort". When the fulcrum is between the load point and the effort

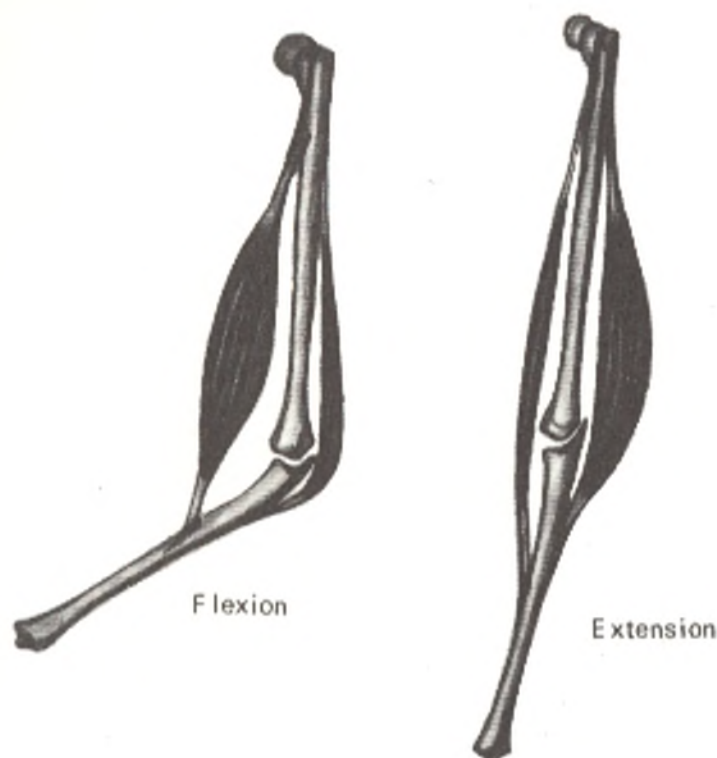


Fig. 119. Mechanics of muscular movement.

*Left*, muscle lying on the medial surface of the joint (its contraction accomplished flexion);

*Right*, muscle lying on the lateral surface of the joint (its contraction causes extension)

point, the lever has two arms (like those of a scale) and serves to maintain balance. It is therefore called a *balance lever*, or first-order (double-arm) lever (Fig. 120). An example of such a lever is the atlanto-occipital joint, in which the fulcrum is on the frontal axis of the joint. The point of resistance (the weight of the anterior part of the head) is in front of it while the effort point (the place where muscles balancing the weight of the body are attached) is behind it. The same applies to the hip joints on whose transverse axis the trunk balances.

A second-order lever is formed when the load point and effort point are on the same side of the fulcrum. There are two types of this lever.

The first type is when the load point is between the fulcrum and the effort point. The foot is an example. The fulcrum is on the transverse axis of the metatarsophalangeal joint. The load point is on the talus on which the weight of the body falls, and the effort point is on the tuberosity of the calcaneum, the site of attachment of the triceps surae muscle which raises the tuberosity and with it the whole body when walking. A lever of this type is called a *lever of force* because the arm of effort is longer than the arm of load (Fig. 121).

The second type is when the effort point is between the fulcrum and the load point. The elbow joint during flexion serves as an example. The fulcrum

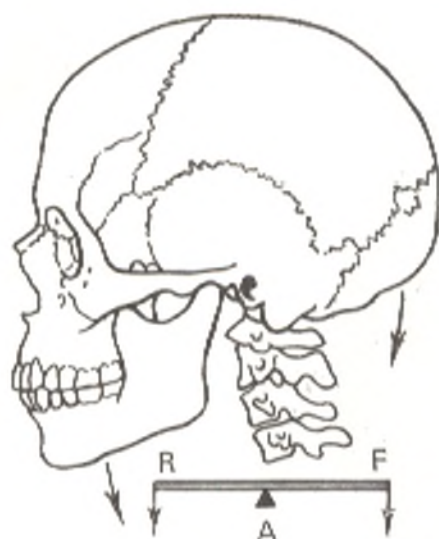


Fig. 120. Balance lever.

A, fulcrum;  
R, effort point;  
F, load point

is within the joint where the forearm bones abut against the end of the humerus, the load point is on the distal end of the forearm while the effort point is in front of the elbow joint, on the tuberosities of the ulna and radius where the flexor muscles are attached. In this lever, the arm of effort is shorter than the arm of load, and a greater force is therefore needed to overcome the load. To make up for this, this type of lever gains in speed and is called the *lever of speed* (Fig. 122).

The longer the distance between the fulcrum and the site where the muscle is attached (effort point), the greater the advantage, because the longer the lever's arm, the better the muscles' force can be exploited. From this standpoint, Lesgaft distinguishes between *strong* muscles attached far from the fulcrum and *agile* muscles attached close to it. Each muscle has a site of *origin* and a site of *insertion*. Since the spinal column passing through the midline of the body supports the whole body, the initial portion of a trunk muscle, usually coinciding with the fixed point, is located nearer the midplane, while that of a limb muscle is found proximally nearer the trunk. The site of insertion, coinciding with the mobile point, is further from the midline; on the limbs it is further from the trunk and distal to it. The fixed point and the mobile point may change places when the former is freed and the latter held fast. For instance, the upper end of the rectus abdominis muscle becomes the mobile point in a standing position (flexion of the upper part of the trunk), but when the body "hangs" on a trapeze by the hands, the lower end is the mobile point (flexion of the lower part of the trunk).

Since movement occurs in two opposite directions (flexion-extension; adduction-abduction, etc.), at least two muscles located on opposing sides are needed to accomplish rotation on any one axis. Muscles acting in mutually opposed directions are called *antagonists*. During each flexion the action of the flexor is always complemented by the action of an extensor, which gradually yields to the flexor and holds it from extreme contraction. The antagonism of muscles ensures, therefore, the smoothness and proportionality of movements. Each movement is, consequently, the result of the action of an-

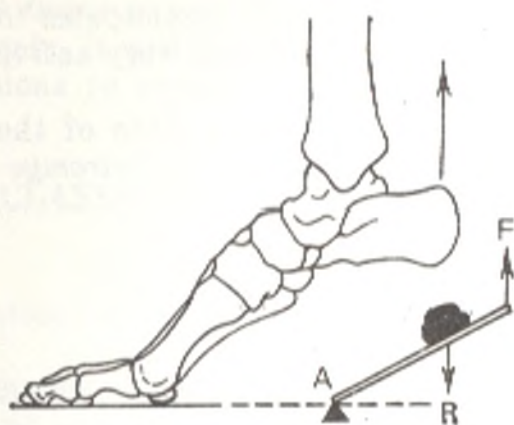


Fig. 121. Lever of force.

A, fulcrum;  
R, effort point;  
F, load point

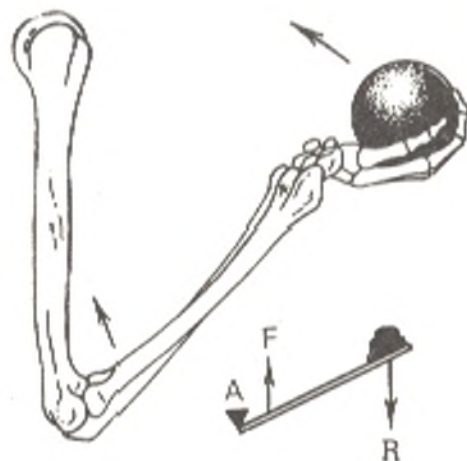


Fig. 122. Lever of speed.

A, fulcrum;  
R, effort point;  
F, load point

tagonists and is the total of the unity and struggle of opposing forces.

As distinct from antagonists, muscles whose resultant<sup>1</sup> passes in one direction are called *agonists* or *synergists*. Depending on the character of movement and the functional combination of the muscles taking part in it, one and the same muscles can act either as synergists or as antagonists.

The work of any muscle or group of muscles in a single body during a normal movement, however, may prove to be much more complex than can be imagined from a purely anatomical standpoint.

The antagonistic and synergic relations between muscles are by no means determined merely by their anatomical position in relation to the various joints. Muscles that are anatomically antagonistic, i.e. found on the opposite sides of one and the same joint, may show no functional antagonism during certain movements and may function as synergists in some natural locomotor acts. In walking, for instance, the flexors and extensors of the hip and knee joints act as antagonists only at the beginning and end of the weight-bearing period. In the middle of this period they act as synergists. The classification of muscles as synergists and antagonists is, therefore, determined by functional rather than morphological relationships.

In addition to the elementary function of muscles determined by their anatomical relation to the pivotal axis of the given joint, it is necessary to take into account the functional changes in the state of the muscles in association with maintenance of the position of the body and its parts and the continuously altering static and dynamic load experienced by the locomotor apparatus. One and the same muscle, consequently, often alters its function depending on the position of the body or its parts during the action and the phase of the corresponding motor action. For instance the upper and lower parts of the trapezius muscle act differently in raising the arm above the shoulder. Both parts participate actively in abduction of the arm, but when the arm is raised above 120 degrees, the lower part of the muscle is no longer active, while the upper part continues acting until the arm is raised to a ver-

<sup>1</sup> The resultant of a muscle is a straight line connecting the centre of its origin with the centre of its insertion.

tical position. The lower part of the trapezius muscle hardly participates in flexion of the upper limb, i.e. in raising it forward, but becomes very active after the limb is brought above the level of 120 degrees.

Such profound and exact information on the functional state of the separate muscles of a living organism is obtained by means of *electromyography* (see the corresponding chapter).

## REGULARITIES IN THE DISTRIBUTION OF THE MUSCLES

1. According to the principle of bilateral symmetry of the body structure, the muscles are *paired* or consist of two symmetric halves (e.g. the trapezius muscle).

2. In the segmented trunk many muscles are *segmental* (the intercostal muscles, the short muscles of the spine) or retain signs of metamerism (the rectus abdominis muscle). The wide muscles of the abdomen were formed from the merger of segmental intercostal muscles due to reduction of the bone segments, the ribs.

3. Since movement accomplished by a muscle occurs on a straight line which is the shortest distance between two points (the fixed point and the mobile point), the muscles themselves lie on the *shortest distance* between these points. That is why, knowledge of the sites of muscle attachment and the fact that the mobile point is pulled toward the fixed point during a muscle contraction, enables one to know beforehand to which side the muscle will move a bone and to define the muscle's function.

4. Muscles passing over a joint have a definite relationship to the pivotal axes, which determines their function.

*Usually the fibres or the resultant of muscles cross almost at a right angle that axis of the joint on which they move.* If a muscle extends vertically (i. e. perpendicular to the axis) from uniaxial joint with a frontal axis (hinge joint), the muscle will also accomplish flexion (diminution of the angle formed by the moving parts) on the flexion surface. If the muscle extends vertically, but from the extension surface, it effects extension (increase of the angle to 180 degrees in full extension).

If there is another horizontal (sagittal) axis in the joint, the resultant forces of the two antagonistic muscles should be arranged analogously, crossing the sagittal axis on the sides of the joint (as, for example, in the radio-carpal joint). In this case, muscles, or their resultants, extending perpendicular and medial to the sagittal axis, will induce a movement toward the midline (an adduction) but those extending perpendicular and lateral to the axis will induce a movement away from the midline (an abduction). Finally, if a joint also has a vertical axis, the muscles cross it perpendicularly or obliquely and accomplish inward rotation (pronation on the limbs) or outward rotation (supination on the limbs). Thus, if we know the number of pivotal axes in a joint we will know the function of the muscles and the way they are arranged about a joint. Knowledge of the arrangement of muscles relative to their pivotal axes is also of practical importance. For example, if

a flexor muscle stretching anteriorly to the frontal axis is transposed posteriorly, it will function as an extensor. This fact is used when transplanting tendons to repair the function of paralysed muscles.

## CLASSIFICATION OF MUSCLES

The numerous muscles (their number is nearly 400) differ in shape, structure, function, and development.

*Long, short, and broad muscles* are classified by their form. The long muscles correspond to long levers of movement and are therefore mainly encountered on the limbs. They are spindle-shaped; their middle portion is called the *belly (venter)*, the end at the origin of the muscle the *head (caput)* and the other end the *tail (cauda)*. The tendons of long muscles resemble narrow bands.

Some of the long muscles originate with more than one head on different bones, strengthening their support. Muscles with *two (biceps)*, *three (triceps)*, and *four heads (quadriceps)* are encountered. In fusion of muscles that differ in origin or develop from several myotomes, *tendinous intersections (intersectiones tendineae)* remain between them. Such muscles (multigastricus, for example) have two bellies (e.g. the digastric muscle) or more (e.g. the rectus abdominis muscle). The number of tendons also varies (multicaudal muscles). The common flexors and extensors of the fingers and toes, for instance, each have more than one tendon (up to four) so that the contraction of one belly of the muscle effects movement of several fingers (toes) simultaneously, and the work of the muscle is, therefore, economized.

The broad muscles are found mainly on the trunk and have an expanded tendon called *aponeurosis*.

Other shapes of muscles are also encountered: quadrate (m. quadratus), triangular (m. triangularis), pyramidal (m. pyramidalis), cylindrical (m. teres), deltoid (m. deltoideus), serrate (m. serratus), and those the shape of the flatfish plaice (m. soleus), etc.

According to the direction of the fibres, which is functionally determined, muscles with straight parallel fibres (m. rectus), oblique fibres (m. obliquus), transverse fibres (m. transversus), and circular fibres (m. orbicularis) are distinguished. The circular fibres form ring-like muscles, or sphincters, around the body's orifices. A muscle whose oblique fibres approach the tendon from only one side is called unipennate; a bipennate muscle is one in which the fibres approach the tendon from two sides. A peculiar relation of fibres to the tendon is encountered in the semitendinous (m. semitendinosus) and semimembranous (m. semimembranosus) muscles (p. 362).

According to function, the muscles are classified as flexors (flexores), extensors (extensores), adductors (adductores), abductors (abductores), rotators (rotatores), effecting medial rotation or pronation, pronators (pronatores) and lateral rotation, supinators (supinatores).

According to their relation to the joints, over which they extend (one, two, or more), the muscles are called uniarticular, biarticular, or multiarticu-

lar. Multiarticular muscles are longer and closer to the surface than the unia-  
rticular muscles. According to position, superficial and deep, internal and  
external, and lateral and medial muscles are distinguished.

## THE AUXILIARY APPARATUS OF MUSCLES

In addition to the main parts of a muscle, the belly and the tendon, there are auxiliary structures which in one way or other make the work of the muscle easier. A group of muscles (or all the musculature of a given part of the body) are invested into membranes of fibrous connective tissue called *fasciae* (L. *fascia* band<sup>1</sup>). The *fasciae* increase the side resistance during muscular contraction and prevent displacement of the muscle to the side. At the site of damage to the fascia, the muscle forms a protrusion, like a muscular hernia. By surrounding the muscles and separating one muscle from another, the *fasciae* promote their isolated contraction. *Fasciae*, therefore, cover either one muscle (*fascia* proper of the given muscle) or a group of synergic muscles, i.e. muscles performing a similar function (deep fascia or *fascia* proper of a region, *fascia propria*). *Fasciae* separating one group of muscles from another give off processes, *intermuscular septa* (*septa intermuscularia*), which penetrate between the neighbouring groups of muscles and attach to the bones. Above the deep *fasciae* there are also superficial *fasciae* which invest all the muscles of a given region and are found under the skin; these are the *subcutaneous*, or *superficial, fasciae* (*fascia subcutanea* s. *superficialis*) (thickened subcutaneous fat). Thus, the *fasciae* not only separate the muscles but also join them.

**The sheath structure of fasciae.** The superficial fascia forms a peculiar sheath for the whole human body. The *fasciae* proper form sheaths for the separate muscles and organs. The sheath structure is typical of *fasciae* investing all parts of the body (trunk, head, and limbs) and the organs of the abdominal, thoracic, and pelvic cavities. This structure in relation to the limbs was studied in particular detail by Pirogov.

Each part of the limb has several sheaths, or fascial sacs, around a single bone (on the upper arm and thigh) or around two bones (on the forearm and leg). The number and size of the fascial sheaths at the different levels of the limb vary because the number and size of muscles originating at different levels and those distally continuous with a tendon also vary along the length of various segments of the limb. For instance, seven or eight fascial sheaths can be distinguished in the proximal segment of the forearm, but there are fourteen in the distal segment.

A main sheath formed by the fascia investing the whole limb and sheaths of the second order containing different muscles, vessels and nerves can be distinguished (Vishnevsky). Pirogov's theory of the sheath structure of the *fasciae* on the limbs is important for understanding the spread of pus in inflammation or of blood during haemorrhage; it is also important in administration of local (infiltration) anaesthesia.

<sup>1</sup> Romans used the term *fascia* for a cloth in which they wrapped infants.



The failure of attempts to induce regional anaesthesia of nerves is explained by the presence of loose fatty tissue directly surrounding the nerves and vessels around which the fascial sheaths form.

Due to the close relationship of the vessels and fasciae, the latter promote the circulation of the blood and lymph. The fasciae of the limbs, for example, are no less important than the venous valves in movement of the blood along the veins.

In addition to the theory of the sheath structure of fasciae, the theory of fascial nodes has been advanced recently. These are connective-tissue structures of three types: aponeurotic, fascial-adipose, and mixed. They are concerned with support and demarcation. The supporting role is accomplished due to connection between the fascial nodes and the bone or periosteum, as a result of which the fasciae contribute to muscle traction. The fascial-adipose nodes strengthen the sheaths of the vessels and nerves, glands, and so on and thus promote the circulation of the blood and lymph. The demarcation role is manifested in separation of one fascial sheath from another by the fascial nodes, thus arresting the flow of pus, which moves freely if the fascial nodes are destroyed. Surrounding the muscles and separating them from one another, the fasciae promote their isolated contraction. Therefore, the fasciae both separate and connect the muscles.

## THE SOFT FRAMEWORK OF THE HUMAN BODY

The thorough study of fasciae led to the development of the theory of the soft framework of the human body.

Fasciae, intermuscular septa, coverings of organs, and the sheaths of vessels and nerves are the most important components of this framework. As pointed out above, superficial and deep fasciae are distinguished. The fasciae propria of muscles and the sheaths of muscles, vessels, nerves and lymph nodes are the coverings of the organs.

Aponeuroses, being intermediate between fasciae and tendons, are also components of the soft framework; the fasciae themselves are an intermediate link between aponeuroses and the fatty tissue.

The skin, subcutaneous fat, and superficial (subcutaneous) fascia are connected functionally and morphologically and provide the elastic support of the body.

The soft framework of the body is, therefore, the connective-tissue skeleton of the body, which consists of the connective-tissue supporting structures named above.

Thickenings in the form of ligaments are found in the fasciae in the region of some limb joints. They are made up of dense fibres running over the tendons which pass here. Fibrous and osteofibrous canals, or sheaths (*vaginae fibrosae tendinum*) transmitting tendons form under these fascial ligaments. The ligaments and the fibrous sheaths located below them hold the tendons in place on the bone. They also prevent their displacement to the sides and as a result help direct the muscle traction more exactly. Gliding of the tendons in the fibrous sheaths is made easier because the walls of the sheaths are

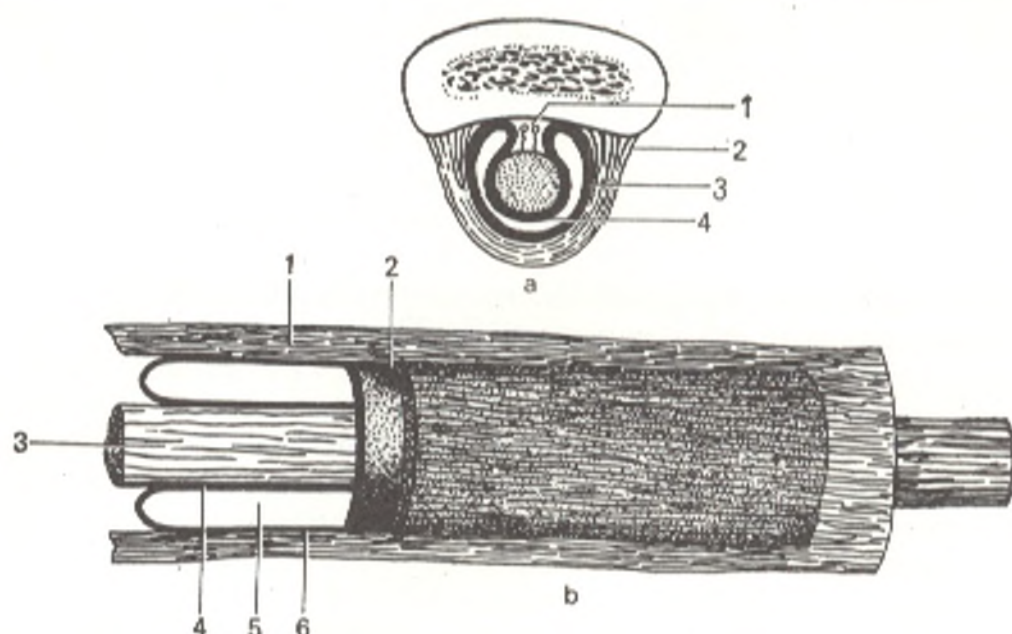


Fig. 123. Synovial sheath of tendon, represented schematically.

a, transverse section:

1, mesotendineum;

2, vagina fibrosa;

3, parietal membrane of synovial sheath;

4, visceral membrane of synovial sheath.

b, longitudinal section:

1, vagina fibrosa tendinis;

2, vagina synovialis tendinis;

3, tendo;

4, visceral membrane of synovial sheath;

5, cavity of vagina synovialis;

6, parietal membrane of synovial sheath.

lined with a fine synovial membrane which at both ends of the sheath folds over on the tendon and forms a closed **synovial sheath** (*vagina synovialis tendinis*) around it. Part of the synovial membrane, enclosing the tendon directly and fusing with it forms the *visceral layer*, while the other part, lining the fibrous sheath and fusing with its wall, forms the *parietal layer*. Duplication of the synovial membrane, called the *mesentery of the tendon* (*mesotendineum*), forms about the tendon where the visceral layer is continuous with the parietal layer (Fig. 123). Nerves and vessels of the tendon pass in its thickness. Necrosis of the tendon, therefore, occurs in injury to the mesotendineum and to the nerves and vessels in it. The mesotendineum is strengthened with fine ligaments (*vincula tendinum*) (see Fig. 149). A few drops of fluid resembling synovia are found in the cavity of the synovial sheath between the visceral and parietal layers of the synovial membrane. The fluid lubricates and facilitates movement of the tendon in the sheath.

**Synovial bursae** (*bursae synoviales*) are of similar significance. They are found in different parts under the muscles and tendons, mainly near the sites of attachment. Some bursae, as is pointed out in the chapter dealing with syndesmology, communicate with the joint cavity. A *pulley-shaped structure* (*trochlea*) is usually formed in places where the tendon of a muscle changes its direction; the tendon passes over the trochleae like a belt over a pulley. There are bony and fibrous trochleae. In the first case the tendon passes over the bone whose surface is lined with cartilage and there is a synovial

bursa between the bone and the tendon; fibrous trochleae are formed by fascial ligaments.

*Sesamoid bones (ossa sesamoidea)* are also related to the auxiliary structures of a muscle. They occur in the thickness of a tendon at the site of their attachment to the bone, in places where it is necessary to increase the angle of attachment of the muscle to the bone in order to increase its force.

## THE EFFECT OF ENVIRONMENTAL FACTORS ON THE MUSCULATURE

A muscle possesses vigorous metabolism, which increases more as the amount of its work increases. The flow of blood along the vessels to the muscle also increases in such cases. Intensified function of the musculature causes improvement of nutrition and increase in the mass of the muscle (the so-called work hypertrophy of the muscle). Physical exercises associated with different types of work and sports lead to work hypertrophy of the muscles experiencing the greatest exertion.

A craftsman's work requires that his body is held in one position for a long time (e.g. bent over when working at a bench) or that his body's position is continuously changed in one direction (e.g. a carpenter bending and straightening his trunk). Distinct occupations, consequently, cause intensified activity of only particular parts of the musculature. As a result a specialized occupation causes excessive development of certain parts of the body and lesser development of others. In the same way, different sports develop only certain groups of muscles. Sports training programmes, therefore, should include general physical exercises to facilitate the harmonious development of the human body. The musculature of almost the whole body of weight lifters, for example, is hypertrophied to such an extent, and their body build is so powerful, that they seem to belong to a special race of people. This, however, is not due to an inherited constitution but is the result of the controlled influence of the athletic specialization.

Proper physical exercises induce proportional development of the whole body musculature. Since intensified work of the muscles has an effect on the metabolism of the whole organism, physical exercise is one of the most powerful factors in the favourable development of the organism.

## SPECIAL MYOLOGY

### MUSCLES OF THE BACK

There are very many muscles in the back, the bulk of them being formed by autochthonous muscles that originate from the dorsal parts of the trunk myotomes. They are covered by muscles which are displaced to the back from the head (visceral muscles) and upper limbs (truncopetal muscles). As a result the muscles of the back are arranged in two layers, the superficial and the deep layers.

A. **Superficial muscles.** 1. *Muscles attached to the shoulder girdle and upper arm:* (a) the trapezius muscle, which is of branchial origin, moved to the trunk from the head and is therefore innervated by the eleventh cranial nerve (n. accessorius); (b) the latissimus muscle of the back, a truncopetal muscle, moved to the back from the head and is therefore supplied with nerves from the brachial plexus; (c) the levator muscle of scapula and the rhomboid muscle are truncofugal muscles which moved from the trunk to the shoulder girdle and are innervated by the short branches of the brachial plexus.

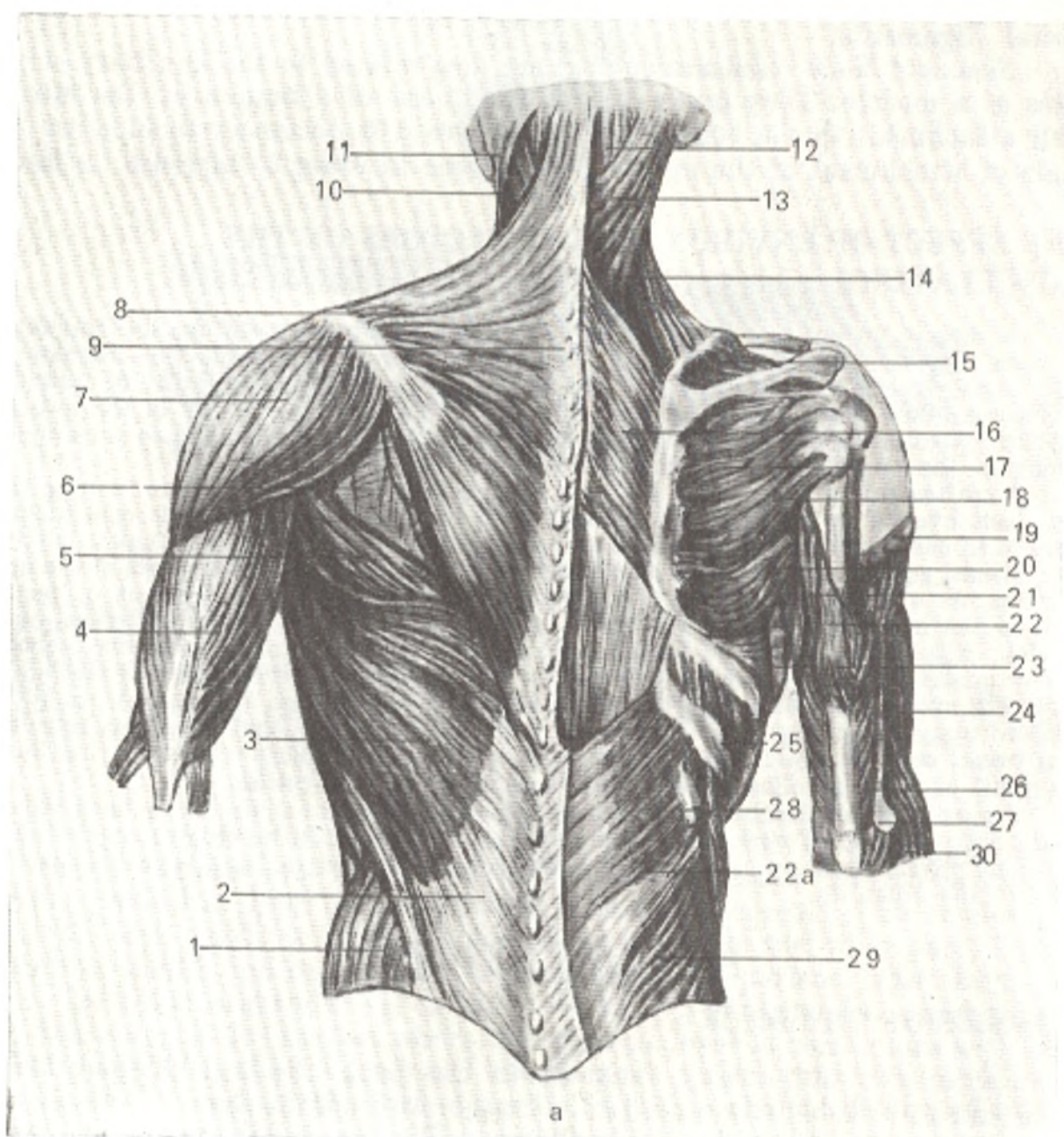
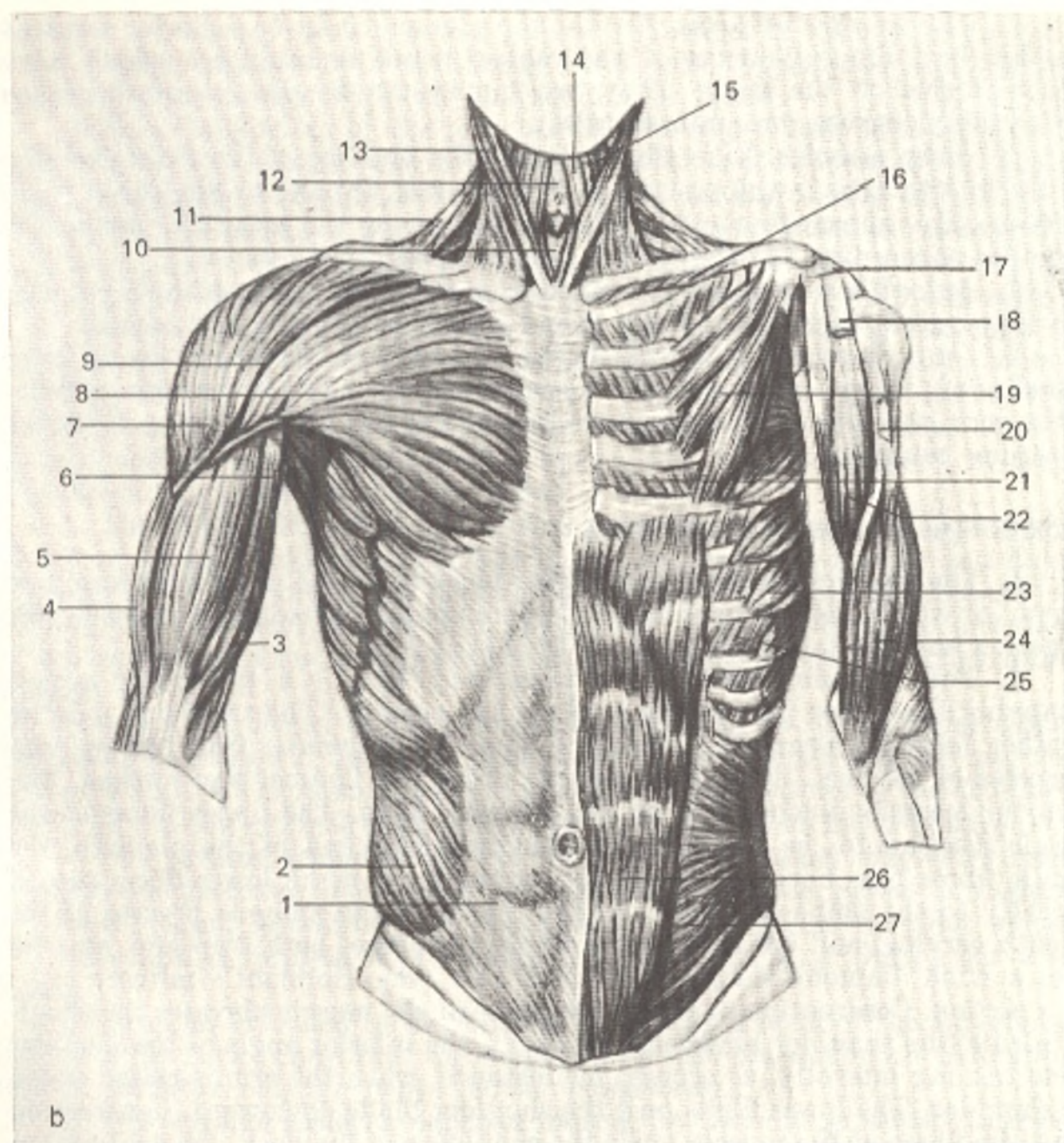


Fig. 124. Muscles of the trunk.

*a*, posterior aspect; left, first layer of superficial muscles; right, second layer of superficial muscles:  
 1, m. obliquus abdominis externus;  
 2, fascia thoracolumbalis;  
 3, m. latissimus dorsi;  
 4, m. triceps brachii;  
 5 and 20, m. teres major;  
 6, fascia infraspinata;  
 7, m. deltoideus;  
 8, m. trapezius;  
 9, vertebra prominens;  
 10 and 13, m. splenius capitis;  
 11, m. sternocleidomastoideus;  
 12, m. semispinalis;  
 14, m. levator scapulae;  
 15, m. supraspinatus;

16, m. rhomboideus major;  
 17, m. infraspinatus;  
 18, m. teres minor;  
 19, m. deltoideus (transected);  
 20, m. teres major;  
 21, caput longum m. tricipitis;  
 22, caput laterale m. tricipitis;  
 22a, m. serratus posterior inferior;  
 23, m. latissimus dorsi (transected);  
 24, m. brachialis;  
 25, m. intercostalis externus;  
 26, septum intermusculare laterale;  
 27, epicondylus lateralis;  
 28, costa XII;  
 29, m. obliquus abdominis internus;  
 30, m. brachioradialis



b, anterior aspect; left, superficial muscles; right, deep muscles:  
 1, vagina m. recti abdominis;  
 2, m. obliquus abdominis externus;  
 3, caput brevis m. bicipitis brachii;  
 4, m. brachialis;  
 5, caput longum m. bicipitis brachii;  
 6, m. teres major;  
 7, m. deltoideus;  
 8, m. pectoralis major;  
 9, sulcus deltoideopectoralis;  
 10, m. sternothyreoideus;  
 11, m. trapezius;  
 12, cartilago thyroidea;  
 13, m. sternocleidomastoideus;

14, m. sternohyoideus;  
 15, m. omohyoideus;  
 16, m. subclavius;  
 17, proc. coracoideus;  
 18, tendo capitis brevis m. bicipitis brachii;  
 19, m. pectoralis minor;  
 20, tendo capitis longi m. bicipitis brachii;  
 21, m. intercostalis internus;  
 22, m. coracobrachialis;  
 23, m. serratus anterior;  
 24, m. brachialis;  
 25, m. intercostalis externus;  
 26, m. rectus abdominis;  
 27, m. obliquus abdominis internus

2. *Muscles attached to the ribs*: the superior and inferior posterior serratus muscles; both are derivatives of the ventral trunk musculature which have been displaced to the back. They are innervated by the anterior branches of the spinal nerves (nn. intercostales).

B. **Deep muscles.** Like the skeleton, the muscles of the axial skeleton are the first to arise in the process of phylogenesis. In man's ontogenesis they, consequently, appear first and lie deeper, preserving the primitive metameric structure. According to origin, they are grouped as follows:

1. *Autochthonous muscles*, derived from the dorsal parts of the myotomes and innervated, therefore, by the dorsal branches of the spinal nerves.

2. *Deep muscles of ventral origin*, innervated, therefore, by anterior branches of the spinal nerves. These are the anterior intertransverse muscles of the neck, the lateral intertransverse muscles of the loins, and the levatores costarum muscles.

### SUPERFICIAL MUSCLES OF THE BACK

I. The muscles attached to the shoulder girdle and upper arm form two layers, of which the one nearest to the skin consists of two wide muscles, the trapezius and the latissimus dorsi (Fig. 124).

1. The **trapezius muscle** (*m. trapezius*). This is a triangular muscle occupying the upper part of the back to the occiput. The trapezius muscles together form a trapezium, hence the name. It *originates* from the spinous processes of all the thoracic vertebrae, from the ligamentum nuchae, and from the superior nuchal line of the occipital bone. The upper fibres of the muscle descend to be inserted into the acromial end of the clavicle, the middle fibres pass horizontally to the acromion, and the lower fibres ascend laterally to the spina scapulae. In the region of the spinous process of the seventh cervical and the first two thoracic vertebrae, both trapezius muscles form a wide diamond-shaped tendinous area (van Helmont's mirror).

*Action.* Contraction of the upper fibres of the muscle elevates the shoulder girdle (the shoulder blade and clavicle), the inferior angle of the shoulder blade turning laterally, as occurs, for instance, when the arm is raised above the shoulder. The lower fibres pull the shoulder blade downward. Contraction of all the fibres of the muscle pulls the shoulders to the back. On contraction of both muscles the shoulder blades are drawn toward each other. *Innervation*: eleventh cranial nerve C<sub>3-4</sub>.

2. The **latissimus dorsi muscle** (*m. latissimus dorsi*) (*L. latissimus* widest) occupies the whole lower part of the back and its upper portion is covered by the lower end of the trapezius muscle. The latissimus dorsi *originates* from the spinous processes of the lower four (sometimes five or six) thoracic, all the lumbar and sacral vertebrae, from the posterior portion of the iliac crest, and, finally, four of its slips arise from the lower four ribs. These slips interdigitate with the posterior slips of the external oblique muscle of the abdomen. From the site of their origin the fibres of the latissimus dorsi muscle pass upward and laterally in a converging manner, embrace with their upper edge the inferior angle of the shoulder blade, and, approaching the

humerus, are *inserted* into the crista tuberculi minoris. In their initial portion in the lumbar region, both latissimus dorsi muscles form an extensive aponeurosis, which merges with the thoracolumbar fascia.

*Action.* Contraction of the muscle pulls the upper limb to the back and downward and at the same time rotates it medially, as it happens, for instance, when a conductor of an orchestra takes a handkerchief out of the pocket of his tail-coat. By means of the humerus, the muscle moves the shoulder girdle in the same direction. Because it is attached to the ribs, the muscle can expand the chest when the upper limbs are held fast and thus help expiration: it can also pull the trunk up to the upper limbs, e.g. during exercises on a horizontal bar or trapeze. Monkeys swing their body from branch to branch by pulling their trunk upward (movement by means of the upper limbs, brachiation), which explains the powerful development of the latissimus dorsi in monkeys and its marked preservation (as an echo of phylogenesis) in man. Innervation: C<sub>5-8</sub>. Thoracodorsal nerve.

3. The **rhomboid major and minor muscles** (*mm. rhomboideus major and minor*) closely adjoin one another under the trapezius muscle and have the shape of a rhomboid plate. They *originate* from the spinous processes of the lower two cervical (lesser) and upper four thoracic vertebrae (greater) and are *inserted* into the medial border of the shoulder blade below the spina scapulae.

*Action.* Contraction of the rhomboid muscles pulls the shoulder blade to the spine and upward. Being the antagonists of the anterior serratus muscle, together with it the rhomboid muscles press the medial border of the shoulder blade firmly to the thoracic cage. (Innervation: C<sub>4-5</sub>. Dorsal nerve of scapula.)

4. The **levator scapulae muscle** (*m. levator scapulae*) *originates* from the transverse processes of the upper four cervical vertebrae, passes downward and laterally, and is *inserted* into the superior angle of the shoulder blade.

Its *action* is implied by its name. Innervation: C<sub>4-5</sub>. Dorsal nerve of scapula.

II. Muscles attached to the ribs are in the third layer of the superficial muscles of the back. They have the shape of two thin plates and are called the *posterior serratus muscles* (*mm. serrati posteriores*).

1. The **serratus posterior superior muscle** (*m. serratus posterior superior*) lies in the upper part of the back under the rhomboid muscle. It *originates* from the spinous processes of the lower two cervical and upper two thoracic vertebrae, runs obliquely downward and laterally, and is *inserted* by four slips into the posterior surfaces of the second to fifth ribs laterally of their angles.

*Action.* Raises the ribs. Innervation: Th<sub>1-4</sub>. Intercostal nerves.

2. The **serratus posterior inferior muscle** (*m. serratus posterior inferior*) lies in the same plane as the superior muscle, but its fibres run in the opposite direction. *Originating* from the thoracolumbal fascia in the region of the spinous processes of the lower two thoracic and upper two lumbar vertebrae, it is *inserted* by four slips into the posterior surfaces of the ninth to twelfth ribs.

*Action.* Pulls the lower ribs downwards. Innervation: Th<sub>9-12</sub>. Intercostal nerves.

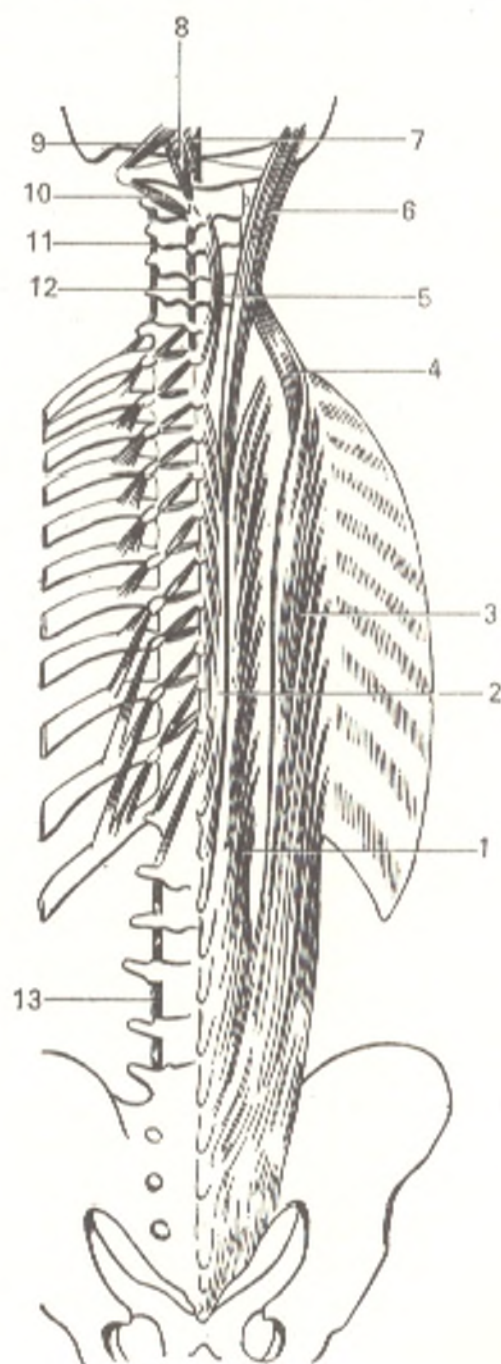
## DEEP MUSCLES OF THE BACK

## AUTOCHTHONOUS MUSCLES OF THE BACK

The autochthonous muscles of the back (Figs. 124 and 125) form on each side two longitudinal (lateral and medial) muscular tracts which are lodged in the groove between the vertebral spinous and transverse processes and the angles of the ribs. In the deep parts, nearest to the skeleton, they are made up of short muscles arranged in segments between the vertebrae (medial tract); the long muscles are closer to the surface (lateral tract). In addition the splenius muscle covers both tracts in the posterior cervical region. All these muscles have a common origin: they originate from the musculature of the back,

Fig. 125. Deep muscles of the back (represented semischematically).

- 1, m. longissimus;
- 2, m. spinalis thoracis;
- 3, m. iliocostalis thoracis;
- 4, m. iliocostalis cervicis;
- 5, m. spinalis cervicis;
- 6, m. longissimus capitis;
- 7, m. rectus capitis posterior minor;
- 8, m. rectus capitis posterior major;
- 9, m. obliquus capitis superior;
- 10, m. obliquus capitis inferior;
- 11, mm. intertransversarii;
- 12, mm. interspinales;
- 13, mm. intertransversarii mediales lumborum





which in the amphibia consists of a series of myomeres. Beginning with the reptiles, however, only part of the muscles of the back maintain a metameric structure, joining the vertebrae to each other (the muscle of the medial tract), while the other part merges to form the long muscles (the lateral tract).

The **splenius capitis** and **splenius cervicis** muscles (*m. splenius capitis* and *m. splenius cervicis*) originate from the spinous processes of the lower five cervical and upper six thoracic vertebrae, run upward and laterally, after which the splenius muscle of the head (*m. splenius capitis*) is inserted into the lateral half of the superior nuchal line and the mastoid process, while the splenius muscle of the neck (*m. splenius cervicis*) is inserted into the transverse processes of the second and third cervical vertebrae.

**Action.** In contraction of one muscle the head turns in its direction; bilateral contraction bends the head and neck backwards.

The **lateral tract.** The characteristic feature of this tract is the attachment of muscles to the vertebral transverse processes and the ribs or to their rudiments.

1. The **sacrospinalis muscle** (*m. erector spinae*) constitutes the main mass of the autochthonous musculature of the back. It originates from the sacrum, spinous processes of the lumbar vertebrae, iliac crest, and thoracolumbar fascia, and then extends to the skull and forms three divisions according to the insertion:

(a) into the ribs, **iliocostocervicalis muscle** (*m. iliocostalis*) (the lateral division of the erector spinae). It has three parts: lumbar, inserted into the transverse processes of the upper lumbar vertebrae and the angles of the lower ribs; thoracic, inserted into the angles of the upper ribs (sixth and fifth); and cervic, inserted into the transverse processes of the lower cervical vertebrae;

(b) into the transverse processes, the **longissimus muscle** (*m. longissimus*) (the intermediate division of the erector spinae). It has four parts (lumbar, thoracic, s. musculi longissimus dorsi, cervicis, and capitis) and is inserted into the transverse processes of all the thoracic and upper cervical vertebrae, the ribs (second to twelfth), and the mastoid process (*m. longissimus capitis*);

(c) into the spinous processes, the **spinalis muscle** (*m. spinalis*) (the medial division of the erector spinae). It is inserted into the spinous processes of the thoracic (second to eighth) and cervical (second to fourth) vertebrae.

2. Separate bundles passing between the transverse processes of two adjacent vertebrae are also related to the lateral tract. They are conspicuous in the most mobile parts of the spine: in the cervical (*mm. intertransversarii posteriores cervicis*) and lumbar (*mm. intertransversarii mediales lumborum*) parts.

The **medial tract.** The muscles of this tract lie under the lateral tract and consist of separate bundles running obliquely from the transverse processes of one vertebra to the spinous processes of the contiguous vertebra above. Because of this they are known by the common name of **transversospinalis muscle** (*m. transversospinalis*). They extend from the sacrum to the occipital bone in three layers that are distinguished by their depth and by the number of vertebrae they overlap. The nearer the muscles to the surface, the steeper

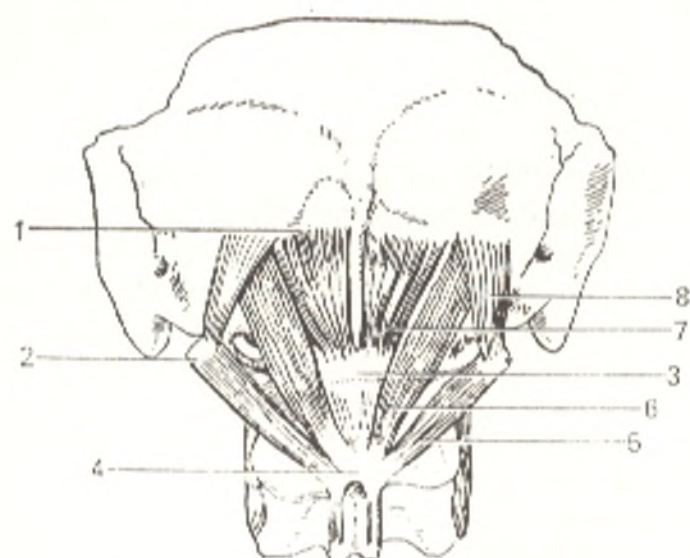


Fig. 126. Deep muscles of the occipital region.

- 1, linea nuchae inf.;
- 2, proc. transversus atlantis;
- 3, tuberculum posterius atlantis;
- 4, proc. spinosus axis;
- 5, m. obliquus capitis inf.;
- 6, m. rectus capitis post. major;
- 7, m. rectus capitis post. minor;
- 8, m. obliquus capitis sup.

and longer the course of their fibres and the greater the number of vertebrae which they overlap. According to this, the following layers are distinguished: a superficial layer (*m. semispinalis*) whose bundles overlap five or six vertebrae; a middle layer (*mm. multifidi*) whose bundles overlap three or four vertebrae, and a deep layer (*mm. rotatores*) passing over one vertebra or to the contiguous vertebra. Muscle bundles between spinous processes of contiguous vertebrae, muscles *interspinales* (*mm. interspinales*), also belong to the medial tract; they are well developed only in the most mobile parts of the spine, i.e. the cervical and lumbar, and are absent in the thoracic region. Their remnant between the sacrum and coccyx is represented by the *sacrococcygeus posterior* muscle (*m. sacrococcygeus posterior*).

In the most mobile part of the spine, in its articulation with the occipital bone, *m. transversospinalis* is particularly well developed and is made up of four paired muscles, two oblique and two straight muscles lying to the back of the atlanto-occipital joint under *m. semispinalis* and *m. longissimus*.

The **oblique** muscles differ from one another in location and are divided into the superior and inferior muscles. The **obliquus capitis superior** muscle (*m. obliquus capitis superior*) stretches from the transverse process of the atlas to the inferior nuchal line. The **obliquus capitis inferior** muscle (*m. obliquus capitis inferior*) passes from the spinous process of the second cervical vertebra to the transverse process of the first cervical vertebra (Fig. 126). The **straight** muscles are distinguished by their length and are divided into the greater and lesser muscles. The greater (*m. rectus capitis posterior major*) passes from the spinous process of the second cervical vertebra to the inferior nuchal line. The lesser (*m. rectus capitis posterior minor*) stretches to the same line from the posterior tubercle of the first cervical vertebra. These muscles exert their action on the atlanto-occipital and atlanto-axial joints. Contraction of the muscles on one side contributes to turning of the head to the corresponding side. Bilateral contraction pulls the head backward.

The *action* of the complex of the autochthonous muscles of the back consists in holding the trunk erect. The specific features of their insertion by

many bundles into many points on the bones ensure the distribution of the muscle force over a large area. Contraction of all the parts of these muscles on both sides effects general extension of the spine, while contraction of separate parts on one side effects extension between the separate vertebrae. Contraction of these muscles on one side causes lateral flexion of the spine and the trunk together with it to this side. The oblique bundles of the autochthonous muscles (*mm. rotatores* and *multifidi*) accomplish rotation of the spine. The upper parts of the muscles, nearest to the skull, participate in the corresponding places to movements of the head, as pointed out above. The deep muscles of the back also take part in the respiratory excursions. The lower part of the iliocostal muscle lowers the ribs, while its upper part raises them. It should be noted that the erector spinae muscle contracts not only in extension of the spine, but also in flexion of the trunk to counteract the backward pull of gravitational force.

Innervation: posterior branches of the spinal nerves, the cervical, thoracic, and lumbar nerves, respectively.

#### DEEP MUSCLES OF THE BACK OF VENTRAL ORIGIN

1. The *levator costarum* muscles (*mm. levatores costarum*) are muscle bundles of the external intercostal muscles that are displaced toward the spine. They exist only in the thoracic region and are under the erector spinae muscle. Each bundle originates from a transverse process (starting from the seventh cervical and ending at the eleventh thoracic vertebra) and is attached to the contiguous rib below. Besides the short bundles, *levator costarum breves* muscles (*mm. levatores costarum breves*) in the lower part of the thoracic region are the long bundles, *levator costarum longi* muscles (*mm. levatores costarum longi*) overlapping one rib. Despite their name, the action of these muscles as levators of the ribs is hardly significant; they mainly participate in lateral bending of the spine. Innervation from the intercostal nerves.

2. The group of muscles of ventral origin also includes the remnants of intercostal muscles found as muscle bundles between the costal rudiments (anterior tubercles) of the cervical vertebrae, *anterior intertransverse muscles* (*mm. intertransversarii anteriores cervicis*), and between the transverse processes of the lumbar vertebrae, *lateral intertransverse muscles* (*mm. intertransversarii laterales lumborum*).

#### FASCIAE OF THE BACK

The outer surface of the trapezius and latissimus dorsi muscles is covered with a thin superficial fascia, which thickens in the posterior portion (fascia nuchae, nuchal fascia). In addition, there is another fascia on the back which lies deeper and separates the autochthonous musculature of the back from the muscles lying more superficially. It is called the *lumbar fascia* (*fascia thoracolumbalis*), and two layers are distinguished in it, the superficial or posterior, and the deep or anterior layers. The *superficial layer* stretches

from the pelvis to the head. Its upper part in the region of the posterior serratus muscle is thin, but its lower part is very strong where it is continuous with the aponeurosis of the latissimus dorsi muscle; medially it is attached to the spinous processes, laterally it is continuous with the ribs. The *deep layer* of the lumbar fascia originates from the transverse processes of the lumbar vertebrae and stretches only between the twelfth rib and the iliac crest and is attached to them above and below. Running laterally the deep layer covers the anterior surface of the erector spinae and on the lateral border of this muscle merges with the superficial layer. The deep autochthonous muscles are thus invested in a closed osteofibrous sheath, with the initial portion of the erector spinae being enclosed in a fibrous sheath.

### VENTRAL MUSCLES OF THE BACK

The ventral musculature of lowest vertebrates stretches uninterruptedly on the abdominal surface of the body. In the higher vertebrates it is differentiated into four regions: cervical, thoracic, abdominal, and caudal.

In man, the abdominal musculature is particularly developed because of his erect posture (see Figs. 124, *b* and 128). The ventral musculature is represented on the neck by muscles attached to the hyoid bone and the scalene and prevertebral muscles, in the thoracic region by the intercostal muscles, the transverse muscle of the thorax, and the diaphragm, and in the abdominal region by the oblique, transverse, and straight muscles of the abdomen and the quadratus muscle of the loins; in the caudal region the ventral musculature is reduced as a result of reduction of the tail.

The trunk autochthonous musculature derived from the ventral processes of the myotomes is monotypical in structure on the whole despite the differentiation according to region. In the fully developed ventral musculature, the lateral part (the broad muscles) usually made up of three layers is distinguished first of all. The medial part (the straight muscles) is seen next; it stretches longitudinally from the pelvis to the head, on each side of the connective-tissue medial septum (*linea alba*). In man, this type of musculature is most conspicuous in the region of the abdomen where the broad lateral (the oblique and transverse abdominal muscles) and the straight middle (the *rectus abdominis*) musculature is well developed; the anterior (straight) muscles are absent in the thoracic region because of the presence of the sternum, but are again encountered on the neck (muscles attached to the hyoid bone).

The lateral musculature is unsegmented in the abdominal region but has retained distinct primary metamerism in the thoracic region owing to the presence of the ribs along the myosepta of the myotomes (intercostal muscles). On the neck, the lateral musculature has transformed into three scalene muscles (*mm. scaleni*). As pointed out above, signs of metamerism (tendinous intersections) persist also in the straight musculature. In addition, some areas of the ventral musculature are displaced to the anterior surface of the spine (prevertebral muscles) or to both sides of it (quadratus muscle of the loins) or even stretch over the dorsal surface of the spine, becoming part of

the musculature of the back (they are described above in the corresponding section).

The prevertebral muscles are developed in the cranial end of the trunk (on the neck). Similar muscles on the caudal end in man served for the formation of the muscular floor of the pelvis (the levator ani muscle and the coccygeal muscles, described in the chapter "Splanchnology"). The ventral musculature includes still another muscle peculiar to mammals. This is the diaphragm, a derivative of the cervical muscles, which descended to the lower end of the thoracic cage, to the border with the abdominal cavity. Finally, newcomer muscles, derivatives of the visceral arches and some of the limb muscles, lie over the autochthonous ventral musculature in places.

## MUSCLES OF THE CHEST

The musculature of the chest is divided into the muscles that originate from the surface of the thoracic cage and stretch from it to the shoulder girdle and upper limb and the muscles proper (autochthonous) of the chest, which are components of the thoracic wall.

1. Chest muscles related to the upper limb: *m. pectoralis major*, *m. pectoralis minor*, *m. subclavius*, *m. serratus anterior*.

The first two are truncopetal and the last two are truncofugal muscles. Innervation is from the branches of the brachial plexus.

2. Autochthonous muscles of the chest: *mm. intercostales externi*, *mm. intercostales interni*, *mm. subcostales* and *m. transversus thoracis*.

Innervation is from the intercostal nerves.

We shall also describe here the diaphragm, which delimits and separates the thoracic cavity from the abdominal cavity. The diaphragm is related to the neck in origin and is therefore innervated mainly from the cervical plexus (phrenic nerve,  $C_{3-5}$ ).

### CHEST MUSCLES RELATED TO THE UPPER LIMB

1. The **pectoralis major muscle** (*m. pectoralis major*) originates from the medial half of the clavicle (*pars clavicularis*), the anterior surface of the sternum and cartilages of the second to seventh ribs (*pars sternocostalis*) and, finally, from the anterior wall of the sheath of the rectus abdominis muscle (*pars abdominalis*). The fibres of the muscle stretch laterally where they converge and are attached by a short tendon to the crista tuberculi majoris of the humerus. The lateral border of the muscle adjoins the border of the deltoid muscle of the arm and is separated from it by a small groove (*sulcus deltoideo-pectoralis*), which widens upward under the clavicle to form a small *infraclavicular fossa*.

**Action.** This muscle draws the arm to the trunk and rotates it medially; the *pars clavicularis* lifts the arm forward. The muscle can raise the ribs with the sternum when the upper limbs are held fast and in this way help inspiration. Innervation:  $C_{5-8}$ . Medial and lateral pectoral nerves.

2. The **pectoralis minor muscle** (*m. pectoralis minor*) is under the greater

pectoral muscle. It *originates* from the second to fifth ribs by means of four slips and is *inserted* into the coracoid process of the scapula (see Fig. 124, b).

*Action.* On contraction this muscle pulls the shoulder blade forward and downward. When the arms are held fast, it acts as a muscle of inspiration. (Innervation C<sub>7-8</sub>. Medial and lateral pectoral nerves.)

3. The **subclavius muscle** (*m. subclavius*) is very small and stretches from the clavicle to the first rib.

*Action.* The muscle strengthens the sternoclavicular articulation by pulling the clavicle down and medially. Innervation: C<sub>5-6</sub>. Subclavius nerve.

4. The **serratus anterior muscle** (*m. serratus anterior*) is on the surface of the lateral chest wall. It usually *arises* by nine slips from the nine upper ribs and is *attached* to the medial border of the scapula. The inferior slips interdigitate with the initial slips of the external oblique muscle of the abdomen found on the lateral surface of the thoracic cage.

*Action.* Together with the rhomboid muscle, which is also attached to the medial border of the scapula, it forms a wide muscular loop embracing the trunk and pressing the scapula to it. Contraction of the whole anterior serratus muscle simultaneously with the muscles of the back (the rhomboid and trapezius muscles) immobilizes the scapula by pulling it forward. The lower end of the muscle rotates anteriorly and laterally the inferior angle of the scapula, as occurs in lifting the limb above the shoulder. The superior slips move the scapula together with the clavicle forward and act as antagonists of the middle fibres of the trapezius muscle. Innervation: C<sub>5-7</sub>. Long thoracic nerve.

#### AUTOCHTHONOUS MUSCLES OF THE CHEST

1. The **external intercostal muscles** (*mm. intercostales externi*) fill the intercostal spaces from the spine to the costal cartilages. They *originate* from the inferior border of each rib, descend posteroanteriorly, and *attach* to the superior border of the contiguous rib above. Between the costal cartilages the muscles are replaced by a fibrous band with fibres lying in the same direction (*membrana intercostalis externa*). Innervation: Th<sub>1-11</sub>. Intercostal nerves.

2. The **internal intercostal muscles** (*mm. intercostales interni*) are under the external muscles, and the direction of their fibres is opposite to that of the fibres of the latter, which they intersect at an angle. *Originating* from the superior border of the contiguous rib below, they ascend anteriorly and *attach* to the contiguous rib above. In contrast to the external muscles, the internal intercostal muscles stretch between the costal cartilages and reach the sternum. Posteriorly, the internal intercostal muscles reach only the costal angles and are further replaced by the *posterior intercostal membrane* (*membrana intercostalis interna*) stretching between the posterior ends of the ribs. Innervation: Th<sub>1-11</sub>. Intercostal nerves.

3. The **subcostal muscles** (*mm. subcostales*) are thin muscular bundles found on the inner surface of the lower part of the thoracic cage in the region of the costal angles. Their fibres are directed like the fibres of the internal

intercostal muscles, but the muscles overlap one or two ribs. Innervation: Th<sub>8-11</sub>. Intercostal nerves.

4. The **transversus thoracis muscle** (*m. transversus thoracis*) is also on the inner surface of the thoracic cage, on its anterior surface, and is a continuation of the transverse muscle of the abdomen. Innervation: Th<sub>3-6</sub>. Intercostal nerves.

*Action.* The external costal muscles raise the ribs and expand the thoracic cage in the anteroposterior and transverse directions and are, consequently, muscles of inspiration during normal quiet breathing. Other muscles also take part in forced respiration; these are muscles capable of raising the ribs (the scalene, sternocleidomastoid, the major and minor pectoral muscles, etc.) provided the mobile points of their attachment in other places are held firmly fixed, as occurs, for instance, instinctively in patients suffering from dyspnoea. Diminution in the capacity of the thorax in expiration is mainly due to the elasticity of the lungs and the thoracic cage itself.

Some authors claim that the internal intercostal muscles also contribute to quiet expiration. The subcostal muscles, the transverse muscle of the thorax, and other muscles which draw the ribs downward (the abdominal muscles) also act in forced expiration.

#### THE THORACOABDOMINAL DIAPHRAGM

The **thoracoabdominal diaphragm** forms the partition between the thoracic and abdominal cavities. It is a flat thin dome-shaped muscle, covered above and below with fasciae and serous membranes (Fig. 127). The muscle fibres arise from the whole circumference of the inferior thoracic aperture, run upwards, and are contiguous with an aponeurotic tendon occupying the centre of the diaphragm and called the **central tendon** (*centrum tendineum*). According to the origin of the fibres, the lumbar, costal, and sternal parts are distinguished in the muscular part of the diaphragm.

The **lumbar part** (*pars lumbalis*) is the strongest and consists of two *crura*, *right* and *left* (*crus dextrum* and *sinistrum*). Both *crura* originate by means of a long tendon from the anterior surface of the bodies of the first to fourth lumbar vertebrae (the left crus arises at a higher level than the right) and from two tendinous ligaments which are thickenings of the thoracolumbar fascia. One of these ligaments, the *medial arcuate ligament* (*lig. arcuatum mediale*) passes above the psoas major muscle and stretches between the body of the first or second lumbar vertebra and its transverse process; the second, *lateral arcuate ligament* (*lig. arcuatum laterale*) runs above the quadratus muscle of the loins from the transverse process of the first lumbar vertebra to the free border of the twelfth rib.

A triangular space (*hiatus aorticus*) is left between both *crura* and the spine; it transmits the aorta and the thoracic duct stretching behind it. The edge of this opening is bordered with a tendinous band as a result of which contraction of the diaphragm does not affect the lumen of the aorta. Ascending, the *crura* converge in front of the aortic hiatus, but somewhat to the left and above it they separate again to form an opening, the *oesophageal*

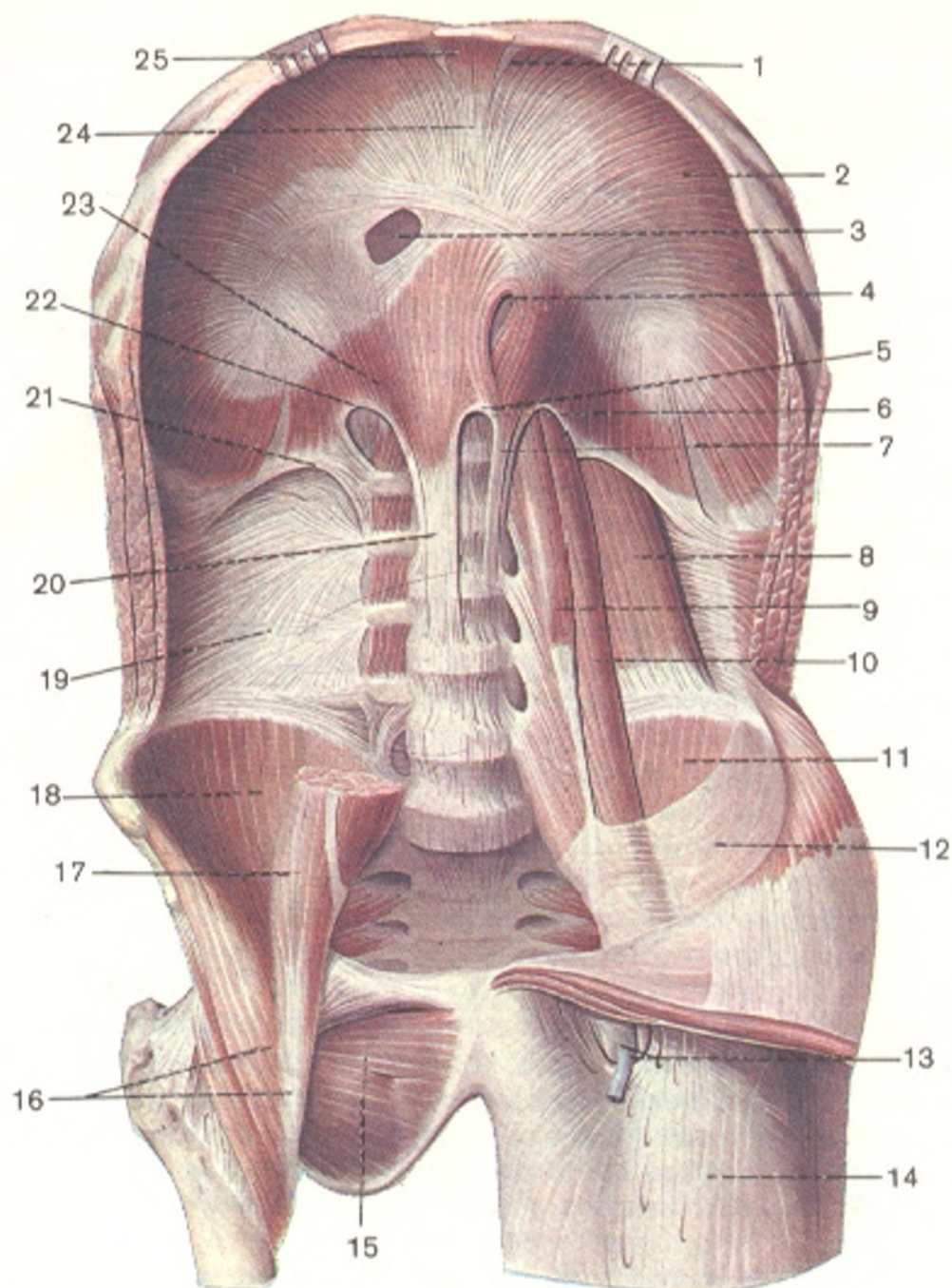


Fig. 127. Diaphragm and muscles of posterior abdominal wall (the quadratus lumborum muscle and part of the psoas major and minor muscles have been removed; after R. D. Sinelnikov).

- |                                  |   |
|----------------------------------|---|
| 1, trigonum sternocostale;       | 14, fascia lata;                                |
| 2, pars costalis diaphragmatis;  | 15, m. obturatorius externus;                   |
| 3, foramen venae cavae;          | 16, m. iliopsoas;                               |
| 4, hiatus esophageus;            | 19, fascia thoracolumbalis (lamina profunda);   |
| 5, hiatus aorticus;              | 20, crus dextrum diaphragmatis;                 |
| 6, crus sinistrum diaphragmatis; | 21, lig. arcuatum laterale;                     |
| 7, trigonum lumbocostale;        | 22, lig. arcuatum mediale;                      |
| 8, m. quadratus lumborum;        | 23, pars lumbalis diaphragmatis (crus dextrum); |
| 9, m. psoas minor;               | 24, centrum tendineum diaphragmatis;            |
| 10 and 17, m. psoas major;       | 25, pars sternalis diaphragmatis                |
| 11 and 18, m. iliacus;           |   |
| 12, fascia iliaca;               |   |
| 13, hiatus saphenus;             |   |



*hiatus (hiatus esophageus)*, through which the oesophagus and both vagus nerves attendant to it pass. The oesophageal hiatus is bordered with muscle bundles which act as a sphincter regulating the movement of food. Narrow openings form between the muscle bundles of each crus. They transmit the splanchnic nerves, the azygos vein (hemiazygos vein on the left), and the sympathetic trunk.

The **costal part** (*pars costalis*) originates by separate slips from the inner surface of the cartilages of the seventh to twelfth ribs; these slips interdigitate with the initial slips of the transversus abdominis muscle and ascend, curving toward the tendinous centre.

The **sternal part** (*pars sternalis*), the smallest of all the parts of the diaphragm, is made up of several short slips arising from the posterior surface of the sternal xiphoid process and stretching to the tendinous centre. A paired triangular opening, the **sternocostal triangle** (*trigonum sternocostale*) is left between the sternal part and the costal part of the diaphragm near the sternum; the internal thoracic artery (superior epigastric artery) passes in it.

Another, larger, paired space, the **lumbocostal triangle** (*trigonum lumbocostale*), lies between the costal and lumbar parts. It corresponds to the communication existing between the thoracic and abdominal cavities in embryonal life. It is covered by the pleura and endothoracic fascia above and by the subperitoneal fascia, retroperitoneal fat and peritoneum below. Diaphragmatic hernias may protrude through it. The posterior surfaces of the kidney and adrenal enclosed in a fatty capsule are contiguous to the lumbocostal triangle. The central tendon of the diaphragm (*centrum tendineum*) has a trifoliate shape. Its surface shines like a mirror, and it was formerly called *Helmont's mirror* or *speculum*. A little to the back and to the right of the midline is a quadrangular opening in the central tendon (*foramen venae cavae*), which transmits the inferior vena cava. As pointed out above, the diaphragm is dome-shaped, but it is asymmetrical in height: its right part, abutting inferiorly on the voluminous liver, stands higher than the left part.

**Action.** During inspiration the diaphragm contracts, its dome flattens out, and its height decreases. With the descent of the diaphragm the thoracic cavity grows larger in the vertical direction, which is what occurs during inspiration. Innervation: C<sub>3-5</sub>. Phrenic nerve, 7th-12th intercostal nerves.

## FASCIAE OF THE CHEST

The anterior surface of the pectoralis major muscle is covered by the **superficial sheet** of the **pectoral fascia** (*fascia pectoralis*), which is continuous medially with the sternal periosteum, superiorly with the clavicular periosteum, and laterally with the deltoid fascia (*fascia deltoidea*). In females this sheet separates the muscle from the mammary gland. Under the pectoralis major muscle is the more conspicuous **deep sheet** of the pectoral fascia; it is thickest in the region of the **clavipectoral triangle** and is known here as the **clavipectoral fascia** (*fascia clavipectoralis*). Separating and then rejoining, the deep sheet of the pectoral fascia encloses the subclavius and lesser pectoral muscles. Both sheets of the pectoral fascia join in two places: in the deltoideo-

pectoral sulcus and at the inferior border of the greater pectoral muscle where the pectoral fascia is continuous with the **axillary fascia** (*fascia axillaris*). This fascia forms the floor of the axillary fossa; from the periphery of the fossa, it spreads to the adjacent muscles, while in the centre it forms a depression with the overlying skin, as the result of which the axilla or armpit is formed. Besides the fasciae covering the external surface of the thoracic cage, here is the **endothoracic fascia** (*fascia endothoracica*) which lines its inner surface and also passes over to the diaphragm as a very thin layer of fat.

## MUSCLES OF THE ABDOMEN

The muscles of the abdomen occupy the space between the inferior circumference of the thoracic cage and the superior border of the pelvis. They surround the abdominal cavity and form its walls.

1. The lateral muscles: the external oblique muscle (*m. obliquus externus abdominis*), the internal oblique muscle (*m. obliquus internus abdominis*), the transversus abdominis muscle (*m. transversus abdominis*).

2. The anterior muscles: the rectus abdominis muscle (*m. rectus abdominis*) and the pyramidalis muscle (*m. pyramidalis*).

3. The posterior muscles: the quadratus lumborum muscle (*m. quadratus lumborum*).

The abdominal muscles are exclusively related to the autochthonous ventral musculature of this region and are innervated by the intercostal nerves (5th to 12th) and the superior branches of the lumbar plexus.

### THE LATERAL MUSCLES

These are three broad muscular sheets, one overlapping the other. Their tendinous aponeuroses, after forming the sheath of the rectus abdominis muscle, join on the anterior aspect of the abdomen at the linea alba (Fig. 128).

1. The **external oblique muscle** (*m. obliquus externus abdominis*) is the outermost of the three broad abdominal muscles. It arises from the lower eight ribs by eight slips on the lateral surface of the thoracic cage; the muscular fibres run downward and forward. The wide surface at the origin of the muscle and the localization that is lower and more caudal than in quadrupeds are due to the increase in the strength of the upper limb musculature which in anthropomorphic apes serves as a means for swinging the body from tree to tree (brachiation), while in humans it is the organ of labour. The need for a greater support for the muscles of the upper limb causes broadening and elongation of the thoracic cage and caudal displacement of the abdominal muscles attached to it, namely, the oblique and rectus abdominis muscles. The fibres of the external oblique muscle act as a continuation of the external intercostal muscles and pass in the same direction, i.e. obliquely downward and forward. This is explained by the gradual disappearance of the ribs in the process of phylogenesis, which caused the intercostal muscles to fuse and form continuous muscular sheets. The posterior slips are inserted into the iliac crest. The other fibres of the muscle are continuous with an extensive

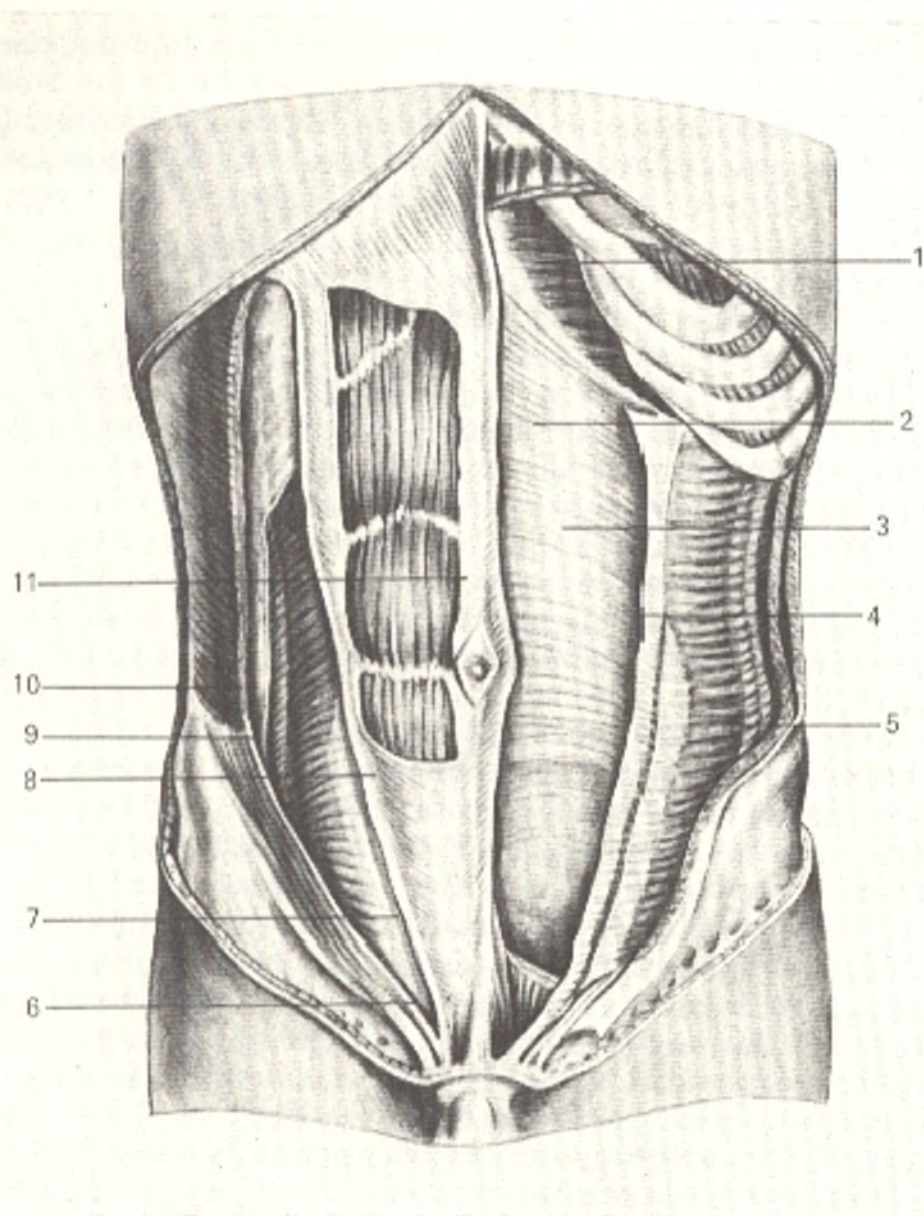


Fig. 128. Muscles of the abdomen.

- |   |   |
|---|---|
| 1, vagina m. recti abdominis (anterior wall); | 7, fascia transversalis;                    |
| 2, m. rectus abdominis;                       | 8, linea arcuata;                           |
| 3, intersectio tendinea;                      | 9, aponeurosis of m. transversus abdominis; |
| 4, m. obliquus int. abdominis;                | 10, m. transversus abdominis;               |
| 5, m. obliquus ext. abdominis;                | 11, linea alba                              |
| 6, m. pyramidalis;                            |   |

aponeurosis, which passes in front of the rectus muscle and joins the contralateral aponeurosis on the midline along the linea alba.

The free inferior border of the aponeurosis of the external oblique muscle spans the gap between the anterior superior iliac spine folding back on itself to form a groove. This border, artificially separated from the rest of the aponeurosis, is called the inguinal or Poupart's ligament (*lig. inguinale Pouparti*). In primates, the inguinal ligament supports the lower abdominal wall and the inguinal canal and is important for erection. In humans it is

simply distinguished as the inferior wall, or floor, of the inguinal canal (see Figs. 123 and 133).

At the medial attachment of the inguinal ligament its fibrous fibres pass backward to the pubic crest and form the **lacunar, or Gimbernat's ligament** (*lig. lacunare Gimbernati*). Above the medial part of the inguinal ligament in the aponeurosis of the external oblique muscle is a triangular cleft, the superficial (subcutaneous) ring of the inguinal canal, *anulus inguinalis superficialis*. It is discussed in detail below. To the back of the posterior border of the fleshy part of the external oblique muscle, between it and the origin of the latissimus dorsi muscle, is a small triangular space, the **lumbar or Petit's triangle** (*trigonum lumbale Petiti*). The floor of the triangle is formed by the internal oblique muscle of the abdomen. The outer surface of the external oblique muscle is covered by a thin sheet of fascia extending over the aponeurosis of the muscle and closely fusing with it. Another superficial fascia, one related to the deep layer of the subcutaneous tissue, is found over this sheet in the hypogastric region; inferiorly it fuses with the inguinal ligament. Innervation: Th<sub>5-12</sub> and L<sub>1</sub>. Intercostal, iliohypogastric, and ilioinguinal nerves.

2. The **internal oblique muscle of the abdomen** (*m. obliquus internus abdominis*) is found under the external oblique muscle. It *arises* posteriorly from the thoracolumbar fascia, then from the iliac crest, and from the lateral two thirds of the inguinal ligament. Its fibres run on the whole, upward, or, to be more precise, they fan out. The posterior muscular bundles ascend and *attach* to the inferior margins of the twelfth, eleventh, and tenth ribs. The internal intercostal muscles are their extensions between the ribs. The anterior bundles of the muscle are continuous with a broad aponeurosis which on the lateral border of the rectus abdominis muscle splits into two layers contributing to the formation of the sheath of this muscle (see below). The aponeurosis meets the contralateral aponeurosis medially to the rectus muscle, on the linea alba. On the outer and inner surfaces the internal oblique muscle is covered with fascial laminae. Innervation, Th<sub>5-7</sub> and L<sub>1</sub>. The 10th-12th intercostal, iliohypogastric, and ilioinguinal nerves.

3. The **transversus abdominis muscle** (*m. transversus abdominis*) is the deepest and thinnest of the broad abdominal muscles. It *arises* from the inner surface of the lower six ribs. Above the diaphragm, it extends as the transverse muscle of the thorax. Inferiorly and posteriorly the muscle originates from the deep layer of the thoracolumbar fascia, and, finally, its lowest part arises from the iliac crest and the lateral two-thirds of the inguinal ligament. From the sites of origin the fibres of the muscle run horizontally forward and medially and end in a wide aponeurosis, which passes to linea alba behind the rectus abdominis in the upper part and in front of this muscle in the lower part. In many mammals this muscle is strongly developed and can pull the testis from the scrotum into the body cavity. In human beings, the internal oblique and the transversus abdominis muscles give rise to only a small muscular bundle, a rudimentary muscle raising the testis, *m. cremaster*. On the inner surface facing the abdominal cavity, the transversus abdominis is covered with the fascia transversalis, which is part of the common subperito-

neal fascia (*fascia subperitonealis*). The latter lines the whole inner surface of the abdominal walls and in places is named according to the localization: fascia transversalis, fascia iliaca, fascia pelvis, etc. Innervation: Th<sub>5-12</sub> and L<sub>1</sub>. The 5th-12th intercostal, iliohypogastric, and ilioinguinal nerves.

#### THE ANTERIOR MUSCLES

1. The **rectus abdominis muscle** (*m. rectus abdominis*) stretches on both sides lateral of the midline and consists of longitudinal muscle bundles running vertically (see Fig. 128). It arises from the anterior surface of the fifth, sixth and seventh costal cartilages and from the xiphoid process of the sternum and then, becoming gradually narrower, stretches downward and is attached by a strong tendon to the pubic bone between the symphysis and the pubic tubercle. In man the rectus abdominis muscle originates at a lower level than in animals. This is explained by the broadening of the chest in anthropoid apes and human beings. Along its length the muscle is interrupted by transverse (three or four) *tendinous intersections* (*intersectiones tendineae*), which fuse with the anterior wall of the sheath in which the rectus abdominis is enclosed. The tendinous intersections are traces of the former segmental development of the ventral musculature. They also possess functional significance: by separating the muscle into segments, they allow each muscle segment to contract independently. This process, however, demands special training (e.g. by circus actors). Innervation: Th<sub>5-12</sub> and L<sub>1</sub>. Intercostal nerves.

2. The **pyramidalis muscle** (*m. pyramidalis*) is a small triangular muscle under the anterior wall of the sheath of the rectus abdominis, above the symphysis pubis. It is attached to the linea alba, which it tenses on contraction. This is a rudiment of a muscle that in monotremes and marsupials surrounds the pouch in which they carry their young. Innervation: Th<sub>12</sub> and L<sub>1</sub>. The subcostal, iliohypogastric, and ilioinguinal nerves.

The **sheath of the rectus abdominis muscle** (Fig. 128, 129, 130, and 131). Each rectus abdominis muscle is enclosed in a **sheath** (*vagina m. recti abdominis*) formed by the aponeuroses of the three lateral abdominal muscles. In the upper part, above the umbilicus, the sheath is so formed that the aponeurosis of the external oblique muscle passes in front of the rectus muscle, while the aponeurosis of the transversus abdominis muscle passes behind it; the aponeurosis of the internal oblique muscle splits into two laminae, which encompass the rectus muscle anteriorly and posteriorly, fuse with the aponeuroses of the external oblique and transverse muscles, and with them form the anterior and posterior walls of the sheath. In the lower part, 4-5 cm below the umbilicus, the structure of the sheath is different: the aponeuroses of the three abdominal muscles pass in front of the rectus muscle as the anterior wall of its sheath, while the posterior wall is replaced by fascia transversalis that lines the inner surface of the abdominal wall. The posterior aponeurotic wall of the sheath terminates here as a rather sharp crescentic margin called the **arcuate line** (*linea arcuata*). The absence of the posterior wall of the sheath facilitates the filling of the urinary bladder, which, on rising above the edge of the symphysis pubis, is displaced to this site. The thickening of the anteri-

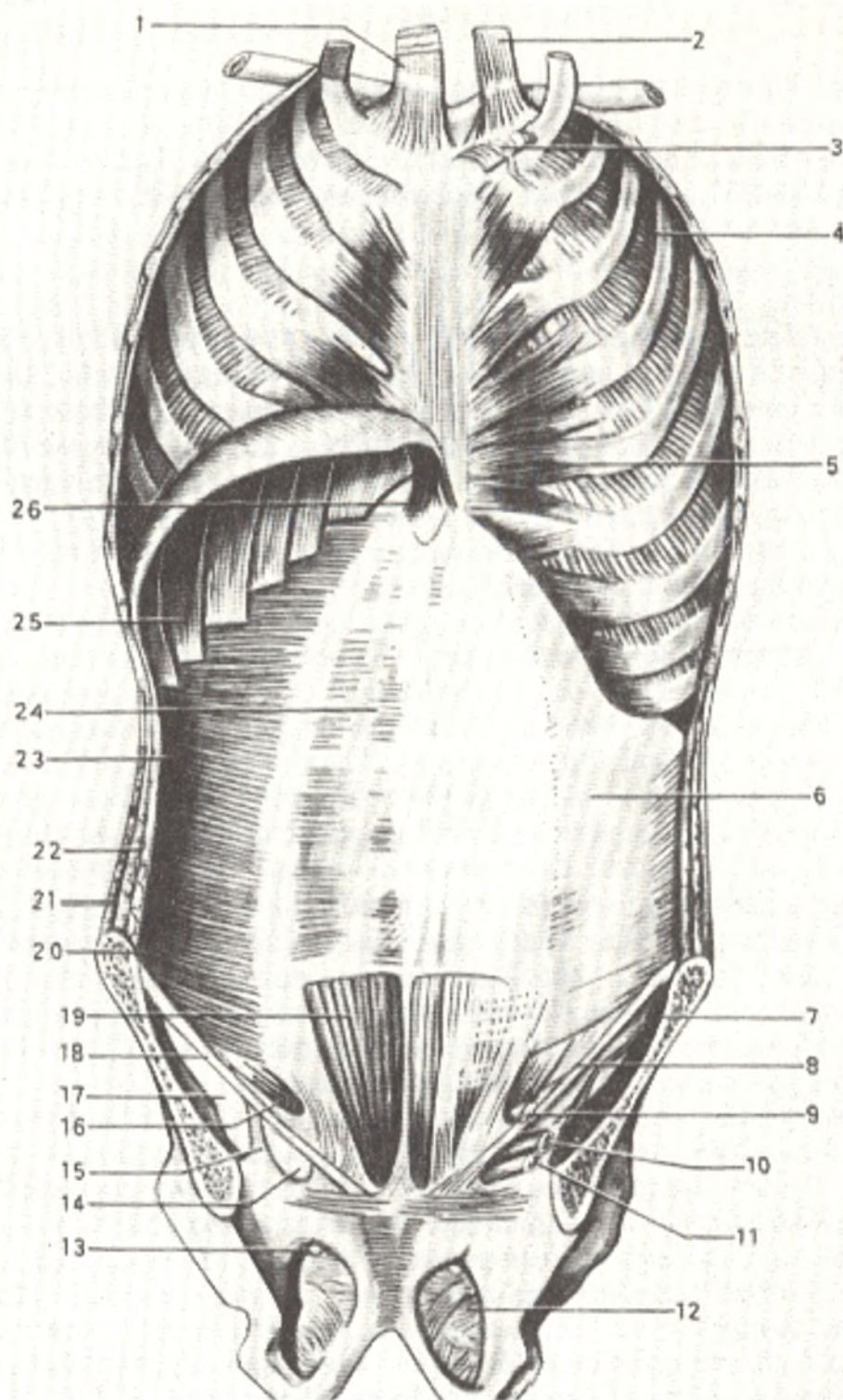


Fig. 129. Muscles and fasciae of the trunk (inner aspect of the thoracic and abdominal wall; after Sinelnikov).

1, 2, and 3, neck muscles;  
 4, mm. intercostales interni;  
 5, m. transversus thoracis;  
 6, fascia transversalis;  
 7, m. iliacus;  
 8, anulus inguinalis profundus;  
 9, funiculus spermaticus;  
 10, a. iliaca externa;  
 11, v. iliaca externa;  
 12, membrana obturatoria;  
 13, canalis obturatorius;  
 14, lacuna vasorum;  
 15, arcus iliopectineus;

16, m. cremaster;  
 17, lacuna musculorum;  
 18, lig. inguinale;  
 19, m. rectus abdominis;  
 20, m. transversus abdominis;  
 21, m. obliquus externus abdominis;  
 22, m. obliquus internus abdominis;  
 23, m. transversus abdominis;  
 24, vagina m. recti abdominis (posterior wall);  
 25, diaphragma (pars costalis);  
 26, diaphragma (pars sternalis)

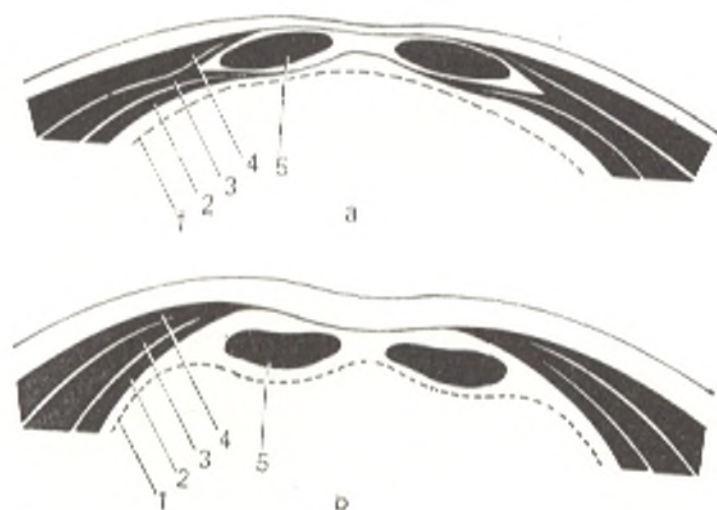


Fig. 130. Schematical representation of horizontal section through the sheath of the rectus abdominis muscle.

- |                                      |  |
|--------------------------------------|--|
| a, above the umbilicus;              | 3, internal oblique muscle of the abdomen; |
| b, below the umbilicus;              | 4, external oblique muscle of the abdomen; |
| 1, transverse fascia of the abdomen; | 5, rectus abdominis muscle                 |
| 2, transverse muscle of the abdomen; |  |

or wall of the lower part of the sheath is associated with the upright position of the human body, in which the lower part of the abdominal wall experiences the most pressure.

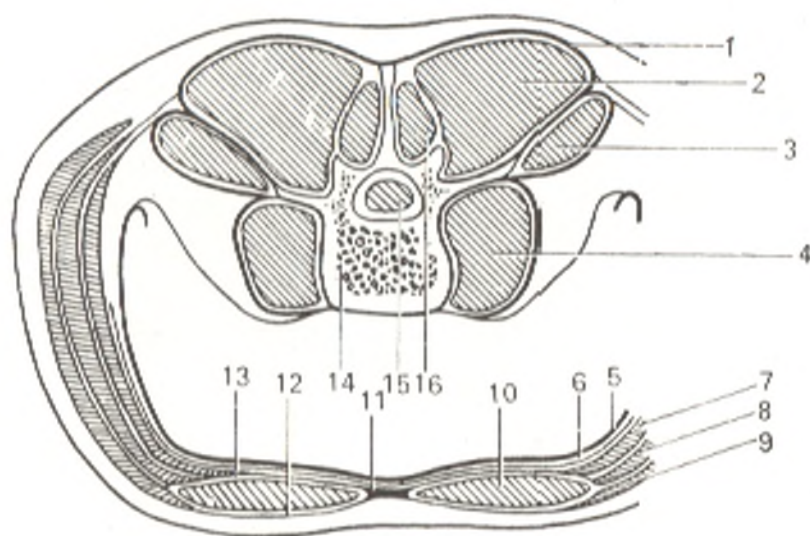


Fig. 131. Schematical representation of muscular and fascial layers of the wall of the trunk; transverse section through the lumbar part (after Ivanov).

- |  |   |
|--|---|
| 1, fascia thoracolumbalis (posterior layer); | 9, m. obliquus externus abdominis;                  |
| 2, m. erector spinae;                        | 10, m. rectus abdominis;                            |
| 3, m. quadratus lumborum;                    | 11, linea alba;                                     |
| 4, m. psoas major;                           | 12, anterior wall of sheath of m. rectus abdominis; |
| 5, peritoneum;                               | 13, posterior wall of sheath;                       |
| 6, fascia transversalis;                     | 14, corpus vertebrae;                               |
| 7, m. transversus abdominis;                 | 15, spinal cord;                                    |
| 8, m. obliquus internus abdominis;           | 16, m. multifidus                                   |

**Linea alba.** The aponeuroses of the broad muscles of the abdomen meet and fuse on the midline and form a tendinous band, **linea alba**, between the rectus abdominis muscles. This line stretches from the sternal xiphoid process to the symphysis pubis. It is quite wide in the upper part (2.0-2.5 cm at the level of the umbilicus), narrows quickly at some distance below the umbilicus, and to compensate thickens in the anteroposterior direction. Almost in the middle of the linea alba is the *umbilical ring* (*anulus umbilicalis*) filled with cicatricial tissue, which fuses with the skin of the umbilicus. The light colour of the linea alba is due to the decussation of the tendinous fibres in the frontal plane (in passing from one side to the other) and sagittal plane (in passing from the surface to greater depth) and its poverty of vessels. Surgeons make use of this circumstance when the abdominal cavity must be opened widely during operation (e.g. in caesarian section).

*Action of the abdominal muscles.* The muscles of the abdomen narrow the abdominal cavity and exert pressure on the viscera enclosed in it, thus forming the abdominal press (*prelum abdominale*), whose action is manifested in expelling the contents of the abdominal organs in defaecation, micturition and labour, as well as in coughing and vomiting. The diaphragm also takes part in this action; it contracts in deep inspiration, and its flattened part presses downward on the abdominal viscera, which are supported by the pelvic diaphragm. The tonus of the *prelum abdominale* muscles keeps the viscera in position, while the musculoaponeurotic wall of the abdomen acts as a support for the abdominal girdle. The abdominal muscles also flex the spine and trunk forward and are antagonists of the muscles that extend the spine. Flexion is accomplished by the rectus abdominis muscles which bring the chest and pelvis closer together, as well as by the oblique muscles in bilateral contraction. In unilateral contraction, the abdominal muscles and the erector spinae muscle bend the trunk laterally. The oblique muscles of the abdomen take part in rotating the spine with the chest. The internal oblique muscle contracts on the side to which the trunk is rotated, while the external oblique muscle contracts on the contralateral side. Finally, the abdominal muscles also assist in respiratory excursions; since they are attached to the ribs, they pull them downward and help in expiration. Their participation in this act consists also in exerting pressure on the viscera and thus raising the relaxed diaphragm to the position it holds in expiration.

#### THE POSTERIOR MUSCLES

The **quadrate muscle of the loins** (*m. quadratus lumborum*) is a quadrangular muscular plate located in front of erector spinae muscle and separated from it by the deep layer of the thoracolumbar fascia. It *arises* from the iliac crest and iliolumbar ligament and is *attached* to the 12th rib and the transverse processes of the first to fourth lumbar vertebrae (see Figs. 127 and 131).

*Action.* In unilateral contraction with the other abdominal muscles and the erector spinae muscle, the quadratus lumborum muscle flexes the spine and the chest laterally. In bilateral tonic contraction with the same muscles,



it holds the spine in a vertical position. It can also act as a respiratory muscle by drawing the 12th rib downward. Innervation: Th<sub>12</sub> and L<sub>1-3</sub>. The lumbar plexus.

### THE INGUINAL CANAL

The inguinal canal (*canalis inguinalis*) is a passage transmitting the spermatic cord (funiculus spermaticus) in the male and the round ligament of the uterus in the female (these organs are discussed in detail in the chapter "Splanchnology"). The inguinal canal (Figs. 132 and 133) is located in the lower part of the abdominal wall, on each side of the abdomen, immediately above Poupart's ligament, and descends medially and forward. The canal

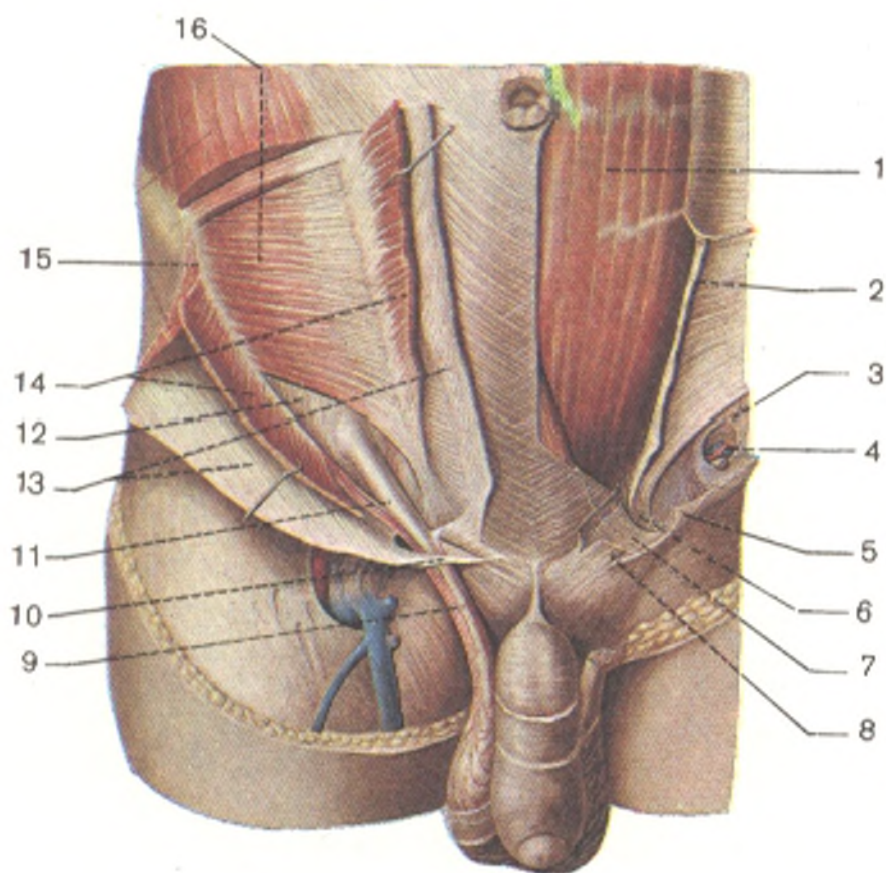


Fig. 132. Inguinal canal (anterior aspect).

Right: the external and internal oblique muscles of the abdomen are divided and reflected; the walls of the deep (abdominal) ring of the inguinal canal, anulus profundus (abdominalis) canalis inguinalis, are seen.

Left: the spermatic cord is removed; the deep ring of the inguinal canal is seen.

1, m. rectus abdominis;  
2, vagina m. recti abdominis (lamina anterior is divided and reflected);  
3, anulus inguinalis (abdominalis) profundus;  
4, funiculus spermaticus (divided);  
5, crus laterale (reflected);

6, falx aponeurotica;  
7, aponeurosis of m. obliqui externi abdominis (divided and reflected);  
8, crus mediale (reflected);  
9, funiculus spermaticus;  
10, crus mediale;  
11, m. cremaster;  
12, fascia transversalis;  
13, aponeurosis of m. obliqui externi abdominis (divided and reflected);  
14, m. obliquus internus abdominis (divided and reflected);  
15, m. obliquus externus abdominis (divided and reflected);  
16, m. transversus

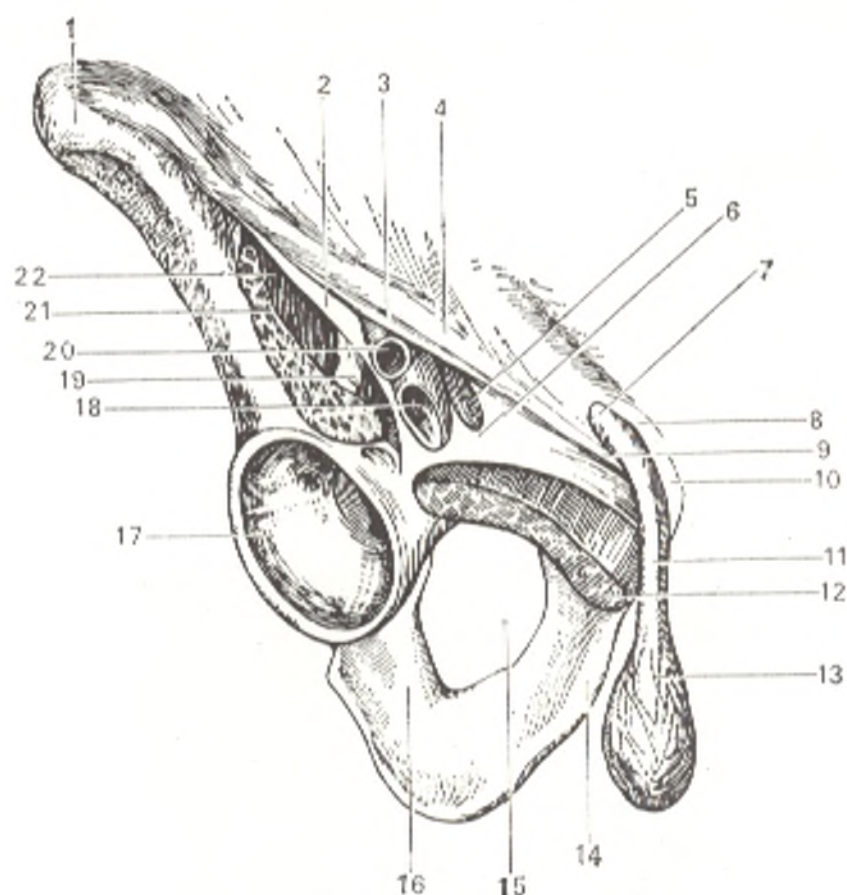


Fig. 133. Lacuna vasorum and lacuna musculorum, right inguinal region (anterior aspect).

- 1, spina iliaca anterior superior;  
 2, arcus iliopectineus;  
 3, fascia lata (cut off);  
 4, lig. inguinale;  
 5, anulus femoralis;  
 6, lig. lacunare;  
 7, anulus inguinalis superficialis;  
 8, crus mediale;  
 9, crus laterale;  
 10, tuberculum pubicum;  
 11, funiculus spermaticus;

- 12, m. pectineus (cut off);  
 13, m. cremaster;  
 14, ramus inferior ossis pubis;  
 15, foramen obturatum;  
 16, corpus ossis ischii;  
 17, acetabulum;  
 18, v. femoralis;  
 19, n. femoralis;  
 20, a. femoralis;  
 21, m. iliopsoas;  
 22, lacuna musculorum

is 4.5 cm long. It forms as follows: the internal oblique and the transversus abdominis muscles are fused with the lateral two thirds of the groove of the inguinal ligament (but not with the medial one third of the ligament) and pass freely over the spermatic cord or the round ligament. Thus, a triangular or oval passage forms between the inferior border of the internal oblique and the transverse muscles above and the medial part of the inguinal ligament below. *This passage is the inguinal canal.* The inferior border of the internal oblique and transverse muscles, overhanging the spermatic cord, gives rise to a bundle of muscle fibres, which accompanies the cord into the scrotum; this is the cremaster muscle (the muscle raising the testis).

The inguinal canal is closed anteriorly by the aponeurosis of the external oblique muscle of the abdomen, which is continuous below with the ingui-

nal ligament; posteriorly it is closed by the transversalis fascia. Thus, four walls can be distinguished in the inguinal canal. The **anterior wall** is formed by the aponeurosis of the external oblique muscle, the **posterior wall** by the transversalis fascia. The **superior wall**, or roof, is formed by the inferior border of the internal oblique and transverse muscles, and the **inferior wall**, or floor, is formed by the inguinal ligament. The anterior and posterior walls each have an opening, called the inguinal ring, the superficial ring, and the deep ring, respectively. The inguinal canal transmits the spermatic cord from the scrotum into the abdominal cavity. Since the deep inguinal ring is found laterally, to the back, and a little above the superficial ring, the inguinal canal stretches obliquely, as mentioned above, i.e. forward, downward, and medially.

The **superficial inguinal ring** (*anulus inguinalis superficialis*) (in the anterior wall), is formed by the separation of the fibres of the aponeurosis of the external oblique muscle into two crura, one of which (*crus laterale*) is attached to the tuberculum pubicum, and the other (*crus mediale*) to the symphysis pubis. Besides these two crura, a third (posterior) crus of the superficial ring is described (*ligamentum reflexum*) located within the inguinal canal itself behind the spermatic cord. This crus is formed by the inferior fibres of the aponeurosis of the contralateral external oblique muscle; these fibres cross the midline, pass behind the crus mediale, and fuse with the fibres of the inguinal ligament. The superficial inguinal ring demarcated by the medial and lateral crura is an oblique triangular slit. The sharp lateral angle of the slit is rounded by arcuate tendinous fibres (*fibrae intercrurales*) originating from the fascia that covers the external oblique muscle. This fascia also descends from the edges of the superficial inguinal ring onto the spermatic cord as a thin film and accompanies the cord into the scrotum as fascia cremasterica.

The **deep inguinal ring** (*anulus inguinalis profundus*) is in the posterior wall of the inguinal canal formed by the fascia transversalis extending from the margins of the ring to the spermatic cord and forming a membrane (*fascia spermatica interna*), which encloses the cord together with the testis. The medial margin of the deep inguinal ring is strengthened by a bundle of arch-shaped fibres, the *interfoveolar ligament* (*ligamentum interfoveolare*). In addition, the posterior wall of the inguinal canal is reinforced in the medial part by tendinous fibres arising from the aponeurosis of the transversus abdominis muscle and descending along the border of the rectus abdominis to the inguinal ligament. This is the *inguinal falx* (*falx inguinalis*). Between these two strengthened areas is a weaker part of the posterior wall of the inguinal canal. The peritoneum covering this wall forms two inguinal fossae (*fossae inguinale*) separated from each other by two vertical folds of the peritoneum, called umbilical folds. These are as follows: a **lateral fold** (*plica umbilicalis lateralis*), a fold of peritoneum elevated by the underlying inferior epigastric artery; a **medial fold** (*plica umbilicalis medialis*) containing the medial umbilical ligament, i.e. the obliterated umbilical artery of the embryo; and a **median fold** (*plica umbilicalis mediana*) covering the median umbilical ligament, the obliterated urachus of the embryo.

The **lateral inguinal fossa** (*fossa inguinalis lateralis*) located laterally of the lateral umbilical fold corresponds to the deep inguinal ring; the **medial fossa** (*fossa inguinalis medialis*) located between the lateral and medial umbilical folds corresponds to the weaker part of the posterior wall of the inguinal canal and is situated exactly opposite the superficial inguinal ring. Inguinal hernia may emerge into the inguinal canal through the fossae described and form a protrusion on the abdominal wall. A lateral (external) oblique inguinal hernia protrudes through the lateral fossa; a medial (internal) direct hernia emerges through the medial fossa. The origin of the inguinal canal is linked with the descent of the testis, descensus testis, and the formation of the peritoneal processus vaginalis in embryonic life (discussed in the chapter "Splanchnology"). The fossa nearest the midline, the *supravesical fossa* (*fossa supravesicalis*) situated between the medial and median umbilical folds, is in no direct relation to the posterior wall of the canal, and most of it is located behind the rectus abdominis.

### MUSCLES OF THE NECK

The group of cervical muscles includes muscles of different origin.

1. Derivatives of the visceral arches: (a) derivatives of the first visceral arch: m. mylohyoideus, venter anterior m. digastrici. Innervation: n. trigeminus; (b) derivatives of the second visceral arch: m. stylohyoideus, venter posterior m. digastrici, platysma. Innervation: n. facialis; (c) derivatives of the branchial arches: m. sternocleidomastoideus. Innervation: n. accessorius and plexus cervicalis.

2. Autochthonous muscles of the neck: (a) anterior muscles: m. sternohyoideus, m. sternothyroideus, m. thyrohyoideus, and m. omohyoideus, as well as m. geniohyoideus; (b) lateral muscles: mm. scaleni anterior, medius and posterior; (c) prevertebral muscles: m. longus colli, m. longus capitis and m. rectus capitis anterior.

The autochthonous cervical muscles are rudiments of the ventral musculature on whose distribution two important circumstances had an effect: reduction of the ribs and reduction of the body cavity. As a result some of the autochthonous muscles of the neck disappeared in man, and only the scalene, vertebral, and geniohyoid muscles remained. According to their development, they are innervated by the anterior branches of the cervical spinal nerves.

The muscles located below the hyoid bone are connected with the sublingual apparatus and innervated from the ansa cervicalis.

Topographically, the muscles of the neck are grouped as follows.

1. Superficial muscles (platysma, m. sternocleidomastoideus).

2. Medial muscles, or muscles of the hyoid bone: (a) muscles located above the hyoid bone (mm. mylohyoideus, digastricus, stylohyoideus, geniohyoideus); (b) muscles located below the hyoid bone (mm. sternohyoideus, sternothyroideus, thyrohyoideus, omohyoideus).

3. Deep muscles: (a) lateral, attached to the ribs (mm. scaleni anterior, medius and posterior); (c) prevertebral muscles (m. longus colli, m. longus capitis, m. rectus capitis anterior and lateralis).

SUPERFICIAL MUSCLES—DERIVATIVES OF THE  
VISCERAL ARCHES

1. **Platysma** is a subcutaneous muscle of the neck (Fig. 134) lying directly under the fascia as a thin sheet. It *arises* on the level of the second rib from the pectoral and deltoid fascia, runs upward over the clavicle, and then *attaches* to the edge of the mandible and the parotid and masseteric fascia and is partly continuous with the muscles of the mouth. A triangular space not covered with the muscle remains on the midline. Innervation: n. facialis.

*Action.* Pulling the skin of the neck, the muscle protects the subcutaneous veins from compression; it can also depress the angle of the mouth, which is important for facial expression.

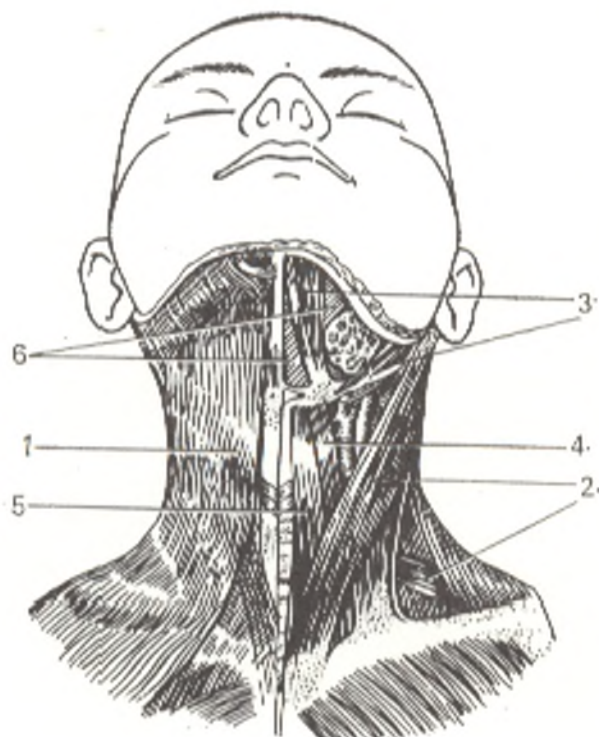
2. The **sternocleidomastoid muscle** (*m. sternocleidomastoideus*) lies immediately under the platysma and is separated from it by the cervical fascia. It *originates* from the sternal manubrium and the sternal end of the clavicle. Both heads fuse proximally, and the muscle is *attached* to the mastoid process and linea nuchae superior of the occipital bone. This muscle originated as part of the trapezius muscle, and it, therefore, has innervation in common with the trapezius (n. accesorius and C<sub>2</sub>).

*Action.* In unilateral contraction, the muscle flexes the cervical segment of the spine to the same side; the head is raised at the same time, and the face turned to the opposite side.

In bilateral contraction, the muscles hold the head in a vertical position (head-holder); that is why the muscle itself and the place of its attachment (the mastoid process) are most developed in man, who walks erect.

Fig. 134. Muscles of the neck (mm. colli), anterior aspect (superficial muscles; anterolateral group).

- 1, m. platysma;
- 2, m. sternocleidomastoideus;
- 3, m. digastricus (venter anterior and posterior);
- 4, m. omohyoideus (venter superior and inferior);
- 5, m. sternohyoideus;
- 6, m. mylohyoideus.



Bilateral contraction may also bend the cervical spine forward and simultaneously raise the face. When the head is fixed, the muscle can raise the chest in respiration (an accessory muscle of inspiration).

#### THE MIDDLE MUSCLES, OR MUSCLES OF THE HYOID BONE

##### Muscles Located above the Hyoid Bone— Derivatives of the Visceral Arches

These muscles of suprahyoid localization lie between the mandible and the hyoid bone (Fig. 135).

1. The **mylohyoid muscle** (*m. mylohyoideus*) is a flat muscle with parallel fibres that arise from the mandibular mylohyoid line, run medially, and terminate on the tendinous line, *raphe*, stretching from the inner surface of the chin to the body of the hyoid bone on the midline along the border between both mylohyoid muscles. The posterior part of the muscle is attached to the body of the hyoid bone. Both mylohyoid muscles meet and form the floor of the mouth (*diaphragma oris*) which closes the bottom of the oral cavity.

2. The **digastric muscle** (*m. digastricus*) consists of two bellies connected by a round intermediate tendon. The whole muscle is shaped like an arch concave upwards. The anterior belly, venter anterior, located on the inferior

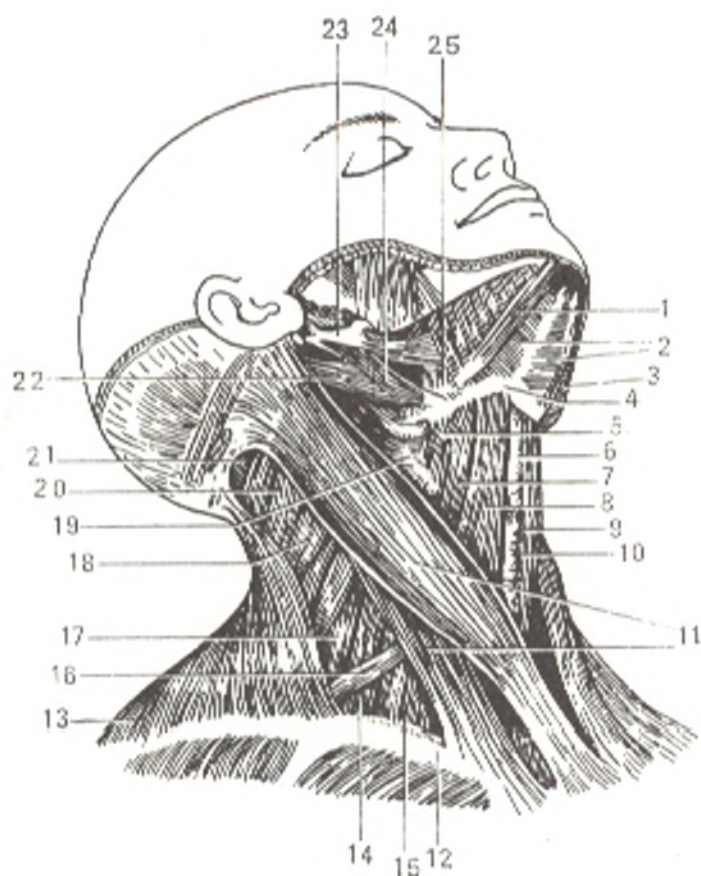


Fig. 135. Muscles of the neck (lateral aspect).

- 1 and 3, *m. digastricus* (venter anterior);
- 2, *m. mylohyoideus*;
- 4, *os hyoideum*;
- 5, *m. thyrohyoideus*;
- 6, *cartilago thyroidea*;
- 7, *m. omohyoideus* (venter superior);
- 8, *m. sternohyoideus*;
- 9, *m. cricothyroideus*;
- 10, *glandula thyroidea*;
- 11, *m. sternocleidomastoideus*;
- 12, *clavicula*;
- 13, *m. trapezius*;
- 14, *m. scalenus anterior*;
- 15, *m. scalenus medius*;
- 16, *m. omohyoideus* (venter interior);
- 17, *m. scalenus posterior*;
- 18, *m. levator scapulae*;
- 19, muscles of the pharynx;
- 20, *m. splenius capitis*;
- 21, *m. semispinalis*;
- 22, *m. digastricus* (venter posterior);
- 23, *processus styloideus*;
- 24, *m. stylohyoideus*;
- 25, *m. hyoglossus*

surface of the oral diaphragm, *arises* in the digastric fossa of the mandible and runs back and laterally to the hyoid bone. The posterior belly, venter posterior, *arises* in the mastoid notch of the temporal bone and descends obliquely forward and medially, gradually narrowing, to the tendon by means of which it is joined to the anterior belly. The intermediate tendon is *attached* to the body and greater horn of the hyoid bone by a fascial loop.

3. The **stylohyoid muscle** (*m. stylohyoideus*) descends obliquely from the styloid process of the temporal bone to the body of the hyoid bone and embraces the intermediate tendon of the digastric muscle with two slips.

4. The **geniohyoid muscle** (*m. geniohyoideus*) lies above the mylohyoid muscle laterally of the raphe. It stretches from the spina mentalis of the mandible to the body of the hyoid bone. It is a derivative of the anterior longitudinal muscle of the trunk.

*Action.* All the four muscles described above raise the hyoid bone. When the bone is steadied, three muscles (mylohyoid, geniohyoid, and digastric) lower the mandible and thus are antagonists of the muscles of mastication. The hyoid bone is steadied by muscles lying below it (sternohyoid, omohyoid, etc.). Without this steadying the mandible cannot be lowered since the hyoid bone, which is lighter and more mobile than the mandible, will be raised. The same three muscles, the mylohyoid in particular, on contraction during swallowing raise the tongue and press it to the palate, as a result of which food is pushed into the pharynx.

Muscles situated above the hyoid bone are components of a complex apparatus including the mandible, hyoid bone, larynx, and trachea. This apparatus plays an important role in the act of articulate speech. Since articulate speech developed under the influence of labour as a means of communication between people, these muscles changed morphologically during the evolution of man. The changes were associated, on the one hand, with the reduced grasping activity of the jaws, which became the function of the hands, and, on the other hand, with the appearance of articulation movements. On comparing the skulls of a Neanderthal man with the skull of modern man, it can, therefore, be seen that the sites of attachment of the corresponding muscles have altered as follows:

(a) the site of attachment of the posterior belly of the digastric muscle, the mastoid notch, was flat in the Neanderthal man but became deep in modern man;

(b) the site of attachment of the anterior belly of this muscle, the digastric fossa, has moved medially in modern man;

(c) the site of attachment of the mylohyoid muscle, the mylohyoid line, is more conspicuous and lower, as a result of which the oral diaphragm is situated lower in modern man;

(d) the site of attachment of the geniohyoid muscle, the mental spine, was hardly present in the Neanderthal man and occurs only in modern man in whom the mental protuberance has also appeared. These changes in the bones occurred with the development of the muscles that take part in the act of articulate speech, inherent only to man.

### Muscles Located below the Hyoid Bone — Derivatives of the Anterior Longitudinal Trunk Muscle

These muscles of infrahyoid localization are related to the system of the straight muscles of the neck and are situated on both sides of the midline directly under the skin, in front of the larynx, trachea, and thyroid gland. They stretch between the hyoid bone and the sternum. An exception is the omohyoid muscle which extends to the scapula and in origin is a muscle displaced from the trunk to the shoulder girdle (truncofugal) (see Fig. 135).

1. The **sternohyoid muscle** (*m. sternohyoideus*) originates from the posterior surface of the sternal manubrium, sternoclavicular joint, and the sternal end on the clavicle, runs upward as a flat band, joins its contralateral fellow, and attaches to the inferior edge of the hyoid bone. Between the medial borders of both sternohyoid muscles is a narrow vertical space closed by fascia; this is the *linea alba cervicalis*.

*Action.* Pulls the hyoid bone downward. Innervation: C<sub>1-3</sub>.

2. The **sternothyroid muscle** (*m. sternothyroideus*) lies under the sternohyoid muscle and is broader. It arises from the posterior surface of the manubrium sterni and the cartilage of the first rib; its medial border touches that of its fellow. It then ascends and attaches to the lateral surface of the thyroid cartilage (to its *linea obliqua*).

*Action.* Lowers the larynx. Innervation: C<sub>1-3</sub>.

3. The **thyrohyoid muscle** (*m. thyrohyoideus*) seems to be a continuation of the sternothyroid muscle from which it is separated by a tendinous intersection. It stretches from the oblique line of the thyroid cartilage to the body and greater horn of the hyoid bone.

*Action.* Pulls the larynx upwards when the hyoid bone is steadied. Innervation: C<sub>1-3</sub>.

4. The **omohyoid muscle** (*m. omohyoideus*) is a long narrow muscle consisting of two bellies joined almost at a right angle by an intermediate tendon. The inferior belly arises medially of the scapular notch, overlaps the spatium antescalenum under cover of sternocleidomastoid muscle where it joins the superior belly by means of the intermediate tendon; the superior belly rises almost perpendicular and is attached to the body of the hyoid bone.

*Action.* The omohyoid muscle lies in the thickness of the cervical fascia which it tightens on contraction and thus aids in dilation of the large veins situated under the fascia. It also pulls the hyoid bone downwards. Innervation: C<sub>1-3</sub>.

#### THE DEEP MUSCLES

##### Lateral Muscles Attached to the Ribs, the Scalene Muscles

The three scalene muscles are altered intercostal muscles, which explains their attachment to the ribs (Fig. 136).



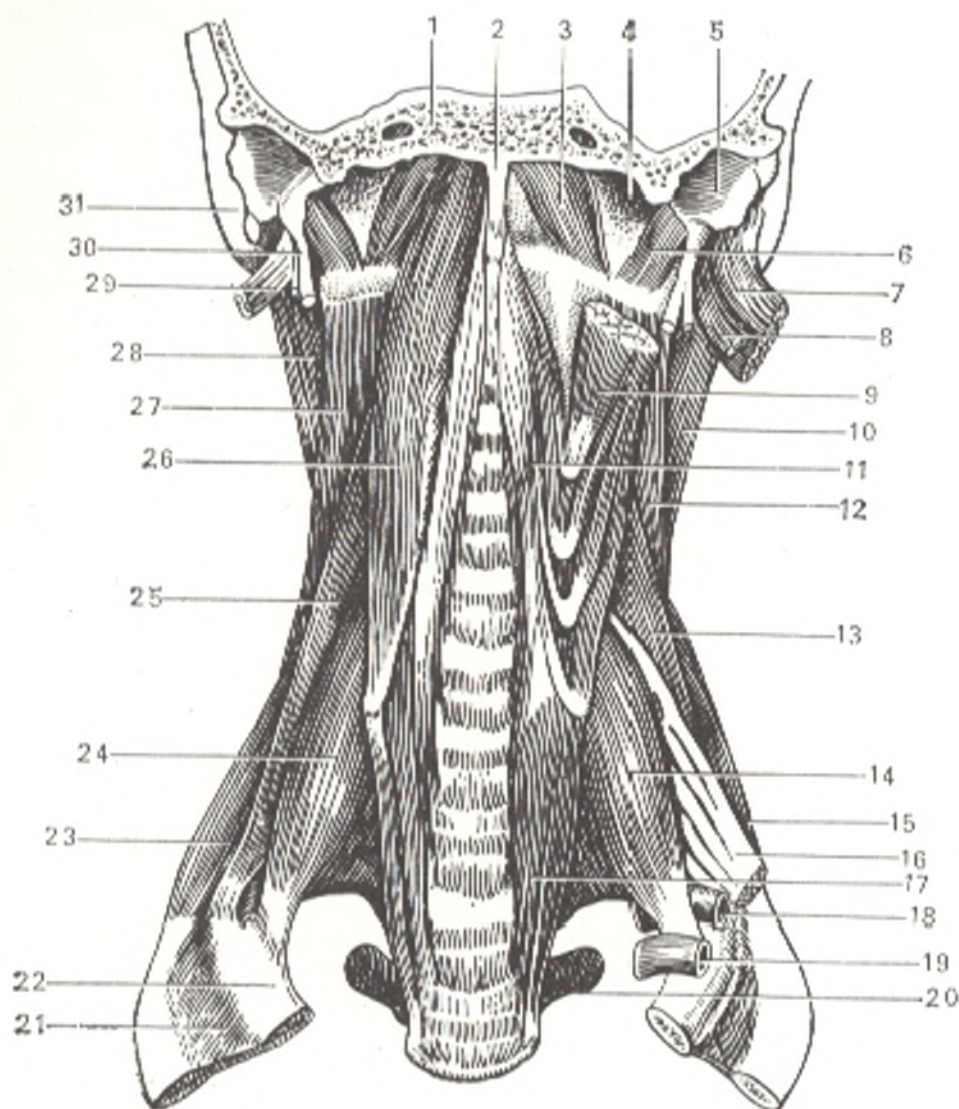


Fig. 136. Deep (prevertebral) muscles of the neck.

- |   |  |
|---|--|
| 1, pars basilaris ossis occipitalis;            | 16, brachial plexus;                             |
| 2, tuberculum pharyngeum;                       | 18, subclavian artery;                           |
| 3, m. rectus capitis anterior;                  | 19, subclavian vein;                             |
| 4, fossa jugularis;                             | 20, processus transversus;                       |
| 5, pars tympanica ossis temporalis;             | 21, rnm. intercostales externi;                  |
| 6, m. rectus capitis lateralis;                 | 22, first rib;                                   |
| 7, m. sternocleidomastoideus (divided);         | 23, m. scalenus posterior;                       |
| 8, m. digastricus, venter posterior (cut away); | 24, m. scalenus anterior;                        |
| 9, m. longus capitis (divided);                 | 25, m. scalenus medius;                          |
| 10 and 28, m. splenius capitis;                 | 26, m. longus capitis;                           |
| 11 and 17, m. longus colli;                     | 29, m. digastricus, venter posterior (cut away); |
| 12 and 27, m. levator scapulae;                 | 30, processus styloideus;                        |
| 13, m. scalenus medius (initial part);          | 31, processus mastoideus                         |
| 14, m. scalenus anterior;                       |  |
| 15, m. scalenus posterior;                      |  |

1. The **scalenus anterior muscle** (*m. scalenus anterior*) arises from the anterior tubercles of the transverse processes of the third to sixth cervical vertebrae and is attached to the scalene tubercle of the first rib and the sulcus of the subclavian artery. Innervation:  $C_{5-7}$ .

2. The **scalenus medius muscle** (*m. scalenus medius*) is the largest scalene muscle. It originates from the anterior tubercles of the transverse processes

of all the cervical vertebrae and is attached to the first rib behind the sulcus of the subclavian artery. Innervation:  $C_{2-8}$ .

3. The **scalenus posterior muscle** (*m. scalenus posterior*) arises from the posterior tubercles of the three lower cervical vertebrae and is attached to the outer surface of the second rib. Innervation:  $C_{5-8}$ .

*Action.* The scalene muscles raise the upper ribs and act as muscles of inspiration. When the ribs are steadied, bilateral contraction of the muscles accomplish forward flexion of the cervical spine; in unilateral contraction, they flex and rotate this segment of the spine to their side.

### Prevertebral Muscles

1. The **longus cervicis muscle** (*m. longus colli*) is triangular and lies on the anterior surface of the spine, on both sides of it (Fig. 136). Three portions are distinguished in it: (1) vertical portion corresponding to the base of the triangle stretching from the anterior surface of the bodies of the upper three thoracic and the lower three cervical vertebrae to the anterior surface of the bodies of the second, third, and fourth cervical vertebrae; (2) superior oblique portion stretching from the anterior tubercles of the transverse processes of the third, fourth, and fifth cervical vertebrae to the anterior tubercle of the atlas and the body of the axis; (3) inferior oblique portion arising from the bodies of the upper thoracic vertebrae and attached to the anterior tubercles of the transverse processes of the fifth and sixth cervical vertebrae. Innervation:  $C_{3-8}$ .

2. The **longus capitis muscle** (*m. longus capitis*) overlaps the upper part of longus colli. It originates from the anterior tubercles of the transverse processes of the third, fourth, fifth, and sixth cervical vertebrae and is attached to the basilar part of the occipital bone. Innervation:  $C_{1-3}$ .

3 and 4. The **rectus capitis anterior** and **lateralis muscles** (*mm. recti capitis anterior* and *lateralis*) stretch from the lateral mass of the atlas (anterior muscle) and its transverse process (lateral muscle) to the occipital bone. Innervation:  $C_1$ .

*Action.* Rectus capitis anterior and longus capitis flex the head forward. Longus colli flexes the cervical spine on bilateral contraction of all its fibres; in unilateral contraction the spine is flexed laterally; the oblique portions take part in rotation and flexion of the head to the side; rectus capitis lateralis helps this muscle.

### TOPOGRAPHY OF THE NECK

The neck (*collum*) is divided into four regions: posterior, lateral, the region of the sternocleidomastoid muscle, and the anterior region (Fig. 137).

The **posterior region** (*regio colli posterior*) is behind the lateral border of the trapezius muscle and is the nape, or nucha.

The **lateral region** (*regio colli lateralis*) is behind the sternocleidomastoid muscle and is bounded in front by this muscle, below by the clavicle, and behind by the trapezius muscle.

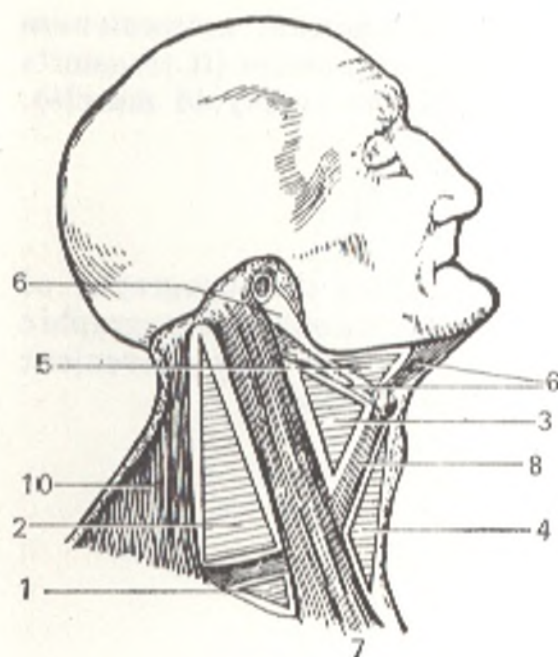


Fig. 137. Regions and triangles of the neck represented schematically.

- 1 and 2, regio colli lateralis (1, trigonum omoclaviculare);  
 3, 4, 5, and 6, regio colli anterior (3, trigonum caroticum; 5, trigonum submandibulare; 6, fossa retromandibularis);  
 7, m. sternocleidomastoideus (regio sternocleidomastoidea);  
 8, m. omohyoideus;  
 9, m. digastricus;  
 10, m. trapezius

The **sternocleidomastoid region** (*regio sternocleidomastoidea*) corresponds to the projection of this muscle.

The **anterior region** (*regio colli anterior*) is in front of the sternocleidomastoid muscle and is bounded posteriorly by this muscle, in front by the midline of the neck, and above by the border of the mandible. A small area behind the mandibular angle and in front of the mastoid process is called the **fossa retromandibularis**. It lodges the posterior part of the parotid gland, nerves, and vessels.

The anterior and lateral regions are divided into a number of triangles by the omohyoid muscle descending obliquely from front to back and crossing the sternocleidomastoid muscle.

The **omoclavicular trigone** or **subclavian triangle** (*trigonum omoclaviculare*) is distinguished in the lateral region of the neck; it is bounded by the sternocleidomastoid muscle in front, the inferior belly of the omohyoid muscle above, and the clavicle below.

Two triangles are distinguished in the anterior region of the neck: (1) the **fossa carotica**, or **carotis trigone** (*trigonum caroticum*) (transmitting the carotid artery), formed by the sternocleidomastoid muscle posteriorly, the posterior belly of the digastric muscle in front and above, and the superior belly of the omohyoid muscle in front and below and (2) the **submandibular trigone** (*trigonum submandibulare*) (lodging the submaxillary gland), formed by the inferior border of the mandible above and the two bellies of the digastric muscle.

Triangular slits or spaces form between the scalene muscles; they transmit nerves and vessels of the upper limb.

1. Between the anterior and middle scalene muscles is **spatium interscalenum**, bounded by the first rib below (it transmits the subclavian artery and the brachial plexus).

2. In front of the anterior scalene muscle is *spatium antescalenum* covered in front by the sternothyroid and sternohyoid muscles (it transmits the subclavian vein, the suprascapular artery, and the omohyoid muscle).

#### FASCIAE OF THE NECK

The fasciae of the neck (Figs. 138 and 139) reflect the topography of organs located in the cervical region. That is why textbooks on topographic anatomy describe these fasciae after Shevkunenکو; this is most convenient for surgical purposes. Five fascial layers are distinguished.

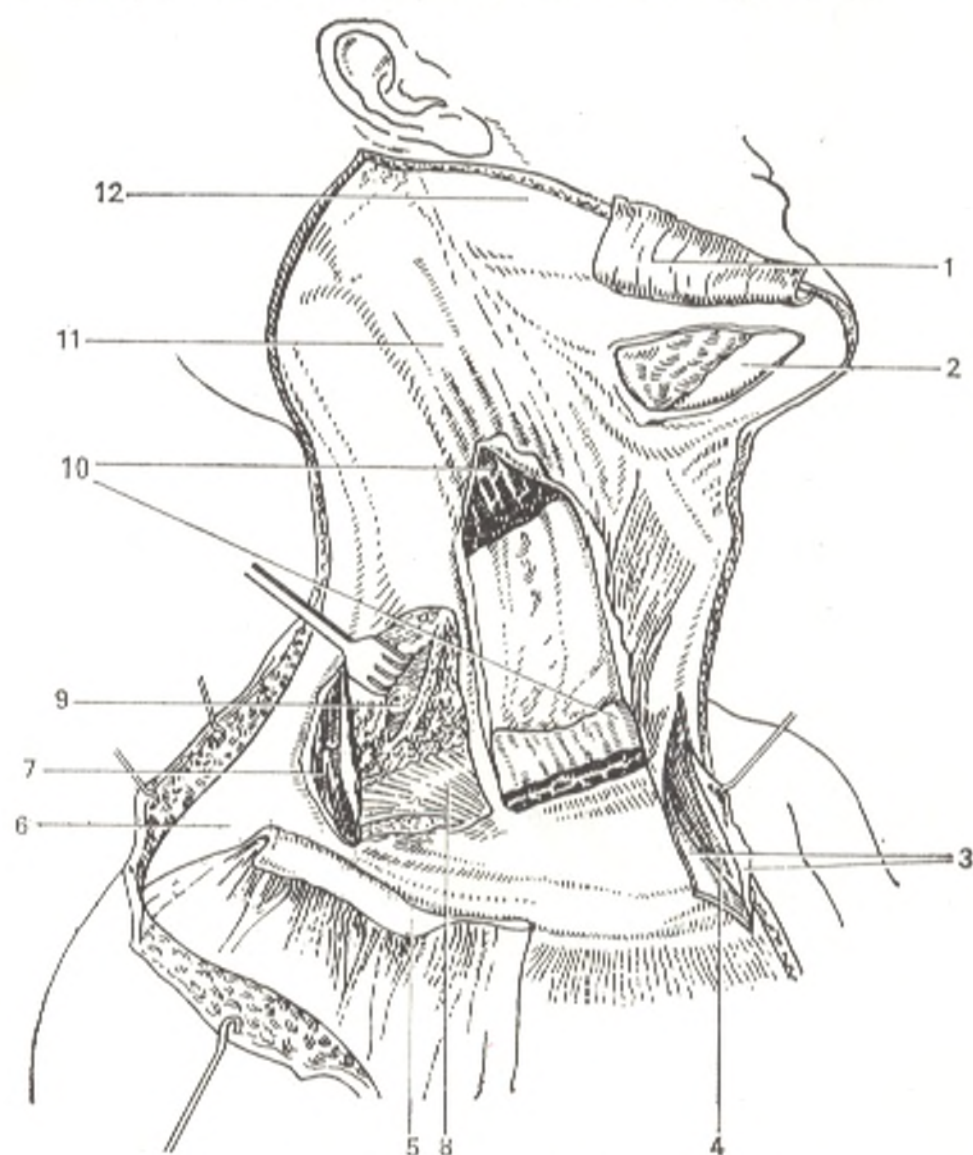


Fig. 138. Fasciae of the neck (lateral aspect).

1 and 5, platysma (divided and reflected);  
2, glandula submandibularis;  
3, 6, and 11, fascia cervicalis, lamina superficialis;  
4, spatium (interaponeuroticum) suprasternale;

7, m. trapezius;  
8, lamina pretrachealis fasciae cervicalis;  
9, lamina prevertebralis fasciae cervicalis;  
10, m. sternocleidomastoideus (divided and reflected);  
12, fascia parotidea

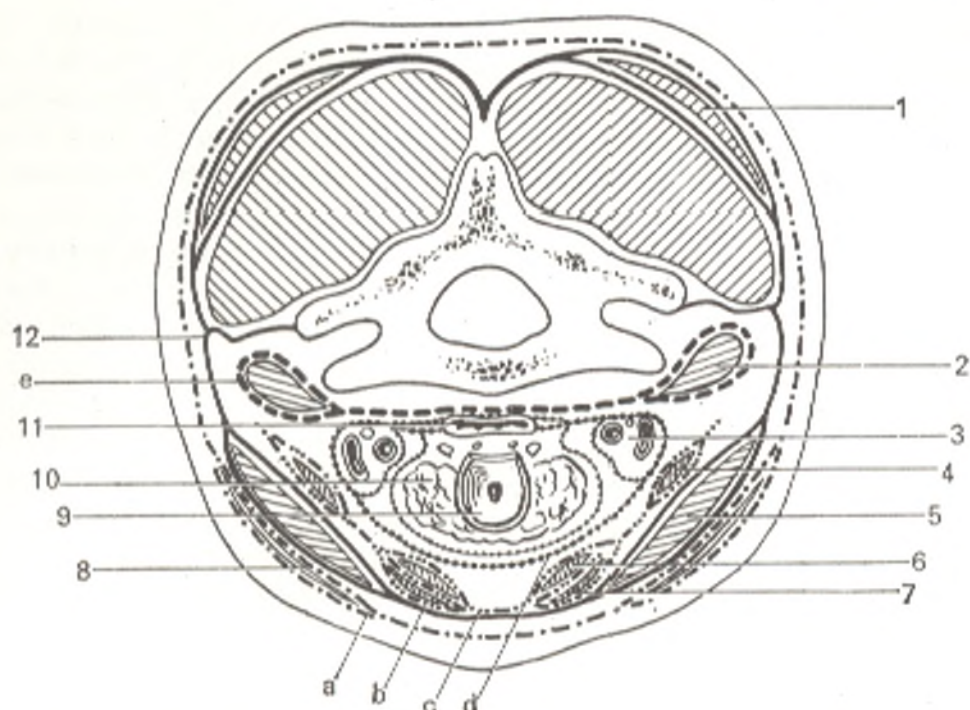


Fig. 139. Fasciae of the neck on horizontal section (schematic representation) (after Shevkunenko).

- |                               |   |
|-------------------------------|---|
| 1, m. trapezius;              | 10, thyroid gland;  |
| 2, m. scalenus anterior;      | 11, oesophagus;   |
| 3, neurovascular bundle;      | 12, fascial lamina, separating the anterior part of the neck from the posterior part; |
| 4, m. omohyoideus;            | a, first layer;   |
| 5, m. sternocleidomastoideus; | b, second layer;  |
| 6, m. thyrohyoideus;          | c, third layer;   |
| 7, m. sternothyroideus;       | d, fourth layer;  |
| 8, m. platysma;               | e, fifth layer  |
| 9, larynx;                    |   |

The first fascia, or the **superficial cervical fascia** (*fascia colli superficialis*) is part of the common superficial (subcutaneous) fascia of the body and is continuous with the fasciae of the neighbouring areas. It is distinguished from the superficial fascia of the other parts of the body in that it contains the platysma muscle for which it is the perimysium.

The second fascia, or the **superficial layer of the cervical fascia proper** (*lamina superficialis fasciae colli propriae*) encloses the whole neck like a collar and covers the suprahyoid and infrahyoid group of muscles, the salivary glands, the vessels, and the nerves. It is attached above to the mandible and the mastoid process and is continuous on the face with the parotid and masseteric fasciae which cover the parotid gland and the masseter muscle. Below, the superficial layer is attached to the anterior border of the manubrium sterni and the clavicle. In front, on the midline, it fuses with the deep layer of the cervical fascia proper to form the *linea alba cervicalis* (2-3 mm in width). On each side of the neck, the superficial layer passes from the linea alba posteriorly to the spinous processes of the cervical vertebrae. On reaching the sternocleidomastoid and the trapezius muscles it separates into two lamellae, encloses the muscles and again fuses, thus forming fascial sheaths

for each of these muscles separately. Where the superficial layer of the cervical fascia proper passes over the transverse processes, it is attached to them for which purpose it gives off a fascial branch in the form of a frontally situated lamina separating the entire fascial space of the neck into two parts, anterior and posterior (Pirogov). As a result, suppurative processes develop in both parts of the fascial space independently of one another.

The third fascia, or the **deep layer of the cervical fascia proper** (*lamina profunda fasciae colli propriae*) is manifest only in the middle part of the neck behind the sternocleidomastoid muscle where it is stretched like a trapezium over a triangular space bounded above by the hyoid bone, on both sides by the omohyoid muscles, and below by the clavicles and the sternum. Since the deep layer of the cervical fascia proper is attached below to the posterior border of the manubrium sterni and the clavicles, while the superficial layer is attached to the anterior border of these bones, a narrow space is left between these layers; this is *spatium interaponeuroticum suprasternale* containing loose fatty tissue and the superficial veins of the neck, the jugular venous arch (*arcus venosus juguli*), injury to which is fraught with danger. Laterally this space communicates with *recessus lateralis*, a blind space behind the inferior end of the sternocleidomastoid muscle into which pus may penetrate. The deep layer, separating and again fusing, forms fascial sheaths for the infrahyoid muscles (the sternohyoid, sternothyroid, and thyrohyoid muscles). It unites these muscles to form a thick connective-tissue muscular expansion, like their aponeurosis (*aponeurosis omoclavicularis*), which tenses when the omohyoid muscles contract and thus facilitates the flow of blood in the cervical veins perforating it and fusing with it. This tension and the triangular shape suggested the image-bearing name of the aponeurosis, the "cervical sail".

The fourth fascia, or the **endocervical fascia** (*fascia endocervicalis*) encloses the organs located in the neck (larynx, trachea, thyroid gland, pharynx, oesophagus, and the large vessels). It consists of two layers, a visceral layer which invests each of these organs and forms a capsule for them, and a parietal layer which encloses all these organs in the aggregate and forms a sheath for the important vessels, the common carotid artery and the internal jugular vein.

The space between the parietal and visceral layers of the endocervical fascia lies in front of the viscera and is therefore called **previsceral space** (*spatium previscerale*), that in front of the trachea, in particular, is called **pretracheal space** (*spatium pretracheale*). The latter contains, in addition to fatty tissue and lymph nodes, the isthmus of the thyroid gland and blood vessels (*arteria thyroidea ima* and *plexus thyroideus impar*) which can be injured during tracheotomy. *Spatium pretracheale* extends into the anterior mediastinum. Enclosing the cervical viscera, the parietal layer is in front and to the sides of them, but at the same time it is behind the infrahyoid group of muscles (the sternohyoid, sternothyroid, thyrohyoid, and omohyoid muscles).

The fifth, **prevertebral fascia** (*fascia prevertebralis*) covers anteriorly the prevertebral and scalene muscles stretching on the spine, and by fusing

with the transverse processes of the vertebrae forms sheaths for these muscles.

Above, the prevertebral fascia arises from the base of the skull behind the pharynx, descends through the entire length of the neck, and enters the posterior mediastinum where it merges with the endothoracic fascia.

Between the fourth and fifth fasciae, behind the pharynx and oesophagus, is a narrow space filled with loose fatty tissue; this is *retrovisceral space* (*spatium retroviscerale*), which is continuous downwards with the posterior mediastinum.

The five fasciae described differ in origin: some are reduced muscles (the first fascia is the perimysium of platysma muscle, the third fascia is the reduced cleidohyoideus muscle of which only the aponeurosis remains); others are the products of thickening of the fatty tissue surrounding the organs (the parietal and visceral layers of the fourth fascia), and still others originate in a manner common to fasciae (the second and fifth fasciae).

According to the Paris Nomina Anatomica, all fasciae of the neck are embraced under the term *fascia cervicalis*, which is divided into three layers as follows.

1. The *superficial layer* (fascia) (*lamina superficialis*) corresponding to the first fascia, *fascia colli superficialis*.

2. The *pretracheal layer* (fascia) (*lamina pretrachealis*) covering the salivary glands, muscles, and other structures located in front of the trachea, hence its name. It corresponds to the second and third fasciae (after Shevkunenko), i.e. the superficial and deep layers of *fascia colli propriae*.

3. The *prevertebral layer* (fascia) (*lamina prevertebralis*) corresponding to the fifth fascia, i. e. *fascia prevertebralis* (after Shevkunenko).

The fourth fascia (*fascia endocervicalis*) is omitted in PNA.

The cervical fasciae are firmly connected with the walls of the veins by means of connective-tissue strands which prevent them from collapsing in injuries. Damage to even the small cervical veins is therefore fraught with danger because due to the closeness of the right atrium and the suction action of the chest air can enter the blood flow, i.e. air embolism can occur.

## THE MUSCLES OF THE HEAD

With the exception of the striated muscles of the sight and hearing organs and the upper part of the digestive system (described in respective sections of this volume), all the muscles of the head can be divided into the following two groups:

1. Muscles of mastication: derivatives of the first visceral (mandibular) arch. Innervation: *nervus trigeminus*.

2. Muscles of facial expression: derivatives of the second visceral (hyoid) arch. Innervation: *nervus facialis*.

## MUSCLES OF MASTICATION

The four muscles of mastication on each side are related genetically (they originate from a single visceral arch, the mandibular arch), morphologically (they are all attached to the mandible which they move when they

contract), and functionally (they accomplish the chewing movements of the mandible, which determines their location).

1. The **masseter muscle** (*m. masseter*) is thick and quadrangular. It arises from the inferior border of the zygoma and the zygomatic arch and is attached to the masseteric tuberosity and the external surface of the mandibular ramus.

2. The **temporal muscle** (*m. temporalis*) is wide at its origin and occupies the whole temporal fossa of the skull up to the temporal line. The muscle fibres converge like a fan and form a strong tendon which passes under the zygomatic arch and is attached to the coronoid process of the mandible.

3. The **lateral pterygoid muscle** (*m. pterygoideus lateralis*) arises from the inferior surface of the greater wing of the sphenoid bone and the pterygoid process. It is directed almost horizontally backward and laterally and is attached to the neck of the mandibular condylar process and to the capsule and articular disk of the temporomandibular joint (Figs. 140 and 141).

4. The **medial pterygoid muscle** (*m. pterygoideus medialis*) arises in the pterygoid fossa of the pterygoid process, passes downward and laterally, and attaches to the medial surface of the mandibular angle, symmetrically with the masseter muscle, at the pterygoid tuberosity.

*Action.* The temporal, masseter, and medial pterygoid muscles pull the mandible to the maxilla when the mouth is open and thus close the mouth. On simultaneous contraction of both lateral pterygoid muscles the mandible protrudes forward. Movement in the opposite direction is accomplished by the posterior fibres of the temporal muscle which pass almost horizontally forward. Unilateral contraction of the lateral pterygoid muscle displaces the mandible to the contralateral side of the mouth. The temporal muscle is associated with articulate speech; it sets the mandible in a definite position when a person speaks.

#### MUSCLES OF FACIAL EXPRESSION

Part of the visceral musculature of the head, which was formerly related to the head and neck viscera, gradually transformed into the skin musculature of the neck and from this musculature, by differentiation into separate thin bundles, to the muscles of facial expression. This pattern of development explains the close relation of these muscles to the skin for whose movements they are responsible. This also explains the other specific features of their structure and function.

For instance, the muscles of facial expression, as distinct from the skeletal muscles, are not doubly attached to the bones but always interlace at one or both ends with the skin or mucous membrane. As a result they are devoid of fasciae and move the skin upon contraction. When they relax, the skin returns to its former state due to its elasticity. The role of antagonists is much less important here than in the case of the skeletal muscles.

The muscles of facial expression are small, thin muscle bundles grouped around the natural orifices (the mouth, nose, palpebral fissure, and ear). These muscles take part in closing or widening the orifices.



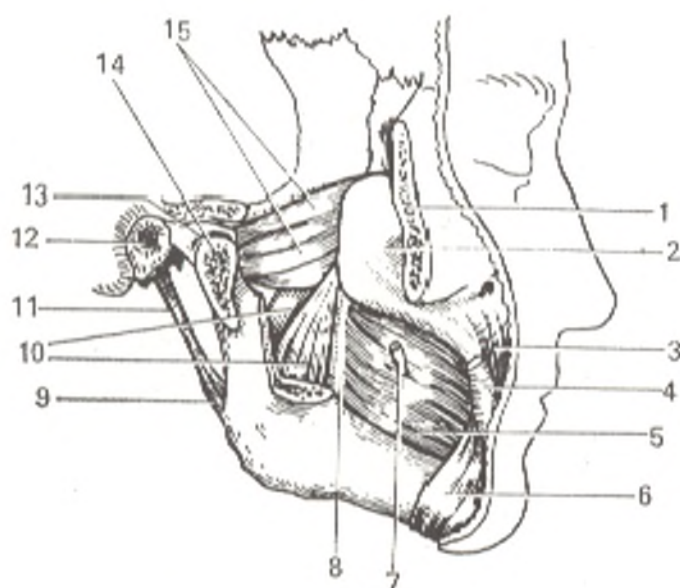


Fig. 140. Pterygoid muscles.

- |                               |                                  |
|-------------------------------|----------------------------------|
| 1, os zygomaticum (cut away); | 9, lig. stylomandibulare;        |
| 2, maxilla;                   | 10, m. pterygoideus medialis;    |
| 3, m. levator anguli oris;    | 11, proc. styloideus;            |
| 4, m. zygomaticus major;      | 12, meatus acusticus externus;   |
| 5, m. buccinator;             | 13, discus articularis;          |
| 6, m. depressor anguli oris;  | 14, proc. condylaris (cut away); |
| 7, ductus parotideus;         | 15, m. pterygoideus lateralis    |
| 8, raphe pterygomandibulare;  |                                  |

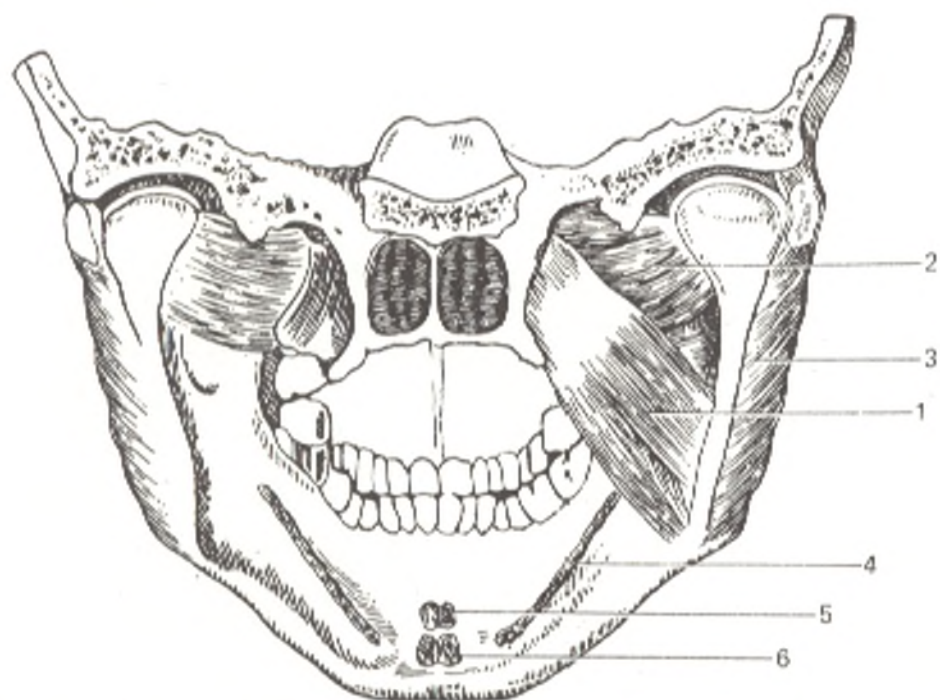


Fig. 141. Anterior part of skull with mandible and muscles of mastication (viewed from inside).

- |                               |                              |
|-------------------------------|------------------------------|
| 1, m. pterygoideus medialis;  | 4, m. mylohyoideus (origin); |
| 2, m. pterygoideus lateralis; | 5, m. genioglossus (origin); |
| 3, m. masseter;               | 6, m. geniohyoideus (origin) |

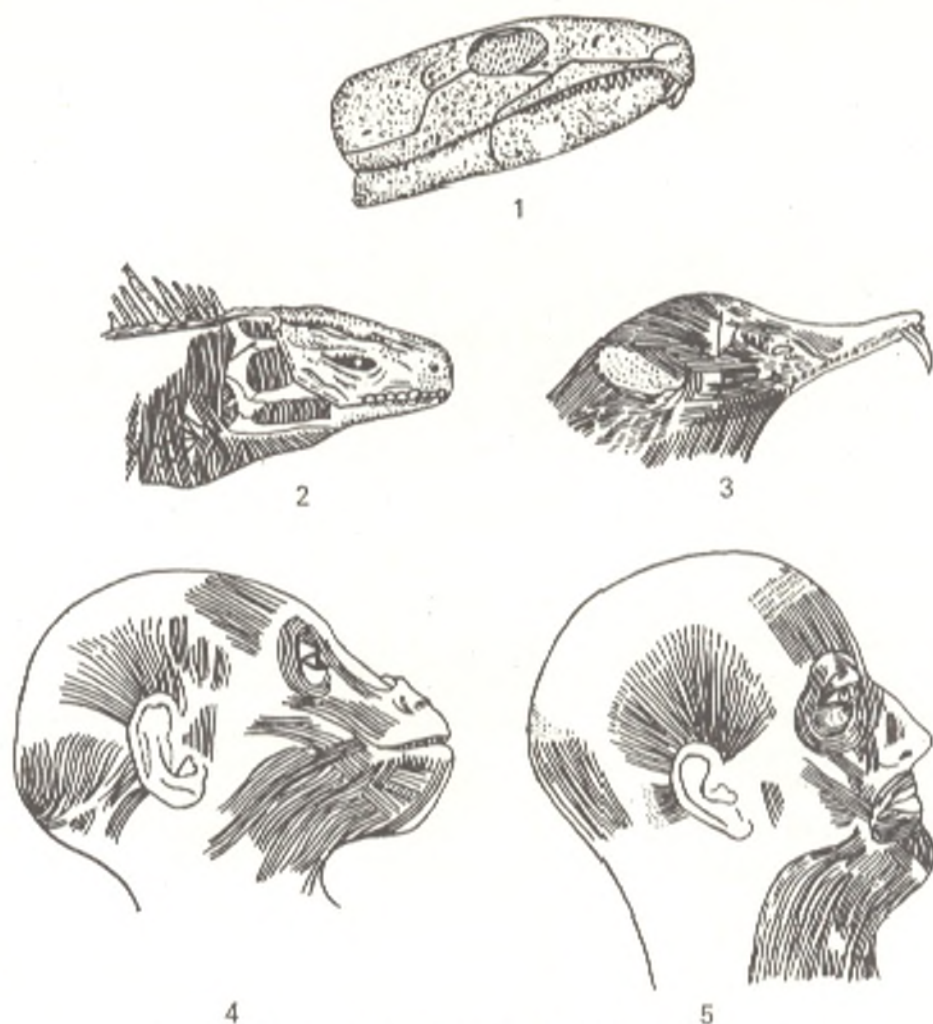


Fig. 142. Evolution of the facial musculature.

1, primitive reptile;  
2, modern reptile;  
3, primitive mammal (echidna);

4, gorilla;  
5, man

*Sphincters* are usually arranged annularly around the orifices they close, while the *dilators*, which widen the orifices, are arranged radially. By changing the shape of the orifices and moving the skin with the formation of various folds, the muscles lend the face various emotional expressions. In addition to expressing feeling, which is their main function, these muscles take part in speech, mastication, and so on.

In the human being, the shortening of the jaws and the use of the lips in articulate speech led to finer development of the muscles of facial expression around the mouth. The ear musculature, in contrast, which is well developed in animals, reduced in the human and survives as rudimentary muscles (Fig. 142).

#### MUSCLES OF THE SCALP

1. Almost the whole skull cap is covered by a thin **epicranius muscle** (*m. epicranius*), which has a wide tendinous part, the **epicranial aponeurosis** (*galea aponeurotica*) (*aponeurosis epicranialis*), and a muscular part separating into three bellies: (1) the **anterior, or frontal, belly** (*venter frontalis*)

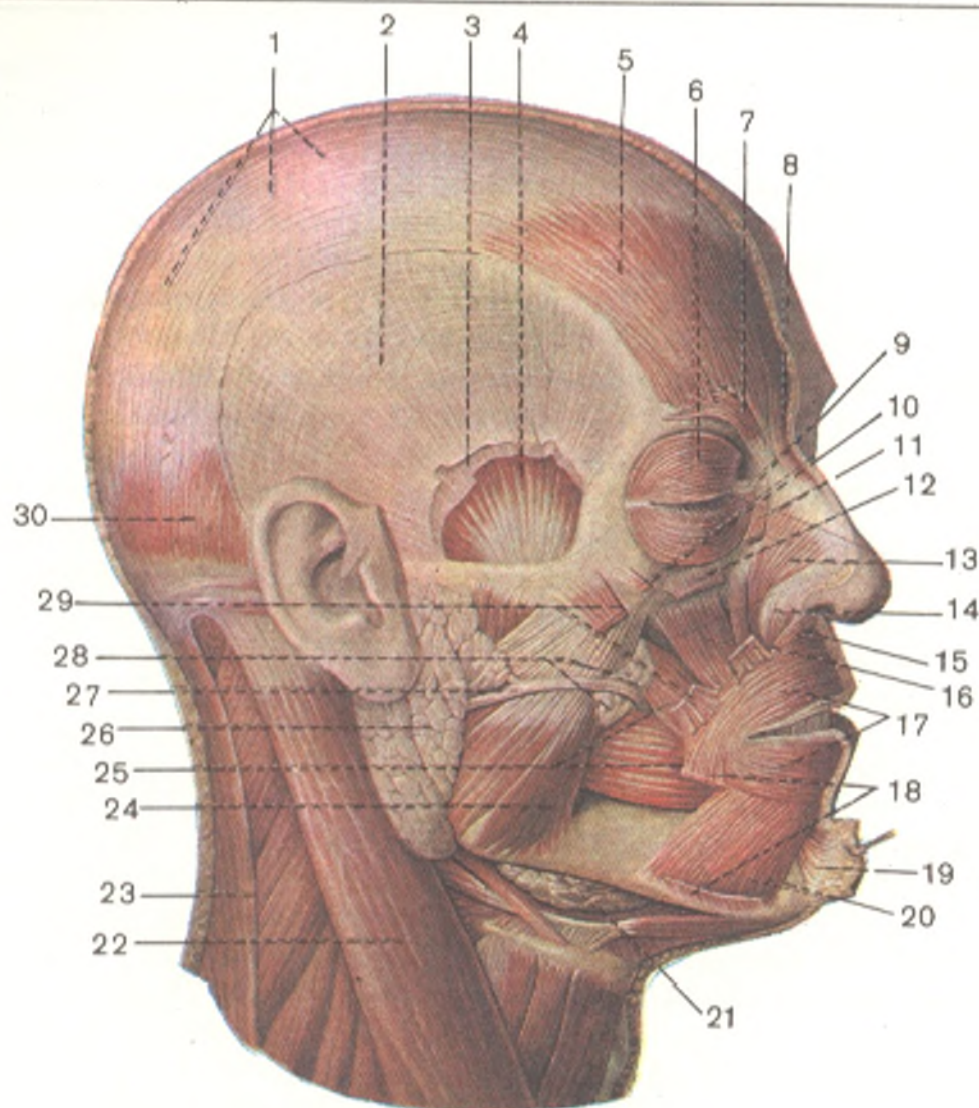


Fig. 143. Muscles of the head.

- |  |                                      |   |
|--|--------------------------------------|---|
| 1, galea aponeurotica;                       | 11, m. levator palpebrae superioris; | 21, glandula submandibularis;                 |
| 2, fascia temporalis (lamina superficialis); | 12, m. levator labii superioris;     | 22, m. sternocleidomastoideus;                |
| 3, fascia temporalis (lamina profunda);      | 13, m. nasalis (pars transversus);   | 23, m. trapezius;                             |
| 4, m. temporalis;                            | 14, m. nasalis (pars alaris);        | 24, m. masseter;                              |
| 5, venter frontalis;                         | 15, m. depressor septi;              | 25, m. buccinator;                            |
| 6, m. orbicularis oculi;                     | 16, m. levator anguli oris;          | 26, glandula parotis;                         |
| 7, m. corrugator supercilii;                 | 17, m. orbicularis oris;             | 27, ductus paratideus;                        |
| 8, m. procerus;                              | 18, m. depressor anguli oris;        | 28, corpus adiposum buccae;                   |
| 9, l. palpebrale mediale;                    | 19, m. mentalis;                     | 29, m. zygomaticus major;                     |
| 10, m. zygomaticus minor;                    | 20, m. depressor labii inferioris;   | 30, venter occipitalis (m. occipitofrontalis) |

arises from the skin of the eyebrows and interlaces with the aponeurosis in front; (2) the posterior, or occipital, belly (*venter occipitalis*) originates from the superior nuchal line and interlaces with the aponeurosis posteriorly, and (3) the lateral belly separates into three small muscles approaching the auricle anteriorly (*m. auricularis anterior*), superiorly (*m. auricularis superior*), and posteriorly (*m. auricularis posterior*). The three auricular muscles interlace with the aponeurosis laterally (Fig. 143). The galea aponeurotica invests the middle part of the dome of the skull to form the central part of the epicranial muscle.

**Action.** Loosely connected to the periosteum of the skull bones, the epicranial aponeurosis fuses closely with the skin, which can, therefore, move with it during contraction of the frontal and occipital bellies. When the epicranial aponeurosis is steadied by the occipital belly of the muscle, the frontal belly raises the eyebrow (arches it) and wrinkles the skin of the forehead transversely.

The auricular muscles (the lateral belly of the epicranial muscle) are very poorly developed in most humans and have no function. The remnants of the human auricular musculature are a classical example of rudimentary organs. Persons who can literally move their ears, as in the figurative expression "to prick up one's ears", are very rare.<sup>1</sup>

#### MUSCLES SURROUNDING THE EYES

2. The **procerus muscle** (*m. procerus*) arises from the bones of the ridge of the nose and the aponeurosis of the nasal muscle and is inserted into the skin of the glabella where it interlaces with the frontal belly of the epicranial. By drawing down the skin of this region, it causes transverse wrinkling of the skin above the bridge of the nose.

3. The **orbicularis oculi muscle** (*m. orbicularis oculi*) surrounds the eyelids; its wide peripheral orbital part (*pars orbitalis*) is on the bony margin of the orbit, while the central palpebral part (*pars palpebralis*) is on the eyelids. A small third, lacrimal, part (*pars lacrimalis*) can also be distinguished. It is a part of the pars palpebralis, which arises from the wall of the lacrimal sac and, by dilating the sac, contributes to the absorption of the tears through the lacrimal canaliculi. The palpebral part closes the lids gently, while strong contraction of the orbital part closes them tightly. Isolated contraction of the upper fibres of this part draws the skin of the forehead and the eyebrow downward; as a result the eyebrow is straightened out, and the transverse wrinkles on the forehead are smoothed out. In this respect it is an antagonist of the venter frontalis.

Still another small part of the orbicular muscle of the eye lodged under the pars orbitalis can be distinguished; this is the **corrugator muscle of the eyebrow** (*m. corrugator supercillii*), which draws the eyebrows toward each other and causes the formation of vertical wrinkles in the space between the eyebrows above the bridge of the nose. In addition to the vertical wrinkles, short transverse wrinkles often form above the bridge of the nose in the middle one third of the forehead as the result of simultaneous action by the venter frontalis. This position of the eyebrows indicates suffering, pain, or other strong emotions.

#### MUSCLES AROUND THE MOUTH

4. The **levator labii superioris muscle** (*m. levator labii superioris*) arises as a quadrangular plate from the infraorbital border of the maxilla; its slips converge and most of them are inserted into the skin of the nasolabial

<sup>1</sup> In another PNA edition, the auricular muscles are grouped independently as the muscles of the ear circumference; the other two bellies of the apicranial muscle, venter frontalis and venter occipitalis, form the occipitofrontal muscle.

fold. It gives off a slip to the ala of the nose, and is classified separately as the levator muscle of the upper lip and the ala of the nose (*m. levator labii superioris alaeque nasi*). When contracted, the muscle raises the upper lip and thus makes the nasolabial sulcus deeper; it pulls the ala of the nose upward and dilates the nares.

5. The **zygomatic minor muscle** (*m. zygomaticus minor*) arises from the zygomatic bone and is inserted into the nasolabial fold which it deepens during contraction.

6. The **zygomaticus major muscle** (*m. zygomaticus major*) passes from the lateral surface of the zygomatic bone to the angle of the mouth and partly to the upper lip. It pulls the angle of the mouth upward and laterally, as a result of which the nasolabial sulcus becomes much deeper. The action of the zygomaticus major muscle is perhaps the most important in the expression of laughter on the face.

7. The **risorius muscle** (*m. risorius*) is another muscle important in the expression of laughter (*L risus* laughter). This small transverse slip arises from the parotid and masseteric fasciae and passes to the angle of the mouth. It is often absent. It stretches the mouth in laughing; in some persons it is attached to the skin of the cheeks and when it contracts, a small depression (dimple) forms laterally to the angle of the mouth.

8. The **depressor anguli oris muscle** (*m. depressor anguli oris*) is a triangular muscular plate. Its base arises from the inferior border of the mandible laterally of the mental tubercle. Its apex is inserted into the skin of the angle of the mouth and the upper lip. It pulls down the angle of the mouth and straightens out the nasolabial fold. Depression of the angles of the mouth produces the expression of grief.

9. The **levator anguli oris muscle** (*m. levator anguli oris*) is quadrangular and is situated under the levator labii superioris and zygomaticus. It arises from the canine fossa (and was formerly called *m. caninus*) below the infra-orbital foramen and is inserted into the angle of the mouth. It raises the angle of the mouth.

10. The **depressor labii inferioris muscle** (*m. depressor labii inferioris*) lies directly on the bone. It arises on the border of the mandible where it is a continuation of the platysma muscle, passes obliquely, and is inserted into the skin of the whole lower lip including its border. It pulls the lip down and a little laterally, as occurs, for example, in expressions of disgust.

11. The **mentalis muscle** (*m. mentalis*) is one of the strongest in the group of muscles of facial expression. It arises from the juga alveolaria of the lower incisors and the canine tooth and is inserted into the skin of the chin. It raises the skin of the chin (with the formation of small dimples in it) and pushes the lower lip upward, pressing it to the upper lip.

12. The **buccinator muscle** (*m. buccinator*) is a wide quadrangular muscle forming the lateral wall of the oral cavity and directly adjoining the mucous membrane. It arises from the maxillary alveolar process along a distance from the first molar posteriorly to the pterygoid process and then descends along the pterygomandibular raphe (a fibrous strand stretching between the hamulus pterygoideus and the crista buccinatoria mandibulae)

to the mandible, where it passes on the crista buccinatoria and the lateral wall of the sockets of the premolars and molars forward to the angle of the mouth. At the level of the second maxillary molar the muscle is pierced by the parotid duct (ductus parotideus). The external surface of the buccinator muscle is covered by the buccopharyngeal fascia on which there is a pad of fat. The action of this muscle consists in the expulsion of the contents of the vestibule of the mouth, as, for example, the expulsion of air when playing a trumpet; hence the name of the muscle, buccinator (*L. trumpeter*).

13. The orbicularis oris muscle (*m. orbicularis oris*) lies in the thickness of the lips around the rima oris. In both the upper and lower lips the fibres of the muscle pass from the angle of the mouth to the midline and interlace with the contralateral fibres. Numerous slips from the adjoining muscles join them. Contraction of the peripheral part of the orbicularis oris purses the lips and pushes them forward, as in kissing. During contraction of the part under the vermilion border, the lips are drawn tightly together and inverted; as a result the vermilion border is hidden. The orbicularis oris, which is arranged around the mouth, functions as a sphincter, i.e. a muscle that closes the mouth. This action is antagonistic to the action of the radial muscles of the mouth, i.e. muscles which radiate from it and open it (*mm. levator labii superioris and levator anguli oris, depressor labii inferioris and depressor anguli oris, etc.*) (Figs. 143 and 144).

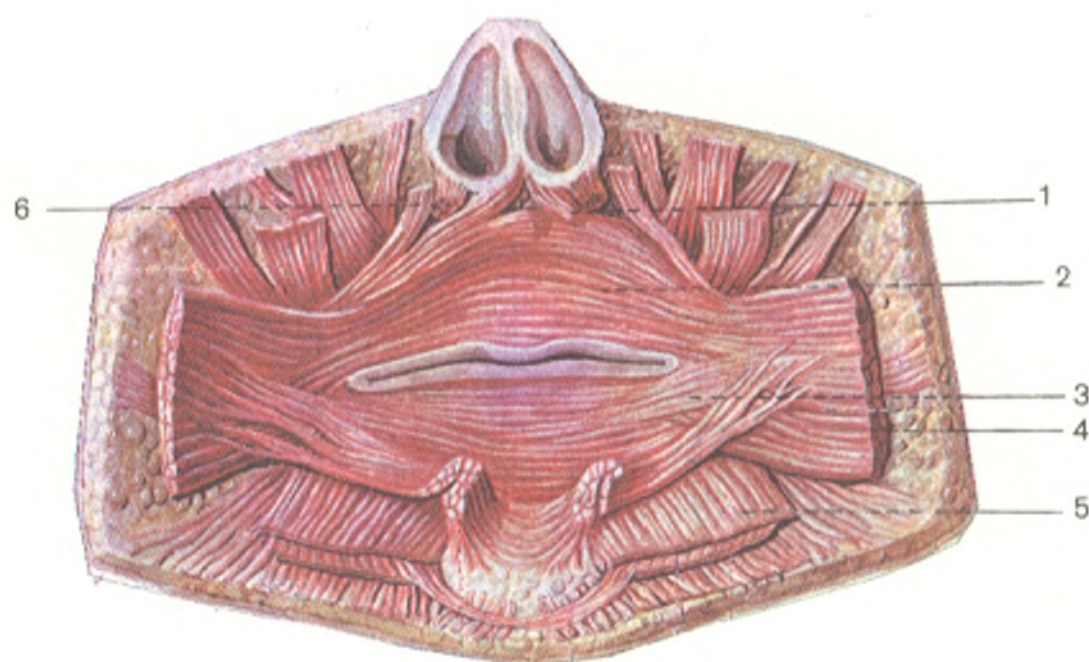

Fig. 144. Muscles of rima oris, viewed from inside.

1 and 6, *m. nasalis*;  
2 and 3, *m. orbicularis oris*;

4, *m. buccinator*;  
5, *m. depressor labii inferioris*

## MUSCLES SURROUNDING THE NOSE

14. The **nasal muscle** (*m. nasalis*) is poorly developed and partly covered by the levator muscle of the upper lip. It arises on the maxilla from the wall of the socket of the maxillary lateral incisor and immediately separates into three parts: pars transversa, pars alaris, and m. depressor septi (nasi). The most laterally located **transverse part** (*pars transversa*) ascends to the bridge of the nose in the nasal cartilage and is continuous here with an aponeurotic expansion which joins the contralateral expansion; contraction of the pars transversa compresses the cartilaginous part of the nose. The **alar part of the nasal muscle** (*pars alaris*) forms the short segment of the nasal muscle proper passing to the ala; its contraction draws the ala downward. The medial part of the muscle, which passes to the cartilaginous part of the nasal septum and depresses it when contracted, is called the **depressor septi muscle** (*m. depressor septi*).

## FASCIAE OF THE HEAD

The epicranial aponeurosis covering the dome of the skull (as pointed out above, see Fig. 143) becomes very thin on the lateral parts of the dome to become a loosely fibrous lamina, under which is a strong **temporal fascia** (*fascia temporalis*) shining like a tendon that covers the temporal muscle and arises above from the temporal line. Below the temporal line it attaches to the zygomatic arch and separates into two layers: a superficial layer, which fuses with the external surface of the arch, and a deep layer, which fuses with the internal surface of the arch. The space between the two layers is filled with fatty tissue. The temporal fascia closes the cranial fossa temporalis in the osteo-fibrous receptacle that lodges the temporal muscle with fatty tissue. The masseter muscle is covered by the **masseteric fascia** (*fascia masseterica*), which invests the muscle and attaches to the zygomatic arch above, to the mandibular border below, and to the mandibular ramus posteriorly and anteriorly. Posteriorly and partly externally, this fascia is connected with the **parotid fascia** (*fascia parotidea*), which forms a capsule around the gland. Fasciae do not exist on the face because the muscles of the facial expression lie directly under the skin. The only exception is the buccinator muscle; its posterior section is covered with the thick **buccopharyngeal fascia** (*fascia buccopharyngea*), which becomes loose anteriorly and blends with the fatty tissue of the cheek, fuses posteriorly with the pterygomandibular raphe, and is continuous with the connective-tissue covering of the pharyngeal muscles.

## THE MUSCLES OF THE UPPER LIMB

The hand, as the organ of labour, performs certain necessary movements with the help of the muscles of the upper limb.

The *musculature of the shoulder girdle* attaches it to the skeleton of the trunk thus forming muscular joining of bones, *synsarcosis* (Gk *sarx*,

*sarcos* flesh), and moves the bones of the girdle, mainly the scapula and the whole upper limb. The muscles of the shoulder girdle run from the head, back, and chest toward the bones like to a centre from all directions. The muscles differ in origin: (1) derivatives of the ventral trunk musculature, which acquired points of attachment on the bones of the girdle, i.e. trunco-fugal muscles (rhomboideus, levator scapulae, serratus anterior, subclavius, omohyoideus); (2) derivatives of the visceral arches (trapezius); and (3) trunco-petal muscles (pectoralis major and pectoralis minor).

The position and action of these muscles are discussed above in the section dealing with the muscles of the back, chest, and neck. The remaining muscles of the upper limb are derived from the ventral part of the myotomes and can be classified into the muscles of the shoulder joint, the muscles of the upper arm, the forearm, and the hand. They are innervated by branches of the brachial plexus, plexus brachialis.

### MUSCLES OF THE REGION OF THE SHOULDER JOINT

The muscles of the shoulder joint develop in accordance with the spherical shape of the shoulder joint and the performance of multidirectional movements at the joint. Its muscles are attached to the humerus and arranged on all sides. They are divided topographically into dorsal and ventral groups.

#### A. THE DORSAL GROUP

1. The **deltoid muscle** (*m. deltoideus*) covers the proximal end of the humerus. It is triangular and *arises* from the lateral one third of the clavicle and the acromial process of the scapula, and from the entire length of the spina scapulae. The anterior and posterior slips of the muscle pass almost straight downward and laterally; the middle slips curve over the humeral head and pass straight downward. All the slips converge and *attach* to the deltoid tuberosity in the middle of the humerus. The *subdeltoid bursa* (*bursa subdeltoidea*) is found between the inner surface of the muscle and the greater tubercle of the humerus (Figs. 145 and 146).

*Action.* Contraction of the anterior (clavicular) part of the deltoid muscle raises the arm forward (anteflexio); contraction of the posterior (scapular) part causes the opposite movement (retroflexio). Contraction of either the middle acromial part or of the whole deltoid muscle abducts the arm from the trunk to the horizontal level. All these movements occur at the shoulder joint. When movements at the joint are restrained by the abutment of the humerus against the vault of the shoulder, the arm can be raised above the horizontal level (elevatio) with the help of the muscles of the shoulder girdle and the muscles of the back which are attached to the scapula. In this case, the superior slips of the trapezius muscle pull the lateral angle of the scapula upward and medially by means of the spina scapulae, while the inferior slips of the anterior serratus muscle pull the inferior angle upward and laterally. As a result, the scapula rotates on the sagittal axis, passing through its superior angle (Fig. 147). This angle is steadied by con-



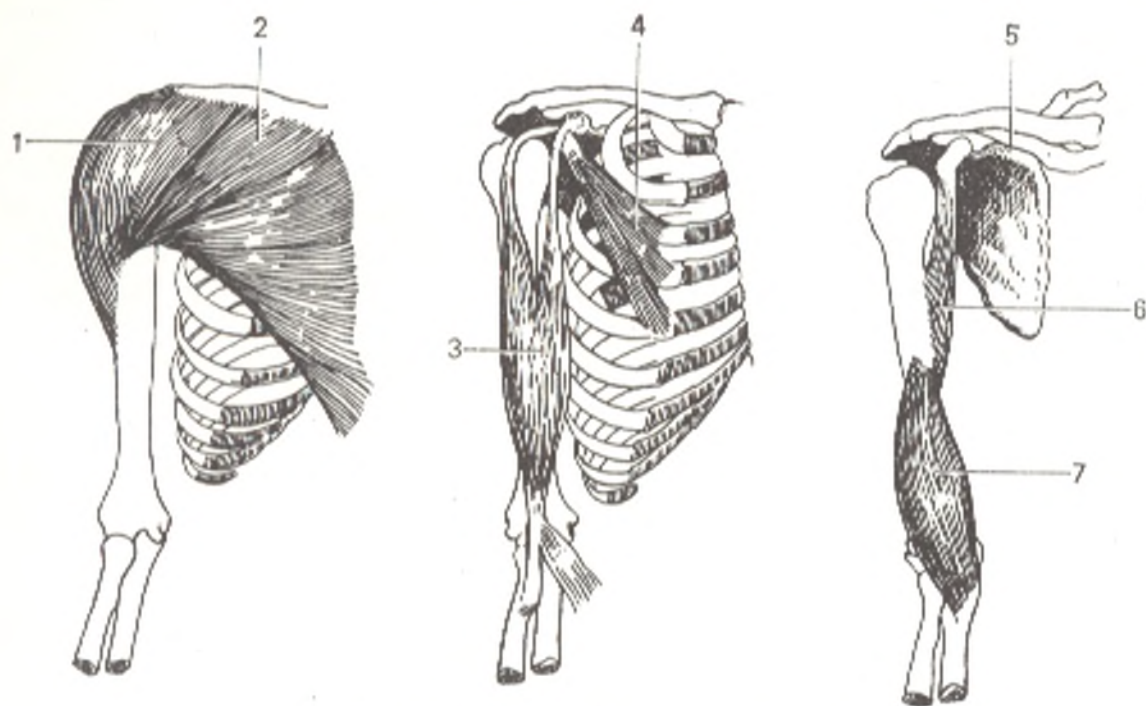


Fig. 145. Muscles of thorax and upper arm.

1, m. deltoideus;  
2, m. pectoralis major;  
3, m. biceps brachii;  
4, m. pectoralis minor;

5, m. subclavius;  
6, m. coracobrachialis;  
7, m. brachialis

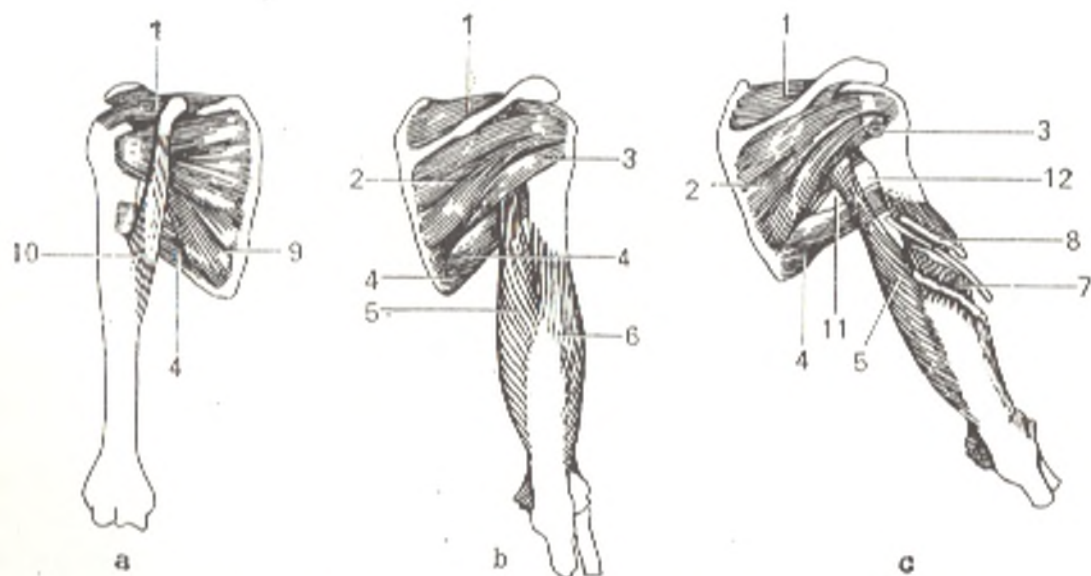


Fig. 146. Muscles of shoulder girdle and upper arm (right side).

a, anterior aspect;  
b and c, posterior aspect.  
1, m. supraspinatus;  
2, m. infraspinatus;  
3, m. teres minor;  
4, m. teres major;  
5, caput longum m. tricipitis;

6, caput laterale m. tricipitis;  
7, caput mediale m. tricipitis;  
8, canalis humeromuscularis;  
9, m. subscapularis;  
10, m. coracobrachialis;  
11, foramen trilaterum;  
12, foramen quadrilaterum

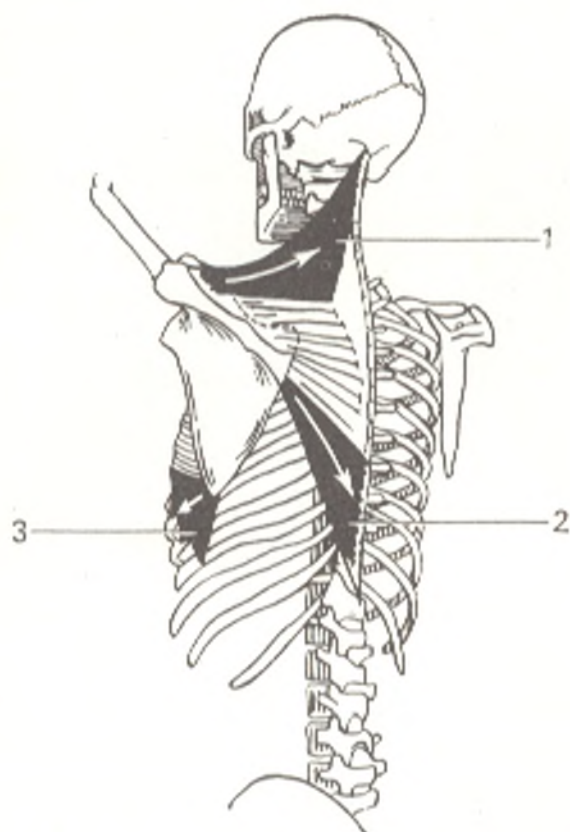


Fig. 147. Direction of muscular forces acting on the scapula in raising the arm above the horizontal position.

1, superior slips of trapezius muscle;  
2, inferior slips of trapezius muscle;  
3, m. serratus anterior

traction of the rhomboid and anterior serratus muscles and the levator muscle of the scapula. When the scapula rotates, its glenoid cavity is lifted with the humerus, which is held in its former position in relation to the vault of the shoulder by contraction of the deltoid and the supraspinous muscle. Innervation:  $C_5$ - $Th_1$ . The axillary nerve.

2. The **supraspinatus muscle** (*m. supraspinatus*) lies in the supraspinous fossa of the scapula, *arises* from this fossa, passes under the coracoacromial ligament, and *attaches* to the upper part of the greater tubercle of the humerus (see Fig. 146). The muscle is covered by a strong fascia (*fascia supraspinata*), which fuses with the edges of the supraspinous fossa to form a sheath for the muscle.

*Action.* Adducts the arm and is a synergist of the deltoid muscle. Innervation:  $C_5$ - $6$ . The suprascapular nerve.

3. The **infraspinatus muscle** (*m. infraspinatus*) occupies most of the infraspinous fossa, *arises* from it and from the infraspinous fascia and *attaches* to the greater tubercle of the humerus.

*Action.* Rotates the humerus laterally. Innervation:  $C_5$ - $6$ . The suprascapular nerve.

4. The **teres minor muscle** (*m. teres minor*) *arises* from the margo lateralis of the scapula and *attaches* to the greater tubercle of the humerus below the tendon of the infraspinous muscle.

*Action.* The same as that of the infraspinous muscle. Innervation:  $C_5$ - $Th_1$ . The axillary nerve.

The infraspinatus muscle, together with the teres minor muscle, is covered by a strong infraspinous fascia, which is fused with the spine and

borders of the scapula and invests these muscles in an osteo-fibrous sheath.

5. The **teres major muscle** (*m. teres major*) arises from the posterior surface of the inferior scapular angle and passes on the lateral border of the scapula to the crista tuberculi minoris of the humerus, to which it is attached, together with the latissimus dorsi. In man this muscle is isolated from the subscapular muscle but retains common innervation.

*Action.* Pulls the arm to the back and downward and thus adducts it and also rotates the arm medially. Innervation: C<sub>5-6</sub>. The subscapular nerves.

6. The **latissimus dorsi muscle** (*m. latissimus dorsi*) (see Fig. 124).

## B. THE VENTRAL GROUP

1. The **subscapularis muscle** (*m. subscapularis*) at its origin occupies the entire costal surface of the scapula. The wide and flat tendon of the muscle passes laterally in front of the shoulder joint and attaches to the tuberculum minus of the humerus. Between the tendon and the articular capsule is lodged the *bursa subscapularis* described above (see "The Shoulder Joint"), which communicates with the joint. The subscapular muscle is covered by the *subscapular fascia* (*fascia subscapularis*), which attaches to the margins of the subscapular fossa.

*Action.* Rotates the arm medially and can also pull the joint capsule tight and thus prevent it from incarceration. The muscles described above, which are attached to the greater tubercle of the humerus, also possess this last property because they are fused with the capsule. Innervation: C<sub>5-6</sub>. The subscapular nerves.

2. The **pectoralis major muscle** (*m. pectoralis major*) (see Fig. 124, b).

3. The **coracobrachialis muscle** (*m. coracobrachialis*) arises from the coracoid process of the scapula along with the short head of the biceps brachii and pectoralis minor and attaches by a short tendon to the medial surface of the humerus distal from the crista tuberculi minoris.

*Action.* Elevates forward and adducts the arm. Innervation: C<sub>5-7</sub>. The musculocutaneous nerve.

## MUSCLES OF THE UPPER ARM

The muscles of the upper arm retain the extremely simple form characteristic of the initial arrangement of the limb musculature and are traditionally divided into two flexors (*m. biceps* and *m. brachialis*) on the anterior surface (anterior group) and two extensors (*m. triceps* and *m. anconeus*) on the posterior surface (posterior group). These muscles are concerned with the movements at the elbow joint on the frontal axis and are, therefore, situated on the anterior and posterior surfaces of the upper arm and attach to the bones of the forearm. The two groups of muscles are separated by two connective-tissue septa (*septa intermuscularia brachii*) passing to the lateral

and medial borders of the humerus from the brachial fascia, which invests all the muscles of the arm. These septa are particularly developed on the distal end of the humerus at the epicondyles.

#### ANTERIOR MUSCLES OF THE UPPER ARM

1. The **biceps brachii muscle** (*m. biceps brachii*) (see Fig. 145) is a large muscle that is clearly visible under the skin when contracted and is, therefore, recognizable even to people unfamiliar with the study of anatomy. Proximally, the muscle consists of two heads: one long head (*caput longum*) arises from the supraglenoid tubercle of the scapula by a long tendon, which passes through the cavity of the shoulder joint and then occupies the intertubercular groove of the humerus where it is surrounded by the *vagina synovialis intertubercularis*; the other head is short (*caput breve*) and arises from the coracoid process of the scapula. Both heads unite and form an oblong, spindle-shaped belly, which terminates as a tendon attached to the tuberosity of the radius. A *synovial bursa* (*bursa bicipitoradialis*) is always found between the tendon and the tuberosity. This tendon gives rise to a flat extension (*aponeurosis m. bicipitis brachii*), which passes medially and interlaces with the fascia of the forearm.

*Action.* Flexes the forearm at the elbow joint; because it is attached to the radius, it also acts as a supinator when the forearm has been pronated. The biceps muscle passes not only over the elbow, but also over the shoulder joint and can act on it and flex the arm if the elbow joint is held fast by the contraction of the triceps muscle. Innervation: C<sub>5-7</sub>. The musculocutaneous nerve.

2. The **brachialis muscle** (*m. brachialis*) lies deeper than the biceps muscle and arises from the anterior surface of the humerus between the deltoid tuberosity and the capsule of the elbow joint, and from both septa intermuscularia brachii. The muscle then descends in front of the elbow joint and covers it and attaches to the tuberosity of the ulna.

*Action.* The brachialis muscle is a pure flexor of the elbow. Innervation: C<sub>5-6</sub>. The musculocutaneous nerve.

#### POSTERIOR MUSCLES OF THE UPPER ARM

1. The **triceps brachii muscle** (*m. triceps brachii*) (see Fig. 146) occupies the entire posterior surface of the upper arm and consists of three heads, which meet to form a single common tendon. The **long head** (*caput longum*) arises from the infraglenoid tubercle of the scapula and then descends between the teres major and teres minor muscles. The **lateral head** (*caput laterale*) arises from the posterior surface of the humerus above and laterally of the sulcus nervi radialis and, lower, from the septum intermusculare brachii laterale. The **medial head** (*caput mediale*) arises from the posterior surface of the humerus distal of the sulcus of the radial nerve and from both intermuscular septa. The wide common tendon is attached to the olecranon of the

ulna. Behind the tendon, between it and the skin in the region of the olecranon, is a *synovial bursa* (*bursa olecrani*).

*Action.* Extends the forearm at the elbow joint. Innervation: C<sub>6-8</sub>. The radial nerve.

2. The **anconeus muscle** (*m. anconeus*) is small and triangular; its proximal border adjoins the triceps muscle. *Arising* from the lateral epicondyle of the humerus and the collateral radial ligament of the elbow joint, it is *attached* by its wide base to the proximal one fourth of the posterior surface of the ulna.

*Action.* The same as that of the triceps muscle. Innervation: C<sub>7-8</sub>. The radial nerve.

## MUSCLES OF THE FOREARM

We describe these muscles with the forearm in complete supination, when the anterior and posterior surfaces and the medial (ulnar) and lateral (radial) borders can be distinguished in it. There are many forearm muscles. The flexors and extensors are classified according to action, some flexing and extending the wrist, some only the fingers; one of the extensors abducts the thumb. In addition, there are pronators and supinators which accomplish the corresponding movements of the radius. These muscles are separated into two groups according to position: the anterior group is composed of flexors and pronators, the posterior group of extensors and supinators.

Each group consists of a superficial and a deep layer. The superficial layer of the anterior group of muscles arises from the medial epicondyle of the humerus, the similar layer of the posterior group from the lateral epicondyle. The deep layer of both groups has no place for attachment on the epicondyles and so originates on the bones of the forearm and on the interosseous membrane. The terminal insertions of the flexors and extensors of the wrist are on the bases of the metacarpal bones<sup>1</sup>; muscles stretching to the fingers are inserted into the phalanges, with the exception of the long abductor muscle of the thumb, which is inserted into the first metacarpal bone. The pronators and supinators are inserted on the radius. The forearm muscles near the upper arm consist of fleshy parts, whereas toward the hand they become long tendons. As a result, the forearm is shaped like a cone flattened anteroposteriorly.

## THE ANTERIOR GROUP

The *superficial layer* is formed of the following muscles (Fig. 148).

1. The **pronator teres muscle** (*m. pronator teres*) arises from the medial epicondyle of the humerus, the medial intermuscular septum, and the tuberosity of the ulna. It descends obliquely and laterally and *attaches* to the lateral surface of the ulna directly above its middle part (Fig. 150).

<sup>1</sup> A seeming exception is the flexor carpi ulnaris, which is inserted into the pisiform bone. But this bone may be considered a sesamoid bone invested in the tendon of the flexor carpi ulnaris that reaches the fifth metacarpal bone.

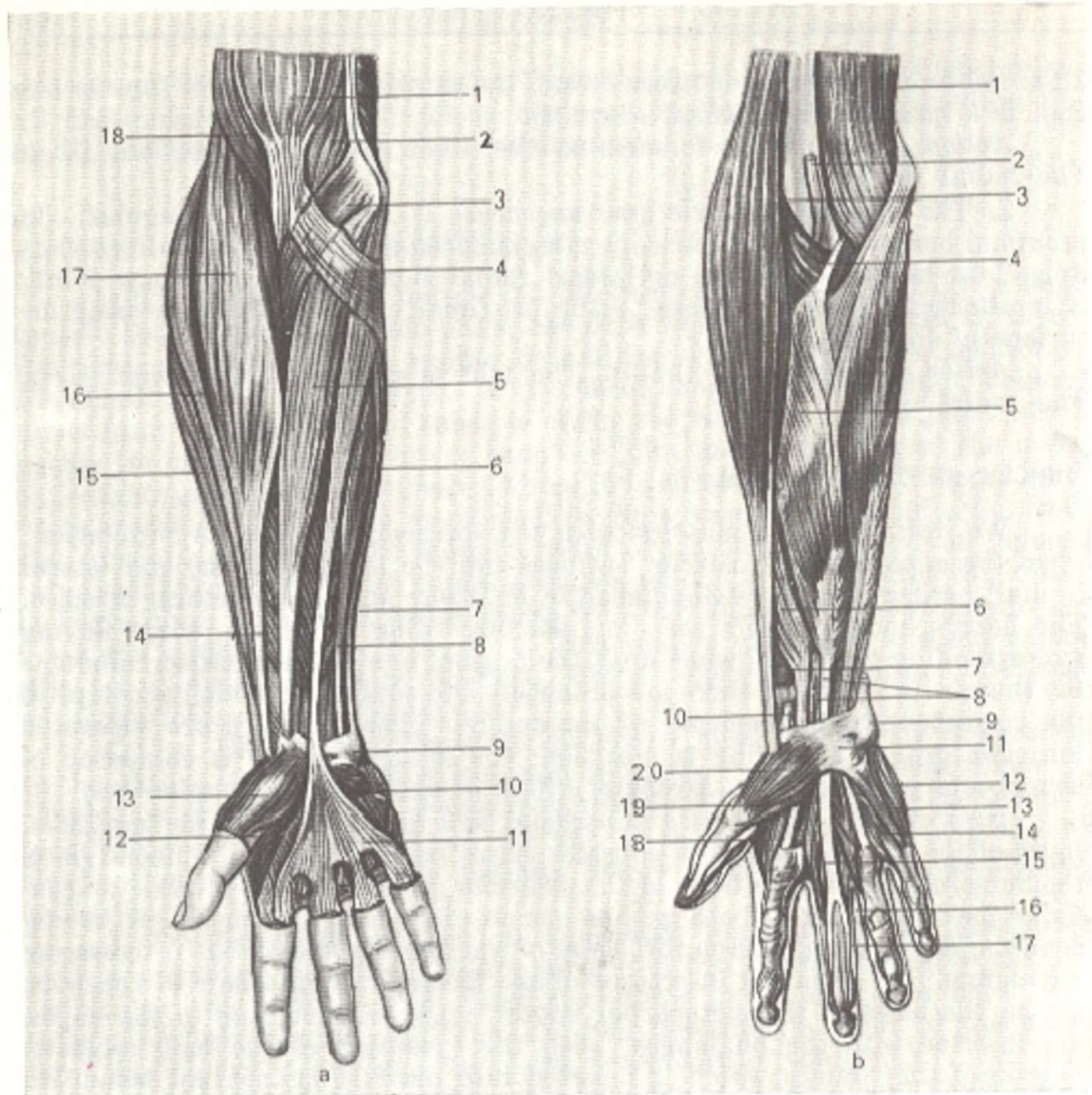


Fig. 148. Muscles of right forearm and hand.

a, superficial layer:

- 1, m. biceps brachii;
- 2, m. brachialis;
- 3, m. pronator teres;
- 4, aponeurosis m. bicipitis brachii;
- 5, m. flexor carpi radialis;
- 6, m. palmaris longus;
- 7, m. flexor carpi ulnaris;
- 8, m. flexor digitorum superficialis;
- 9, os pisiforme;
- 10, m. palmaris brevis;
- 11, aponeurosis palmaris;
- 12, m. flexor pollicis brevis;
- 13, m. abductor pollicis brevis;
- 14, m. flexor pollicis longus;
- 15, m. extensor carpi radialis brevis;
- 16, m. extensor carpi radialis longus;
- 17, m. brachioradialis;
- 18, m. brachialis.

b, deep (and part of the superficial) layer:

- 1, m. brachialis;
- 2, tendo m. bicipitis brachii;
- 3, m. brachioradialis;
- 4, m. supinator;
- 5, m. flexor digitorum superficialis;
- 6, m. flexor pollicis longus;
- 7, pronator quadratus;
- 8, tendo m. flexoris digitorum profundus;
- 9, tendo m. flexoris carpi ulnaris;
- 10, tendo m. flexoris carpi radialis;
- 11, retinaculum flexorum;
- 12, m. abductor digiti minimi;
- 13, m. flexor digiti minimi brevis;
- 14, m. opponens digiti minimi;
- 15, m. lumbricalis;
- 16, tendo m. flexoris digitorum superficialis;
- 17, tendo m. flexoris digitorum profundus;
- 18, m. adductor pollicis;
- 19, m. flexor pollicis brevis;
- 20, m. abductor pollicis brevis

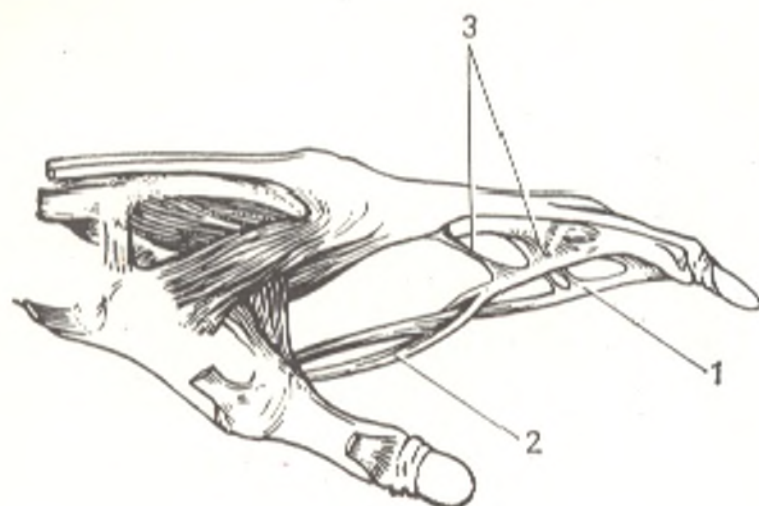


Fig. 149. Chiasma tendinum.

- 1, tendon of *m. flexor digitorum profundus*;  
 2, tendon of *m. flexor digitorum superficialis*;  
 3, vincula tendinum

*Action.* Pronates the forearm and participates in its flexion. Innervation:  $C_6-7$ . The median nerve.

2. The **flexor carpi radialis muscle** (*m. flexor carpi radialis*) is a fusiform bipennate muscle lying on the medial border of the pronator teres muscle. It arises from the medial epicondyle of the humerus and attaches to the base of the second metacarpal.

*Action.* Accomplishes plantar flexion of the wrist and can also abduct the hand radially in combination with other muscles. Innervation:  $C_6-7$ . The median nerve.

3. The **palmaris longus muscle** (*m. palmaris longus*) runs medial to flexor carpi radialis and arises from the medial epicondyle of the humerus. Its short fusiform belly ends very high in a thin long tendon, which passes over the retinaculum flexorum and blends with the *palmar aponeurosis* (*aponeurosis palmaris*). This muscle is often absent.

*Action.* Tenses the palmar aponeurosis and accomplishes plantar flexion of the wrist. Innervation:  $C_8-Th_1$ . The median nerve.

4. The **flexor carpi ulnaris** (*m. flexor carpi ulnaris*) is on the ulnar border of the forearm. It originates from the medial epicondyle of the humerus, from the posterior margin of the ulna, and from the olecranon. Its tendon is attached to the pisiform bone, which is a sesamoid bone in relation to it, and then to the hamate bone (as *lig. pisohamatum*) and the fifth metacarpal bone (as *lig. pisometacarpeum*).

*Action.* Together with the flexor carpi radialis accomplishes palmar flexion of the wrist. It also abducts the wrist in the ulnar direction together with the extensor carpi ulnaris. Innervation:  $C_8-Th_1$ . The ulnar nerve.

5. The **flexor digitorum sublimis muscle** (*m. flexor digitorum superficialis*) lies deeper than the four muscles described above. It arises from the medial epicondyle of the humerus, the coronoid process of the ulna,

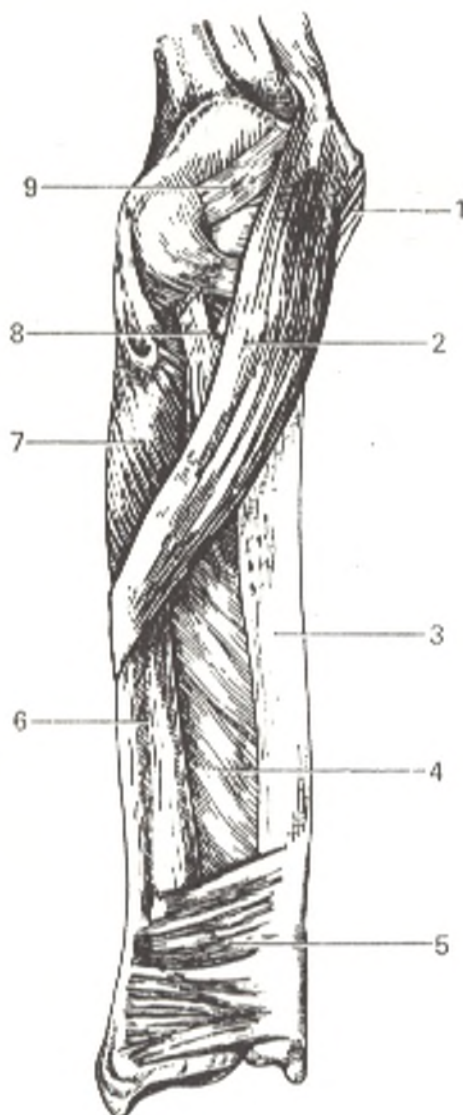


Fig. 150. Pronator and supinator muscles of right forearm (anterior aspect).

- 1, epicondylus medialis;
- 2, m. pronator teres;
- 3, ulna;
- 4, membrana interossea antebrachii;
- 5, m. pronator quadratus;
- 6, radius;
- 7, m. supinator;
- 8, tendo m. bicipitis brachii;
- 9, capsula articularis

and the upper part of the radius. The muscle separates into four long tendons, which descend from the forearm to the palm through the *canalis carpalis* and then pass to the index, middle, ring, and little fingers.

At the level of the body of the proximal phalanx, each tendon splits into two parts which separate to form a gap called the *hiatus tendineus*. The tendon of the deep flexor passes through the gap and crosses the other tendons (*chiasma tendinum*), which then *attach* to the palmar surface of the base of the middle phalanx (Figs. 148 and 149).

*Action.* Flexes the proximal and middle phalanges of the fingers (except for the thumb) and the wrist. Innervation:  $C_8$ - $Th_1$ . The median nerve.

The *deep layer* (see Fig. 148, *b*).

6. The **flexor pollicis longus** muscle (*m. flexor pollicis longus*) arises from the anterior surface of the radius distal to the radial tuberosity and often from the medial epicondyle of the humerus. Its long tendon passes under the *retinaculum flexorum* onto the palm and, in the groove between the two heads of *m. flexor pollicis brevis*, passes to the base of the second phalanx of the thumb.



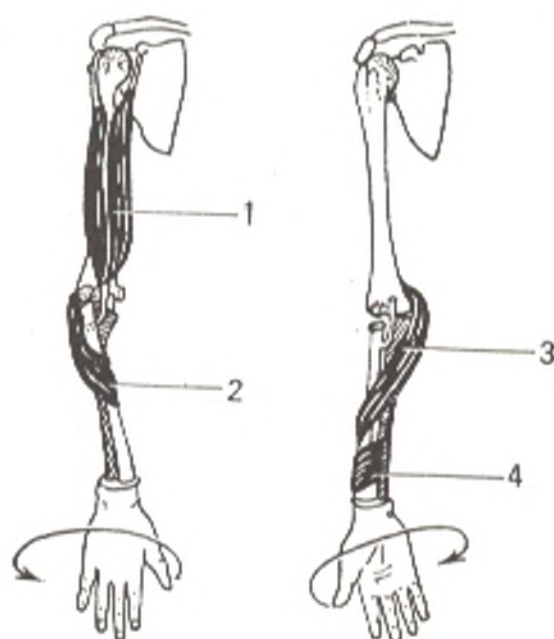


Fig. 151. Pronators (right) and supinators (left) of forearm.

- 1, m. pronator teres;  
 2, m. pronator quadratus;  
 3, m. biceps brachii;  
 4, m. supinator

*Action.* Flexes the distal phalanx of the thumb and also the wrist. Innervation:  $C_{6-7}$ . The median nerve.

7. The **flexor digitorum profundus** muscle (*m. flexor digitorum profundus*) originates from the ulna and the interosseous membrane. Its four tendons arising from the belly in the middle of the forearm pass through the canalis carpalis, onto the palm under the tendons of the superficial flexor, and then to all the fingers with the exception of the thumb. Each of these tendons enters the hiatus tendineus between the two parts of the tendon of the flexor digitorum superficialis, crosses it, and attaches to the distal phalanx.

*Action.* Flexes the middle and distal phalanges of the index, middle, ring, and little fingers, and also assists in flexion of the wrist. Innervation:  $C_7-Th_1$ . The median and ulnar nerves.

8. The **pronator quadratus** muscle (*m. pronator quadratus*) (see Fig. 150) is a flat quadrangular muscle lying directly on both forearm bones and on the interosseous membrane immediately above the wrist joints. The fibres of the muscle arise on the palmar surface of the ulna, pass laterally and slightly downward, and attach on the palmar surface of the radius.

*Action.* This muscle is the main pronator of the forearm, while the pronator teres is an auxiliary pronator (Fig. 151). Innervation:  $C_6-Th_1$ . The median nerve.

## THE POSTERIOR GROUP

The superficial layer of the posterior muscles can be divided into two subgroups, radial and ulnar. The first occupies the anterolateral surface of the forearm, while the second occupies the posterior surface.

### The Radial Group of the Superficial Layer

1. The **brachioradialis muscle** (*m. brachioradialis*) lies on the lateral border of the forearm. It arises from the lateral border of the humerus and the lateral intermuscular septum between the brachial and triceps muscles. Its expanding belly descends in front of the radius and ends in the middle

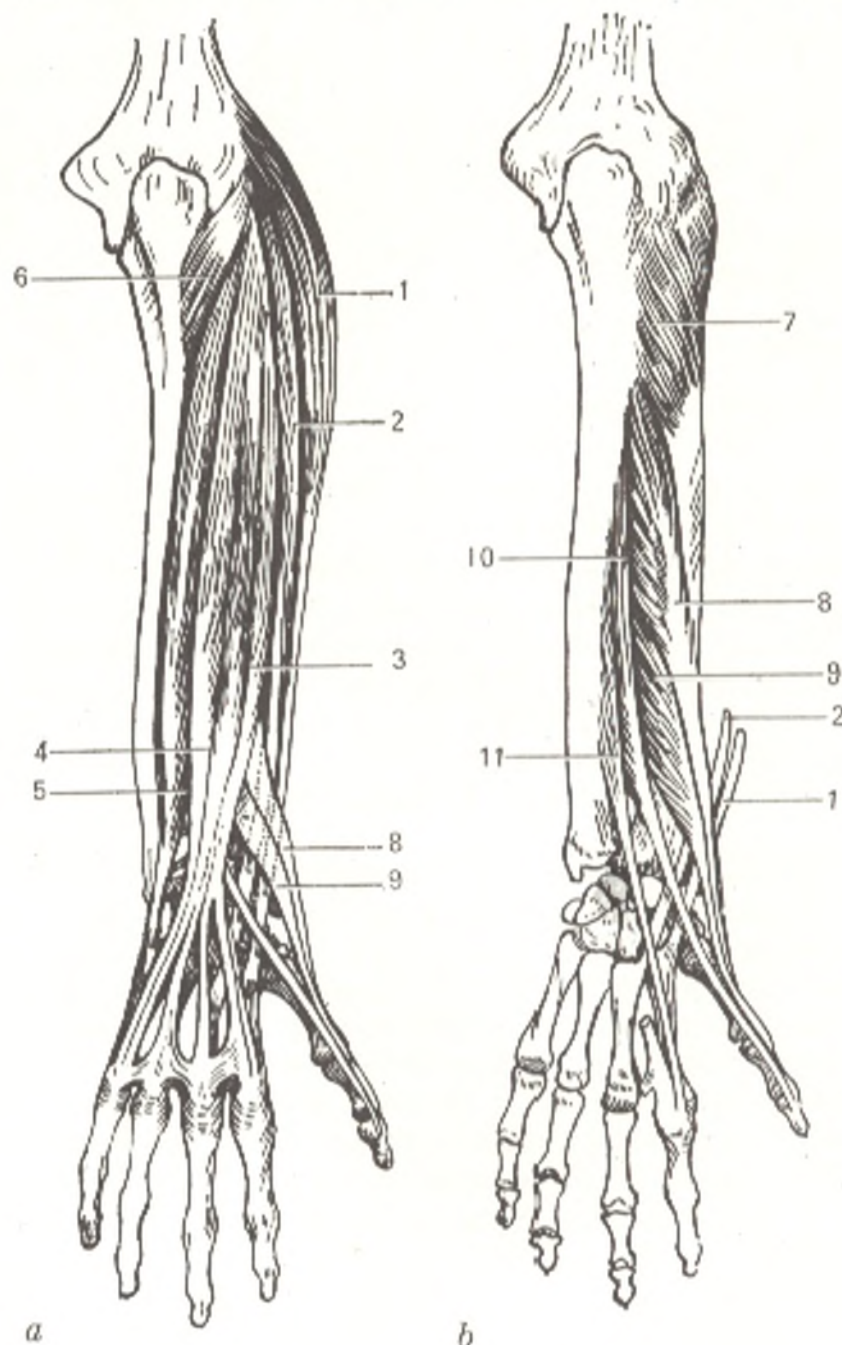


Fig. 152. Posterior muscles of right forearm.

a, superficial layer;  
 b, deep layer;  
 1, m. extensor carpi radialis longus;  
 2, m. extensor carpi radialis brevis;  
 3, extensor digitorum;  
 4, m. extensor digiti minimi;  
 5, m. extensor carpi ulnaris;

6, m. anconeus;  
 7, m. supinator;  
 8, m. abductor pollicis longus;  
 9, m. extensor pollicis brevis;  
 10, m. extensor pollicis longus;  
 11, m. extensor indicis

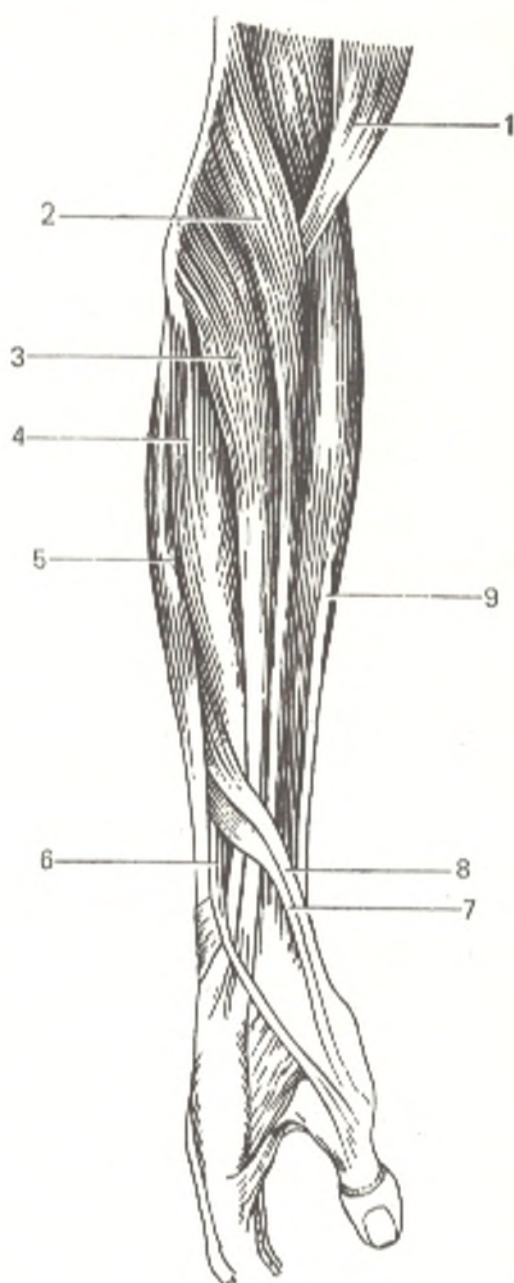


Fig. 153. Muscles of radial side of forearm.

- 1, m. biceps brachii;  
 2, m. brachioradialis;  
 3, m. extensor carpi radialis longus;  
 4, m. extensor carpi radialis brevis;  
 5, m. extensor digitorum;  
 6, m. extensor pollicis longus;  
 7, m. extensor pollicis brevis;  
 8, m. abductor pollicis longus;  
 9, m. flexor digitorum superficialis

of the forearm in a long flat tendon, which *attaches* to the radius above the styloid process. Medially it borders upon the pronator teres and the flexor carpi radialis muscles.

*Action.* Flexes the forearm at the elbow joint and sets the radius in a position intermediate between pronation and supination (the forearm and hand are usually held in this position when the limb is hanging limp). *Innervation:* C<sub>5-6</sub>. The radial nerve.

2. The **extensor carpi radialis longus** (*m. extensor carpi radialis longus*) is lateral to and behind the brachioradialis muscle and originates from the lateral border and lateral epicondyle of the humerus and from the lateral intermuscular septum. In the middle of the forearm, the muscle ends in a tendon, which passes on the lateral surface of the radius, then under the

retinaculum extensorum, and *attaches* to the dorsal surface of the base of the second metacarpal bone.

*Action.* Flexes the forearm and accomplishes dorsal flexion and radial abduction of the wrist joint (the last action is performed together with the flexor carpi radialis). Innervation: C<sub>6-7</sub>. The radial nerve.

3. The **extensor carpi radialis brevis muscle** (*m. extensor carpi radialis brevis*) lies behind the long radial extensor of the wrist and *arises* from the lateral epicondyle of the humerus and the capsule of the elbow joint. Its tendon accompanies the tendon of the long radial extensor of the wrist, both crossing the abductor pollicis longus and the extensor pollicis brevis in the distal one third of the forearm and the tendon of the extensor pollicis longus on the hand. They then pass through a common (second) fibrous canal under the retinaculum extensorum, and the tendon of the extensor carpi radialis brevis *attaches* to the dorsal surface of the base of the third metacarpal bone. A small synovial bursa lies under the tendon (Figs. 152 and 153).

*Action.* The same as that of the extensor carpi radialis longus. Innervation: C<sub>6-7</sub>. The radial nerve.

#### The Ulnar Group of the Superficial Layer

4. The **extensor digitorum muscle** (*m. extensor digitorum*) stretches on the posterior surface of the forearm. It *arises* with the extensor carpi radialis brevis from the lateral epicondyle. In the middle of the forearm, the muscle separates into four bellies, each ending in a long tendon. The tendons descend to the dorsal surface of the hand, pass under the retinaculum extensor through the fourth canal and then diverge toward the four fingers (with the exception of the thumb). On the dorsal surface of the hand near the metacarpophalangeal joints, the tendons are joined by means of oblique fibrous bands, *intertendinous connexion* (*conexus intertendineus*), with the result that the middle and ring fingers can be extended only jointly; the index finger and partly the little finger retain their independence because they have their own extensors. On the dorsal surface of each finger each tendon of the common extensor forms a triangular tendinous expansion separating into three slips; a middle slip is *attached* to the base of the middle phalanx and two colateral slips are attached to the base of the distal phalanx.

*Action.* Extends the index, middle, ring, and little fingers and accomplishes dorsal flexion of the wrist. Innervation: C<sub>6-8</sub>. The radial nerve.

5. The **extensor digiti minimi muscle** (*m. extensor digiti minimi*) branches off from the common extensor of the fingers on its ulnar side. Its long tendon passes through the fifth canal under the retinaculum extensorum to the dorsal surface of the hand, to the little finger, and joins the tendon of the common extensor that reaches this finger.

*Action.* Extends the little finger. Innervation: C<sub>6-8</sub>. The radial nerve.

6. The **extensor carpi ulnaris muscle** (*m. extensor carpi ulnaris*), whose lateral border adjoins the common extensor and the extensor of the little finger, *arises* with these muscles from the lateral epicondyle of the humerus

and from the posterior border of the ulna. The tendon of the muscle passes through the sixth tendinous canal under the retinaculum extensorum and *attaches* to the base of the fifth metacarpal bone (tuberositas ossis metacarpi V).

*Action.* Accomplishes dorsal flexion of the wrist and abducts it to the ulnar side; the last action is performed with the flexor carpi ulnaris. Innervation: C<sub>7-8</sub>. The radial nerve.

### The Ulnar Group of the Deep Layer

7. The **supinator muscle** (*m. supinator*) is in the superolateral part of the forearm. It is covered by the brachioradialis muscle and by both radial extensors of the wrist. The supinator muscle *arises* from the lateral epicondyle of the humerus, the radial collateral ligament of the elbow joint, and the upper end of the ulna. It *embraces* the proximal end of the radius above and below the radial tuberosity.

*Action.* The muscle is a pure supinator of the forearm. Innervation: C<sub>5-6</sub>. The radial nerve.

8 and 9. The **abductor pollicis longus muscle** (*m. abductor pollicis longus*) and the **extensor pollicis brevis muscle** (*m. extensor pollicis brevis*) arise next to each other, the long muscle above the short, from the posterior surface of the radius, the interosseous membrane, and partly from the ulna.

Lying together, they pass distally and laterally, emerge from under the radial border of the common extensor of the fingers, and pass through the first canal under the retinaculum extensorum to the thumb; the tendon of the abductor pollicis longus is *attached* partly to the base of the first metacarpal bone and partly to a tendinous slip of the abductor pollicis brevis, while the tendon of the extensor pollicis brevis is attached to the base of the proximal phalanx of the thumb (Fig. 152).

*Action.* The abductor pollicis longus abducts the thumb and abducts the wrist radially; the extensor pollicis brevis extends the proximal phalanx of the thumb. Innervation: C<sub>6-7</sub>. The radial nerve.

10. The **extensor pollicis longus muscle** (*m. extensor pollicis longus*) *arises* from the middle one third of the posterior surface of the ulna and the interosseous membrane, emerges as a tendon from under the common extensor of the fingers below the preceding two muscles, crosses the tendons of both radial extensors of the wrist obliquely, passes under the retinaculum extensorum in the third canal and then to the dorsal surface of the thumb, where it is *attached* to the base of the second phalanx. A hollow, called the **anatomical snuffbox**, forms on the radial side of the wrist joint between the tendon of the extensor pollicis longus and the tendons of the extensor pollicis brevis and abductor pollicis longus.

*Action.* Extends the thumb by pulling it dorsally. Innervation: C<sub>7-8</sub>. The radial nerve.

11. The **extensor indicis muscle** (*m. extensor indicis*) *arises* from the distal one third of the posterior surface of the ulna. Its tendon passes with the tendons of the common extensor of the fingers through the fourth canal

under the retinaculum extensorum. There it *joins* the ulnar side of the tendon of the common extensor passing to the index finger and is continuous with the dorsal tendinous expansion of this finger.

*Action.* Extends the index finger. Innervation: C<sub>7-8</sub>. The radial nerve.

## MUSCLES OF THE HAND

In addition to the tendons of the forearm muscles passing on the dorsal and palmar surfaces of the hand, there are short muscles of the hand proper, which arise and are inserted in this part of the upper limb. Three groups of these muscles can be distinguished. Two of them, located on the radial and ulnar borders of the palm, form the **thenar eminence** (*thenar*) and the **hypothenar eminence** (*hypothenar*); the third (middle) group is situated in the hollow of the hand (*palma manus*). The muscles of the human hand, which, as the organ of labour, is the most important part of the upper limb, are extremely well developed. As compared to the thumb of anthropoid apes the muscles of the human thumb are so highly developed, that the thumb is maximally apposable, i.e. the tip of the thumb can reach the joints of the little finger when the fingers are flexed in a fist. The extensors are also highly developed in man, and each finger can be fully extended. As a result, the hand and each finger are capable of maximum flexion and extension, which is necessary in work.

### THE THENAR MUSCLES

1. The **abductor pollicis brevis muscle** (*m. abductor pollicis brevis*) lies more superficially than the other muscles. Its fibres *arise* from the retinaculum flexorum and the tubercle of the scaphoid body and converge to be *attached* to the radial surface of the base of the proximal phalanx of the thumb.

*Action.* Abducts the thumb at the carpometacarpal joint. Innervation: C<sub>6-7</sub>. The median nerve.

2. The **flexor pollicis brevis muscle** (*m. flexor pollicis brevis*) has two heads. The superficial head *arises* from the retinaculum flexorum, stretches along the ulnar border of the thenar, and then becomes narrower and *attaches* to the radial sesamoid bone of the metacarpophalangeal joint of the thumb. The deep head *arises* from the trapezium, trapezoid, and capitate bones and *attaches* primarily to the ulnar sesamoid bone and to the base of the proximal phalanx of the thumb and, by a small slip, to the radial sesamoid bone. The groove formed between the two heads transmits the tendon of the flexor pollicis longus (Figs. 154 and 155).

*Action.* Flexes the proximal phalanx of the thumb and assists opposition of the thumb. Innervation: C<sub>8</sub> and Th<sub>1</sub>. The ulnar nerve.

3. The **opponens pollicis muscle** (*m. opponens pollicis*) lies along the radial border of the thenar under the abductor pollicis brevis. It *arises* from the retinaculum flexorum and the tubercle of the trapezium and *attaches* to the radial border of the first metacarpal bone.

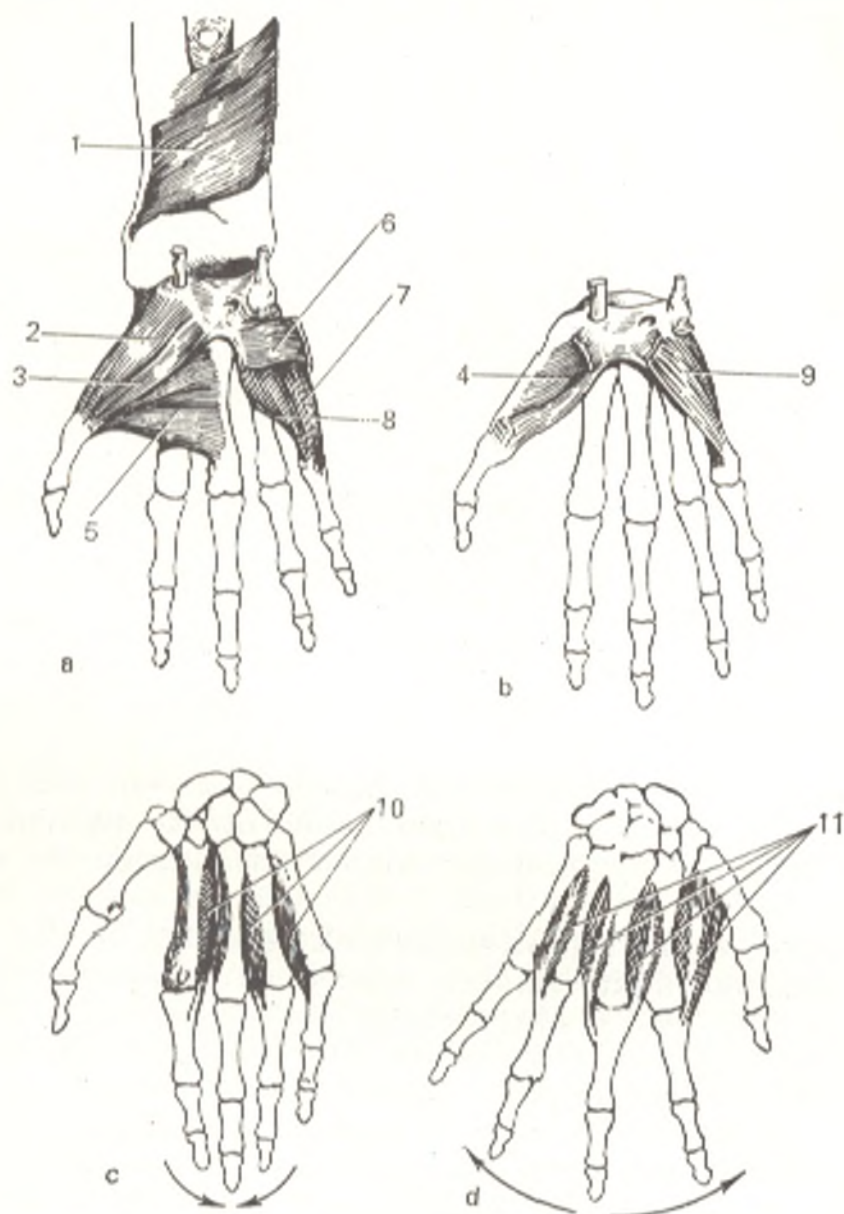


Fig. 154. Muscles of the hand (right side).

a and b, muscles of the thumb  
and little finger;  
c and d, interosseous muscles  
(the arrows show their action):  
1, m. pronator quadratus;  
2, m. abductor pollicis brevis;  
3, m. flexor pollicis brevis;  
4, m. opponens pollicis;

5, m. adductor pollicis;  
6, m. palmaris brevis;  
7, m. abductor digiti minimi;  
8, m. flexor digiti minimi brevis;  
9, m. opponens digiti minimi;  
10, mm. interossei palmares;  
11, mm. interossei dorsales

*Action.* Opposes the thumb by pulling its metacarpal bone to the palm.  
*Innervation:* C<sub>6-7</sub>. The median nerve.

4. The **adductor pollicis muscle** (*m. adductor pollicis*) lies deep in the palm. Its wide base *arises* from the palmar surface of the third metacarpal bone. The muscle then passes in front of the second intermetacarpal space

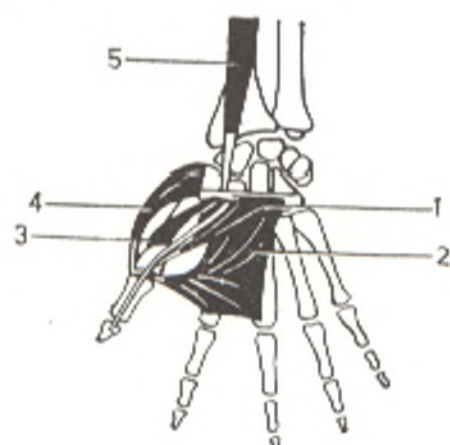


Fig. 155. Schematical representation of the muscles of the thumb.

- 1, m. flexor pollicis brevis;  
 2, m. adductor pollicis;  
 3, m. opponens;  
 4, m. abductor pollicis brevis;  
 5, m. flexor pollicis longus

and the second metacarpal bone, narrows, and *attaches* to the ulnar sesamoid bone and to the base of the proximal phalanx of the thumb.

*Action.* Adducts and assists in opposition of the thumb. Innervation:  $C_8$  and  $Th_1$ . The ulnar nerve.

#### THE HYPOTHENAR MUSCLES

1. The **short palmar muscle** (*m. palmaris brevis*) lies superficially under the skin. It *arises* from the ulnar border of the palmar aponeurosis and from the flexor retinaculum and *ends* in the skin on the ulnar border of the palm.

*Action.* Tenses the palmar aponeurosis. Innervation:  $C_8$ . The ulnar nerve.

2. The **abductor digiti minimi muscle** (*m. abductor digiti minimi*) stretches superficially on the ulnar border of the hypothenar. It *arises* from the flexor retinaculum and the pisiform bone and is *inserted* into the ulnar border of the base of the proximal phalanx of the little finger.

*Action.* Abducts the little finger. Innervation:  $C_8$  and  $Th_1$ . The ulnar nerve.

3. The **flexor digiti minimi brevis muscle** (*m. flexor digiti minimi brevis*) is situated on the radial border of the preceding muscle. It *originates* from the retinaculum flexorum and the hook of the hamate bone and *attaches* to the base of the proximal phalanx of the little finger (Fig. 154).

*Action.* Flexes the proximal phalanx of the little finger. Innervation:  $C_{7-8}$ . The ulnar nerve.

4. The **opponens digiti minimi muscle** (*m. opponens digiti minimi*) is almost completely covered by the preceding two muscles. It *arises* from the flexor retinaculum and from the hook of the hamate bone and *attaches* to the ulnar border of the fifth metacarpal bone.

*Action.* Draws the little finger toward the thumb (opposition). Innervation:  $C_{7-8}$ . The ulnar nerve.

#### MUSCLES OF THE HOLLOW OF THE HAND

1. The **lumbrical muscles** (*m. lumbricales*) are four narrow muscular slips lodged between the tendons of the deep flexor of the fingers, from which



Fig. 156. Arrangement of the interosseous muscles, represented schematically. Left, dorsal muscles; right, palmar muscles



they arise. Two radial muscles originate from the radial border of the corresponding tendons, while two ulnar muscles arise from adjacent sides of the second, third, and fourth tendons of the deep flexor. Passing to the fingers, the lumbrical muscles curve around the heads of the metacarpal bones on the radial side and attach on the dorsal surface of the proximal phalanx to the tendinous expansion of the common extensor of the fingers (see Fig. 148).

*Action.* The muscles flex the proximal phalanges and extend the middle and distal phalanges of the index, middle, ring, and little fingers. Innervation:  $C_8$ - $Th_1$ . The two radial muscles are innervated by branches from the median nerve, the two ulnar muscles from the ulnar nerve.

2. The **palmar interossei muscles** (*mm. interossei palmares*) occupy the spaces between the metacarpal bones and are separated into palmar and dorsal muscles (Figs. 154 and 156). Innervation: the ulnar nerve.

These muscles are adductors and abductors of the fingers in relation to the midline, and they are naturally grouped around the middle finger. Thus, the three **palmar interossei muscles** (*mm. interossei palmares*), are adductors; they radiate from the midline, i.e. from the third metacarpal bone, and attach, therefore, to the dorsal tendinous expansion of the extensor digitorum on the index, ring, and little fingers. The thumb is adducted by its own adductor (adductor pollicis), which serves as a substitute for a fourth palmar interosseous muscle. The four **dorsal muscles** (*mm. interossei dorsales*) are abductors; they converge toward the third metacarpal bone and attach to the index, middle, and ring fingers. The thumb and the little finger have their own abductors. All interosseous muscles, in addition, flex the proximal phalanx and extend the middle and distal phalanges wormlike. Thus, each phalanx of each finger has one or even two separate muscles moving it; for example, the proximal phalanx of each finger is flexed by the lumbrical and the palmar interosseous muscles, the middle phalanx by the superficial flexor of the fingers, and the distal phalanx by the deep flexor of the fingers.

This specialization of the muscles and their tendons is less pronounced in the ape than in man. The greater specialization lends the muscles greater independence of movement.

## FASCIAE OF THE UPPER LIMB AND THE TENDON SHEATHS

The deltoid muscle lying in the region of the shoulder is covered by a thin **deltoid fascia** (*fascia deltoidea*), which gives off processes projecting between the muscular bundles. This fascia is continuous anteriorly with the pectoral fascia and posteriorly with the superficial fascia of the back. Distally it blends with the brachial fascia. The **brachial fascia** (*fascia brachii*), which forms a tubular investment for the muscles of the upper arm, is quite thin.

On both sides the brachial fascia gives off two fibrous intermuscular septa: the *septa intermuscularis brachii*, which project deeply and separate the anterior muscles from the posterior (Fig. 157). The *medial septum* (*septum intermusculare brachii mediale*) passes between the brachial and the triceps muscles and attaches to the osseous crest above the medial epicondyle of the humerus. The *lateral septum* (*septum intermusculare brachii laterale*) passes on the other border of the upper arm between the brachial and triceps muscles and distally between the triceps and the brachioradial muscles. It fuses with the crest on the lateral border of the humerus above the lateral epicondyle. In the bend of the arm, the fascia is continuous with the forearm fascia (*fascia antebrachii*) and has a thickened band here, which is part of the tendon of the biceps muscle, *aponeurosis m. bicipitis brachii* (see p. 336). The

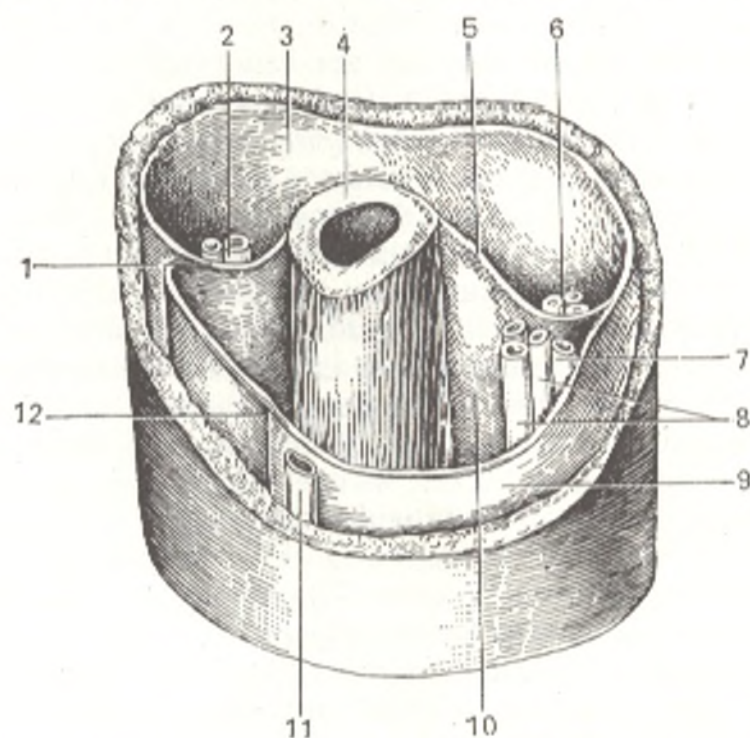


Fig. 157. Fasciae and fascial sheaths of the upper arm.

1, septum intermusculare laterale;  
2, a. collateralis radialis and n. radialis;  
3, sheath of m. tricipitis brachii;  
4, humerus;  
5, septum intermusculare mediale;  
6, a. collateralis ulnaris superior and  
n. ulnaris;  
7, v. basilica;

8, a. brachialis and n. medianus;  
9, fascia brachii;  
10, sheath of m. biceps brachii and  
m. brachialis;  
11, v. cephalica;  
12, groove between the heads of the  
biceps muscle

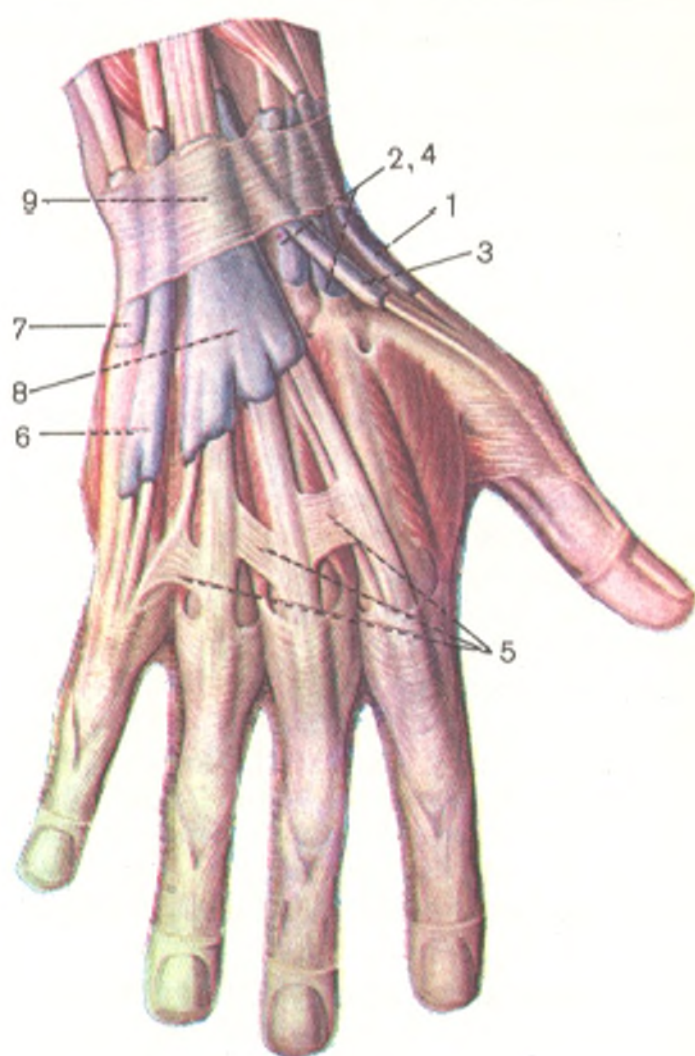


Fig. 158. Synovial sheaths on dorsal surface of the hand. Sheaths for the tendons of the muscles.

- 1, vagina tendinum mm. abductoris longi and extensoris brevis pollicis;
- 2 and 4, vagina tendinis mm. extensorum carpi radialis;
- 3, vagina tendinis m. extensoris pollicis longi;
- 5, connexus intertendineus;
- 6, vagina tendinis m. extensoris digiti minimi;
- 7, vagina tendinis m. extensoris carpi ulnaris;
- 8, vagina tendinum mm. extensoris digitorum and extensoris indicis;
- 9, retinaculum extensorum

**antebrachial fascia** (*fascia antebrachii*) invests the forearm muscles and produces fibrous septa which project between them. It also fuses with the epicondyles of the humerus and the posterior border of the ulna.

On its dorsal border with the hand, the antebrachial fascia forms a transverse thickening in the form of a ligament, which is called the *extensor retinaculum* (*retinaculum extensorum*). Processes from the retinaculum fuse with the dorsal surface of the radius and ulna. Between these processes, under the ligament, are six *canals*, which are partly *osteofibrous* (Fig. 158) and partly *fibrous*. These canals transmit the tendons of the finger and wrist extensors. If we count from the radial to the ulnar border the *first* canal transmits the tendons of the abductor pollicis longus and the extensor pollicis brevis. The *second* canal (sometimes a double canal) transmits the tendons of the extensors carpi radiales longus and brevis. The *third*, crossing the preceding canal obliquely, transmits the tendon of the extensor pollicis longus. The *fourth* canal transmits the tendons of the extensor digitorum and the extensor indicis, while the *fifth* canal, situated more superficially, transmits the tendon of the extensor digiti minimi. Finally, the *sixth* canal transmits the tendon of the carpi ulnaris. The walls of the canals are lined with a sy-

novial membrane, which, above and below the extensor retinaculum, folds over the tendons and covers them, forming the **tendon sheaths** (*vaginae tendinum*) of the dorsal muscles. The number of sheaths corresponds to the number of canals. The sheaths protrude on the dorsal surface of the hand from under the extensor retinaculum.

The considerably thickened fascia in the middle of the palm forms a strong **palmar aponeurosis** (*aponeurosis palmaris*), which is an extension of the tendon of the long palmar muscle. The palmar aponeurosis is triangular, with the apex lying on the flexor retinaculum and the base directed to the fingers, where it separates into four flat slips between which *transverse fibres* (*fasciculi transversi*) stretch. Under the aponeurosis is a flat, fibrous ligament restraining the flexor tendons and hence called the *flexor retinaculum* (*retinaculum flexorum*). Where the borders of the palmar aponeurosis are continuous with the thin fascia ensheathing the thenar and hypothenar, the palmar aponeurosis gives off fascial layers that deeply project and fuse with the deep palmar fascia covering the interosseous muscles. A receptacle is thus formed in the middle part of the palm for the tendons of the flexors and the lumbrical muscles. Besides the deep palmar fascia, there is still another fascia, which covers the interosseous muscles on the dorsal surface of the hand and fuses with the periosteum of the metacarpal bones. This is the **dorsal fascia of the hand** (*fascia dorsalis manus*).

## TOPOGRAPHY OF THE UPPER LIMB

**Topography of the axillary region** (*regio axillaris*), or **fossa** (*fossa axillaris*). During abduction of the arm, the **axilla**, or the **axillary fossa**, is clearly visible. It is bounded (with the arm abducted) inferiorly by the greater pectoral muscle in front and by the latissimus dorsi and teres major muscles behind, medially by an imaginary line connecting the borders of these muscles on the chest, and laterally by a line connecting these borders on the inner surface of the upper arm. If the fascia that, together with the skin, form the floor of the axilla, is removed, access is gained into the **axillary cavity** (*cavum axillare*). Its *anterior* wall is formed by the greater and smaller pectoral muscles, the *posterior* wall by the latissimus dorsi, teres major, and subscapular muscles. The *medial* wall is formed by the anterior serrate muscle, and the *lateral* wall is formed by the humerus and the coracobrachial muscle and the short head of the biceps muscle covering it.

Inferiorly, the axillary cavity ends in an opening. Superiorly, it narrows and communicates with the region of the neck. The cavity is filled with fatty tissue containing nerves, vessels, and lymph nodes. To facilitate more exact description of the topography of the vessels and nerves, the anterior wall of the axillary cavity is traditionally divided into three triangles, arranged one on top of the other. The *upper triangle* (*trigonum clavipectorale*) is formed by the clavicle and the superior border of the smaller pectoral muscle. The *middle triangle* (*trigonum pectorale*) corresponds to the smaller pectoral muscle. The *lower triangle* (*trigonum subpectorale*) is bounded by

the inferior border of the smaller pectoral muscle, the inferior border of the greater pectoral muscle, and the deltoid muscle.

On the posterior wall of the axillary cavity is a triangular space formed by the surgical neck of the humerus (laterally), the teres major muscle (inferiorly), and the subscapular muscle (superiorly). This space is divided vertically by the long head of the triceps muscle into two openings (see Fig. 146).

1. The lateral, *quadrangular opening* (space) (*foramen quadrilaterum*) is formed by the teres major and subscapular muscles and by the bone. It transmits the posterior circumflex humeral artery and the axillary nerve.

2. The medial, *triangular opening* (space) (*foramen trilaterum*) is bounded only by the teres major and subscapular muscles. It transmits the circumflex scapular artery.

Spaces, canals, and grooves (sulci) form between the muscles, fasciae, and bones of the upper limb and lodge various vessels and nerves. Knowledge of their location is important in surgery.

The sulcus of the radial nerve of the humerus is covered by the triceps muscle, and thus converted in a canal (*canalis humeromuscularis*, s. *canalis n. radialis*, s. *canalis spiralis*). It transmits the radial nerve and the attendant deep brachial artery and vein.

Two grooves, the **medial bicipital groove** and **lateral bicipital groove** (*sulcus bicipitalis medialis* and *sulcus bicipitalis lateralis*) are located on the anterior surface of the humerus, between the brachial muscle and the borders of the biceps. The deeper, medial sulcus lodges the neurovascular bundle of the arm.

In front of the elbow joint, in the bend of the arm, is the **cubital fossa** (*fossa cubitalis*), bounded by the brachioradial muscle (laterally) and the pronator teres muscle (medially). The floor and superior border of the fossa are formed by the brachial muscle.

There are three grooves between the forearm muscles.

1. The **medial, ulnar groove** (*sulcus n. ulnaris*) lies between m. flexor carpi ulnaris (medially) and m. flexor digitorum superficialis (laterally). It transmits the ulnar nerve, artery, and veins.

2. The **lateral, radial groove** (*sulcus n. radialis*) lies between m. brachioradialis (laterally) and m. flexor carpi radialis (medially). It transmits the radial nerve, artery, and veins.

3. The **median groove** (*sulcus medianus*) lies between the flexor carpi radialis (laterally) and the flexor digitorum superficialis (medially). It transmits the median nerve.

In the region of the wrist joint, *three canals* form as a result of the flexor retinaculum nearby. Bridging the space between the eminentia carpi ulnaris and eminentia carpi radialis, the flexor retinaculum converts the groove between these eminences, the carpal sulcus (*sulcus carpi*), into the **carpal canal or tunnel** (*canalis carpalis*). Then separating and running to the radial and ulnar sides, the flexor retinaculum forms, respectively, the **canalis carpi radialis** and **canalis carpi ulnaris**. The ulnar nerves and vessels that extend from the sulcus ulnaris of the forearm pass in the ulnar canal (tun-

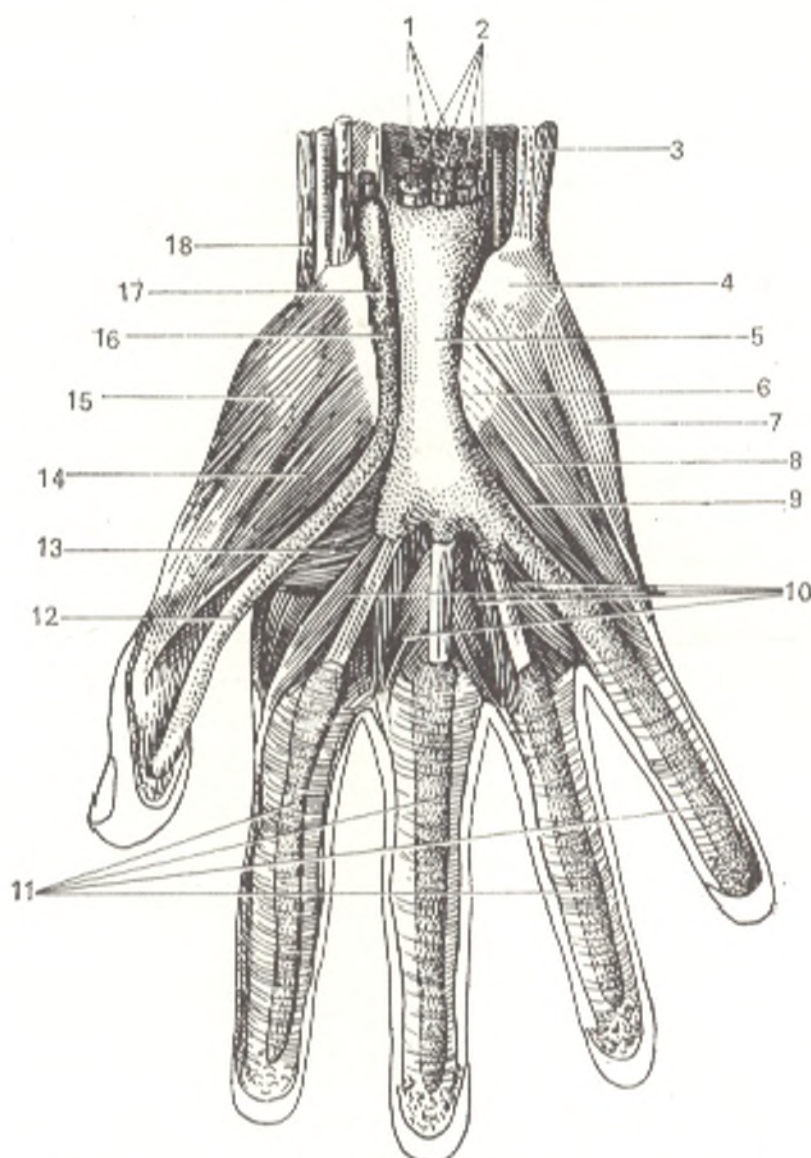


Fig. 159. Synovial sheaths on palmar surface of the hand.

1, 2, 3, and 18, muscles of forearm;  
 4, os pisiforme;  
 5, vag. synov. comm. mm. flexorum;  
 6, retinaculum flexorum (cut off);  
 7, m. abductor digiti minimi;  
 8, m. flexor digiti minimi brevis;  
 9, m. opponens digiti minimi;

10, mm. lumbricales;  
 11, vag. synov. tendinum digitorum;  
 12, 16, and 17, vagina tendinis m.  
 flexoris pollicis longi;  
 13, m. adductor pollicis;  
 14, m. flexor pollicis brevis;  
 15, m. abductor pollicis brevis

nel). The tendon of the flexor carpi radialis ensheathed in a synovial sheath lies in the canalis carpi radialis. Finally, in the canalis carpalis are two separate synovial sheaths, one for the tendons of mm. flexores digitorum superficialis and profundus, the other for the tendon of m. flexoris pollicis longus (Fig. 159). The first, the **common synovial sheath of the flexor tendons** (*vag. synovialis communis mm. flexorum*) is a large medially located sac enclosing eight tendons of the deep and superficial flexors of the fingers. Superiorly, it protrudes 1-2 cm proximally of the flexor retinaculum, while inferiorly it reaches the middle of the palm. The sheath continues only on the tendons

of the long flexors of the little finger, surrounds them, and reaches, together with them, the base of the distal phalanx of the little finger.

The second, the **synovial sheath of the long flexor muscle of the thumb** (*vag. tendinis m. flexoris pollicis longi*) is situated laterally. This long, narrow canal encloses the tendon of the long flexor muscles of the thumb. Superiorly, this sheath also protrudes 1-2 cm proximally of the flexor retinaculum, while inferiorly it extends on the tendon to the base of the distal phalanx of the thumb. The remaining three fingers have separate sheaths, **synovial sheaths of the tendons of the hand, digital** (*vaginae synoviales tendinum digitorum [manus]*), enclosing the tendons of the flexors of the corresponding finger. These sheaths stretch from the line of the metacarpophalangeal joints to the base of the distal phalanges. Consequently, the index, middle, and ring fingers have isolated sheaths for the tendons of their common flexors on the palmar surface but are devoid of these sheaths in the segment corresponding to the distal halves of the metacarpal bones.

It has been suggested recently that the common synovial sheath of the flexor tendons encloses the tendon of the little finger but does not surround completely the tendons of the index, middle, and ring fingers; it is believed that the sheath forms three protrusions, one in front of the tendons of the superficial flexors, another between them and the tendons of the deep flexor, and the third behind these tendons. The ulnar synovial sheath is, therefore, a true synovial sheath only for the tendons of the little finger.

The *synovial sheaths* on the palmar surface of the fingers are covered by a dense, fibrous lamina that fuses with the ridges on the edges of the phalanges and forms an osteofibrous canal on each finger, which surrounds the tendons and their sheath. The fibrous walls of the canal are very thick near the phalangeal shafts, where they form transverse thickenings (*pars anularis vaginae fibrosae*). They are much thinner near the joints and are strengthened by bundles of connective tissue (*pars cruciformis vaginae fibrosae*) which intersect obliquely. The tendons are connected with the walls of the enclosing sheaths by a thin mesotendineum transmitting blood vessels and nerves (see Fig. 123).

## THE MUSCLES OF THE LOWER LIMB

The muscles of the lower limb are divided into the muscles of the hip region, thigh, leg, and foot. There are no special muscles of the pelvic girdle because it is held stationary. The muscles of the lower limb are innervated by the lumbar and sacral plexus (*plexus lumbalis* and *plexus sacralis*).

### MUSCLES OF THE HIP REGION

The muscles of the region of the hip (Figs. 127, 160, 161) pass from the pelvic girdle to the femur and allow movement at the hip joint on each of its three axes. Arranged on all sides of the joint, the muscles perform every type of movement. They can be classified according to the location of their

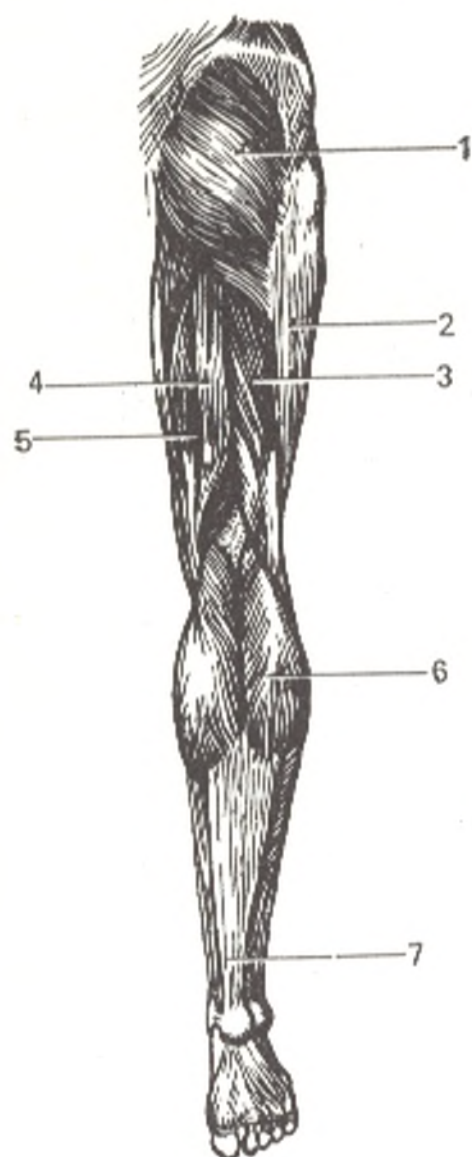


Fig. 160. Posterior muscles of pelvis and muscles of lower limb, posterior aspect.

- 1, m. gluteus maximus;
- 2, tractus iliotibialis;
- 3, m. biceps femoris;
- 4, m. semitendinosus;
- 5, m. semimembranosus;
- 6, m. gastrocnemius and its Achilles tendon (7)

attachment to the femur and according to their principal action into anterior, posterior, and medial groups.

The *anterior group* (flexors) is attached to the lesser trochanter; it consists of the iliopsoas muscle (m. psoas major and m. iliacus and m. psoas minor).

The *posterior group* (extensors, rotators, and abductors) are attached to the greater trochanter or in its vicinity; this group includes the following muscles: gluteus maximus, gluteus medius, tensor fasciae latae, gluteus minimus, piriformis, obturatorius internus with mm. gemelli, quadratus femoris and obturatorius externus.

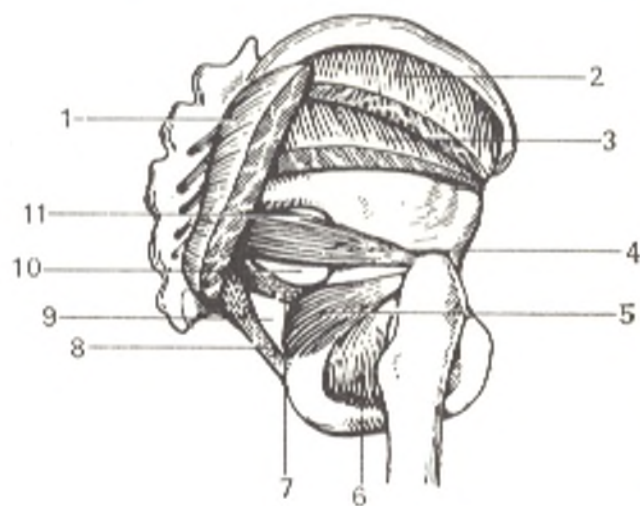
The *medial group* (adductors) attaches to the linea aspera femoris (the only exception is gracilis, which is attached on the leg) and consists of the following muscles: pectineus, adductor longus, adductor brevis, adductor magnus and gracilis.

The muscles of the medial group are functionally related to the hip



Fig. 161. Posterior muscles of pelvis.

- 1, m. gluteus maximus;
- 2, m. gluteus medius;
- 3, m. gluteus minimus;
- 4, m. piriformis;
- 5, m. obturatorius internus;
- 6, m. obturatorius externus;
- 7, lig. sacrospinale;
- 8, lig. sacrotuberale;
- 9, foramen ischia-dicum minus;
- 10, foramen infrapiriforme;
- 11, foramen suprapiriforme



joint, at which they accomplish adduction of the thigh, but their entire mass is located on the thigh. For the sake of convenience, therefore, the medial group of hip muscles is classified topographically and described below as the medial group of the thigh.

#### THE ANTERIOR GROUP

1. The **iliopsoas muscle** (*m. iliopsoas*) consists of two heads described as two separate muscles. The **psoas major muscle** (*m. psoas major*) arises from the lateral surface of the body and the intervertebral discs of the twelfth thoracic and upper four lumbar vertebrae and from the transverse processes of the lumbar vertebrae. Descending slightly laterally it meets the iliacus muscle. The second head, the **iliacus muscle** (*m. iliacus*) arises from the iliac fossa and from the superior and inferior anterior iliac spinae. Medially the iliac muscle is partly covered by the psoas muscle, and a deep groove to transmit the femoral nerve forms here between the two muscles. The fibres of the iliac muscle converge as they pass downward and join the tendon of the greater psoas muscle to form a single iliopsoas muscle. This muscle lies on the anterior surface of the hip joint, emerges from under the inguinal ligament through the lacuna musculorum (described below in "The Topography of the Lower Limb"), and attaches to the lesser trochanter. Between the muscle and the joint capsule is a small *synovial bursa* (*bursa iliopectinea*), which sometimes communicates with the joint (see Fig. 127).

**Action.** Accomplishes flexion at the hip joint by pulling the thigh to the abdomen and slightly rotating it medially. When the lower limb is steadied, the muscle causes forward flexion of the pelvis with the trunk. **Innervation:** L<sub>2-4</sub>. The lumbar plexus.

2. The **psoas minor muscle** (*m. psoas minor*) adjoining the greater psoas muscle is an inconstant muscle. It arises from the twelfth thoracic and first lumbar vertebrae. Its long tendon blends with the iliac fascia and is inserted into the iliopubic eminence. It tenses the iliac fascia and may flex the lumbar segment of the spine. **Innervation:** L<sub>1-2</sub>. The lumbar plexus.

## THE POSTERIOR GROUP

1. The **gluteus maximus muscle** (*m. gluteus maximus*) is a massive muscular layer lying directly under the skin and fascia in the region of the buttock. It *arises* from the external (lateral) surface of the ilium, from the lateral parts of the sacrum and coccyx, and from the sacrotuberal ligament and descends obliquely and laterally as parallel muscular bundles separated by thin septa arising from the fascia covering the muscle. The anterior muscular bundles end in a wide flat tendon, which curves around the lateral surface of the greater trochanter and is continuous with the fascia lata femoris (its iliotibial tract). The posterior part of the muscle is *attached* to the gluteal tuberosity of the femur. A *synovial bursa* (*bursa trochanterica m. glutei maximi*) is lodged between the tendon of the muscle and the greater trochanter (Figs. 160 and 161).

*Action.* An antagonist of the iliopsoas muscle, the gluteus maximus muscle extends the thigh, rotating it slightly laterally. When the lower limbs are held fast, it extends the anteriorly flexed trunk. When the body is upright and the pull of gravity affects the front of the transverse axis of the hip joints (as typical of military carriage), tension of this muscle maintains the balance of the pelvis and the body and prevents the torso from falling forward. Innervation: L<sub>5</sub>-S<sub>1</sub>. The inferior gluteal nerve.

2. The **gluteus medius muscle** (*m. gluteus medius*) is covered posteriorly by the gluteus maximus muscle. Its anterior part lies near the surface. This muscle *arises* from the external surface of the ilium as a fan-shaped belly and *ends* in a flat tendon *attached* to the lateral surface of the greater trochanter close to the apex.

*Action.* When contracted, this muscle abducts the thigh. Separate contraction of the anterior bundles rotates the thigh medially, while contraction of the posterior bundles rotates it laterally. When the body is supported on a single lower limb, the muscle shifts the pelvis to one side. Innervation: L<sub>4</sub>-S<sub>1</sub>. The superior gluteal nerve.

3. The **tensor fasciae latae muscle** (*m. tensor fasciae latae*) developed in the embryo separately from the gluteus medius muscle. It lies directly in front of the gluteus medius muscle on the lateral surface of the thigh between the two layers of the fascia lata. The muscle *arises* from the superior anterior iliac spine, where it blends with the initial part of the middle gluteal muscle and is *continuous* distally with the thickened band of fascia lata called the iliotibial tract. This band stretches along the lateral surface of the thigh and *attaches* to the lateral tibial condyle.

*Action.* It tenses the iliotibial tract and, through it, acts on the knee joint and flexes the thigh. Because of their connection with the tensor fasciae latae, the maximus and medius gluteus muscles contribute to movement at the knee joint by assisting flexion and lateral rotation. Innervation: L<sub>4-5</sub> and S<sub>1</sub>. The superior gluteal nerve.

4. The **gluteus minimus muscle** (*m. gluteus minimus*) lies under the gluteus medius muscle. It *arises* from the external surface of the ilium and *attaches* to the anterior surface of the greater trochanter by a flat tendon.

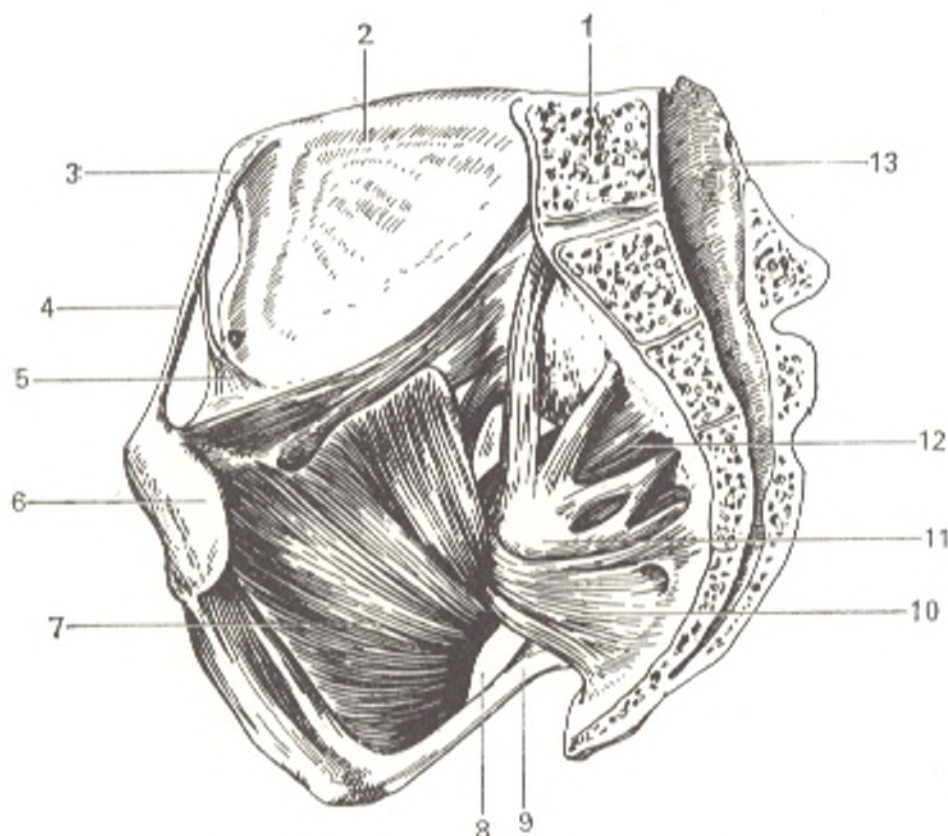


Fig. 162. Internal muscles of pelvis.

1, fifth lumbar vertebra;  
2, os ilium;  
3, spina iliaca anterior superior;  
4, lig. inguinale;  
5, arcus iliopectineus;  
6, facies symphyialis;  
7, m. obturatorius internus;

8, foramen ischiadicus minus;  
9, lig. sacrotuberale;  
10, m. coccygeus;  
11, plexus sacralis;  
12, m. piriformis;  
13, canalis sacralis

A bursa (*bursa trochanterica m. glutei minimi*) is lodged under the tendon.

**Action.** The same as that of the middle gluteal muscle. **Innervation:** L<sub>4-5</sub> and S<sub>1</sub>. The superior gluteal nerve.

5. The **piriformis muscle** (*m. piriformis*) arises on the pelvis surface of the sacrum lateral to the anterior sacral foramina (between the second and fourth foramen). It leaves the pelvic cavity through the greater ischiadic foramen, passes transversely on the posterior surface of the hip joint, and **attaches** to the greater trochanter. The muscle does not fill the greater ischiadic foramen completely but leaves slits on its superior and inferior edges for transmitting vessels and nerves (see p. 377).

**Action.** Rotates the thigh laterally and assists in its abduction; when the limb is held fast, the piriformis muscle can flex the pelvis to the side and forward. **Innervation:** S<sub>1-2</sub>. The muscular branches of the sacral plexus (Figs. 161 and 162).

6. The **obturator internus muscle** (*m. obturatorius internus*) originates on the inner surface of the hip bone from the margin of the obturator foramen and the obturator membrane, passes over the bony edge of the lesser ischiadic foramen, and **attaches** to the trochanteric fossa on the femur. A **synovial**

*bursa (bursa ischiadica m. obturatorii interni)* is lodged under the muscle where it curves over the bone. The edges of the internal obturator tendon lying outside the pelvic cavity on the posterior surface of the hip joint are fused with two flat and narrow muscles, **gemellus muscles** (*mm. gemelli*) (*L. gemelli* twins). The *superior muscle (m. gemellus superior)* arises on the ischial spine, the *inferior muscle (m. gemellus inferior)* on the ischial tuberosity. Both these small muscles, together with the tendon of the internal obturator muscle, are *attached* in the trochanteric fossa and are covered by the gluteus maximus muscle (see Fig. 161).

*Action.* Rotates the thigh laterally. Innervation:  $L_4-S_2$ . The muscular branches of the sacral plexus.

7. The **quadratus femoris muscle** (*m. quadratus femoris*) lies inferior to the inferior gemellus muscle under the lower border of the gluteus maximus muscle. Its fibres run transversely from the ischial tuberosity to the intertrochanteric crest on the femur.

*Action.* Rotates the thigh laterally. Innervation:  $L_4-S_1$ . The muscular branches of the sacral plexus.

8. The **obturator externus muscle** (*m. obturatoris externus*) arises from the external surface of the pelvic bones along the medial margin of the obturator foramen and from the obturator membrane, passes around the capsule of the hip joint from below and from the back, and *attaches* by a narrow tendon to the trochanteric fossa and to the joint capsule.

*Action.* Rotates the thigh laterally. Innervation:  $L_3-4$ . The obturator nerve.

## MUSCLES OF THE THIGH

The muscles of the thigh help man walk erect and maintain an erect position by moving the long bone levers. As a consequence, these long muscles fuse to form strong masses with a single common tendon and more than one head (e.g. the biceps and quadriceps muscles). The muscles of the thigh are divided into three groups: anterior (mainly extensors), posterior (flexors), and medial (adductors). The last group acts only on the hip joint, whereas the first two groups also act on the knee joint by producing movements predominantly on its frontal axis. This is possible because of their positions on the anterior and posterior surfaces of the thigh and attachment to the leg.

Laterally the anterior and posterior groups of muscles are separated by a lateral intermuscular septum (septum intermusculare laterale) of the femoral fascia, which is attached to the lateral lip of the linea aspera. Medially a layer of adductor muscles is wedged between them.

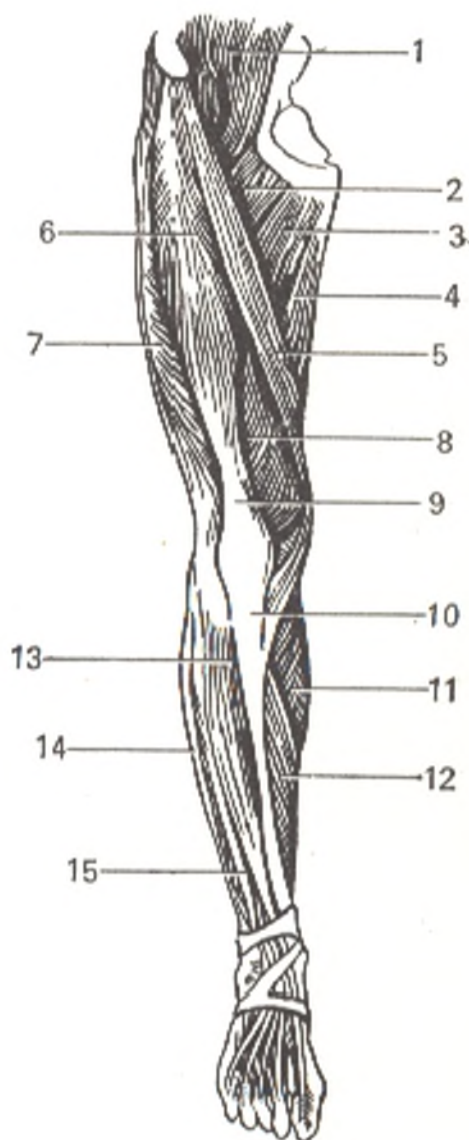
## THE ANTERIOR GROUP

1. The **quadriceps femoris muscle** (*m. quadriceps femoris*) occupies the entire anterior and part of the lateral surface of the thigh and is formed of three heads fused to each other. These heads are as follows.

The **rectus femoris muscle** (*m. rectus femoris*) lies superficially and arises from the inferior anterior iliac spine and from the superior margin of the acetabulum. At its origin, it is covered by the tensor fasciae latae and by the sartorius. The rectus femoris muscle passes on the middle of the thigh and joins the common tendon of the whole quadriceps muscle above the patella. The **vastus lateralis muscle** (*m. vastus lateralis*) encircles the femur laterally and arises from the intertrochanteric line, from the lateral surface of the greater trochanter, and from the lateral lip of the linea aspera femoris. The fibres of the muscle descend obliquely and end some distance above the patella. The **vastus medialis muscle** (*m. vastus medialis*) lies medially in relation to the femur. It arises from the medial lip of the linea aspera femoris. Its fibres pass obliquely from the medial side laterally and downwards. The **vastus intermedius muscle** (*m. vastus intermedius*) lies directly on the anterior surface of the femur from which it takes its origin almost reaching the intertrochanteric line proximally. Its fibres stretch vertically parallel toward the common tendon. Laterally and medially the vastus intermedius

Fig. 163. Muscles of lower limb, anterior aspect.

- 1, m. iliopsoas;
- 2, m. pectineus;
- 3, m. adductor longus;
- 4, m. gracilis;
- 5, m. sartorius;
- 6, m. rectus femoris;
- 7, m. vastus lateralis;
- 8, m. vastus medialis;
- 9, tendo m. quadriceps femoris;
- 10, lig. patellae;
- 11, m. gastrocnemius;
- 12, m. soleus;
- 13, m. tibialis anterior;
- 14, m. peroneus longus;
- 15, m. extensor digitorum longus



muscle is covered by the lateral and medial great muscles, with which it blends here. The rectus femoris muscle is in front of it. Under the knee joint these parts of the quadriceps muscle form a common tendon, which is attached to the base and sides of the patella and is then continuous with the patellar ligament *attached* to the tibial tuberosity. Some of the tendon fibres of the vastus lateralis and vastus medialis pass on the sides of the patella downward and obliquely to form the *retinaculum of the patella* (*retinacula patellae*) mentioned in the section on syndesmology. The patella, as if framed in the tendon of the quadriceps muscle, increases the angle at which the muscle meets the lever, which favourably influences the application of its force (Fig. 163).

*Action.* Flexes the leg at the knee joint. The rectus femoris flexes the hip joint as it passes over it. Innervation:  $L_{3-4}$ . The femoral nerve.

2. The sartorius or tailor's muscle (*m. sartorius*). *Arising* from the superior anterior iliac spine, this muscle descends medially as a long band of parallel fibres and is *attached* to the fascia of the leg and the tibial tuberosity.

*Action.* Flexes the knee joint, and, when the knee is flexed, rotates the leg medially, acting with the other muscles that have attachment in common with it. It can also flex the thigh at the hip joint, thus assisting the iliopsoas and rectus femoris. Innervation:  $L_{2-3}$ . The femoral nerve.

#### THE POSTERIOR GROUP

1. The semitendinosus muscle (*m. semitendinosus*) is called so because of its long tendon, which makes up almost the entire distal half of the muscle. It *arises* on the ischial tuberosity and *attaches* behind the gracilis muscle to the tibial tuberosity and the fascia of the leg. At the site of attachment, the tendon of the semitendinosus muscle, together with the tendons of the gracilis and sartorius muscles, forms a triangular tendinous extension continuous with the fascia of the leg. This extension is called the "superficial goose's foot" (*pes anserinus superficialis*), under which a *synovial bursa* (*bursa anserina*) is lodged. Innervation:  $L_5$  and  $S_{1-2}$ . The sciatic nerve.

2. The semimembranosus muscle (*m. semimembranosus*) lies under the semitendinosus muscle. It *arises* on the ischial tuberosity as a flat tendon which descends and forms almost the entire proximal half of the muscle, hence the name. The end tendon separates at the site of attachment into three bands, the *pes anserinus profundus*, one of which is *attached* to the medial condyle of the tibia. Another attaches to the fascia covering the popliteus muscle, and the third folds over to the posterior wall of the knee joint and is continuous with the oblique popliteal ligament. Innervation:  $L_4-S_1$ . The sciatic nerve.

3. The biceps femoris muscle (*m. biceps femoris*) is located near the lateral border of the thigh and is separated from the vastus lateralis by the lateral intermuscular septum. The muscle consists of two head. The **long head** (*caput longum*) *arises* with the semitendinosus muscle from the ischial tuberosity; the **short head** (*caput breve*) *arises* from the middle one third of the lateral

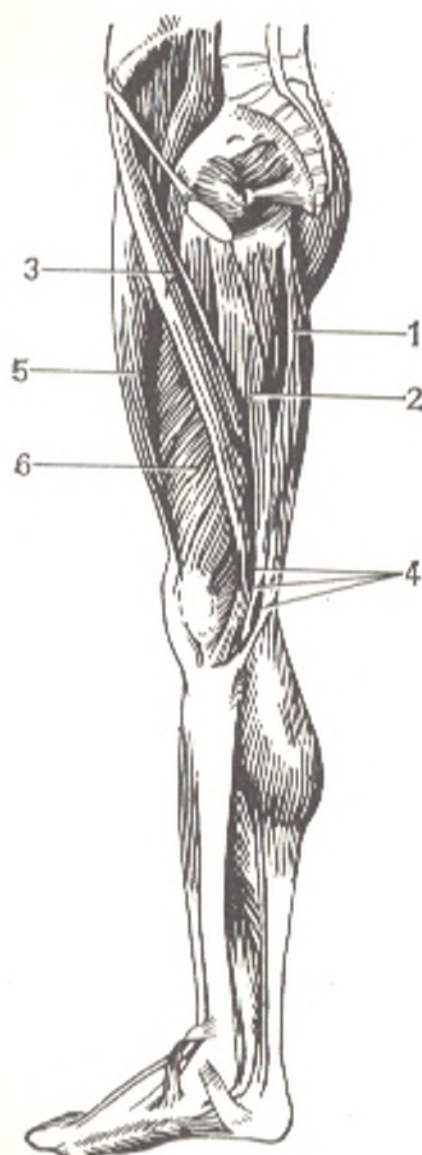


Fig. 164. Muscles of lower limb, medial surface.

- 1, m. semitendinosus;
- 2, m. gracilis;
- 3, m. sartorius;
- 4, pes anserinus superficialis;
- 5, m. rectus femoris;
- 6, m. vastus medialis

lip of the linea aspera femoris and the lateral intermuscular septum of the thigh. The heads fuse and *attach* to the head of the fibula. Innervation: caput longum,  $S_{1-2}$ , the tibial and sciatic nerves; caput breve,  $L_{4-5}$  and  $S_1$ , the common peroneal and sciatic nerves.

4. The **popliteus muscle** (*m. popliteus*) is triangular and lies on the posterior surface of the knee joint. It *arises* from the lateral epicondyle of the femur and from the capsule of the knee joint (the oblique popliteal ligament) and is *inserted* into the proximal part of the posterior surface of the tibia. Innervation:  $L_4-S_1$ . The tibial nerve (Figs. 160 and 164).

*Action.* Since the semitendinosus, semimembranosus, and biceps femoris muscles stretch over two joints, their simultaneous action flexes the leg at the knee joint, extends the thigh when the pelvis is steadied, and assists the gluteus maximus muscle in extension of the trunk when the leg is steadied. When the knee is flexed, these muscles rotate the leg, contracting separately on either side. The leg is rotated laterally by the biceps muscle

and medially by the semitendinosus and semimembranosus muscles. The popliteus muscle acts only on the knee joint; it flexes the knee and rotates the leg medially.

#### THE MEDIAL GROUP

1. The **pectineus muscle** (*m. pectineus*) originates from the superior ramus and crest of the pubis and from the superior pubic ligament, passes downward and slightly to the side, and attaches to the pectineal line of the femur. Its lateral border adjoins the iliopsoas muscle. Where these muscles converge they form the *iliopectineal fossa* (*fossa iliopectinea*) lodging the femoral vessel at their exit from the pelvis. Innervation: L<sub>2-3</sub>. The obturator and femoral nerves.

2. The **adductor longus muscle** (*m. adductor longus*) originates on the anterior surface of the superior ramus of the pubis and attaches to the medial lip of the linea aspera femoris in its middle third. Its fibres, like the fibres of the other adductors, extend downwards and laterally. Innervation: L<sub>2-3</sub>. The obturator nerve.

3. The **adductor brevis muscle** (*m. adductor brevis*) lies under the preceding muscles. It arises on the anterior surface of the pubis and attaches to the medial lip of the linea aspera in its upper part. Innervation: L<sub>2-4</sub>. The obturator nerve.

4. The **adductor magnus muscle** (*m. adductor magnus*) is the strongest of the adductor group. It is furthest to the back, and its proximal part is covered in front by the long and short adductor muscles. The adductor magnus arises from the rami of the pubic and ischial bones and from the ischial tuberosity, passes laterally, and attaches to the medial lip of the linea aspera for its entire distance, up to the medial condyle of the femur. The upper fibres of the muscle stretch almost transversely from the pubic bone to the site of their attachment and are classified separately as the **adductor minimus muscle** (*m. adductor minimus*). The lower fibres in the medial border of the muscle stretch almost vertically and end in a strong tendon attached to the medial epicondyle of the femur. The edge of this tendon is tightly stretched and can be easily palpated through the skin in the lower one third of the thigh. Innervation: L<sub>3-5</sub>. The obturator and partly the sciatic nerves.

5. The **gracilis muscle** (*m. gracilis*) is a long, narrow band of muscle passing superficially on the medial border of the adductor group. Its origin is on the inferior ramus of the pubic bone close to the symphysis. The muscle is attached to the fascia of the leg at the tibial tuberosity. Innervation: L<sub>3-4</sub>. The obturator nerve (Figs. 163 and 164).

*Action.* As their names indicate, all the adductor muscles adduct the thigh, slightly rotating it laterally. Those lying closer to the front and crossing the transverse axis of the hip joint (the pectineus muscle and the longus and brevis adductors) can also accomplish flexion at this joint. The gracilis muscle, passing over two joints, in addition to adduction of the thigh, flexes the leg at the knee joint and rotates it medially.



## MUSCLES OF THE LEG

The muscles of the leg move the distal part of the limb—the foot—and, like the muscles of the thigh are adapted to moving and supporting the body in an upright position. The individual muscles, therefore, are not highly specialized when compared with the muscles of the forearm, which specialize as the result of the functioning of the hand as an organ of labour. On the contrary, large masses of muscles in the leg, which fuse and have common tendons, combine their efforts to make the strong, wide movements necessary in walking erect. To facilitate movement on the frontal axis of the ankle joint and the finger joints, most muscles are arranged on the anterior and posterior surfaces of the leg between the tibia and fibula in front (the anterior muscles) and in back (the posterior muscles). To facilitate movement of the foot on the sagittal axis, the muscles are also arranged on the lateral surface along the fibula (the lateral muscles).

The anterior and lateral groups are developmentally related to the dorsal muscles of the lower limb; the posterior is related to the ventral muscles. The posterior group is better developed than the other groups and consists of two layers: superficial (the calf muscles) and deep. All the muscles of the leg extend longitudinally and are attached on the foot, some on the tarsal bones and the bases of the metatarsals, others on the phalanges of the toes. The fleshy parts of the muscles are located in the proximal part of the leg. Distally, near the foot, the muscles end in a tendon. The leg, as a result, is shaped like a cone. The anterior muscles accomplish dorsal flexion of the foot; those passing to the toes extend them. Plantar flexion of the foot is accomplished by the posterior and lateral muscles whose tendons reach the foot on the posterior surface or on the sole. Some of the posterior muscles also flex the toes. Pronation and supination of the foot is accomplished mainly by those muscles of the leg which are attached on the medial or lateral border of the foot.

### THE ANTERIOR GROUP

1. The **tibialis anterior muscle** (*m. tibialis anterior*) lies medially to all the other muscles and is the strongest in the group described. It arises on the lateral condyle and the proximal two thirds of the lateral surface of the tibia and from the interosseous membrane and the crural fascia. It descends on the tibia and ends in a strong tendon passing through the medial fibrous canal under the retinaculum of the superior and inferior extensors to the medial border of the dorsal surface of the foot, where it is attached to the medial cuneiform bone and the base of the first metatarsal bone. A synovial bursa is usually lodged under the tendon at the site of its attachment (Fig. 163).

**Action.** Accomplishes dorsal flexion of the foot and raises its medial border (supination). When the foot is stationary, the muscle bends the leg forward, bringing it closer to the dorsal surface of the foot. **Innervation:** L<sub>4</sub>-S<sub>1</sub>. The deep peroneal nerve.

2. The **extensor digitorum longus muscle** (*m. extensor digitorum longus*) originates from the lateral tibial condyle, from the head and anterior surface of the fibula, from the interosseous membrane, and from the crural fascia. It descends and ends in a tendon, which separates into four parts extending through the lateral canal in the retinaculum of the superior and inferior extensors to the dorsal surface of the foot. There they diverge in the shape of a fan and attach to the tendinous expansion on the dorsal surface of the lateral four toes. A small slip of muscle arising from the lateral side of the distal part of the long extensor ends in a fifth tendon which passes under the inferior extensor retinaculum and attaches to the base of the fifth metatarsal bone. This is the **peroneus tertius (fibular) muscle** (*m. peroneus [fibularis] tertius*). It is considered the first stage of the separation of a muscle new to man (it is absent in the apes), the pronator of the foot that is necessary for walking on two limbs.

*Action.* Together with the peroneus tertius muscle, the extensor longus muscle accomplishes dorsal flexion of the foot, raises the lateral border (pronation), and everts the foot. When the foot is stationary, the muscle acts similarly to the anterior tibial muscle. It also extends the lateral four toes, although this action is slight. Innervation: L<sub>4</sub>-S<sub>1</sub>. The deep peroneal nerve.

3. The **extensor hallucis longus muscle** (*m. extensor hallucis longus*) lies deeper in the space between the two muscles described above. It arises from the medial surface of the fibula and from the interosseous membrane, descends through the middle canal under the inferior extensor retinaculum onto the dorsal surface of the foot to the great toe; it is attached to the distal phalanx of the toe and also gives off a slip to the proximal phalanx.

*Action.* Accomplishes dorsal flexion of the foot, raises its medial border, and extends the great toe. When the foot is stationary, it assists the other anterior muscles in bending the leg forward. Innervation: L<sub>4-5</sub> and S<sub>1</sub>. The deep peroneal nerve.

#### THE LATERAL GROUP

1. The **peroneus longus muscle** (*m. peroneus [fibularis] longus*) lies superficially and arises from the head and proximal one third of the lateral surface of the fibula and from the anterior and posterior intermuscular septa and the crural fascia. The tendon passes laterally and then behind the short peroneal muscle and, together with it, curves around the lateral malleolus posteriorly and inferiorly lying in a synovial sheath under the superior peroneal retinaculum. It then passes in a groove on the lateral surface of the calcaneus and is retained on the bone by the inferior peroneal retinaculum. Further, it bends around the lateral border of the foot, fits under it in a groove on the cuboid bone, where it is invested in a synovial sheath, crosses the sole of the foot obliquely, and is attached on its medial border to the medial cuneiform and first metatarsal bones. Innervation: L<sub>5</sub>-S<sub>1</sub>. The superficial peroneal nerve.

The attachment to the medial cuneiform bone is inherent only in man (but not in apes), which reflects the tendency of the musculature of the leg

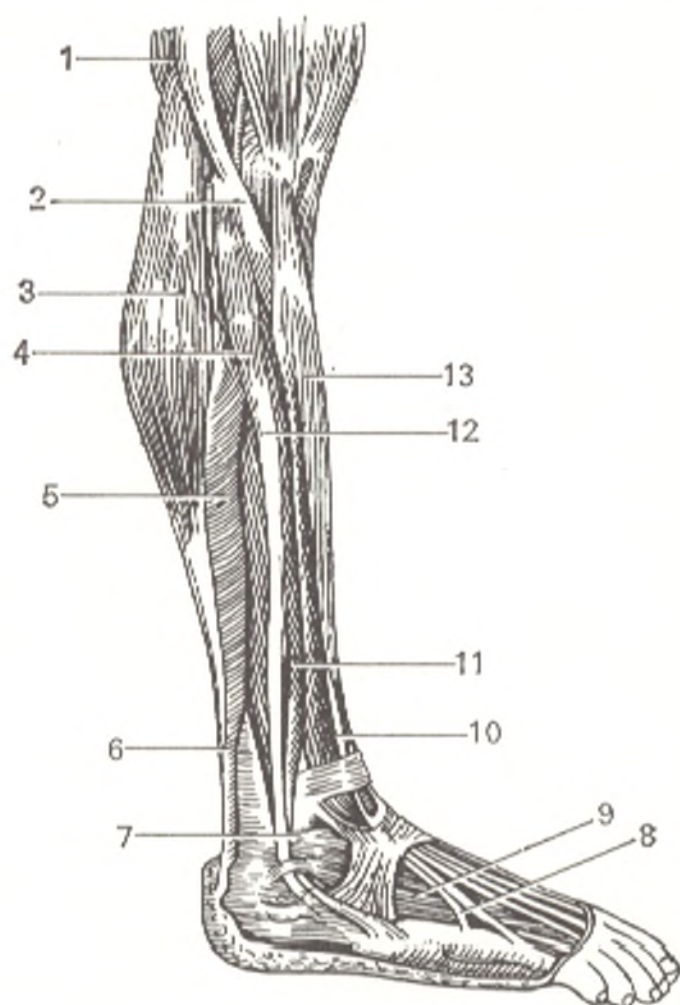


Fig. 165. Muscles of the leg, lateral aspect.

- 1, m. biceps femoris;
- 2, caput fibulae;
- 3, caput laterale m. gastrocnemius;
- 4, m. peroneus longus;
- 5, m. soleus;
- 6, tendo calcaneus (Achilles);
- 7, malleolus lateralis;
- 8, tendo m. peronei tertii;
- 9, m. extensor digitorum brevis;
- 10, m. extensor digitorum longus;
- 11, m. peroneus brevis;
- 12, m. peroneus longus;
- 13, m. tibialis anterior

and foot to migrate to the tibial side and maintain the transverse arch of the foot.

2. The **peroneus brevis muscle** (*m. peroneus [fibularis] brevis*) lies under the long peroneal muscle. It arises from the middle third of the lateral surface of the fibula and from both intermuscular septa. Its tendon passes behind the lateral malleolus in a sheath shared with the long peroneal muscle, extends under the superior peroneal retinaculum and then under the inferior peroneal retinaculum and is attached to the tuberosity of the fifth metatarsal bone. It sometimes gives off a thin slip to the tendon of the extensor of the fifth toe. Innervation:  $L_5-S_1$ . The superficial peroneal nerve (Fig. 165).

**Action.** Both peroneal muscles pronate the foot, lowering its medial and raising its lateral borders; they also abduct the foot and assist the other muscles in its plantar flexion.

#### THE POSTERIOR GROUP

The *superficial layer* (muscles of the calf):

1. The **triceps surae muscle** (*m. friceps surae*) forms the main bulk of the calf. It is made up of two muscles, *m. gastrocnemius* lying superficially and *m. soleus* lying under it; both muscles have a tendon in common distally.

The **gastrocnemius muscle** (*m. gastrocnemius*) arises from the popliteal surface of the femur above both condyles by two heads whose tendons blend at their origin with the capsule of the knee joint<sup>1</sup>. Uniting on the midline, both heads of the muscle end almost at the middle of the crus in a tendon, which fuses with the tendon of the soleus muscle to form the massive *calcaneal* (Achilles) *tendon*, *tendo calcaneus* (Achillis)<sup>2</sup>, attached to the posterior surface of the calcaneal tuber (see Fig. 160). A very constant *synovial bursa* (*bursa tendinis calcanei* [Achillis]) is lodged between the tendon and the bone at the site of the attachment.

The **soleus muscle** (*m. soleus*) is thick and fleshy. It lies under the gastrocnemius muscle and at its origin occupies a great length of the leg bones. The line of its *origin* is on the head and on the upper third of the posterior surface of the fibula and descends on the tibia almost to the borderline between the middle and lower third of the leg. Where the muscle crosses from the fibula to the tibia, the *tendinous arch of the soleus muscle* (*arcus tendineus m. solei*) forms, under which the popliteal artery and the tibial nerve pass. The fibres descend and end on a wide tendinous expansion, which narrows distally and fuses with the calcaneal tendon.

2. The **plantaris muscle** (*m. plantaris*) originates from the popliteal surface of the femur above the lateral condyle and from the capsule of the knee joint. The short and narrow belly of this muscle soon ends in a very long and slender tendon stretching in front of the gastrocnemius muscle to the medial margin of the calcaneal tendon where it *attaches* to the calcaneal tuber. This muscle is undergoing reduction and is a rudimentary structure in man and may therefore be absent.

*Action.* The musculature of triceps surae (including the plantar muscle) accomplishes plantar flexion at the ankle joint, both when the limb is free and when a person supports himself on the tip of the foot. Since the line of traction of the muscle passes medially of the axis of the subtalar joint, triceps surae also adducts and supinates the foot. In an erect position, triceps surae (the soleus muscle in particular) prevents the body from toppling over forward at the ankle joint. The muscle acts mostly under the weight of the whole body and is therefore distinguished by force and a large physiological diameter. Being a bi-articular muscle, the gastrocnemius can also flex the knee when the leg and foot are steadied. Innervation of *m. triceps surae* and *m. plantaris*: L<sub>5</sub>-S<sub>2</sub>. The tibial nerve.

The *deep layer* is separated from the superficial layer by the deep fascia of the leg and is made up of three flexors, which are antagonists of the three extensors of the same name situated on the anterior surface of the leg.

3. The **flexor digitorum longus muscle** (*m. flexor digitorum longus*) is the extreme medial muscle of the deep layer. It lies on the posterior surface of the tibia and *arises* from it and from the deep fascia of the leg. Its tendon

<sup>1</sup> A synovial bursa is lodged under the origin of each head (*bursae subtendineae m. gastrocnemii lateralis and medialis*).

<sup>2</sup> Named so after the Greek mythological hero Achilles who was vulnerable only in the heel. This tendon has five connective-tissue layers containing nerves and vessels, which must be borne in mind during its plastics.

descends behind the medial malleolus and under retinaculum of the mm. flexorum and in the middle of the sole separates into four secondary tendons, which pass to the lateral four toes, pierce the tendon of the flexor digitorum brevis (like the deep flexor on the hand), and *attach* to the distal phalanges.

*Action.* The muscle is of small importance as a flexor of the toes, it mainly acts on the foot as a whole and accomplishes its plantar flexion and supination, when the limb is free. Together with triceps surae it sets the foot on the tips of the toes (walking on tiptoe). In standing, the muscle assists actively in strengthening the longitudinal arch of the foot. It presses the toes to the ground in walking. Innervation:  $L_5-S_1$ . The tibial nerve.

4. The **tibialis posterior muscle** (*m. tibialis posterior*) occupies the space between the leg bones and is situated on the interosseous membrane and partly on the tibia and fibula. It *originates* from these sites; its tendon is closest to the margin of the medial malleolus and is lodged behind it in a bone groove under the flexor retinaculum. The tendon then emerges onto the sole to be *attached* to the tuberosity of the navicular bone and then by several bundles to the three cuneiform bones and the bases of the second, third, and fourth metatarsal bones.

*Action.* It adducts the foot and also accomplishes plantar flexion like the other posterior muscles. Together with the other muscles also attached to the medial border of the foot (the anterior tibial and the long peroneal muscle), the tibialis posterior muscle forms a stirrup, as it were, that strengthens the arch of the foot; its tendon stretches through the calcaneonavicular ligament as a result of which the muscle together with the ligament support the head of the talus. Innervation:  $L_5-S_1$ . The tibial nerve.

5. The **flexor hallucis longus muscle** (*m. flexor hallucis longus*) is the extreme lateral muscle of the deep layer. It lies on the posterior surface of the fibula, from which it *arises*, as well as from the interosseous membrane and the posterior intermuscular septum. Its tendon passes in the groove on the posterior process of the talus, where it is covered by a layer of the flexor retinaculum, and then passes under the sustentaculum of the talus to the great toe and *attaches* to its distal phalanx (Fig. 160).

*Action.* Flexes the great toe. Due to its possible connection with the tendon of the flexor digitorum longus, it may also flex the second and even the third and fourth toes. Like the other posterior muscles of the leg, the flexor digitorum longus muscle accomplishes plantar flexion, adduction, and supination of the foot and strengthens the arch of the foot in the anteroposterior direction. Innervation:  $L_5-S_2$ . The tibial nerve.

## MUSCLES OF THE FOOT

The foot, like the hand, in addition to tendons of the long muscles of the leg descending on it, has its own short muscles among which dorsal and plantar muscles are distinguished.

## THE DORSAL MUSCLES

The **extensor digitorum brevis muscle** (*m. extensor digitorum brevis*) lies on the dorsal surface of the foot under the extensor digitorum longus tendons. It *originates* on the superolateral surface of the calcaneus just before the entrance into the sinus tarsi, extends forward, and divides into four thin tendons. These tendons stretch to the medial four toes and *fuse* with the lateral margin of the extensor digitorum longus and extensor hallucis longus tendons with which they form the dorsal tendinous expansion of the toes. The medial belly passing obliquely together with its tendon to the great toe is also designated separately, the **extensor hallucis brevis muscle** (*m. extensor hallucis brevis*) (see Fig. 166).

*Action.* Extends the medial four toes and at the same time abducts them slightly laterally. Innervation:  $L_4-S_1$ . The deep peroneal nerve.

## THE PLANTAR MUSCLES

The muscles of the sole of the foot (Fig. 167) form three groups: medial (muscles of the great toe), lateral (muscles of the little toe), and middle group situated in the middle of the sole.

A. The medial group consists of three muscles.

1. The **abductor hallucis muscle** (*m. abductor hallucis*) is closest to the surface on the medial border of the sole. This strong muscle *arises* from the medial process of the tuberosity of the calcaneus, the retinaculum of the flexor muscles, and the tuberosity of the navicular bone, and is *attached* to the medial sesamoid bone and the base of the proximal phalanx. Innervation,  $L_5-S_1$ . The medial plantar nerve.

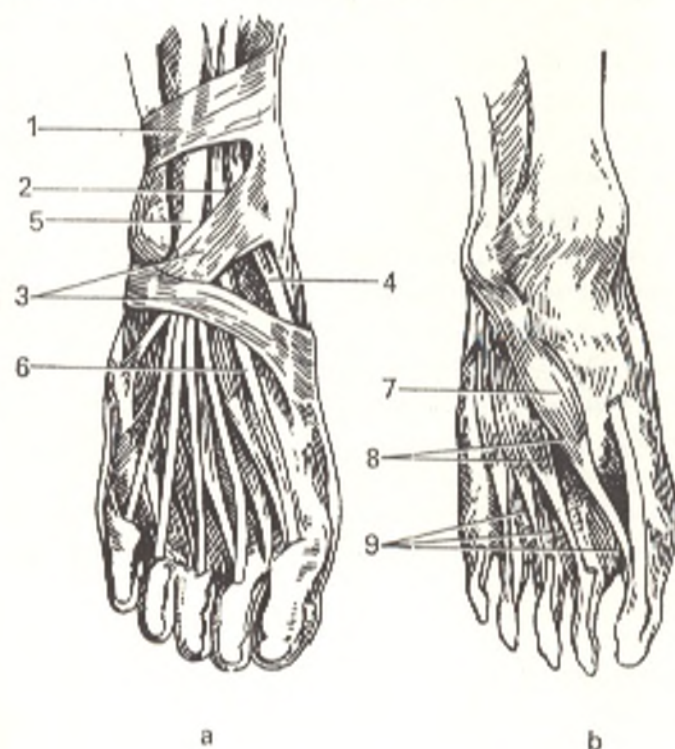


Fig. 166. Muscles of the dorsal surface of the foot.

- a*, dorsal muscles of foot (right);  
*b*, idem, but with the long muscles removed;  
 1, retinaculum mm. extensorum superius;  
 2 and 6, tendo m. extensoris hallucis longi;  
 3, retinaculum mm. extensorum inferius;  
 4, tendo m. tibialis anterior;  
 5, m. extensor digitorum longus;  
 7, m. extensor hallucis brevis;  
 8, m. extensor digitorum brevis;  
 9, mm. interossei dorsales

2. The **flexor hallucis brevis muscle** (*m. flexor hallucis brevis*) adjoins the lateral border of the above described muscle. It arises from the medial cuneiform bone and the plantar calcaneocuboid ligament, passes straight to the front separating into two heads between which the tendon of the flexor hallucis longus muscle passes. Both heads are attached to the sesamoid bones of the first metatarsophalangeal joint and to the base of the proximal phalanx of the great toe. Innervation,  $S_{1-2}$ . The medial and lateral plantar nerves.

3. The **adductor hallucis muscle** (*m. adductor hallucis*) lies deeply and consists of two heads. One of the heads, the **oblique head** (*caput obliquum*) arises from the cuboid bone, the long plantar ligament, the lateral cuneiform bone and the bases of the second, third and fourth metatarsal bones and passes obliquely to the front and somewhat medially. The other head, **transverse** (*caput transversum*), originates from the inferior surface of the capsules of the four lateral metatarsophalangeal joints and the plantar ligaments; it passes transversely to the sole and together with the oblique head is attached to the lateral sesamoid bone of the great toe. Innervation,  $S_{1-2}$ . The lateral plantar nerve.

**Action.** In addition to the action indicated by their name, the muscles of the medial plantar group contribute to strengthening the arch of the foot on the medial side.

B. There are three muscles in the lateral group.

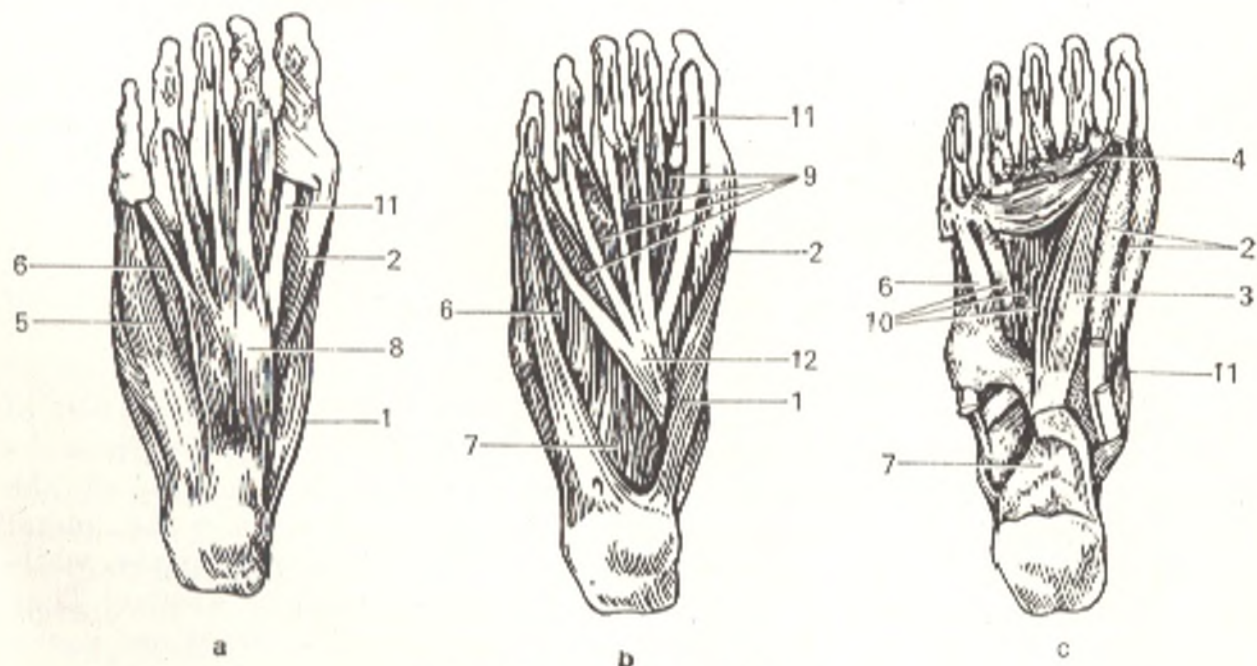


Fig. 167. Muscles of the sole.

a, muscles of the right sole;  
 b, *m. flexor digitorum brevis* has been removed;  
 c, *mm. flexor digitorum brevis*, *quadratus plantae*, *abductores hallucis* and *digiti minimi* have been removed:  
 1, *m. abductor hallucis*;  
 2, *m. flexor hallucis brevis*;  
 3, *m. adductor hallucis* (*caput obliquum*);

4, *m. adductor hallucis* (*caput transversum*);  
 5, *m. abductor digiti minimi*;  
 6, *m. flexor digiti minimi brevis*;  
 7, *m. quadratus plantae*;  
 8, *m. flexor digitorum brevis*;  
 9, *mm. lubricales pedis*;  
 10, *mm. interossei plantares*;  
 11, *tendo m. flexoris hallucis longi*;  
 12, *m. flexor digitorum longus*

1. The **abductor digiti minimi muscle** (*m. abductor digiti minimi*) lies on the lateral border of the sole closer to the surface than the other muscles. It *arises* from the inferior surface of the calcaneus and the plantar aponeurosis and *attaches* to the base of the proximal phalanx of the little toe.

2. The **flexor digiti minimi muscle** (*m. flexor digiti minimi brevis*) *arises* from the base of the fifth metatarsal bone and the long plantar ligament and *attaches* to the base of the proximal phalanx of the little toe.

3. The **opponens digiti minimi muscle** (*m. opponens digiti minimi*) lies laterally of the muscle described above. It *originates* from the long plantar ligament and fuses with the flexor digiti minimi muscle and is *attached* on the fifth metatarsal bone.

*Action.* The action exerted by each muscle of the lateral group on the little toe is mild. The main role of these muscles is to strengthen the lateral border of the arch of the foot. Innervation of all three muscle: S<sub>1-2</sub>. The lateral plantar nerve.

#### C. Muscles of the middle group.

1. The **flexor digitorum brevis muscle** (*m. flexor digitorum brevis*) lies superficially under the plantar aponeurosis. It *arises* from the tuberosity of the calcaneus and the proximal part of the plantar aponeurosis, stretches straight to the front and divides into four slender tendons *attached* to the middle phalanges of the four lateral toes. Before attachment, each tendon separates into two limbs between which the long flexor tendon passes. The muscle holds fast the longitudinal arch of the foot and accomplishes plantar flexion of the four lateral toes. Innervation: L<sub>5</sub>, S<sub>1</sub>. The medial plantar nerve.

2. The **flexor digitorum accessorius muscle** (*m. quadratus plantae* [*m. flexor accessorius*]) lies under the short flexor of the toes, *arises* from the calcaneus and joins the lateral border of the long flexor tendon. This bundle regulates the action of the long flexor of the toes, lending its traction a straight direction in relation to the toes. Innervation: S<sub>1-2</sub>. The lateral plantar nerve.

3. The **lumbrical muscles** (*mm. lumbricales*) are four in number. Similar to the lumbrical muscles of the hand, they *arise* from the medial borders of the four long flexor tendons: the three lateral muscles also originate from the opposing borders of the tendons. They *attach* to the medial margin of the proximal phalanges of the four lateral toes and do not always reach the dorsal tendinous extension. These muscles may flex the proximal phalanges, while their extensor action on the other phalanges is very weak or absent. They can also pull the four lateral toes toward the great toe. Innervation: L<sub>5</sub>-S<sub>2</sub>. The lateral and medial plantar nerves.

4. The **dorsal interossei muscles** (*mm. interossei*) are the deepest muscles on the sole and lie in the spaces between the metatarsal bones. Like the interosseous muscles on the hand, they separate into two groups: three **plantar muscles** (*mm. interossei plantares*) and four **dorsal muscles** (*mm. interossei dorsales*) but differ from the hand muscles in arrangement. On the hand, in view of its grasping function, the muscles are grouped around the middle finger; on the foot, which is responsible for support,



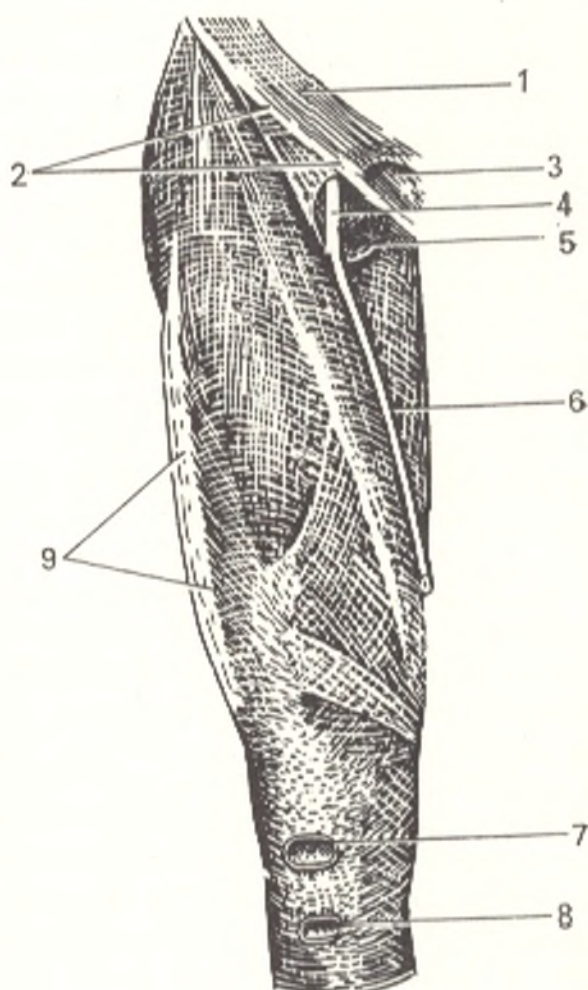


Fig. 168. Fascia lata.

- 1, aponeurosis of m. obliqui externi abdominis;
- 2, lig. inguinale;
- 3, anulus inguinalis superficialis;
- 4, v. femoralis;
- 5, hiatus saphenus;
- 6, v. saphena magna;
- 7, bursa subcutanea prepatellaris;
- 8, bursa subcutanea infrapatellaris;
- 9, tractus iliotibialis

they are grouped around the second toe, i.e. in relation to the second metatarsal bone, and exert a similar action, which is very restricted, however. Innervation:  $S_{1-2}$ . The lateral plantar nerve.

#### FASCIAE OF THE LOWER LIMB AND TENDON SHEATHS

The iliopsoas muscle is covered in the region of the abdomen by the *fascia iliaca*, which is part of the common *subperitoneal fascia* (*fascia subperitonealis*). The iliopsoas muscle *attaches* to the skeleton along the edges of the entire region occupied by the iliopsoas muscle and thus forms a closed sheath for it. Below the inguinal ligament, the fascia iliaca descends on the thigh, where it is continuous with *fascia lata* investing the muscles of the thigh (Fig. 168). Directly below the inguinal ligament, within the boundaries of the femoral triangle (see below), the fascia divides into two layers, deep and superficial. The former passes behind the vessels of the thigh. The superficial layer extends in front of the thigh vessels and lateral of the femoral vein and terminates as a free *falciform margin* (*margo falciformis*).

This margin bounds a depression called the *saphenous opening* (*hiatus saphenus*) or *fossa ovalis* (BNA) (see Figs. 132 and 168). Two "horns" are distinguished in the falciform margin. Vena saphena magna draining into the

femoral vein overlaps the *inferior horn* (*cornu inferius*), which blends with the deep layer of fasciae latae. The *superior horn* (*cornu superius*) attaches to the inguinal ligament and, curving under it, fuses with the lacunar ligament. Hiatus saphenus is covered by the *cribriform fascia* (*fascia cribrosa*) (the subcutaneous tissue of the thigh is pierced like a sieve by lymphatic vessels), which grows into the falciform margin. Fascia lata, investing the muscles of the thigh, gives off processes, which pass deeply between the muscles and are attached to the bone. Some of these processes are on the lateral part of the thigh and form the *lateral intermuscular septum* (*septum intermusculare femoris laterale*). It is attached to the lateral lip of the linea aspera femoris and separates m. vastus lateralis from the posterior muscles of the thigh (m. biceps femoris in particular). The other, *medial intermuscular septum* (*septum intermusculare femoris mediale*) is on the medial aspect of the thigh and attaches on labium mediale lineae asperae in front of the adductor muscles.

Besides, fascia lata separates into two layers along the edges of some of the muscles to form a closed sheath for them. Fascia lata is very thick, particularly on the lateral surface of the thigh, where tendinous fibres blend into it. Here it forms a wide thickened band, the *iliotibial tract* (*tractus iliotibialis*) extending for the entire length of the thigh. It serves as a tendon for the tensor muscle of the fascia lata and for the gluteus maximus muscle. In contrast to the tendinously thickened fascia on the gluteus medius muscle (the proximal end of the iliotibial tract) the fascia covering the gluteus maximus muscle is very thin. Distally, fascia lata extends to the anterior surface of the knee and is continuous with the fascia of the leg; posteriorly it is continuous with *fascia poplitea* covering the popliteal fossa and representing an intermediate area between the fascia of the thigh and that of the leg. Thus, fascia lata of the thigh differs in structure in its different parts: along with very strong areas (e.g. the iliotibial tract) there are also weak areas (fascia cribrosa).

The *crural fascia* (*fascia cruris*) surrounds the leg and fuses with the bones where they are uncovered by muscles. On the posterior aspect of the leg, it consists of a superficial and deep layers. The superficial layer covers the triceps surae muscle, while the deep layer lies between this muscle and the deep posterior muscles and is attached on the sides to the tibia and fibula. On the lateral side, fascia cruris gives off two intermuscular septa, which penetrate deeply and attach to the fibula. The anterior one (*septum intermusculare anterius cruris*) passes in front of the peroneus muscles, while the posterior septum (*septum intermusculare posterius cruris*) stretches behind them. On the anterior surface of the leg, above the malleoli, fibres blend with the fascia to form a transverse band between the leg bones, the *superior extensor retinaculum of the foot* (*retinaculum mm. extensorum pedis superius*). This ligament presses the tendons of the anterior leg muscles to the bones. Of similar significance is the *inferior extensor retinaculum* (*retinaculum mm. extensorum inferius*), located distally in front of the ankle joint: it usually resembles in shape the letter Y laid on its side (Fig. 169). This ligament originates from the lateral surface of the calcaneus, and its deep layer from the tarsal sinus, and then separates into two bands, the superior band passes to the medial malleolus while the inferior attaches to the navicular and the medial cuneiform bones.

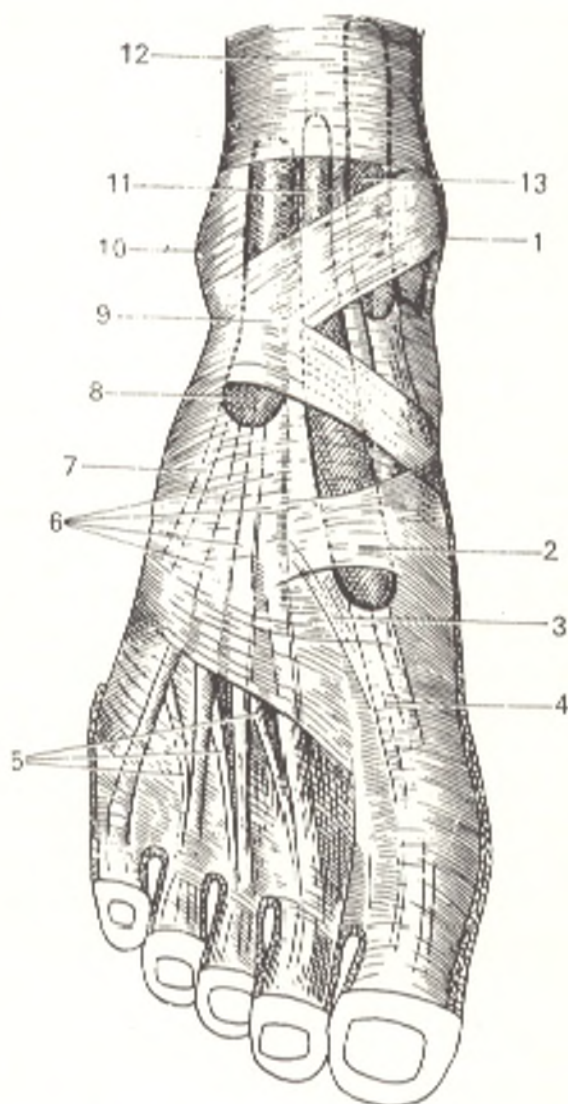


Fig. 169. Fasciae and synovial sheaths of foot (dorsal aspect).

- 1, malleolus medialis;
- 2, fascia dorsalis pedis (reinforcing slip);
- 3, tendo m. extensoris hallucis brevis;
- 4, tendo m. extensoris hallucis longi;
- 5, tendines m. extensoris digitorum brevis;
- 6, tendines m. extensoris digitorum longi;
- 7, tendo m. peronei III;
- 8, vagina tendinum m. extensoris digitorum longi;
- 9, retinaculum mm. extensorum inferius;
- 10, malleolus lateralis;
- 11, vagina tendinis m. extensoris hallucis longi;
- 12, retinaculum mm. extensorum superius;
- 13, vagina tendinis m. tibialis anterioris

At places this ligament splits into a superficial and deep layers investing the extensor tendons as a consequence of which four *fibrous canals* (three for tendons and one for vessels) are formed. The extreme lateral and the widest canal, located under the common origin of the inferior extensor retinaculum, transmits the tendons of the extensor digitorum longus and the peroneus tertius muscles. The canal next to it transmits the tendon of the extensor hallucis longus muscle, while the third, medial, canal transmits the tendon of the tibialis anterior muscle. The tendons passing through the canals are invested in synovial sheaths. The fourth canal, located behind the middle one, contains vessels (a. and v. dorsales pedis) and a nerve (n. peroneus profundus).

Thickenings of the fascia are also found behind both malleoli; they press the tendons against the bones. The medial thickening forms a ligament, the *flexor retinaculum of the foot* (*retinaculum mm. flexorum pedis*), which passes from the calcaneus to the medial malleolus over the tendons of the tibialis posterior, flexor digitorum longus, and flexor hallucis longus muscles. The ligament gives rise to a septum that penetrates deeper and forms three osteo-

fibrous canals to transmit the above-named tendons (Fig. 170) and one fibrous canal that lies closer to the surface to transmit the posterior tibial artery and the tibial nerve. The tendons in the canals under the ligament are invested in three separate sheaths. Behind the lateral malleolus is a fascial thickening, the *superior peroneal retinaculum* (*retinaculum mm. peroneorum superioris*) stretching from the malleolus to the calcaneus over the tendons of the peroneus longus and brevis muscles, which lie under it in a common osteo-fibrous canal. Distally and somewhat downward both tendons pass under another ligament, the *inferior peroneal retinaculum* (*retinaculum mm. peroneorum inferioris*) attached to the lateral surface of the calcaneus (Fig. 171). The space under the inferior peroneal retinaculum is divided by a septum into two canals transmitting each tendon separately. The tendons of the peroneal muscles are invested in a common synovial sheath, which divides distally into two parts corresponding to the two canals under the inferior peroneal retinaculum.

The **dorsal fascia of the foot** (*fascia dorsalis pedis*) is rather thin distally from the inferior extensor retinaculum and only on the level with the base of the first metatarsal bone it has a thickening of arched fibres passing over the tendon of the extensor hallucis longus muscle.

The **fascia of the sole**, like the fascia of the palm, is greatly thickened and forms in its middle part a strong tendinous shining **plantar aponeurosis** (*aponeurosis plantaris*), which stretches from the calcaneal tuberosity of the base of the toes and is continuous proximally with the flexor digitorum brevis muscle which it covers. Toward the toes, the aponeurosis expands and separates into five slips between which transverse fibres pass. These slips termi-

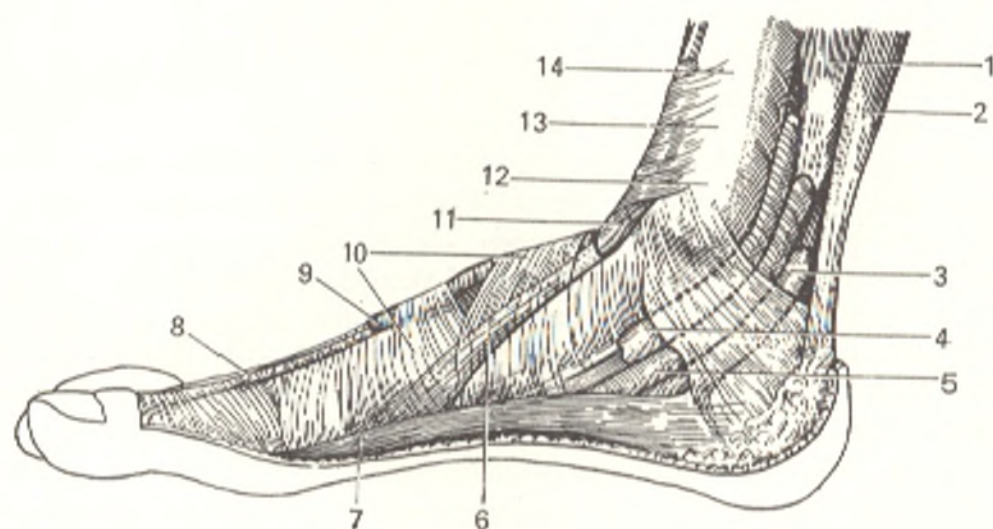


Fig. 170. Synovial sheaths of foot (medial aspect).

- |   |  |
|---|--|
| 1, m. flexor digitorum longus;                        | 8, tendo m. extensoris hallucis longi;           |
| 2, tendo calcaneus;                                   | 9, vagina tendinis m. extensoris hallucis longi; |
| 3, vagina tendinis m. flexoris hallucis longi;        | 10, retinaculum mm. extensorum inferioris;       |
| 4, vagina tendinis m. tibialis posterioris;           | 11, vagina tendinis m. tibialis anterioris;      |
| 5, vagina tendinis m. flexoris digitorum pedis longi; | 12, malleolus medialis;                          |
| 6, tendo m. tibialis anterioris;                      | 13, retinaculum mm. extensorum superioris;       |
| 7, m. abductor hallucis;                              | 14, tibia  |

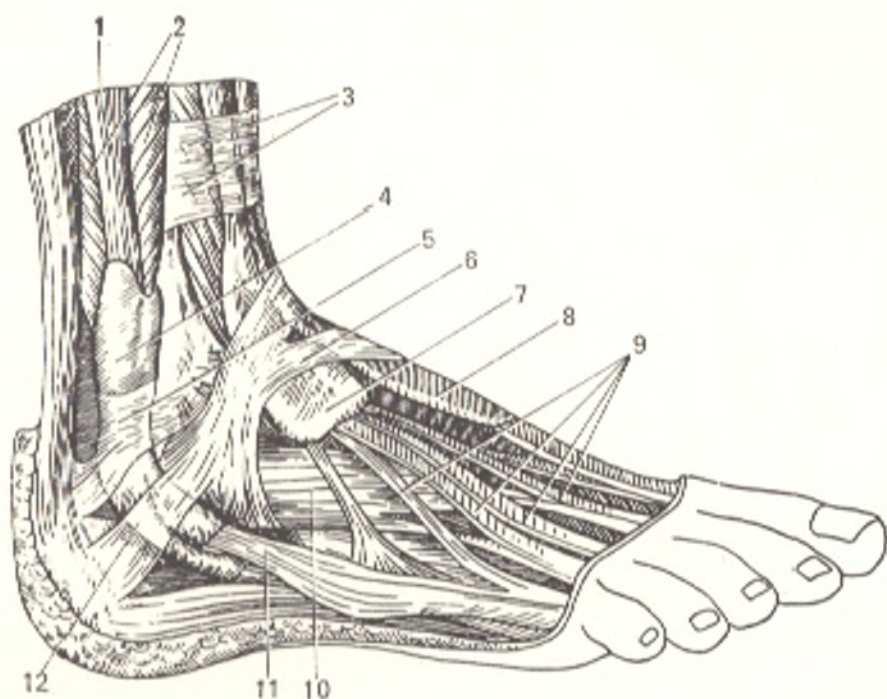


Fig. 171. Tendon sheaths, right foot, dorsolateral surface.

- 1, tendo m. peronei longi;  
 2, m. peroneus brevis;  
 3, retinaculum mm. extensorum superiorum;  
 4, vagina synovialis mm. peroneorum communis;  
 5, retinaculum mm. peroneorum superiorum;  
 6, retinaculum mm. extensorum inferiorum;

- 7, vagina tendinum m. extensoris digitorum pedis longi;  
 8, vagina tendinis m. extensoris hallucis longi;  
 9, tendines m. extensoris digitorum longi;  
 10, m. extensor digitorum brevis;  
 11, tendo m. peronei brevis;  
 12, retinaculum mm. peroneorum inferiorum

nate on the fibrous sheaths of the tendons on the toes. Two vertical septa arise from the edges of the plantar aponeurosis, pass upward between the muscles, and are attached to the deep fascia covering the interosseous muscles. These septa divide the sole into three incompletely closed compartments, which correspond on the whole to the three groups of muscles of the sole. According to certain authors, three fascial septa are also distinguished: lateral, medial, and intermediate. This is confirmed by the paths along which pus spreads on the sole. Several sheaths investing the tendons are found on the sole (Fig. 172). One of them, the tendon sheath of the peroneus longus muscle (*vagina tendinis m. peronei longi plantaris*), is lodged deep in the sole around the tendon of this muscle where the latter passes in the groove of the cuboid bone under the long plantar ligament. The other five sheaths (*vaginae tendinum digitales pedis*) invest the flexor tendons on the plantar aspect of the toes and stretch from the region of the metatarsal heads to the distal phalanges.

## TOPOGRAPHY OF THE LOWER LIMB

### CANALS TRANSMITTING THE VESSELS AND NERVES

The piriform muscle passes through the greater sciatic foramen above and below which narrow openings (*foramen suprapiriforme* and *foramen infra-piriforme*) remain and transmit the gluteal vessels and nerves.

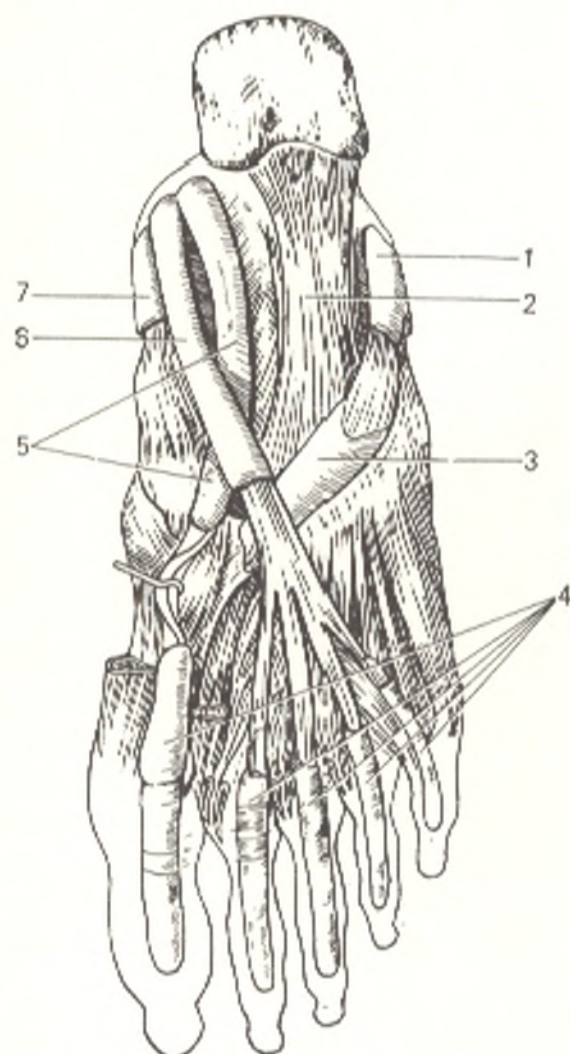


Fig. 172. Tendon sheaths, right foot, plantar surface.

- 1, vagina synovialis mm. peroneorum communis;
- 2, lig. plantare longum;
- 3, vagina tendinis m. peronei longi plantaris;
- 4, vaginae tendinum digitales pedis;
- 5, vagina tendinis m. flexoris hallucis longi;
- 6, vagina tendinis m. flexoris digitorum longi;
- 7, vagina tendinis m. tibialis posterioris

Sulcus obturatorius of the pubic bone is supplemented below by the obturator membrane and is thus converted to a canal (**canalis obturatorius**) providing passage for the obturator vessels and nerves.

The inguinal ligament runs over the hip bone from the superior anterior iliac spine to the pubic tubercle of the pubic bone and in this manner bounds the space between the above-named bone and ligament. Fascia iliaca passing in this space fuses in its lateral part with the inguinal ligament while its medial portion diverges from the ligament, thickens, and attaches to the iliopubic eminence. The part of this thickened band of fascia iliaca between the inguinal ligament and the iliopubic eminence is distinguished artificially under the name of the *iliopectineal arch* (*arcus iliopectineus*) (see Fig. 133).

*Arcus iliopectineus* divides the entire space below the inguinal ligament into two parts: a lateral, **muscular part** (*lacuna musculorum*) lodging the iliopsoas muscle and the femoral nerve, and a medial, **vascular part** (*lacuna vasorum*) for passage of the femoral artery and vein (the latter passes medially). From *lacuna vasorum* the vessels pass to the thigh, leg, and foot. The vessels and nerves pass in grooves, which are converted to canals and

then again opened to form grooves. According to the passage of the vessels and nerves, the following grooves (sulci) and canals are distinguished.

**Sulcus iliopectineus**, with which *lacuna vasorum* is continuous, lies between the iliopsoas (laterally) and the pectineal (medially) muscles and is then in turn continuous with **sulcus femoralis anterior** formed by the vastus medialis (laterally) and the adductor longus and magnus (medially) muscles. Both sulci are in the **femoral triangle** (*trigonum femorale*) bounded by the inguinal ligament (superiorly, the base of the triangle), the sartorius muscle (laterally) and the adductor longus muscle (medially). The floor of the triangle, called **fossa iliopectinea**, is formed by the iliopsoas and pectineal muscles. At the downward-facing apex of the triangle, **sulcus femoralis anterior** leaves it between the muscles and transforms into a canal, **canalis adductorius**, passing on the lower third of the thigh into the popliteal fossa. The canal is formed by the vastus medialis muscle (laterally), the adductor magnus muscle (medially), and a tendinous lamina, *lamina vastoadductoria*, running over them (anteriorly); its distal foramen is called *hiatus tendineus* (adductorius) formed by the diverging bundles of the adductor magnus muscle.

**Canalis adductorius** opens distally into the **popliteal fossa** (*fossa poplitea*) shaped like a rhomb. The superior angle of the rhomb is formed by the biceps muscle laterally and by the semimembranous and semitendinous muscles medially. The inferior angle is bounded by both heads of the gastrocnemius muscle. The floor of the fossa is formed by *facies poplitea femoris* and the posterior wall of the knee joint. The popliteal fossa contains fatty tissue with the popliteal lymph nodes. From the superior to the inferior angle pass the sciatic nerve (or its two branches into which it divides) and the popliteal artery and vein in the following order (from the surface and deeper): nerve, vein, artery.

The popliteal fossa is continuous with **canalis cruropopliteus** extending between the superficial and deep layers of the posterior leg muscles and mainly formed by the tibialis posterior (anteriorly) and the soleus (posteriorly) muscles. It provides passage for the tibial nerve and the posterior tibial artery and vein. A branch of this canal which corresponds to the course of the peroneal artery is **canalis musculoperoneus inferior** formed by the middle third of the fibula and the flexor hallucis longus and tibialis posterior muscles. **Canalis musculoperoneus superior** is in the upper third of the leg, between the fibula and the peroneus longus muscle; the superficial peroneal nerve passes in it. In line with the course of the plantar vessels and nerves, two grooves are found on the sole along the edges of the flexor digitorum brevis muscle: (1) a **medial groove** (*sulcus plantaris medialis*) between the above-indicated muscle and the abductor hallucis muscle and (2) a **lateral groove** (*sulcus plantaris lateralis*) between the same flexor and the abductor digiti minimi muscle.

#### THE FEMORAL CANAL

Under normal conditions the femoral canal does not exist; there is a narrow opening in the medial corner of *lacuna vasorum* called the **femoral ring** (*anulus femoralis*). The ring is bounded laterally by the femoral vein,

anteriorly and superiorly by the inguinal (Poupart's) ligament, medially by the lacunar ligament, which is a continuation of the inguinal ligament, and posteriorly by the pectineal ligament which is also a continuation, as it were, of the lacunar ligament on the pubic bone.

The anulus femoralis is filled with connective tissue (*septum femorale*), which is actually the subperitoneal fascia loosened here, and is covered by Pirogov's lymph node from the outside and by the peritoneum from the inside; the peritoneum forms here a depression (*fossa femoralis*). Femoral hernias may form through the femoral ring, more frequently in females than in males because it is wider in the former due to the broader pelvis. With the protrusion of a hernia anulus femoralis transforms into a canal with two openings, an inlet and an outlet.

The inlet, or *internal*, opening is the femoral ring (anulus femoralis) described above. The outlet, or *external*, opening is the hiatus saphenus, bounded by the falciform margin and its superior and inferior horns. The space between the openings is the **femoral canal** (*canalis femoralis*) (Figs. 133 and 168), which has three walls: **lateral**, formed by the femoral vein; **posterior**, formed by the deep layer of fascia lata femoris; and the **anterior** wall, formed by the inguinal ligament and the superior horn of the crescent-shaped margin of fascia lata. The latter is loosened in the hiatus saphenus and perforated by lymph vessels and v. saphena magna as a consequence of which it resembles a lattice and is called fascia cribrosa. Loosening of fascia lata femoris in the oval fossa is responsible for the protrusion of a femoral hernia just in this place.

## THE MOST IMPORTANT SPECIFIC FEATURES OF THE STRUCTURE OF THE MOTOR SYSTEM IN MAN DISTINGUISHING HIM FROM ANIMALS

I. *The trunk.* With the erect posture in man, curvatures formed in the spine (kyphoses and lordoses); the five sacral vertebrae fused to form a single bone, the sacrum; the short but wide thoracic cage (predominance of the frontal dimension) became a support for the muscles of the hand; the bulk of m. erector spinae increased considerably as a result of which the back became flat (only man can sleep on his back); the mass of the gluteal muscles also increased, particularly that of the gluteus maximus muscle (extending the trunk at the hip joints) which became simultaneously a soft cushion for sitting (only man can sit on a chair). Anthropoid apes can stand and walk on two limbs only for a short time, their trunk soon falls forward and they support themselves on the front limbs because the ischiatic (gluteal) musculature maintaining balance of man's erect body is weakly developed in them. That is why a child learning to walk, first learns to use its gluteal musculature, which in the first years of life grows faster than the other muscles.

II. *The head.* As man acquired an erect posture, the head with the sensory organs took a higher position favourable for observing the environment. The foramen magnum of the occipital bone proved to be lying almost on a horizontal plane. The sternocleidomastoid muscle holding the head and thus contributing to the maintenance of this position and the mastoid process, the site of its attachment of the bone, reached the highest developmental level. Due to the development of the brain, its receptacle, the cerebral cranium, attained the greatest dimensions (volume of up to 1500 cm<sup>3</sup>). As a result, its prevalence over the visceral cranium increased, the forehead became high and straight



while the jaws diminished in size. With the development of articulate speech the suprahyoid muscles differentiated, especially the muscle of facial expression around the mouth.

III. *The upper limb.* The upper limb became the organ of labour. As a consequence, all its links—the upper arm, forearm, and hand—became shorter but at the same time capable of wider and finer movements, namely: (1) maximum pronation and supination with the corresponding development of the radioulnar joint and muscles, pronators and supinators; (2) the ability not only to clasp but grasp objects due to the development of the thumb; this is facilitated by the large size of the short tubular bones, the saddle joint, and the thenar muscles, *m. opponens* in particular; (3) maximum flexion of each finger because each short tubular bone has a separately developed part of the flexor muscle (tendons of the flexor digitorum superficialis and profundus, lumbrical and palmar interosseous muscles); (4) the ability to straighten out the hand and each finger due to the high development of each tendon of the extensor digitorum muscle and the presence of additional extensors of the extreme (thumb and little finger) and the index fingers. Thus, the part of the upper limb possessing the most distinguishing structural features is the hand, the most important part of the organ of labour coming in direct contact with the tools of labour.

IV. *The lower limb.* The lower limb became the organ of standing and body movement. With the development of the erect posture, the pelvic girdle became firmly joined with the sacrum. As a result the pelvis formed, which is the bearing for the bones and muscles and the support for the viscera. It achieved the largest dimensions in man; the superior wing-like portion of the ilium deflected laterally; angulus subpubicus increased to form a right angle (in females). In accordance with the vertical position of the body, the pelvic inclination increased and the angle between the femoral neck and shaft decreased (in females it became a right angle). Steadiness of the body in the erect position improved because the hip joint was more limited in movements than the shoulder joint; Bertin's ligaments and the iliopsoas muscle, which prevent the body from falling backwards, sharply developed; the leg bones were incapable of pronation and supination but remained joined by syndesmoses allowing only a slight range of movement; the ligaments of the knee joint (cruciate and collateral) shifted so that they became stretched in extension of the joint and thus made standing easier. With the development of the upright posture, the foot lost the grasping function characteristic of apes and became the support for the whole body. The initial shape of the ape's flat grasping foot also drastically changed: three points of support formed in it, on the heel and great toe in particular, and it acquired an arched structure, which cushioned the jolts. As a consequence, some of the tarsal bones increased in bulk, especially the calcaneus, which became one of the three points of support (the posterior) of the foot on the ground. The phalanges, in contrast, with the loss of their importance, became smaller and at places even reduced (e.g. the phalanges of the little toe). The bony arch of the foot was reinforced by strong ligaments, especially *lig. plantare longum*, and by muscles. The muscles strengthened the foot both lengthwise (longitudinal arch) (the deep flexors of the foot and fingers) and transversely (the peroneus longus muscle and the transverse head of the adductor hallucis muscle).

In comparison to apes, the site of the origin of the leg and foot muscles in man has shifted laterally and the sites of their insertion moved to the medial border where most of them are concentrated near to the great toe, which they press to the ground and, consequently, contribute to pronation of the foot and the maintenance of the arch. With weakening of the arch the foot becomes flat like in apes, which is a pathological condition in humans (flatfoot).

## SURVEY OF MUSCLES ACCOMPLISHING MOVEMENT OF THE BODY SEGMENTS

### MOVEMENTS OF THE SPINE

Extension: the autochthonous musculature of the back in all its mass on both sides, including *m. splenius capitis* and *cervicis* and *m. trapezius* in the upper part.

Flexion: *m. sternocleidomastoideus*, *mm. scaleni*, *m. longus colli*, *m. rectus abdo-*

minis, mm. obliqui abdominis externus and internus, and m. psoas major. All of them contract on both sides.

Lateral flexion (to the right and left) is accomplished by the same muscles, which are responsible for flexion and extension but when they contract only on the side to which flexion occurs. They are aided by unilaterally contracting mm. levatores costarum, mm. intertransversarii, and m. quadratus lumborum.

Torsion (twisting to the right and left) is accomplished by muscles acting on one side: in the cervical segment the superior and inferior oblique slips of the longus colli muscle, the oblique slips of m. erector spinae (mm. rotatores and mm. multifidi), m. obliquus abdominis internus on the side to which the twisting is accomplished, and m. obliquus abdominis externus on the contralateral side.

### THE ATLANTOCCIPITAL JOINT

Extension (flinging back the head): m. trapezius (in fixation of the shoulder girdle), the superior slips of the deep muscles of the back attached to the skull (m. splenius, m. longissimus capitis, m. semispinalis, mm. recti capitis posteriores major and minor, m. obliquus capitis superior).

Both sternocleidomastoid muscles also accomplish extension of the head but flex the cervical segment of the spine.

Flexion (bending the head forward): m. rectus capitis anterior, m. rectus capitis lateralis, m. longus capitis, and the anterior muscles of the neck. All the muscles listed accomplish flexion and extension on bilateral contraction.

Lateral flexion of the head (to the right and left) is accomplished by the same muscles that cause flexion and extension but only on unilateral contraction, as well as by m. rectus capitis lateralis and m. longissimus capitis.

Twisting of the head (to the right and left): m. obliquus capitis superior and inferior, m. longus colli (the superior oblique slip), m. splenius, and m. sternocleidomastoides. All these muscles contract on one side.

### THE SHOULDER GIRDLE

Raising of the clavicle and scapula: superior slips of m. trapezius, m. levator scapulae, partly m. rhomboideus.

Lowering of the clavicle and scapula occurs mainly under the effect of gravitational attraction to which contraction of the inferior slips of m. serratus anterior and inferior fibres of m. trapezius, as well as m. pectoralis minor and m. subclavius contribute.

Forward movement: m. serratus anterior, m. pectoralis minor, m. pectoralis major (by means of the humerus).

Backward movement (of the clavicle and scapula): m. rhomboideus, the middle part of m. trapezius and m. latissimus dorsi (by means of the humerus).

Rotation of the scapula, which usually occurs at the end of the upward movement, is accomplished by the inferior slips of m. serratus anterior (they pull the inferior angle of the scapula laterally) and the superior fibres of m. trapezius (which pull the scapula upwards and medially). The opposite movement is accomplished by m. rhomboideus with the aid of m. pectoralis minor.

### THE SHOULDER JOINT

Flexion (forward movement): the anterior part of m. deltoideus, the clavicular part of m. pectoralis major, m. coracobrachialis, and m. biceps brachii.

Extension (backward movement): the posterior part of m. deltoideus, m. latissimus dorsi, and m. teres major. Since the last two muscles also rotate the arm medially, simultaneous contraction of m. infraspinatus and m. teres minor occurs to counteract it.

Abduction: m. deltoideus and m. supraspinatus.

Adduction: m. pectoralis major, m. latissimus dorsi, and m. teres major. M. infraspinatus and m. teres minor also contract to counteract the simultaneous medial rotation.

Medial rotation: *m. subscapularis*, *m. pectoralis major*, *m. latissimus dorsi*, and *m. teres major*.

Lateral rotation: *m. infraspinatus* and *m. teres minor*.

### THE ELBOW JOINT

Flexion: *m. biceps brachii*, *m. brachialis*, *m. brachioradialis*, and *m. pronator teres*.

Extension: *m. triceps brachii*, and *m. anconeus*.

Pronation: *m. pronator teres* and *m. pronator quadratus*.

Supination: *m. supinator* and *m. biceps brachii*. *M. brachioradialis*, which sets the forearm into a position intermediate between pronation and supination, also contributes to this movement.

### THE JOINTS OF THE HAND

Palmar flexion of the hand: *m. flexor carpi radialis*, *m. flexor carpi ulnaris*, as well as *m. palmaris longus*, *mm. flexores digitorum superficialis* and *profundus*, and *m. flexor pollicis longus*.

Dorsal flexion of the hand: *mm. extensores carpi radiales longus* and *brevis*, *m. extensor carpi ulnaris*, as well as all the extensors of the fingers.

Adduction of the hand (ulnar flexion): *m. extensor carpi ulnaris* and *m. flexor carpi ulnaris* acting simultaneously.

Abduction of the hand (radial flexion): *mm. extensores carpi radiales longus* and *brevis* and *m. flexor carpi radialis* contracting simultaneously.

### THE JOINTS OF THE FINGERS

Flexion of the lateral four fingers (with the exception of the thumb): *mm. flexores digitorum superficialis* and *profundus*. The proximal phalange is flexed, in addition, by *mm. lumbricales* and *mm. interossei*. *M. flexor digiti minimi brevis* contributes to flexion of the little finger.

Extension of the lateral four fingers: *m. extensor digitorum*; the index and little fingers have, in addition, their own extensors: *m. extensor indicis* and *m. extensor digiti minimi*.

Outspreading of the fingers (abduction from a line through the middle finger): *mm. interossei dorsales*.

Adduction of the fingers to a line through the middle finger: *mm. interossei palmares*.

Flexion of the thumb: *m. flexor pollicis longus* and *m. flexor pollicis brevis*.

Extension of the thumb: *m. extensor pollicis longus* and *m. extensor pollicis brevis*.

Abduction of the thumb: *m. abductor pollicis longus* and *m. abductor pollicis brevis*.

Adduction of the thumb: *m. adductor pollicis*.

Opposition of the thumb: *m. opponens pollicis*.

### THE HIP JOINT

Forward flexion (anteflexion): *m. iliopsoas*, *m. rectus femoris*, *m. tensor fasciae lata*, *m. sartorius*, and *m. pectineus*.

Extension (retroflexion): *m. gluteus maximus*, *m. biceps femoris*, *m. semitendinosus*, *m. semimembranosus*, *m. adductor magnus*, and other muscles approaching the greater trochanter from the back (*m. piriformis* and other muscles).

Abduction: *m. gluteus medius* and *m. gluteus minimus*.

Adduction: all the adductor muscles together with *m. gracilis* and *m. pectineus*.

Medial rotation: the anterior slips of *mm. glutei medius* and *minimus*.

Lateral rotation: *m. iliopsoas* (partly), *m. gluteus maximus*, the posterior slips of *mm. glutei medius* and *minimus*, *m. piriformis*, *m. obturatorius internus* with *mm. gemelli*, *m. quadratus femoris*, and *m. obturatorius externus*.

## THE KNEE JOINT

Extension: m. quadriceps femoris.

Flexion: m. semitendinosus, m. semimembranosus, m. biceps femoris, m. popliteus, as well as m. sartorius, m. gracilis, and m. gastrocnemius (when the leg is held fast below).

Medial rotation: m. semitendinosus, m. semimembranosus, m. popliteus, m. sartorius, m. gracilis, and the medial head of m. gastrocnemius.

Lateral rotation: m. biceps femoris and the lateral head of m. gastrocnemius.

## MOVEMENTS OF THE FOOT

Plantar flexion of the foot: m. triceps surae, m. flexor digitorum longus, m. tibialis posterior, m. flexor hallucis longus, and mm. peronei longus and brevis.

Dorsal flexion (dorsiflexion) of the foot: m. tibialis anterior, m. extensor digitorum longus, m. extensor hallucis longus, m. peroneus tertius.

Pronation (eversion) of the foot and abduction: m. peroneus longus, m. peroneus brevis, and m. peroneus tertius.

Supination (inversion) and adduction of the foot: m. tibialis anterior, m. tibialis posterior, m. extensor hallucis longus, and partly m. triceps surae.

## JOINTS OF THE TOES

Flexion of the toes: m. flexor digitorum longus and m. flexor digitorum brevis. The great toe has its own flexors: m. flexor hallucis longus and m. flexor hallucis brevis.

Extension of the toes: m. extensor digitorum longus and m. extensor digitorum brevis. The great toe is also extended by contraction of mm. extensor hallucis longus and brevis.

The above-described action of the pelvic and lower limb muscles is accomplished when the limb is not resting on the ground but is in a free, as if hanging, position. In this case the fixed point of the muscles is situated proximally and the mobile point distally. Usually, however, when a person is standing, walking, running, or making some other movements, the lower limb rests on the ground as a result of which the fixed mobile points change position.

## ELECTROMYOGRAPHIC INFORMATION ON THE ACTION OF MUSCLES

The elementary information on the action of muscles accounted here was gained from the study of a cadaver, a mechanical model or a live human being standing in a vertical position accepted as classical for description. A human body, however, may undergo different complicated conditions (the effect of reactive forces, interaction of muscular groups, changes in body statics and dynamics, etc.), which change the participation of muscles in some movements and require more accurate information on the action of individual muscles. Such information was recently gained by electromyography used by physiologists and neurologists in the diagnosis of the physiological condition of the muscular and nervous systems.

Electromyography provides the possibility for testing the electrical activity of muscles, which is produced by the contraction of the muscular fibres, i.e. for testing the contractile activity of muscles. Electromyographic analysis yields information on the functional activity of the musculature, which is more exact. The precise data gained by the method are, briefly, as follows.

**Muscles of the trunk, head, and neck.** In *flexion of the trunk* forward (foreward bending), contractile activity arises simultaneously in the rectus abdominis muscles and in the latissimus dorsi muscles; the activity of the rectus abdominis muscles in this case is recorded only during bending. When the trunk is held bent, activity is recorded only in the longissimus muscles but is absent in the rectus abdominis muscles.

Bending of the trunk is therefore associated with bilateral contraction of the muscles of the back. When the upper limbs rest on a support, activity of the muscles of the back

ceases immediately and recurs only when the trunk is no longer supported by the hands.

In *extension of the trunk*, contractile activity is also recorded only in the latissimus dorsi muscles but not in the abdominal muscles. When extension is continued beyond the erect position (backward bending), activity appears in the abdominal muscles and is inhibited in the muscles of the back.

Different relations between the abdominal muscles and those of the back form when the same movement of the trunk is accomplished but the person is lying on his side. Contractile activity is recorded only in the straight muscles of the abdomen in bending and only in the longissimus dorsi muscle in extension.

In *lateral bending* of the trunk in an erect position, contractile activity in the latissimus dorsi and iliocostal muscles on the same side is recorded only during movement of the trunk but disappears suddenly when the trunk is held bent and is not recorded for the time that it remains in this position. At the same time, contractile activity is recorded in the contralateral muscles both during bending and for the time that the trunk is bent.

In lateral bending of the trunk, the latissimus dorsi muscle on the side opposite to the bending displays its contractile activity while the latissimus dorsi muscle on the side to which the trunk is bent relaxes.

The absence of contractile (electrical) activity in the muscles of the back in some positions of the trunk associated with a certain occupation (e.g. forward bending of the trunk or lateral curvature of the spine during support on the hands) is very important in the formation of the carriage of this category of persons and may lead to stabilization of the spine in a defective position (round-shouldered back, scoliosis of schoolchildren).

In *turning and bending of the head*, the contractile activity of the muscles of the back on the contralateral side increases while that of the muscles of the same side is inhibited. The role of the trapezius and sternocleidomastoid muscles is particularly important in maintaining the position of the head. The masseter and temporal muscles are of decisive importance in holding the mandible in place (counteraction to the force of gravity).

Though the buccinator muscle is usually thought to be the muscle of trumpeters (hence its name), it plays only a passive role in distending the cheeks and blowing. On contraction it retracts the angle of the mouth, compresses the lips, and when the mouth is full participates in chewing, contributing to lowering of the mandible.

**Muscles of the upper limb.** All three parts of the deltoid muscle participate in *abduction of the limb*; the middle part is most active, while the posterior part is least active.

In *flexion of the upper limb*, i.e. in its forward and upward movement, the anterior and middle parts of the deltoid muscle contract and the activity of the anterior part predominates. The posterior part does not participate in the elevation, but aids in holding the limb raised.

The biarticular muscles (mm. biceps and triceps humerus) as well as latissimus dorsi and pectoralis major hardly help in holding the upper limb elevated forward and laterally. When one upper limb is raised forward, contractile activity is recorded in the muscles of the back on both sides; in abduction of the limb the contralateral muscles on the back are active.

Electromyography not only adds to our ideas of the functioning of muscles, but also introduces corrections to the traditional conceptions of their activity. For instance, it helped establish that the pronator quadratus plays the main role in pronation of the forearm, while the pronator teres only aids it. The latter muscle is mainly concerned with flexion of the forearm. It was also found that the brachioradial muscle only flexes the forearm.

**Muscles of the lower limb.** M. rectus femoris is predominantly an extensor of the knee joint; its role as a flexor of the hip joint when the pelvis is held firm is negligible. The action of m. quadriceps femoris is therefore aimed only at extending the limb at the knee joint. In extension of the hip joint with the limb held straight at the knee joint, the antagonistic relations of the anterior and posterior groups of muscles of the thigh are replaced by synergistic relations in which the activity of the posterior muscles predominates. M. iliopsoas plays a very important role in maintaining an upright position by preventing excessive extension at the hip joint.

M. peroneus longus is especially important in maintenance of the arch of the foot. The results of electromyography made it possible to establish that such a complex

act as walking is accomplished not only by the muscles of the lower limbs but also by those of the back. The following relations form between the different groups of muscles of the back during walking in which the body rests now on one and now on the other limb: all the muscles on the side of the raised limb are in a state of activity, while the activity of all the muscles on the side of the limb serving as the support at the given moment is inhibited.

Electromyography employed in physiology and in the clinic is still not accepted in the practice of anatomical study, which explain the incompleteness of the information concerning the action of each individual muscle.

As it is indicated above the new method of electroroentgenography demonstrates in a live person an X-ray image of the soft tissues, i.e. skin, subcutaneous fat, cartilages, ligaments, and muscles in particular.

Electroroentgenographs of the limbs show separate bundles of muscle fibres, the muscles which they compose, the direction and thickness of the muscular bundles, and the connective-tissue septa separating one muscle from another.

Thus, electroroentgenography is giving rise to a new branch of roentgenoanatomy, roentgenomyology.

# THE SCIENCE OF THE VISCERA (SPLANCHNOLOGY)

## GENERAL INFORMATION

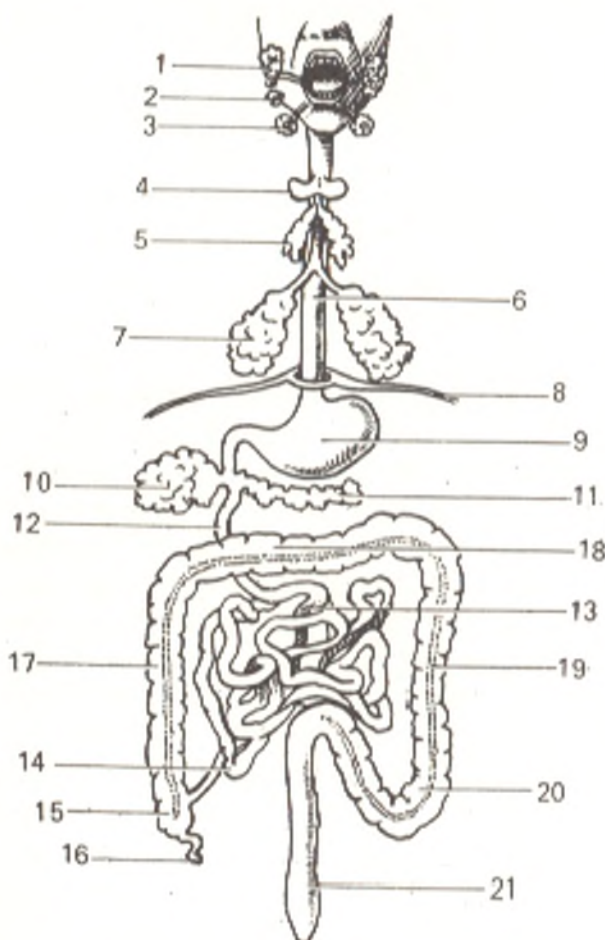
The **internal organs** (*viscera*, s. *splanchna*) are organs lodged mainly in the body cavities (abdominal and thoracic). This includes the digestive, respiratory, and urogenital systems. The viscera (Fig. 173) are concerned with metabolism; the sex organs are an exception to this, they are concerned with reproduction. All these processes are also inherent in plants, that is why the viscera are also called the organs of vegetative life. As distinct from the muscular system developing primarily in the dorsal part at the sides of the notochord and the cerebral tube, the organs of vegetative life are laid down in the ventral part of the embryo. Here, as it is indicated on p. 66 the entoderm forms the vegetative (intestinal) tube, which is surrounded by the abdominal parts of the mesoderm (splanchnotomes or lateral plates) in the form of paired coelomic sacs containing the secondary body cavity, the coelom. The walls of the sacs, which adjoin the entoderm, form the visceral layer of the mesoderm, the *splanchnopleure*, while the walls adjoining the ectoderm form the parietal layer of the mesoderm, the *somatopleure* (see Figs. 2 and 3). From these layers the epithelium of the membranes is derived. The ectoderm and the somatopleure give rise to the walls of the body, whereas the primitive alimentary canal, in which three parts (the foregut, midgut, and hindgut) are distinguished, forms the basis for the development of the alimentary and respiratory organs. The somatopleure and splanchnopleure bound the embryonic body cavity, the coelom, from which four serous sacs form by division: three sacs in the thoracic cavity (the two pulmonary pleural sacs and the pericardium) and one in the abdominal cavity (the abdominal sac). Another two small serous sacs are located in the scrotum; they invest the male sex glands and are in essence appendages broken off from the abdominal sac.

The development of the urogenital system differs from the development of the other viscera. The primary germ of this system appears not in the primary alimentary canal but at the junction of the mesoderm both with the somatopleure and the splanchnopleure. The development of the viscera is described in more detail below.

Though lodged in the cavities, the visceral systems communicate, nonetheless, with the external environment. The alimentary canal passing through the whole body has an entrance, an orifice in the upper (anterior) end of the body through which food is taken, and an exit, an orifice in the lower (posterior) part of the body through which the waste matter of digestion is discharged. The respiratory system has only one orifice of the tube through

Fig. 173. Organs of the neck and the thoracic and abdominal cavities represented schematically.

- 1, parotid salivary gland;
- 2, sublingual gland;
- 3, submandibular gland;
- 4, thyroid gland;
- 5, thymus;
- 6, oesophagus;
- 7, lungs;
- 8, diaphragm;
- 9, stomach;
- 10, liver;
- 11, pancreas;
- 12, duodenum;
- 13, jejunum;
- 14, ileum;
- 15, caecum;
- 16, vermiform process;
- 17, ascending colon;
- 18, transverse colon;
- 19, descending colon;
- 20, sigmoid colon;
- 21, rectum



which air gains entrance during respiration; it is at the upper (anterior) end of the body. As it is pointed out above, the respiratory tube is actually a branch of the upper part of the primary alimentary canal (it arises from the anterior, or ventral, surface of the canal). In the intrauterine period, the upper end of the respiratory tube situated above the branching is subdivided by a horizontal septum into two parts, upper and lower. The lower part (the oral cavity) is the initial part proper of the alimentary canal communicating with the external environment by means of the oral orifice. The upper part (the nasal cavity) serves for the passage of air and has special orifices (the nostrils). The urogenital system has only one exit, an opening in the lower end of the body in front of the orifice of the alimentary canal.

The formation of the tubes and their openings in the intrauterine period reflects the phylogenesis. During phylogenesis, the primary alimentary canal appears first as a tube stretching through the entire body of the animal from the cephalic to the caudal end and has an entry (on the cephalic end) and an exit (on the caudal end). Ultimately, from the cephalic end of this canal form the respiratory organs whereas its caudal part communicates with the urogenital organs as a result of which the cloaca forms in it; this is the common opening for the organs of digestion, excretion, and reproduction. The urogenital organs of higher mammals are set apart from the other organs and acquire their own orifice. As a result the organs of vegetative life in higher



vertebrates and humans are represented by three tubes communicating with the external environment by means of openings: (1) the *alimentary canal*, which passes through the entire body and has two openings, an entry (the mouth) and an exit (the anus); (2) the *respiratory tube* has one opening, the entry (the nose); (3) the *urogenital tube*, or, to be more precise, two tubes, urinary and genital, with only one exit, an orifice on the lower (caudal) end of the body in front of the orifice of the alimentary canal; in males this is the urethra and in females the urethra and the vagina. The organs derived from the primary alimentary canal that stretches along the entire length of the body and possesses an entry and an exit are lodged in the thoracic and abdominal body cavities. The organs that developed from the respiratory tube are lodged only in the thoracic cavity. These organs possess only an entry orifice which begins on the cephalic end of the body. Finally, the urogenital organs that possess only an exit orifice are lodged mainly in the lower part of the abdominal cavity (pelvic). As it is indicated above, the urogenital system in males has only one exit orifice situated in front of the orifice of the alimentary canal; females have two orifices for the urinary and sex systems. Therefore, there are three exit orifices in females (in the order from front to back): that of the urethra, the vagina, and the rectum (anus). The tubes of the vegetative organs constructed according to this plan become more complicated in shape due to the difference in growth of their different parts. A common principle can be detected in these modifications: tubes of least volume receive the largest surface for metabolism (P. F. Lesgaft).

The thoracic and abdominal cavities are lined with a special type of *serous membranes* (the pleura, pericardium, peritoneum) which are also reflected onto the viscera and in this way contribute partly to their fixation in a definite position. In structure, the *serous membrane* (coat) (*tunica serosa*) is composed of fibrous connective tissue covered on the external free surface by single-layer squamous epithelium (mesothelium). It is connected to the underlying tissue by loose subserous *areolar tissue* (*tela subserosa*), which is irregularly developed. The free surface of the serous membrane is smooth and moist as a consequence of which the organs covered by it have the lustre of a mirror. Owing to its smooth and moist surface, the serous membrane reduces friction between the organs and the surrounding parts during movement. In places devoid of the serous membrane, the surface of the organs is covered by a layer of fibrous connective tissue, *adventitia* (L. outermost), which connects them with the neighbouring parts. In contrast to the serous membrane covering the organs from the outside, the *mucous membrane* (coat) (*tunica mucosa*) forms their lining. It usually appears rather moist, covered with mucus, and its colour ranges from pale pink to a brighter red (depending on the extent of the filling of the vessels with blood).

In structure, the mucous membrane consists of: (1) epithelium and (2) lamina propria mucosae (the connective-tissue foundation of the mucosa). Lamina propria contains glands and lymphoid structures; at the junction with the subserosa, lamina propria contains a thin layer of smooth muscle fibres (lamina muscularis mucosae). Under it is tela submucosa connecting the mucosa with the externally situated muscle layer (tunica muscularis).

Besides occasional epithelial cells secreting mucus (goblet cells or monocellular glands), the mucous membrane possesses complexes of epithelial cells of a more complicated structure, which form *glands (glandulae)* (Gk *aden*, gland, hence adenitis, inflammation of a gland). In origin these multicellular glands are processes of the epithelium penetrating the underlying tissue. Tubular (a simple tube), alveolar (a sac-like dilatation, alveolus), and mixed (alveolar-tubular) glands are distinguished. The walls of the tube or the alveolus are composed of glandular epithelium and secrete material which flows onto the surface of the mucous membrane through the orifice of the gland. *Simple glands* consist of a single tube or alveolus, compound glands are formed of a system of branching tubes or alveoli which finally drain into a single tube, the efferent duct. A *complex gland* is usually divided into lobuli separated one from another by layers of connective tissue.

The mucous membrane usually also contains lymphoid tissue which is reticular connective tissue (its fibres form a network reticulum); in its loops are lodged lymphocytes. At places, the lymphoid tissue aggregates to form small lymph nodes, or follicles. The lymphoid tissue is developed better in children.

The *muscular coat* of the vegetative tubes (*tunica muscularis*) situated between the external serous and the internal mucous membranes (coats) is formed of smooth muscular tissue; the superior and inferior parts of the alimentary canal also contain striated fibres.

## THE DIGESTIVE SYSTEM (SYSTEMA DIGESTORIUM)

The **digestive (alimentary) system** (*systema digestorium*) is a complex of organs whose function consists in mechanical and chemical treatment of food, absorption of the treated nutrients, and excretion of undigested remnants of the food. The structure of the *digestive (alimentary) canal (canalis digestorius, s. alimentarius)* is determined in the different animals and in man in the process of evolution by the shape-forming effect of the environment: (nutrition). The human alimentary canal is about 8-10 m long and is subdivided into the following parts: the cavity of the mouth, the pharynx, the oesophagus, the stomach, and the small and large intestine. The upper three parts located in the head, neck, and chest maintain a relatively straight direction. In the pharynx the alimentary canal intersects with the respiratory tract. After the oesophagus passes through the diaphragm, the digestive tube dilates and thus forms the stomach; the next in order after the stomach, the small intestine, is in turn composed in the duodenum, jejunum, and ileum. The large intestine consists of the caecum with the vermiform process, the ascending, transverse, descending, and sigmoid colon, and, finally, the rectum.

These parts of the digestive tract in the different mammals differ in the extent of their development, depending on the mode of life and the character of nutrition. Since vegetable food, differing greatly in chemical composition from the body of animals, needs to be treated more vigorously, the in-

testine of herbivores is very long and the large intestine is especially developed; in some animals, e.g. in the horse, the large intestine acquires accessory blind processes, in which the undigested food remnants undergo fermentation like in a fermenting vat. The stomach of some herbivores has several chambers (e.g. the four-chamber stomach of the cow). In contrast, the intestine in carnivores is much shorter, the large intestine is less developed, and the stomach always consists of a single chamber. In structure of the digestive tract, omnivores occupy an intermediate position. Man is an omnivore.

The entodermal primary alimentary canal is subdivided into three parts: (1) *anterior* (the *foregut*), from which develop the posterior part of the mouth, the pharynx (except for the superior area close to the choanae which is of ectodermal origin), the oesophagus, the stomach, and the initial part of the duodenum (the bulb); (2) *middle part* (the *midgut*) communicating with the yolk sac and developing into the small intestine, and (3) the *posterior part* (*hindgut*), from which the large intestine develops. Some histologists claim that the portion of the foregut up to the junction with the stomach has a cutaneous-type epithelium, which explains the sharp borderline where the epithelium of the oesophagus is continuous with that of the stomach which is derived from the entoderm.

According to the different function of the different segments of the digestive tract, the three membranes of the primary alimentary canal, mucous, muscular, and connective-tissue, acquire different structure in the different parts of the canal.

## DERIVATIVES OF THE FOREGUT

### THE CAVITY OF THE MOUTH

The **cavity of the mouth**, *oral cavity* (*cavitas oris*) is divided into two parts, the *vestibule of the mouth* (*vestibulum oris*) and the *cavity of the mouth proper* (*cavitas oris proprium*) (Fig. 174). The vestibule of the mouth is the space bounded by the lips and cheeks externally and by the teeth and gingivae internally. By means of the *opening of the mouth*, the *oral fissure* (*rima oris*), the vestibule opens into the external environment.

The **lips** (*labia oris*) are fibres of the orbicular muscle of the mouth covered on the outside by the skin and lined inside with mucous membrane. At the angles of the oral fissure the lips come together by means of *commissures* (*commissurae labiorum*). The skin on the lips is continuous with the mucous membrane of the mouth; extending from the upper lip to the surface of the **gum** (*gingiva*) the mucous membrane forms on the midline a rather conspicuous fold, *frenulum labii superioris*. *Frenulum labii inferioris* is usually hardly noticeable. Epithelial villi (*torus villosus*) are seen in the region of the angle of the mouth and on the posterior margin of the vermilion border of the lip in the newborn; they help the infant to grasp and hold in the mouth the mother's nipple during sucking.

The cheeks (*buccae*) are similar to the lips in structure but instead of *m. orbicularis oris*, the buccinator muscle (*m. buccinator*) is situated here. The fat lodged in the thickness of the cheeks (*corpus adiposum buccae*) is developed much better in the child than in an adult and is conducive to a decrease of pressure on the part of the atmosphere during sucking.

*Cavitas oris proprium* extends from the teeth anteriorly and laterally to the entry into the pharynx posteriorly. The oral cavity is bounded superiorly by the hard palate and the anterior part of the soft palate; the floor is formed by the *diaphragm of the mouth* (*diaphragma oris*) (the paired mylohyoid muscles) and is occupied by the tongue. When the mouth is closed, the tongue comes in contact with the palate so that the oral cavity becomes narrow slit-like space between them. The mucous membrane extending to the inferior surface of the tip of the tongue forms on the midline the *frenulum of the tongue* (*frenulum linguae*). On each side of the frenulum is a noticeable

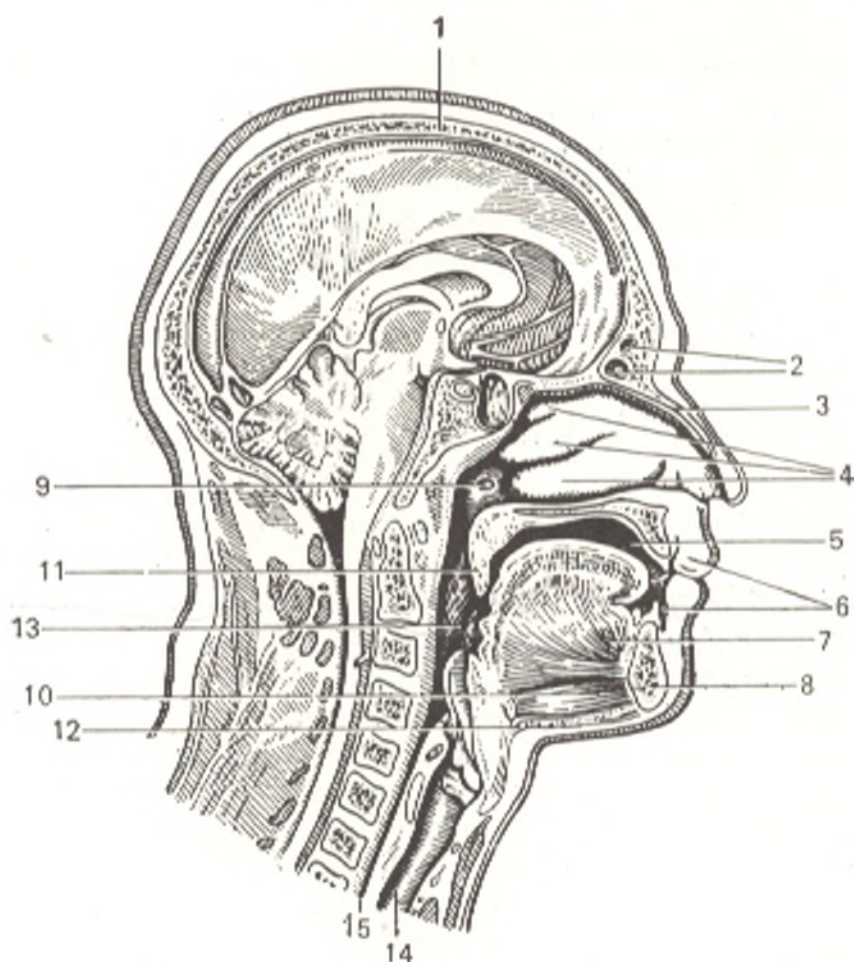


Fig. 174. Sagittal section through medial plane of head and neck.

- |   |                                       |
|---|---------------------------------------|
| 1, calvaria;                                      | 8, mandibula;                         |
| 2, sinus frontalis;                               | 9, ostium pharyngeum tubae auditivae; |
| 3, os nasalis;                                    | 10, m. geniohyoideus;                 |
| 4, conchae nasalis superior, media, and inferior; | 11, uvula;                            |
| 5, cavum oris;                                    | 12, m. mylohyoideus;                  |
| 6, vestibulum oris;                               | 13, tonsilla palatina;                |
| 7, m. genioglossus;                               | 14, trachea;                          |
|   | 15, oesophagus                        |

eminence, *caruncula sublingualis*, with the openings of the ducts of the submandibular and sublingual salivary glands. The *sublingual fold* (*plica sublingualis*) stretches on each side laterally and posteriorly of the sublingual caruncle; it is formed by the sublingual salivary gland situated here.

## THE PALATE

The **palate** (*palatum*) consists of two parts. Its anterior two thirds have a bony foundation, *palatum osseum* (the palatine process of the maxilla and the horizontal plate of the palatine bone); this is the **hard palate** (*palatum durum*). The posterior third, the **soft palate** (*palatum molle*) is a muscular structure with a fibrous foundation. During quiet breathing through the nose it hangs obliquely downward and separates the oral cavity from the pharynx (Fig. 175). A seam, *raphe palati*, is seen on the midline of the palate. At the anterior end of the raphe is a row of transverse ridges (about six of them), *plicae palatinae transversum* (rudiments of palatine ridges contributing in some animals to the mechanical treatment of the food). The mucous

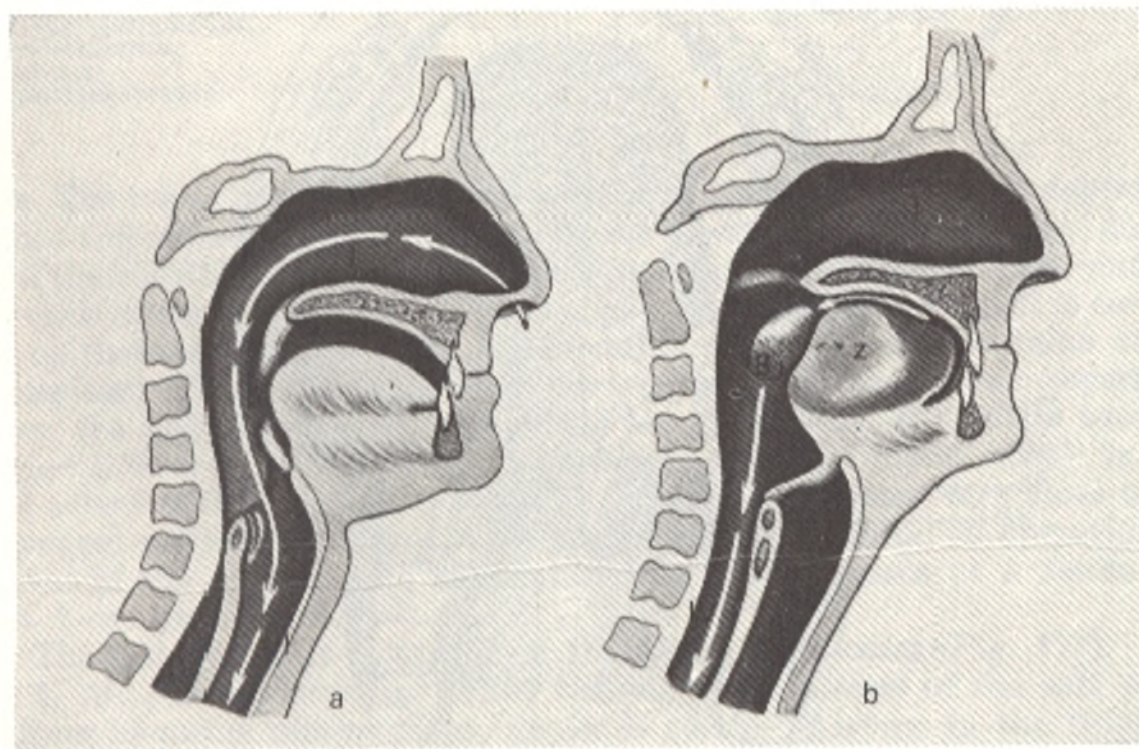


Fig. 175. The oral, nasal, and pharyngeal cavities.

*a*, during inhalation; *b*, during swallowing, the inhaled air enters the pharynx through the nasal cavity; the uvula is drawn toward the closed oral cavity containing rarefied air; the epiglottis is raised as the result of which the air gains entrance into the trachea, while the oesophagus is pressed to the pharynx and closes the path to the stomach, the bolus glides along the back of the tongue

into the pharynx. The uvula raises under the effect of the pressure in the mouth and contraction of the muscles and separates the nasal part of the pharynx from the oral part so that the food cannot enter the nasal cavity. The epiglottis is pressed downward and closes the trachea and prevents the food from entering it. The food drops into the dilated oesophagus.

membrane covering the inferior surface of the hard palate adheres closely to the periosteum by means of dense fibrous tissue.

The **soft palate** (*palatum molle*) is a duplication of the mucous membrane in which muscles are lodged together with a fibrous plate, the palatine aponeurosis, as well as glands (Fig. 176). Its anterior margin is attached to the posterior edge of the hard palate, while the posterior part of the soft palate (*velum palatinum*) extends freely downward and to the back and has on the midline a tongue-like projection, the *uvula*.

Laterally, the soft palate is continuous with folds, or arches. The anterior **palatoglossal arch** (*arcus palatoglossus*) passes to the lateral surface of the tongue, the posterior **palatopharyngeal arch** (*arcus palatopharyngeus*) stretches for some distance on the lateral wall of the pharynx. A depression forms between the anterior and posterior arches which lodges the **palatine tonsil** (*tonsilla palatina*). Each palatine tonsil is an oval-shaped mass of lymphoid

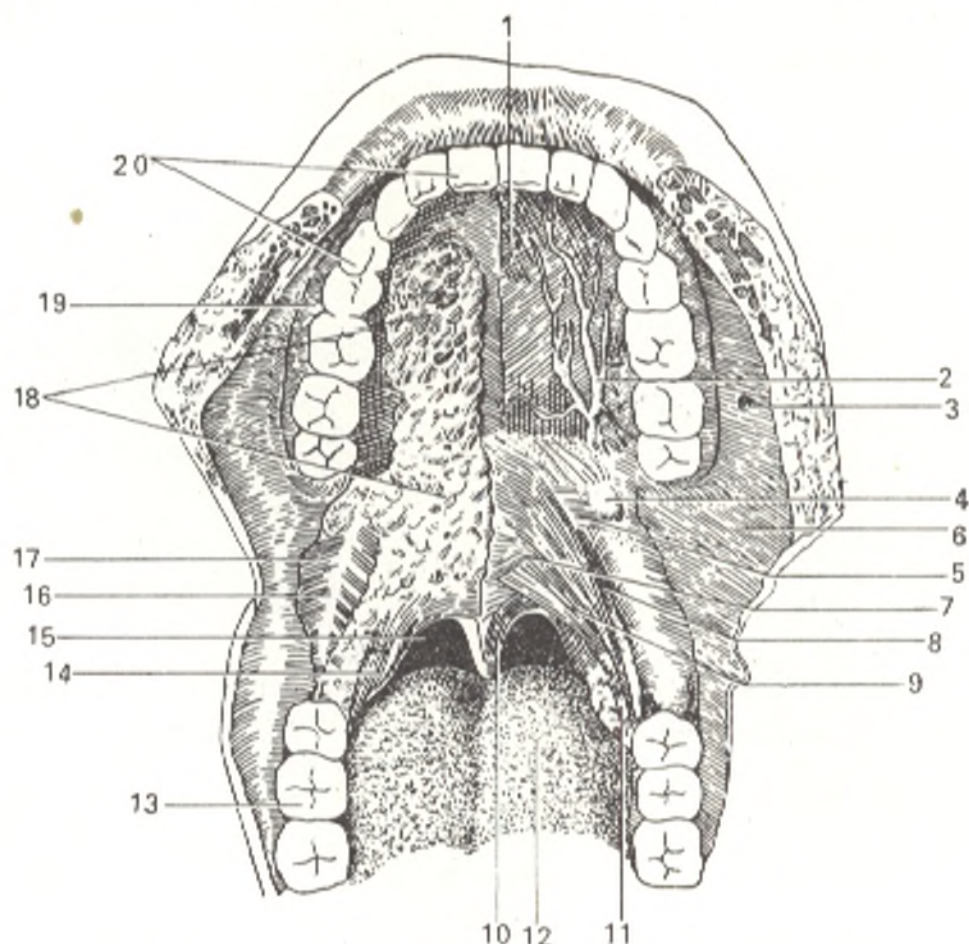


Fig. 176. The palate with the mucous membrane removed. Inferior aspect.

- 1, palatum durum;
- 2, artery supplying the palate;
- 3, opening of ductus parotideus;
- 4, hamulus pterygoideus;
- 5, m. tensor veli palatini;
- 6, tunica mucosa oris;
- 7, m. levator veli palatini;
- 8, m. constrictor pharyngis superior;
- 9, m. palatopharyngeus;
- 10, m. uvulae;

- 11, m. palatoglossus;
- 12, dorsum linguae;
- 13, arcus dentalis inferior;
- 14, tonsilla palatina;
- 15, isthmus faucium;
- 16, raphe pterygomandibularis;
- 17, m. buccinator;
- 18, glandulae palatinae;
- 19, gingiva;
- 20, arcus dentalis superior

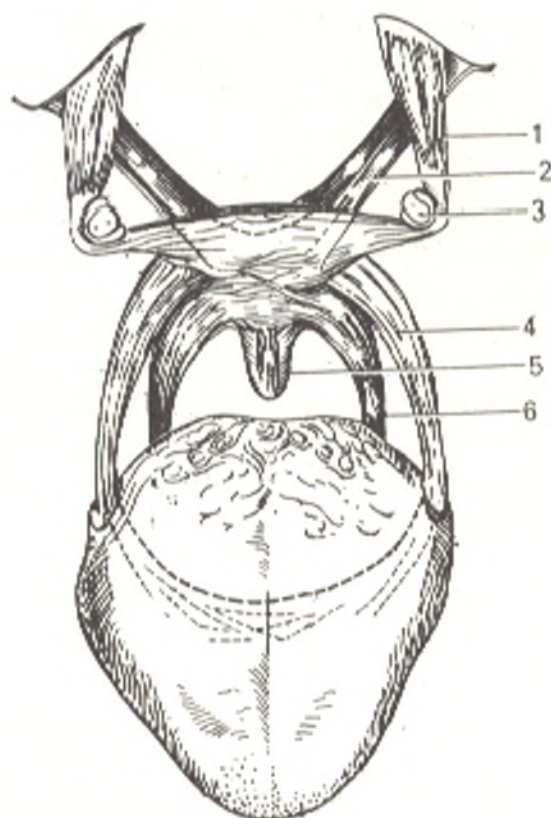


Fig. 177. Musculature of the soft palate represented schematically.

- 1, m. tensor veli palatini;
- 2, m. levator veli palatini;
- 3, hamulus pterygoideus;
- 4, m. palatoglossus;
- 5, m. uvulae;
- 6, m. palatopharyngeus

tissue. The tonsil occupies the greater inferior part of a triangular depression between the arches (*sinus tonsillaris* s. *fossa tonsillaris*). The vertical dimension of the tonsil is 20 to 25 mm, the anteroposterior 15 to 20 mm, and the transverse dimension 12 to 15 mm. The medial surface of the tonsil is covered with epithelium, has an irregular, nodular, contour, and contains crypts (depressions). The lateral surface is covered by a fibrous capsule separating it from the pharyngeal wall. According to recent data, the entire tonsil is invested in a very thin capsule. The nearest important blood vessel in the facial artery which sometimes (when it is tortuous) comes very close to the pharyngeal wall at this level. This must be borne in mind in operation for removal of the tonsils. The internal carotid artery passes at a distance of about 1 cm from the tonsil.

The soft palate is composed of the following *muscles* (Fig. 177).

1. *M. palatopharyngeus* arises from the aponeurosis of the soft palate and from hamulus pterygoideus, descends to the pharynx in the thickness of arcus palatopharyngeus, and is inserted in the posterior margin of the thyroid cartilage and the pharyngeal wall. It pulls the velum palatinum downwards and the pharynx upwards, in which case the pharynx becomes shorter and presses the soft palate to the posterior pharyngeal wall.

2. *M. palatoglossus*, arises on the inferior surface of the soft palate, descends in the thickness of arcus palatoglossus and is inserted on the side of the tongue where it is continuous with m. transversus linguae. It lowers velum palatinum and during this movement both palatoglossal arches become tense and the opening of the fauces is narrowed.

3. *M. levator veli palatini* originates on the inferior surface of the base of the skull and on the inferior surface of the cartilaginous part of the auditory tube and passes downwards and medially to the soft palate. It raises velum palatinum.

4. *M. tensor veli palatini* arises from spina ossis sphenoidalis and from the lateral surface of the membranous part of the auditory tube, descends vertically, its tendon curves around hamulus processus pterygoidei, turns medially almost at a right angle, and is inserted into the aponeurosis of the soft palate. It tenses velum palatinum in the transverse direction.

5. *M. uvulae* arises from spina nasalis posterior and from the aponeurosis of the soft palate and is inserted in the uvula. It shortens the uvula.

The uvula is present only in man because it is necessary to create a condition of air-tightness in the oral cavity, which prevents the jaw from hanging in the erect position of the body.

The aperture by means of which the oral cavity communicates with the pharynx is called the **fauces**, s. **isthmus faucium**. It is bounded on the sides by the palatoglossal arches, above by the soft palate, and below by the back of the tongue.

The palate is supplied with *nutrients* by a. facialis, a. maxillaris, and a. pharyngea ascendens (branches of a. carotis externa).

The *veins* carrying venous blood from the palate drain into v. facialis. The *lymph* drains into the submandibular and submental nodes.

*Innervation* of the palate is accomplished by plexus pharyngeus formed by the branches of the ninth and tenth pairs of cranial nerves, truncus sympathicus, nn. palatini, and n. nasopalatinus (second division of the trigeminal nerve). N. vagus innervates all the muscles of the soft palate with the exception of m. tensor veli palatini, which is supplied by the third division of the trigeminal nerve. Nn. palatini, n. nasopalatinus, and the ninth pair of cranial nerves are mainly concerned with sensory innervation.

## THE TEETH

The **teeth** (*dentes*) are ossified papillae of the mucous membrane concerned with the mechanical treatment of food (Figs. 178, 181, 182, and 183). Phylogenetically, the teeth are derived from the scales of fish which grow along the edge of the jaws but acquire here new functions. Since teeth wear away they are shed and replaced by new ones; this occurs repeatedly many times in lower vertebrates and only twice in man: (1) **deciduous teeth** (*dentes decidui*) and (2) **permanent teeth** (*dentes permanentes*). Sometimes the teeth are replaced for the third time (replacement of the teeth for the third time was encountered in a 100-year-old man).

The most important parts of the tooth, enamel and dentin, are found in the structure of sharks, so that one can speak of the homology of teeth in the process of evolution from shark fish to man. During evolution, the teeth of reptiles took a firmer position in the jaws, as a result of which two parts became distinguishable in the tooth: the part lodged in the alveoli of the jaws, the root, and the external part, the crown, concerned with mechanical treatment of the food. In this case, the diversity of food eaten by terrestrial animals and the development of their masticatory apparatus determine the



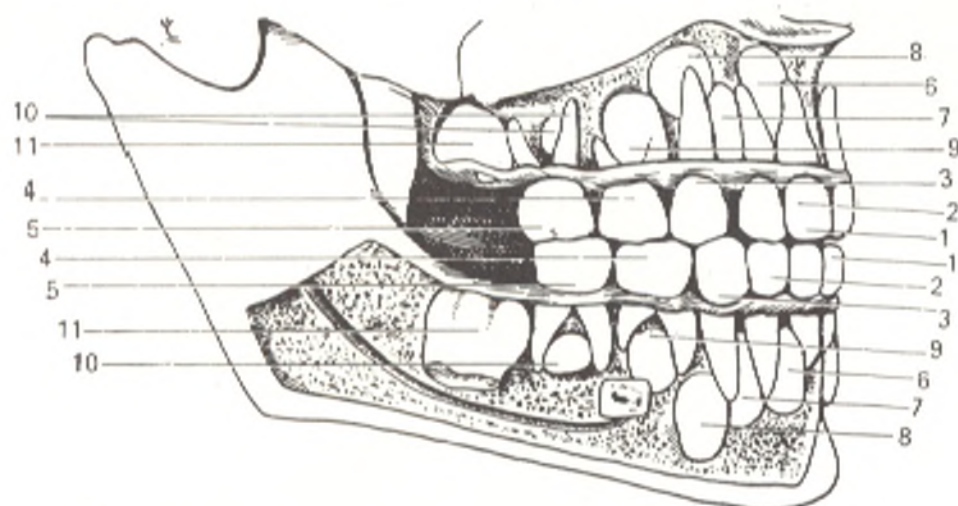


Fig. 178. Deciduous teeth and germs of permanent teeth.

- |   |                                    |
|---|------------------------------------|
| 1, medial (central) deciduous incisors; | 7, lateral permanent incisors;     |
| 2, lateral deciduous incisors;          | 8, permanent canines;              |
| 3, deciduous canines;                   | 9, anterior permanent premolars;   |
| 4, anterior deciduous molars;           | 10, posterior permanent premolars; |
| 5, posterior deciduous molars;          | 11, first permanent molars         |
| 6, medial permanent incisors;           |                                    |

development and specialization of the teeth. As a consequence, in distinction from the monotypical conic teeth of fish which serve only for the retention of food, the teeth of mammals acquired different shapes adapted to different types of food grasping and treating, namely: the tearing (the canine teeth), cutting (the incisor teeth), crushing (the premolars), and grinding of food (the molars).

Man, being omnivorous, has preserved all these types of teeth. Since the function of grasping changed from the jaws to the hands, however, the jaws became smaller and the teeth less in number. Placental mammals, for instance have 44 teeth (dental formula: 3. 1. 4. 3).<sup>1</sup> The number of teeth in the New World monkeys is less (2. 1. 3. 3=36), whereas in the Old World monkeys it is still less (2. 1. 2. 3 = 32). In man, the development of the third molar (the "wisdom tooth") is sharply delayed, which reflects the tendency of regression of the teeth. A toothless man has been described as a case of anomaly.

The teeth were the first hard structures in the body of ancient vertebrates, which developed before the other parts of the skeleton. Palaeontologists established that vertebrates originated in the Paleozoic era from the discovery of teeth, the only remnants of that time. Since the shape of teeth corresponds to the type of nutrition and the mode of life, the palaeontologist can recognize the fossils of animals and human beings by the teeth.

**Development of the teeth.** Development of the teeth in man begins approximately on the seventh week of embryonic life. By this time, thickening of the epithelium lining the oral cavity appears in the region of the future upper and lower jaws and projects as an arch-like lamina into the underlying mesenchyma. Soon this epithelial lamina, still

<sup>1</sup> The dental formula is discussed on p. 407.

penetrating deeper, divides longitudinally into two secondary laminae situated almost at a right angle to each other.

The anterior, or buccolabial, lamina splits eventually and transforms into an open epithelial fold separating the lip and the cheek from the gingiva and leading, consequently, to the formation of the vestibule of the oral cavity.

The posterior, dental, lamina passes almost horizontally at first, but as it gradually grows and penetrates deeper it becomes more vertical. Epithelial growths appear on the edge of the lamina; they take the shape of flask-like protrusions and are the germs of the deciduous teeth. They are called dental "flasks", or the enamel organs. After the enamel organs form, the dental lamina continues penetrating deeper so that the enamel organs prove to be situated on its anterior (i.e. facing the lip or cheek) surface.

Soon after its origin, the developing enamel organ acquires the shape of a bowl or bell with the corresponding depression being filled by mesenchyme forming the papilla of the tooth germ.

The enamel organs gradually lose their connection with the dental lamina because the mesenchyme proliferates into their necks, which disintegrate to form separate nests of epithelial cells. As a result the tooth germs are isolated absolutely.

With the further development of the isolated tooth germs, the components of the tooth develop in them in such a manner that the epithelial cells give rise to the enamel, the mesenchymal tissue of the papilla gives origin to the dentine and the pulp, while the mesenchyme initially investing the enamel organ as the dental sac gives rise to the cement and the root sheath.

Differentiation of the cells and the formation of dentine and enamel begin at the apex of the tooth germ and spread gradually to its base. Therefore, during the entire period of the development of the tooth germ more advanced stages are encountered at its apex while the nearer to its base the earlier are the developmental stages.

With the gradual growth of the tooth germ in length, the bony walls of the alveolus become higher.

The teeth are located in the alveolar processes of the maxilla and mandible and are jointed by means of gomphosis (*Gk gomphos*, belting together) (the term is incorrect because actually the teeth are not driven in from the outside, but grow from the inside; this is an example of the formalism of descriptive anatomy). The tissue covering the alveolar process is called the **gums** (*gingivae*). The mucous membrane is closely jointed to the periosteum here by means of fibrous tissue; the gingival tissue is rich in blood vessels (and therefore bleeds relatively easily) but poor in nerves.

The grooved depression between the tooth and the free margin of the gum is called the *gingival pocket*.

Each **tooth** (*dens*) consists of: (1) a **crown** (*corona dentis*), (2) a **neck** (*collum dentis*), and (3) a **root** (*radix dentis*) (Figs. 179 and 180). The crown is elevated above the gum, the neck (the slightly narrowed part of the tooth) is embraced by the gum, while the root sits in the dental alveolus and terminates in an apex (*apex radialis*), on which a small opening, the *apical foramen* (*foramen apicis*) is seen even with the naked eye. Vessels and nerves enter the tooth through this opening. Inside the tooth crown is a cavity (*cavum dentis*), in which are distinguished the *crown part*, the widest part of the cavity, and the *root part*, the narrowed part of the cavity called the *root canal* (*canalis radialis dentis*). The canal opens at the apex by means of the above mentioned apical foramen. The cavity of the tooth is filled with the *tooth pulp* (*pulpa dentis*) rich in vessels and nerves. The tooth roots fuse tightly with the surface of the tooth alveoli by means of the **alveolar periosteum** (*periodontium*)

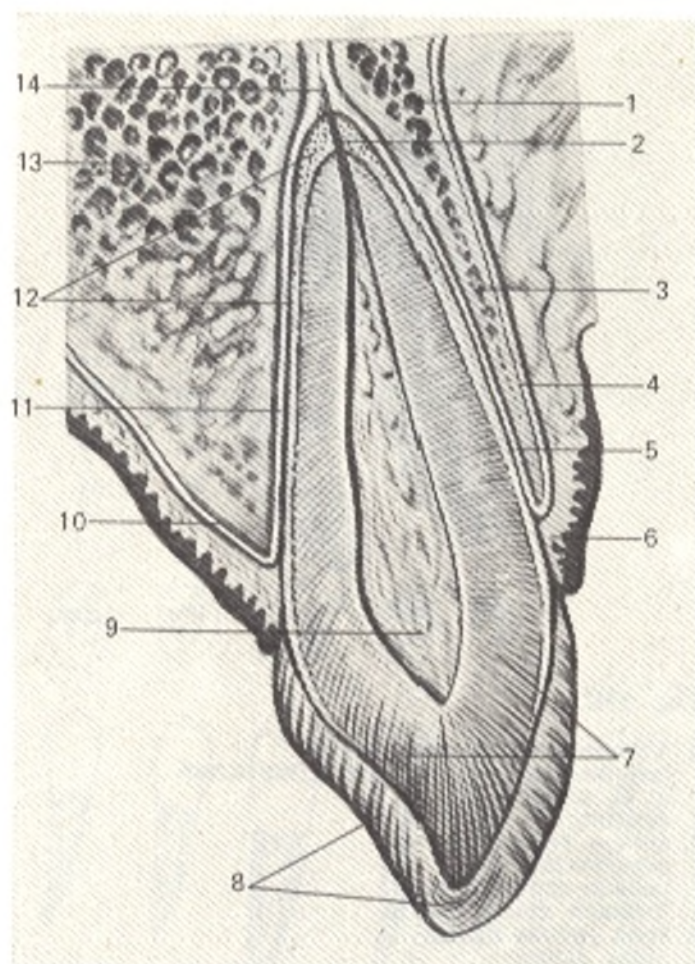


Fig. 179. Single-root tooth (schematic representation) and its position in the jaw (after Kiss and Szentagóthai).

- 1 and 13, substantia spongiosa maxillae;  
 2, canalis radialis dentis;  
 3, substantia compacta maxillae;  
 4 and 10, periosteum maxillae;  
 5 and 11, periodontium (periodontal membrane);  
 6, gingiva;  
 7, dentinum;  
 8, enamelum;  
 9, pulpa dentis;  
 12, cementum;  
 14, canal leading into foramen apicis dentis

supplied richly with blood vessels. The tooth, the periodontium, the alveolar wall, and the gingiva compose the **tooth organ**. The hard material of the tooth consists of: (1) *dentine* (*dentinum*), (2) *enamel* (*enamelum*), and (3) *cement* (*cementum*). The bulk of the tooth enclosing the cavity of the tooth is dentine. The crown is coated with enamel, while the root is covered with cement.

The teeth are so fitted into the jaws that the crowns are above the gums and form the dental rows, the upper (maxillary) and the lower (mandibular) rows. Each row consists of 16 teeth arranged in the form of dental arch.

Five surfaces are distinguished in each tooth (Figs 181, 182, and 183): (1) *facies vestibularis*, facing the vestibule of the mouth; in the anterior teeth it comes in contact with the lip mucosa and is called *facies labialis*, while in the posterior teeth it touches the mucosa of the cheeks and is called *facies buccalis*; (2) *facies lingualis*, s. *oralis*, facing the oral cavity, the tongue; (3) and (4) *facies contactus*, the surfaces coming in contact with the surfaces of the adjacent teeth. The contact surfaces directed towards the centre of the dental arch are designated *facies approximalis mesialis* (Gk *mesos* middle). This surface is medial in the anterior teeth but anterior in the posterior teeth. The contact surfaces directed away from the centre of the dental row are called *facies distalis*. In the anterior teeth this is the lateral surface, and in the posterior teeth, the posterior surface; (5) the *masticating surface* (*facies*

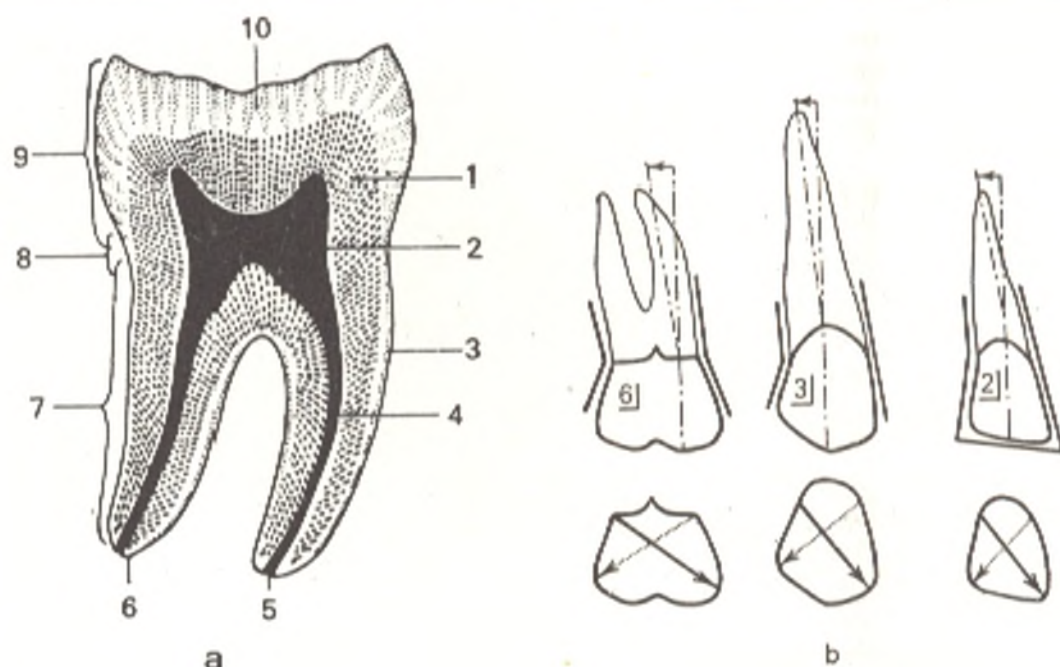


Fig. 180.

a, Two-root tooth, permanent  
(semischematic representation after  
R. D. Sineinikov;

- 1, dentinum;
- 2, cavum dentis;
- 3, cementum;
- 4, canalis radialis dentis;
- 5, foramen apicis dentis;
- 6, apex radialis dentis;
- 7, radix dentis;

- 8, collum dentis;
- 9, corona dentis;
- 10, enamelum.

b, Root inclination sign and crown angle  
sign (after P. Balakirev, S. Galperin, and  
G. Yasvoin).

Upper teeth on right side:

- 2, lateral incisor;
- 3, canine tooth;
- 6, first molar

*masticatoria*), or the surface for occlusion with the teeth of the opposite row (*facies oclusalis*).

To determine the location of a pathological process on a tooth, stomatologists use terms corresponding to the surfaces listed above: vestibular, oral, mesial, distal, occlusal, apical (towards the *apex radialis*).

The following three signs are used in *determining to which side, right or left, a tooth belongs*: (1) the root sign; (2) the crown angle sign, and (3) the crown curvature sign (see Fig. 180, b).

The *root sign*: the longitudinal root axis is inclined distally and forms an angle with a line passing through the middle of the crown.

The *crown angle sign*: the line of the masticating edge of the tooth forms a smaller angle where it passes to the mesial surface than where it passes to the distal surface.

The *crown curvature sign*: the vestibular surface of the crown is continuous more abruptly with the mesial than with the distal surface. Consequently, the mesial segment of the vestibular surface is more convex in the transverse direction than the distal segment. This is explained by the fact that the mesial part of the crown is developed more powerfully than the distal part. The mesiodistal slope of the crown is thus formed.

Whether a tooth belongs to the *upper* or *lower* jaw is established from the shape of the crown and the shape and number of the roots. It is therefore

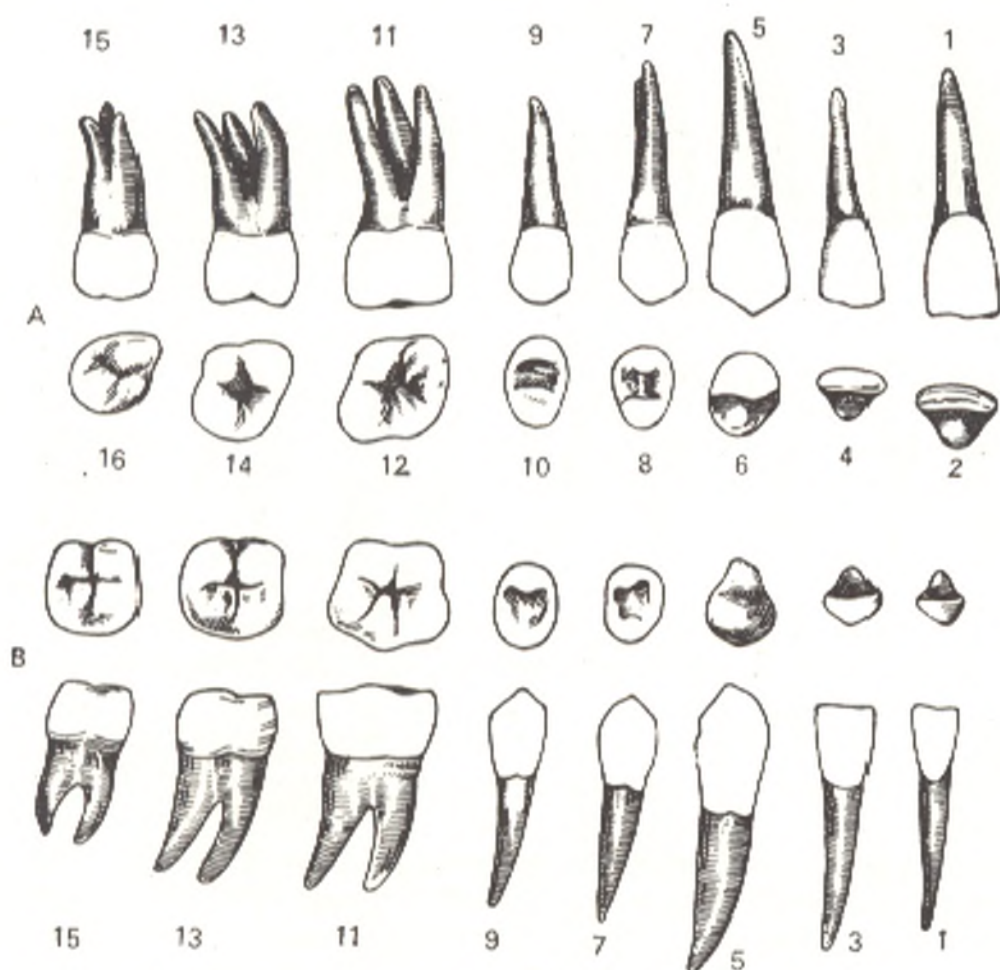


Fig. 181. Permanent teeth, right side (after R. D. Sinelnikov).

- a, maxillary teeth;  
 b, mandibular teeth.
- 1, central incisor, labial surface;  
 2, central incisor, cutting (incisal) edge;  
 3, lateral incisor, labial surface;  
 4, lateral incisor, cutting edge;  
 5, canine tooth, labial surface;  
 6, canine tooth, cutting edge;  
 7, first premolar, buccal surface;  
 8, first premolar, masticating surface;  
 9, second premolar, buccal surface;  
 10, second premolar, masticating surface;  
 11, first molar, buccal surface;  
 12, first molar, masticating surface;  
 13, second molar, buccal surface;  
 14, second molar, masticating surface;  
 15, third molar, buccal surface;  
 16, third molar, masticating surface

necessary to know the shape and the number of roots not only of a definite group of teeth but also of each separate tooth of the given group.

The **incisors** (*dentes incisivi*), four on each jaw, have a *crown* shaped like a cutting chisel; they cut food to the needed size. The crown of the upper incisors is wide, twice the width of that of the lower incisors. Each tooth has a single *root*, which in the lower incisors is flattened from the sides. The apex of the root deviates a little laterally.

The **upper (maxillary) medial (central) incisor** is the largest in the group of incisors. The labial surface of the *crown* is convex in the transverse and longitudinal directions. It has three longitudinal ridges each terminating on the mastication edge of the tooth in a small projection. On each side of the medial ridge is a longitudinal depression. The lingual surface of the crown is concave in the longitudinal and transverse directions. In the region

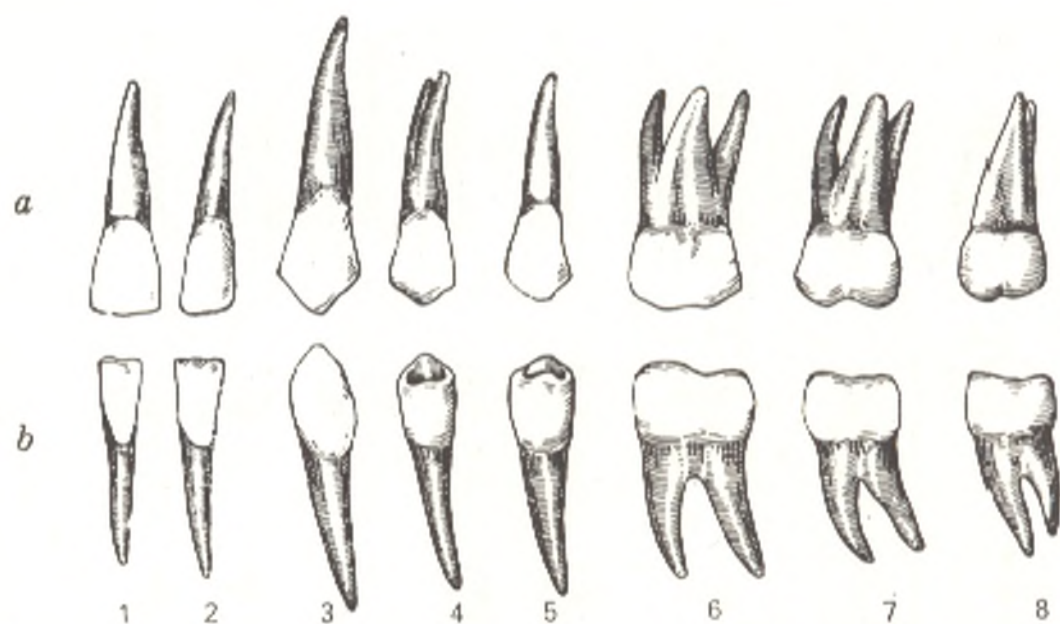


Fig. 182. Permanent teeth, dentes permanentes, right side (after R. D. Sinelnikov).

a, maxillary teeth, lingual surface;  
 b, mandibular teeth, lingual surface;  
 1, central incisor;  
 2, lateral incisor;  
 3, canine tooth;

4, first premolar;  
 5, second premolar;  
 6, first molar;  
 7, second molar;  
 8, third molar

of the neck it has a small tubercle (*tuberculum dentale*) from which ridges arise and pass along the lateral and medial margins of the lingual surface to the masticating edge of the tooth. Of the three tooth signs, the crown cur-

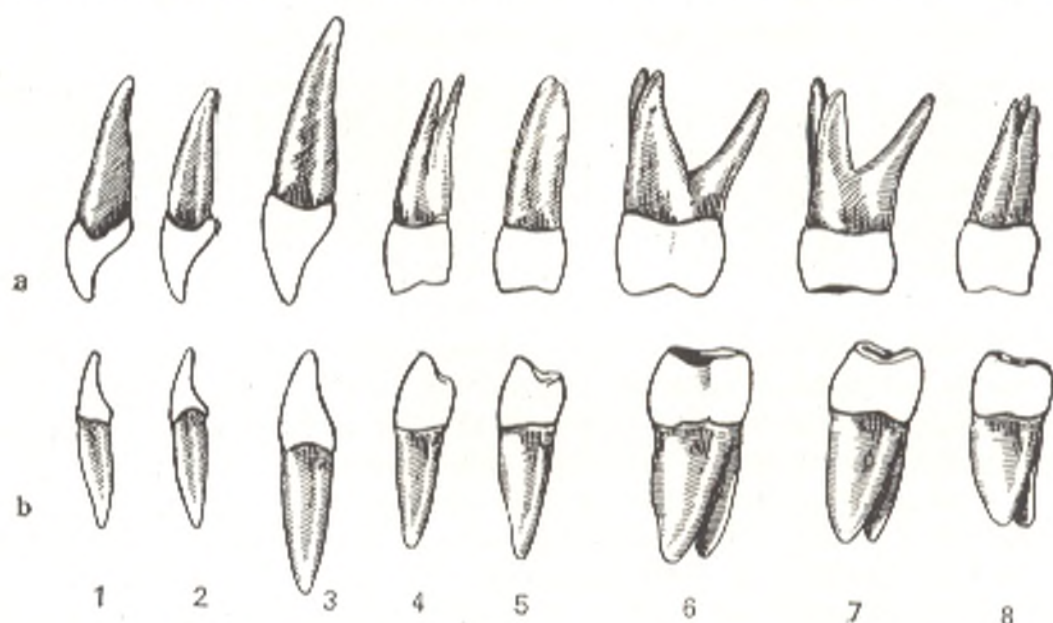


Fig. 183. Permanent teeth, right side (after R. D. Sinelnikov).

a, maxillary teeth;  
 b, mandibular teeth;  
 1, central incisor, mesial surface;  
 2, lateral incisor, mesial surface;  
 3, canine tooth, mesial surface;

4, first premolar, anterior surface;  
 5, second premolar, anterior surface;  
 6, first molar, anterior surface;  
 7, second molar, anterior surface;  
 8, third molar, anterior surface

vature sign is pronounced best. The *root* is conical and longer than the crown; the ridges on its sides are weakly pronounced. It has three surfaces, one labial and two contacting.

The **upper lateral incisor** is smaller than the medial (central) incisor from which it is distinguished by the following features; the labial surface of the *crown* often bears a medial longitudinal groove on each side of which on the cutting edge in non-eroded teeth is a small nodular eminence. The ridges on the sides of the lingual surface are usually pronounced better than those on the medial incisors. A depression (*foramen cecum*) is often seen on this surface below the dental tubercle. The mesial surface is longer than the distal (lateral) surface and meets the cutting edge almost at a right angle, while the junction of the lateral surface with the cutting edge is rounded. The crown angle sign is well pronounced. The *root* is shorter than that of the medial incisor and is flattened in the mesiodistal direction; in most cases it is straight and has grooves on the sides. Its lateral surface is more convex than the medial.

**The lower (mandibular) medial (central) and lateral incisors.** The lower incisors are the smallest teeth in both jaws. The medial incisor is smaller than its distal neighbour. Both teeth possess the features characteristic of all incisors. The *crown* has the most typical shape of a chisel. Its anterior surface is slightly convex in the longitudinal direction and flattened transversely; the posterior surface is concave longitudinally and flattened transversely. The ridges are weakly pronounced or are absent in some cases. The *root* is greatly flattened.

The signs of the curvature, angle and root are absent in the medial incisor. The better pronounced lateral longitudinal groove on the root is important in distinguishing the right medial incisor from its left fellow.

The crown of the lateral incisor is wider than that of the medial tooth and the root is more massive. The angle and root signs are clearly pronounced, while the curvature sign is poorly pronounced.

The **canines** (*dentes canini*), two on each jaw, have a long single root flattened and grooved on its sides. The *crown* has two cutting edges which meet at an angle; a tubercle is seen on its lingual surface at the neck. The crown is so flattened that the lingual and labial surfaces converge toward the cutting edge. The vestibular surface is convex transversely and longitudinally. It always has a conspicuous, particularly at the cutting edge, longitudinal ridge dividing this surface into a smaller mesial and a larger distal segment. The lingual surface carries on its sides noticeable ridges converging towards the neck at the tubercle of the tooth. The cutting edge of the crown consists of two halves, a smaller mesial and a larger distal halves, which converge towards its apex. The distal half descends towards the corresponding contacting surface more steeply than the mesial half. All the tooth signs are characteristic of the canines.

**The upper (maxillary) canine.** The *crown* is massive. Its contracting surfaces diverge considerably towards the cutting edge. A powerful middle ridge passes on the lingual surface; it arises from the dental tubercle and becomes considerably thicker and wider in the direction of the cutting edge.

The contacting surfaces are wide at the base but are relatively short. The *root* is massive and the longest of all the tooth roots. Its contacting surfaces are wide. In comparison with the lingual edge, the labial edge is blunt and wide.

The **lower (mandibular) canine** is smaller than its upper fellow. The longitudinal ridges on the labial and lingual surfaces of the *crown* are less conspicuous. The labial surface is slightly convex, the lingual surface is slightly concave. The contacting surfaces are almost parallel, the mesial does not converge towards the neck, while the distal contacting surface is slightly inclined towards it. The cutting edge of the crown is shorter than that of the upper canine but its mesial segment hardly differs from the distal in length. The *root* is shorter than the root of the upper canine, flatter, and has longitudinal grooves that are more pronounced. The root may bifurcate at the apex and a double root may form.

Teeth set in the jaw in front of the canines changed in one way: their crown became flat and a cutting edge formed; the teeth situated to the back of the canines changed in a different way; they acquired a well developed crown serving for the crushing and grinding of food. The canines, meanwhile, proved to be as if in a neutral zone and maintained the initial conical shape and the ancient function of the tooth, i.e. the cutting and tearing of food. That is why they are set on the boundary between the anterior (incisors) and the posterior (premolars and molars) teeth.

The **premolars (*dentes premolares*)**, four on each jaw, are set immediately distal to the canines. The first premolar is located mesially and the second distally. A characteristic feature is the presence on the masticating surface of the *crown* of two masticating or occlusal eminences, or cusps (*tuberculum masticatoria*, s. *tuberculum occlusalia*). That is why these teeth are also called bicuspid (*dentes bicuspidati*). One of the cusps is vestibular (buccal) and the other lingual. The premolars have a single *root*, but that of the upper first premolar usually bifurcates; it is flattened anteroposteriorly.

The **upper (maxillary) first premolar**. The buccal surface of the *crown* resembles the labial surface of the canine. Its masticating edge is formed of a mesial and distal segments converging on the apex of the buccal cusp. The mesial segment is usually longer and almost horizontal, as a rule; the distal segment descends more steeply. A ridge descends from the cusp to the buccal surface; it is bounded by longitudinal grooves. The crown curvature sign is reverse. The lingual surface of the crown is narrower and more convex than the buccal surface and its junction with the lingual cusp is more rounded. Its contacting surfaces are almost quadrangular and slightly convex. The largest convexity is in the buccal half of the surface at the occlusal edge and serves for contact with the adjacent teeth. The masticating surface is trapezoid; the buccal cusp on it is somewhat higher than the lingual cusp. The *root* is compressed mesiodistally. Each contacting surface has a deep longitudinal groove and is continuous smoothly with the lingual and at an angle with the buccal surfaces. Bifurcation of the root at the apex is encountered in more than half of cases.

The **upper (maxillary) second premolar** is smaller than the first premo-



lar, as a rule. They differ little in shape. The buccal cusp is less developed in the second than in the first premolar. The *root* is usually conical and single. Deep grooves are seen on the contacting surfaces. The root canal may be single or bifurcate.

The upper first premolar is distinguished from the second premolar by several signs: in the first premolar the buccal cusp is higher than the lingual cusp; the root is greatly compressed and usually bifurcate; in the second premolar the root is conical and may bifurcate only at the apex; the cusps on the crown are set almost at the same level. The buccal surface of the first premolar is triangular and more often than the buccal surface of the second premolar resembles the corresponding surface of the canine.

**The lower (mandibular) first premolar.** The lower premolars are distinguished from the upper premolars by a smaller size and a spherical *crown* whose transverse section has the contours of a circle. The buccal surface of the first premolar is inclined lingually; the lingual surface is narrower and shorter than the buccal; the contacting surfaces are convex and converge slightly towards the neck. The convexity is largest at the sites of contact with the adjacent teeth. The lingual cusp on the masticating surface of the crown is much smaller than the buccal cusp and this surface is consequently tilted lingually. The *root* is straight, rarely curved, and its circumference is even as a consequence of which rotation may be applied in extraction of the tooth. The root sign is demonstrated best.

**The lower (mandibular) second premolar.** The *crown* is a little larger than that of the first tooth. The crown axis meets the root axis at an angle open in the direction of the floor of the oral cavity. The masticating surface is quadrangular and inclined slightly toward the floor of the mouth. The groove separating the buccal cusp from the lingual cusp may give rise to accessory grooves, in which case the tooth is tricuspid. This shape of the crown enables the premolars to grind the food to small fragments. The *root* has a more apparent conical shape than the root of the first lower premolar. Besides, it is more massive and longer. All the signs determining the side to which the tooth belongs are clearly seen.

**The molars (*dentes molares*).** There are six molars on each jaw and they are smaller in the order from front to back; the first premolar is the largest, the third premolar is the smallest. The latter erupts late and is called the wisdom tooth (*dens serotinus* s. *dens sapientia*). The *crown* is cuboid and the masticating surface is more or less square (that of the upper molars is almost rhomboid), and has three or more cusps. This shape of the crown determines the function of the molars—they grind the food. The upper molars have *three roots*, two buccal and one lingual; the lower molars have only *two roots*, anterior and posterior. The three roots of the wisdom tooth may fuse to form a single conical root. This group of teeth is characterized by the crown curvature sign.

**The upper (maxillary) first molar.** The *crown* is massive, the masticating surface is shaped like a rhombus with the long diagonal passing obliquely from the anterobuccal point to the distal lingual point of the surface. The four cusps on this surface are separated by three grooves forming the letter H.

The mesial (buccal and lingual) cusps are larger than the distal cusps. The lingual surface of the crown is narrower and more convex than the buccal surface. The contacting surfaces are more convex at the masticating edge, at the site of contact of the teeth. The tooth has *three roots*, two buccal (a longer mesial cusp and distal cusp) and one lingual.

The **upper (maxillary) second molar** is smaller than the first one. Several variants are distinguished according to the appearance of the tooth and the character of the masticating surface of the *crown*.

The most common variant: the masticating surface bears three cusps, two buccal and one lingual; it is triangular with the apex facing the tongue.

The second variant: the masticating surface bears four cusps and the tooth resembles the first molar. In this case, the second upper molar is distinguished from the first molar by the position of the roots: the lingual root of the first molar is opposite to the space between the two buccal roots, whereas the lingual root of the second molar is opposite to or even fused with the mesial buccal root.

The third (rare) variant: the crown is tricuspid with the cusps arranged in a single row crossing the dental arch obliquely. The whole crown is narrow and flattened.

The *three roots* of the upper second molar are shorter than the roots of the first molar. They are often curved and may fuse (usually the lingual root fuses with the anterior buccal root).

The **upper (maxillary) third molar** is the smallest of all the molars and the shape of its *crown* greatly varies. It usually has three masticating cusps, two buccal and one lingual. The number of cusps may be more or less than three. The tooth has *three roots*, but in most cases they fuse to form a blunt conical stem with longitudinal grooves at their fusion. Often this tooth does not develop at all or does not erupt.

The **lower (mandibular) first molar**. The *crown* is shaped like a cube. The masticating surface is square and has five cusps: two lingual, two buccal, and one distal. The buccal cusps are more massive and lower than the lingual cusps; the distal cusp is small. The masticating surface is conspicuously inclined distally. Two grooves, transverse and longitudinal, pass on the masticating surface to form a cross at their intersection. The ends of the transverse groove stretching between the two buccal and the two lingual cusps descend onto the lingual and buccal surfaces of the crown. The longitudinal groove separates the buccal cusps from the lingual cusps. The distal cusp occupies the posterior part of the crown in the buccal half. The tooth has *two roots*, mesial (the wider one) and distal. Two tooth signs are conspicuous: the crown curvature and the root signs.

The **lower (mandibular) second molar** resembles the first molar but it is smaller. The *crown* is of a regular cubic shape. It has four cusps on the masticating surface. The *roots* are like those of the first molar. All the signs indicating the side to which the tooth belongs are clearly seen.

The **lower (mandibular) third molar** varies greatly. It is smaller than the second molar, the masticating surface of the *crown* bears four or five cusps. Their *roots* are usually two in number but may fuse for a greater or lesser

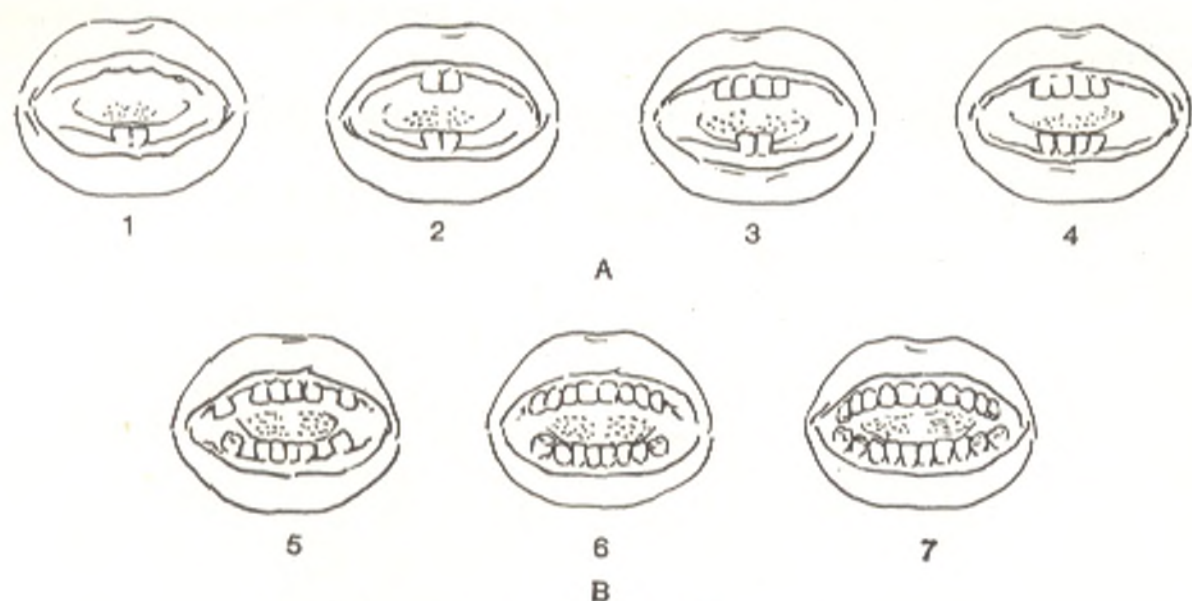


Fig. 184. Terms of eruption of deciduous teeth.

- A, 1st year.  
 1, 6-7 months;  
 2, 7-8 months;  
 3, 8-9 months;  
 4, 10-12 months.  
 B, 2nd year;  
 5, 12-15 months;  
 6, 18-20 months;  
 7, 20-24 months

length to form a single conical root. Not infrequently, the root curves considerably, usually distally.

The deciduous (milk) teeth are marked by some features: they are smaller and have less cusps and diverging roots between which are lodged the germs of the permanent teeth. The deciduous and permanent teeth have the same number of roots.

*Eruption, or cutting, of the deciduous teeth* (Fig. 184), i.e. thinning of the gum and the appearance of the tooth crown in the mouth, begins in the seventh month of extrauterine life (the lower central incisors erupt first) and ends by the beginning of the third year. There are 20 deciduous teeth.

Their *dental formula* is as follows:  $\frac{2.1.2}{2.1.2}$ . The figures indicate the number of teeth on one half of each jaw (upper and lower): two incisors, one canine tooth, and two molars. The deciduous teeth are replaced by the permanent teeth after the age of six. The process consists in the eruption of new teeth, in addition to the 20 deciduous teeth, and the replacement of each milk tooth by a permanent tooth. Eruption of the permanent teeth begins with the first molar (the 6-year-old molar) and by the age of 12-13 all the teeth have erupted, except the third molar, which erupts between the ages of 18 and 30.

The dental formula of a human adult for one side of the jaw is  $\frac{2.1.2.3}{2.1.2.3}$ , a total of 32 teeth. A more convenient formula is used in the stomatological clinic: the teeth are indicated in the order of their numbers beginning with

the first (central) incisor and ending with the last (third) molar: 1, 2 (incisors), 3 (canine tooth), 4, 5 (premolars), 6, 7, 8 (molars).

**Order and time of eruption of deciduous and permanent teeth**

*Deciduous teeth*

Central incisors	6-8 months
Lateral incisors	7-9 months
First molars	12-15 months
Canines	16-20 months
Second molars	20-24 months

*Permanent teeth*

First molar	6-7 years
Central incisors	8 years
Lateral incisors	9 years
First premolars	10 years
Canines	11-13 years
Second premolars	11-15 years
Second molars	13-16 years
Third molars	18-30 years

When the upper and lower teeth come in contact (occlusion) the upper incisors overlap the lower incisors and partially cover them. This occurs because the maxillary dental arch is a little larger than the mandibular arch and because the maxillary teeth are inclined labially, whereas the mandibular teeth are directed lingually. As a consequence, the lingual cusps of the upper molars fit into the groove between the lingual and buccal cusps of the lower molars. There is no full congruence between the upper and lower teeth: each tooth comes in contact not with one but with two teeth of the other jaw. The teeth which meet in occlusion (articulate) are called antagonists (main and accessory); the lower central incisor and the upper third molar each have only one antagonist. As the result of such articulation, with the loss of a tooth the activity of the antagonist and the adjacent teeth articulating with the lost tooth is impaired. This should be borne in mind after the extraction of a bad tooth.

Two variants of normal occlusion (bite) are distinguished according to the relations of the upper anterior teeth to the lower anterior teeth in the vestibule-oral direction. The first variant is called the *scissor-like bite* (*psalidodontia*) (Gk *psalis* scissors, *odus* tooth). It is encountered in most individuals (in 79.6 per cent according to certain data). In this type of occlusion, the cutting edges of the upper teeth overlap the cutting edges of the lower anterior teeth and cover 1.5-3.0 mm of the labial surface of the lower teeth with their lingual surface.

The second variant is called the *tong-like bite* (*labiododontia*). In this bite the cutting edges of the upper anterior teeth meet the cutting edges of the lower anterior teeth. It is encountered much less frequently than the bite of the first type; it mostly occurs in childhood (in attrition of the teeth) and in the elderly.

**Pathological bites.**

1. *Hiatodontia*, gap-like (*hiatus* gap, cleft), a gap remains between the upper and lower anterior teeth.

2. *Stegodontia*, roof-like (Gk *stegos* roof), the upper incisors protrude forward and cover the lower incisors like the slope of a roof.

3. *Opisthodontia* (Gk *opisthen* behind), the upper anterior teeth are behind the lower anterior teeth.

*Anomalous position of teeth.* The adjacent teeth may exchange their position; a tooth may be set outside the dental arch, closer to the hard palate or the vestibule of the mouth. Teeth may sometimes erupt in the cavity of the nose, on the hard palate, in the maxillary sinus.

*Anomalous number of teeth.* The upper lateral incisors or the second premolars may be absent.

*Anomalous shape of crown or root.* Elongated or shortened roots or roots curved at different angles are encountered. The molars may have more roots than usually found. The number of cusps on the masticating surface of the crown may vary.

*The vessels and nerves of teeth.* The arteries of the maxillary teeth arise from the maxillary artery; the posterior teeth of the upper jaw are vascularized from the posterior superior alveolar arteries, the anterior teeth from the anterior superior alveolar arteries (from the infraorbital artery). All the mandibular teeth receive blood from the inferior alveolar artery. Each alveolar artery gives off branches to (1) the teeth themselves: rami dentales, (2) the periosteum of the teeth: rami alveolares, and (3) the adjacent areas of the gum: rami gingivales. The blood drains along the corresponding veins into the facial veins. The lymph drains into the submandibular, submental, and deep cervical lymph nodes. The upper teeth are innervated by the superior alveolar nerves (from the second division of the trigeminal nerve). The superior anterior, medial, and posterior alveolar nerves forming the superior dental plexus are distinguished among them. The nerves of the lower teeth arise from the inferior dental plexus formed from the inferior alveolar nerve (the third division of the trigeminal nerve).

*X-ray examination of the teeth* is mostly made intraorally, i.e. the film is inserted into the mouth and pressed to the lingual surface of the teeth with the finger or the teeth are closed upon it. The teeth may also be examined on extraoral radiographs and on radiographs of the facial skull. The radiograph clearly demonstrates all the anatomical details of the tooth with an area of low density at the site of the dental cavity. A narrow band of low density corresponding to the pericementum (periodontal membrane) is noticeable on the periphery of the part of the tooth that is embedded in the dental socket.

Germs of the deciduous teeth located in the jaw are seen on the radiographs of the facial skull of the newborn. Radiographs taken later show the X-ray picture of the development, eruption and shedding of the deciduous teeth, the appearance of the germs of the permanent teeth, the development of these teeth, and the age changes in them.

## THE TONGUE

The tongue (*lingua*) (Gk *glossa* tongue, hence glossitis, inflammation of the tongue) is mainly a muscular organ (striated fibres) (Fig. 185). The changes in its shape and position are significant in the acts of mastication and speech, while due to the presence of specific nerve endings in the mucous membrane the tongue is also the organ of taste. Three parts are distinguished in the tongue: the larger part, or the body (*corpus linguae*) facing anteriorly, the tip (*apex*) and the postero-inferior part, or the root (*radix linguae*) by means of which the tongue is attached to the mandible and the hyoid bone. Its convex superior surface faces the palate and pharynx and is called the back (*dorsum*). The inferior surface of the tongue (*facies inferior linguae*) is free only in the anterior part; the posterior part is occupied by muscles. On the sides the tongue is bounded by margins (*margo linguae*). Two parts are distinguished on the dorsum of the tongue: the anterior, larger (accounting for about two thirds of the tongue), part is situated almost horizontally on the floor of the oral cavity; the posterior part is almost vertical and faces the pharynx.

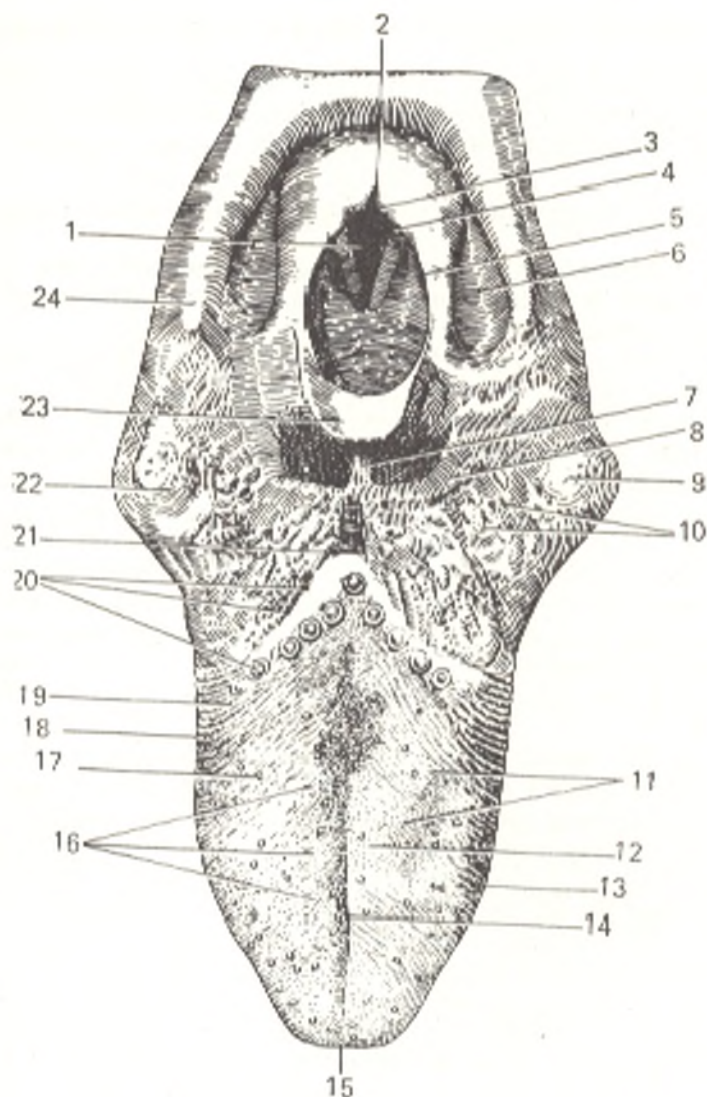


Fig. 185. The tongue and entry into the pharynx.

- 1, rima glottidis;
- 2, incisura interarythenoidea;
- 3, tuberculum corniculatum;
- 4, tuberculum cuneiforme;
- 5, plica aryepiglottica;
- 6, recessus piriformis;
- 7, plica glossoepiglottica mediana;
- 8, plica glossoepiglottica lateralis;
- 9, tonsilla palatina sinistra;
- 10, folliculi linguales;
- 11, papillae conicae;
- 12 and 16, papillae filiformes;
- 13, 18 and 19, papillae foliatae;
- 14, sulcus medianus linguae;
- 15, apex linguae;
- 17, papillae fungiformes;
- 20, papillae vallatae and sulcus terminalis posteriorly;
- 21, foramen cecum linguae;
- 22, tonsilla palatina dextra;
- 23, epiglottis;
- 24, cornu majus ossis hyoidel

At the junction of the anterior and posterior parts of the tongue on the midline is a depression (*foramen cecum linguae*), which is the remnant of the tubular projection from the floor of the primary pharynx, from which the thyroid isthmus develops. Forward and lateralward from this foramen extends on either side the *terminal sulcus of the tongue* (*sulcus terminalis linguae*). The two parts of the tongue differ in development and structure of the mucous membrane. The tongue mucosa is a derivative of the first, second and, probably, the third visceral arches (to be more precise, the branchial pockets), evidence of which is its innervation by the nerves of these arches (the fifth, seventh, ninth, and tenth pairs of cranial nerves). The first visceral (mandibular) arch gives rise to two lateral areas, which fuse on the midline to form the anterior part. The trace of the fusion of the paired germ remains throughout life on the dorsum of the tongue in the form of a *median sulcus* (*sulcus medianus linguae*) and within the tongue as a *fibrous septum of the tongue* (*septum linguae*). The posterior part arises from the second, third, and, evidently, the fourth visceral arches and fuses with the anterior part on *linea terminalis*. The mucous membrane of the anterior part of the tongue is sup-

plied with numerous papillae and bears the median sulcus mentioned above. In the posterior part, the mucous membrane is thicker and smoother because there are no papillae, but it has a bulging appearance due to the presence of lymphoid follicles. The aggregation of the lymphoid structures of the posterior part of the tongue is called the **lingual tonsil** (*tonsilla lingualis*). Three folds of the mucous membrane, **glosso-epiglottic fold** (*plica glosso-epiglottica mediana*) and two **pharyngo-epiglottic folds** (*plicae glosso-epiglotticae laterales*) stretch from the posterior part of the tongue to the epiglottis; two depressions, **valleculae epiglotticae**, are seen between the median and lateral folds.

The *tongue papillae* (*papillae lingualis*) are of the following types.

1. *Filiform and conical papillae* (*papillae filiformis* and *conicae*) are the smallest but most numerous. They occupy the superior surface of the anterior part of the tongue and lend its mucous membrane a rough or velvety appearance. The filiform and conical papillae evidently act as tactile organs.

2. *Fungiform papillae* (*papillae fungiformes*) are less in number and are found mainly at the apex and on the margins of the tongue. They are supplied with taste buds and it is therefore accepted that they are concerned with the sense of taste.

3. *Vallate (walled) papillae* (*papillae vallatae*) are surrounded by a bank. They are the largest and are arranged in the shape of the letter V immediately in front of the foramen cecum and the terminal sulcus, with the apex facing posteriorly. Their number varies between 7 and 12. Each papilla consists of a central cylindrical part (1.0-2.5 mm in diameter) and a surrounding deep narrow groove. Very many taste buds are embedded in each papilla.

4. *Foliate papillae* (*papillae foliatae*) are located on the margins of the tongue.

The taste papillae are also encountered on the free edge and nasal surface of the palate and on the posterior surface of the epiglottis. Peripheral nerve endings, the receptors of the taste analyser, are embedded in the taste papillae.

The **muscles of the tongue** constitute its muscular bulk, which is divided into two symmetric halves by a longitudinal fibrous septum (*septum linguae*). The superior edge of the septum does not reach the dorsum of the tongue. The muscles of the tongue are usually separated into two groups: (1) extrinsic, skeletal, muscles, i.e. those the *punctum fixum* of which is on the bones and which alter its position on contraction: the genioglossus, hyoglossus, and styloglossus muscles; (2) intrinsic muscles, which have no insertion on bones and are embedded within the tongue itself and change its shape: the superior and inferior longitudinal muscles and the transversus linguae and verticalis linguae muscles (Figs. 174, 186, and 187). This separation, however, is not quite correct since all the muscles of the tongue are connected with bones to some degree, with the hyoid bone in particular. On contraction they simultaneously change the position and shape of the tongue because the tongue is a single muscular structure, in which isolated contraction of separate muscles is not possible. It is more correct, therefore, to distinguish three groups of muscles according to structure and action: (1) muscles arising on the derivatives of the first visceral arch (on the mandible), these are the genioglossus

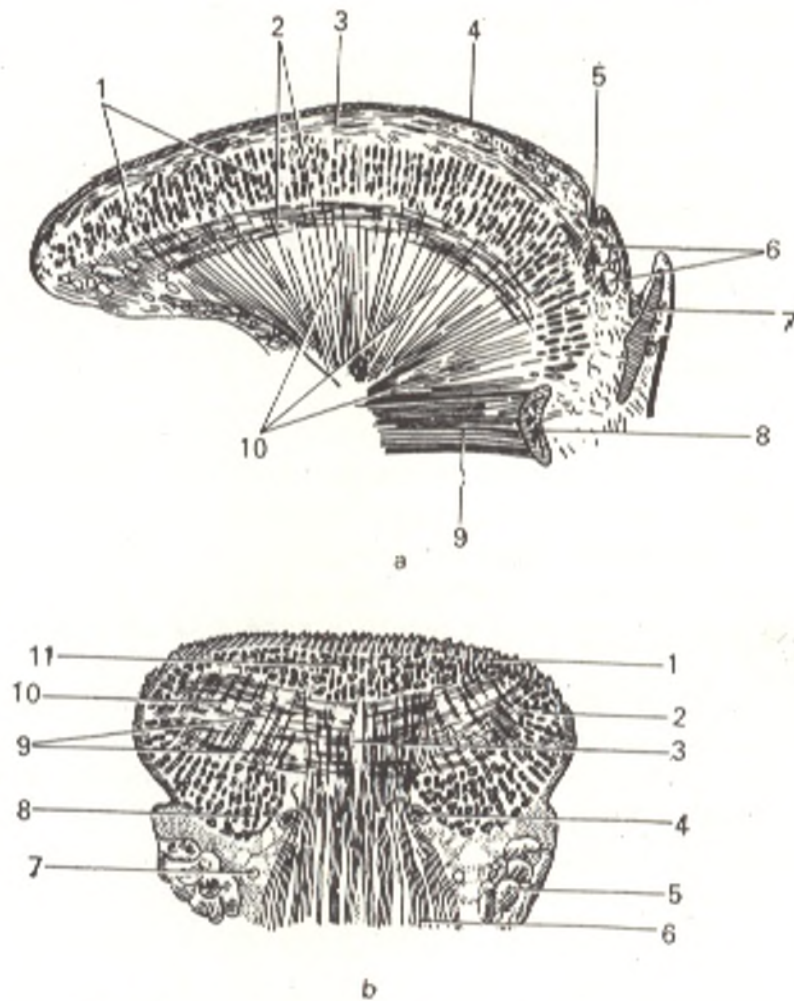


Fig. 186. Muscles of the tongue of a newborn.

a, sagittal section:

- 1, m. transversus linguae;
- 2, m. longitudinalis inferior;
- 3, m. longitudinalis superior;
- 4, tunica mucosa linguae;
- 5, foramen cecum;
- 6, glandulae linguales;
- 7, epiglottis;
- 8, corpus ossis hyoidel;
- 9, m. geniohyoideus;
- 10, m. genioglossus;

b, frontal section:

- 1, tunica mucosa linguae;
- 2, m. styloglossus;
- 3, septum linguae;
- 4, a. profunda linguae;
- 5, glandula sublingualis;
- 6, m. genioglossus;
- 7, n. lingualis;
- 8, m. longitudinalis inferior;
- 9, m. transversus linguae;
- 10, m. verticalis linguae;
- 11, m. longitudinalis superior

muscle and its continuation, the vertical muscle; (2) muscles arising on the derivatives of the second visceral arch (on the styloid process and lesser horns of the hyoid bone): these are the styloglossus and the superior and inferior longitudinal muscles; (3) muscles arising on the derivatives of the third visceral (first branchial) arch (on the body and greater horns of the hyoid bone): these are the hyoglossus and the transverse muscles. The palatoglossus muscle is also related to this group.

*First group: muscles arising on the derivatives of the first visceral arch.* The *genioglossus* muscle is the largest of all the tongue muscles and achieves highest development only in man due to the appearance of articulate speech. It



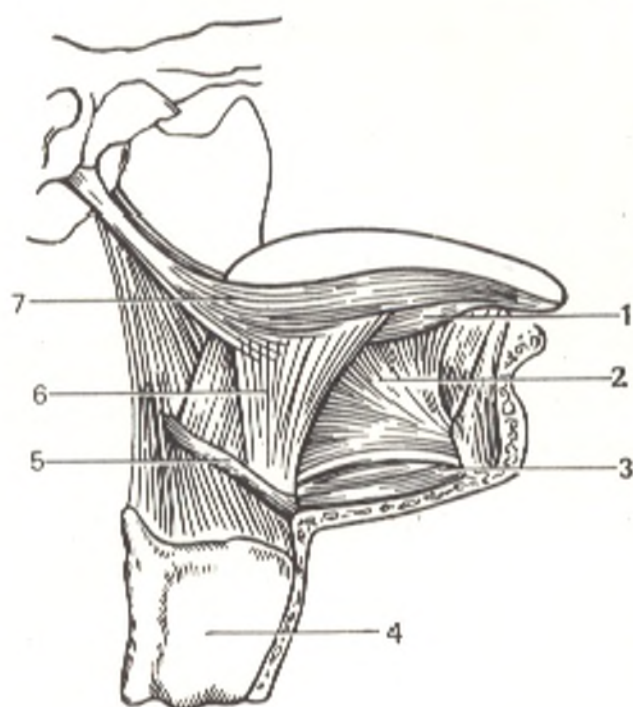


Fig. 187. Muscles of the tongue.

- 1, m. longitudinalis inferior;  
 2, m. genioglossus;  
 3, m. geniohyoideus;  
 4, cartilago thyroidea;  
 5, os hyoideum;  
 6, m. hyoglossus;  
 7, m. styloglossus

arises from the mental spine, which is also most conspicuous in man due to the effect of the muscle, and its discovery in fossil hominids is therefore accepted as a sign that this family was capable of speech. From the mental spine the muscular fibres irradiate fanwise, the lower fibres being inserted into the body of the hyoid bone, the intermediate fibres into the root of the tongue, and the upper fibres curving forwards to be inserted into the tip of the tongue. The continuation of the muscle in the thickness of the skull are vertical fibres (*m. verticalis*) stretching between the inferior surface and the dorsum of the tongue. The muscle fibres of the genioglossus muscle and its continuation—the vertical muscle—are predominantly vertical. As a result their contraction moves the tongue forward and flattens it.

*Second group: muscles arising on the derivatives of the second visceral arch.* The *styloglossus* muscle originates on the styloid process and the stylo-mandibular ligament, descends medially, and inserts into the side and inferior surface of the tongue; at the site of insertion it intersects with the fibres of the hyoglossus and palatoglossus muscles. It pulls the tongue upward and to the back.

The *superior longitudinal muscle* (*m. longitudinalis superior*) arises on the lesser horns of the hyoid bone and on the epiglottis and stretches under the mucosa of the dorsum of the tongue on either side of septum linguae to the tip.

The *inferior longitudinal muscle* (*m. longitudinalis inferior*) arises from the lesser horns of the hyoid bone and stretches on the inferior surface of the tongue between the genioglossus and hyoglossus muscles to the tip of the tongue.

The bundles of this group of muscles are mainly directed sagittally, as a result their contraction moves the tongue backward and shortens it.

*Third group: muscles arising on the derivatives of the third visceral arch.* The *hyoglossus muscle* arises from the greater horn and the nearest part of the body of the hyoid bone, stretches forward and upward and is inserted into the margins of the tongue together with the fibres of the styloglossus and transverse muscles. It pulls the tongue backward and downward. The *transverse muscle of the tongue* (*m. transversus linguae*) stretches in the horizontal plane between the superior and inferior longitudinal muscles from the septum to the margins of the tongue. Its posterior part is attached to the hyoid bone. The transverse muscle of the tongue is continuous with the palatoglossus muscle described above (see "The Soft Palate").

The slips of this group of muscles are mainly directed frontally with the result that their contraction reduces the transverse dimension of the tongue. In unilateral contraction, the tongue moves to the side of the contracting muscles, in bilateral contraction it moves downward and backward.

The origin of the tongue muscles on three bone points located posteriorly and superiorly (the styloid process), posteriorly and inferiorly (the hyoid bone), and anteriorly of the tongue (the mental spine of the mandible), and the arrangement of the muscle fibres in three mutually perpendicular planes enable the tongue to change its shape and move in all three directions.

All the tongue muscles have a common source of development: they are derivatives of the branchial myotomes. That is exactly why they are attached to the derivatives of the branchial arches, grow into the germs of the branchial pockets, which are located between these arches, and give rise to the mucous membrane of the organ. They have a single source of innervation: the twelfth pair of cranial nerves, the hypoglossus nerve.

The tongue is provided with *nutrition* from the lingual artery whose branches form in the tongue a network with loops extending in line with the course of the muscle bundles.

*Venous blood* is carried away in the lingual vein draining into the internal jugular vein. *Lymph* flows from the tip of the tongue into the submental lymph nodes, from the body into the submandibular lymph nodes, and from the root into the retropharyngeal lymph nodes and also into the superior and inferior deep cervical nodes. The jugulodigastricus and jugulo-omohyoideus lymph nodes are very important among them (see V. 2). Most of the lymphatic vessels from the middle and posterior thirds of the tongue intersect. This is of practical importance because in carcinoma of half of the tongue the lymph nodes must be removed from both sides. *Innervation* of the tongue is accomplished as follows: the muscles, from the hypoglossus nerve; the anterior two thirds of the mucous membrane from the lingual nerve (from the third division of the trigeminal nerve) and chorda tympani (the intermediate nerve), which passes together with it and supplies the fungiform papillae with taste fibres; the posterior third including the vallate papillae from the glossopharyngeal nerve, and the root area near the epiglottis is innervated from the vagus nerve (the superior laryngeal nerve).

## GLANDS OF THE ORAL CAVITY

The ducts of three pairs of large salivary glands open into the oral cavity: the parotid, submandibular, and sublingual glands (Figs. 186 and 188). Besides these, there are numerous small glands in the mucous membrane of the mouth, which, according to their location, are called as follows: the la-

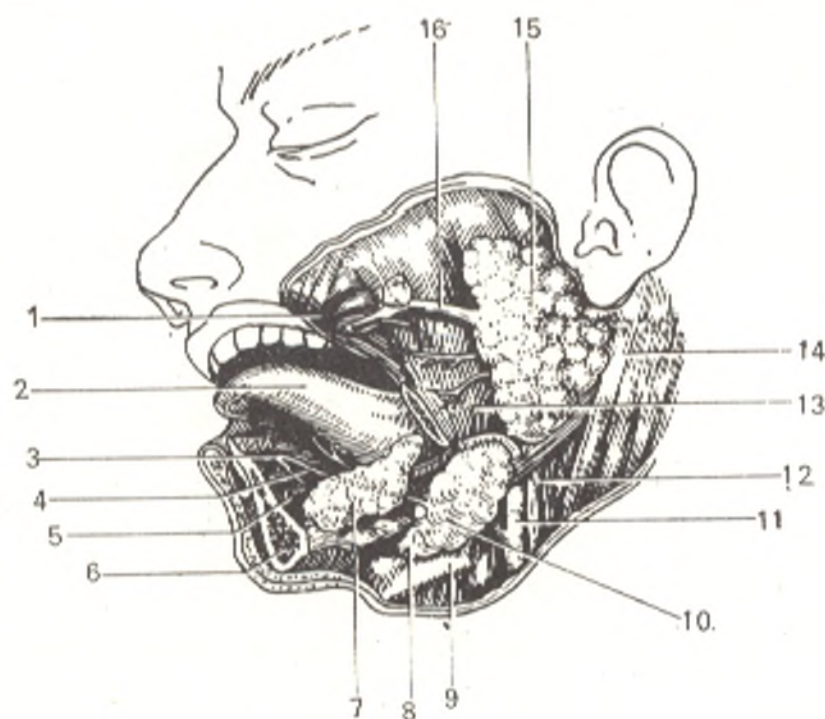


Fig. 188. Salivary glands.

1, m. buccinator;  
 2, lingua;  
 3, caruncula sublingualis;  
 4, ductus submandibularis;  
 5, ductus sublingualis;  
 6, mandibula (divided);  
 7, glandula sublingualis;  
 8 and 10, glandula submandibularis;  
 9, os hyoideum;

11, a. carotis externa;  
 12, v. jugularis interna;  
 13, m. masseter;  
 14, m. sternocleidomastoideus;  
 15, glandula parotis;  
 16, ductus parotideus (a probe is introduced into it and advanced through the opening into the oral vestibule at the level of the second upper molar)

bial, buccal, palatine, and lingual glands. According to the character of the secretion, the glands may be serous, mucous or mixed.

The three pairs of large salivary glands (*glandulae salivales*) attain considerable size and are located beyond the mucous membrane and retain connection with the oral cavity by their ducts. These glands are as follows.

1. The **parotid** (*glandula parotis*) (Fig. 188) is the largest of the salivary glands and is a serous gland. It is situated on the lateral side of the face in front of and a little below the ear and penetrates into the retromandibular fossa. On the surface, the tissue of the gland extends upward almost to the zygomatic arch and downward to the mandibular angle, in front it lies on the masseter muscle, and at the back it reaches the external acoustic meatus and the anterior border of the sternocleidomastoid muscle. The gland has a lobular structure and consists of seven lobules (Fig. 189). The parotid is invested in a fascia (*fascia parotidea*). The **duct of the gland** (*ductus parotideus*) is 5-6 cm long and arises from the anterior border of the gland, passes on the surface of the masseter muscle, curves around its anterior border, and after passing through the fatty tissue of the cheek pierces the buccinator muscle. It then enters the oral cavity under the mucous membrane and opens into the vestibule of the mouth by a small opening opposite the second upper molar. According to Kasatkin, the course of the duct varies greatly and it

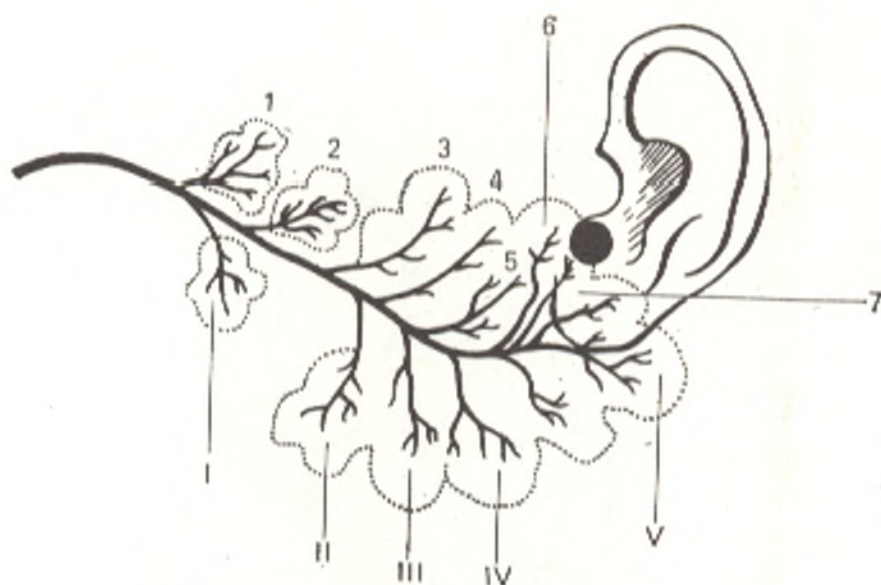


Fig. 189. Schematical representation of the structure of the parotid gland (after Kasatkin)

may be straight, arched, genual, S-shaped, descending, and bifurcate. In structure, the parotid is a compound racemous gland. Investigation of parotid secretion led Pavlov to the discovery of conditioned reflexes and became the method for their study.

2. The **submandibular gland** (*glandula submandibularis*) is of a mixed character, compound alveolar-tubular in structure, and the second largest after the parotid. Kasatkin found that it consists of ten lobules. The submandibular gland is situated in the submandibular fossa, emerges from under the border of the mandible and is covered here by the skin, the platysma muscle, and the fascia of the neck; the fascia invests the gland and forms a thin-walled capsule. The posterior part of the gland extends a little beyond the posterior border of the mylohyoid muscle. On the posterior border of this muscle a process of the gland curves over to its anterior surface; from this process extends the **submandibular duct** (*ductus submandibularis*), which passes over the mylohyoid muscle on the floor of the oral cavity and opens on *caruncula sublingualis*.

3. The **sublingual gland** (*glandula sublingualis*) is of the mucous type and alveolar-tubular in structure. It is situated over the mylohyoid muscle on the floor of the oral cavity, and, covered only by the mucous membrane, forms a **sublingual fold** (*plica sublinguales*) between the tongue and the inner surface of the mandible. In front of the frenulum of the tongue it comes in contact with the contralateral gland. The ducts of some lobules (18-20 in number) open independently into the oral cavity along the sublingual fold; they are called the **smaller sublingual ducts** (*ductus sublinguales minores*). The **principal duct of the sublingual gland** (*ductus sublingualis major*) passes next to the duct of the submandibular gland and opens by means of a single opening common to both ducts or by its own opening alongside the opening of the submandibular duct.

The parotid salivary gland receives *nutrients* from the vessels piercing it (the superficial temporal artery); the *venous blood* drains into the retromandibular vein, the *lymph* into the parotid lymph nodes; the gland is *innervated* by branches of the sympathetic trunk and the glossopharyngeal nerve. The parasympathetic fibres from the glossopharyngeal nerve reach the otic ganglion and pass further to the gland in the auriculotemporal nerve. The submandibular and sublingual salivary glands are supplied with *nutrients* from the facial artery. The *venous blood* drains into the facial vein, the *lymph*, into the submandibular and mandibular lymph nodes. The *nerves* originate from the intermediate nerve (chorda tympani) and innervate the gland by way of the submandibular ganglion.

## THE PHARYNX

The **pharynx** is that part of the alimentary canal and respiratory tract, which is a connecting link between the cavity of the nose and mouth and the oesophagus and trachea. It stretches from the level of the base of the skull to that of the sixth or seventh cervical vertebra. The space within the pharynx is the **pharyngeal cavity** (*cavitas pharyngis*). The pharynx is situated behind the nasal and oral cavities and the larynx and in front of the basilar part of the occipital bone and the upper six cervical vertebrae. In accordance with the organs situated in front of the pharynx, three parts can be distinguished in it: *pars nasalis*, *pars oralis*, and *pars laryngea*. The superior wall of the pharynx, which adjoins the base of the skull, is called the **vault of the pharynx** (*fornix pharyngis*).

The **nasal part of the pharynx**, or the **nasopharynx** (*pars nasalis pharyngis*) (Fig. 190) is a purely respiratory part functionally. As distinct from the other parts of the pharynx, its walls do not collapse because they are immobile. The anterior wall of the nasal part is occupied by the choanae. On either lateral wall is a funnel-shaped *pharyngeal opening* of the auditory tube (part of the middle ear), *ostium pharyngeum tubae*. Superiorly and posteriorly the opening of the tube is bounded by *torus tubarius* formed due to the projection of the cartilage of the auditory tube here. At the junction of the superior and posterior pharyngeal walls on the midline is an accumulation of lymphoid tissue, the *pharyngeal tonsil*, or *adenoids* (*tonsilla pharyngea* s. *adenoidea*) (in adults it is hardly noticeable, or disappears entirely). Another accumulation of lymphoid tissue, but paired, is located between the pharyngeal opening of the tube and the soft palate; this is the *tube tonsil* (*tonsilla tubaria*). Thus, almost a complete ring of lymphoid structures is found at the entry into the pharynx: the lingual tonsil, two palatine tonsils, two tube tonsils, and one *pharyngeal tonsil* (*Pirogov's lymphoepithelial ring*).

The **oral part** (*pars oralis*) is the middle part of the pharynx communicating with the oral cavity in front through the *isthmus faucium*, its posterior wall corresponds to the third cervical vertebra. The oral part is mixed in function because the alimentary and respiratory tracts intersect here. The intersection formed during the development of the respiratory organs from the wall of the primary gut. The nasal and oral cavities originated from the primary naso-oral bay, the nasal cavity being situated superiorly or as if dorsally in relation to the oral cavity, whereas the pharynx, trachea, and lungs arose from the ventral wall of the foregut. The cephalic part of the alimentary tract is, consequently, located between the nasal cavity (superior-

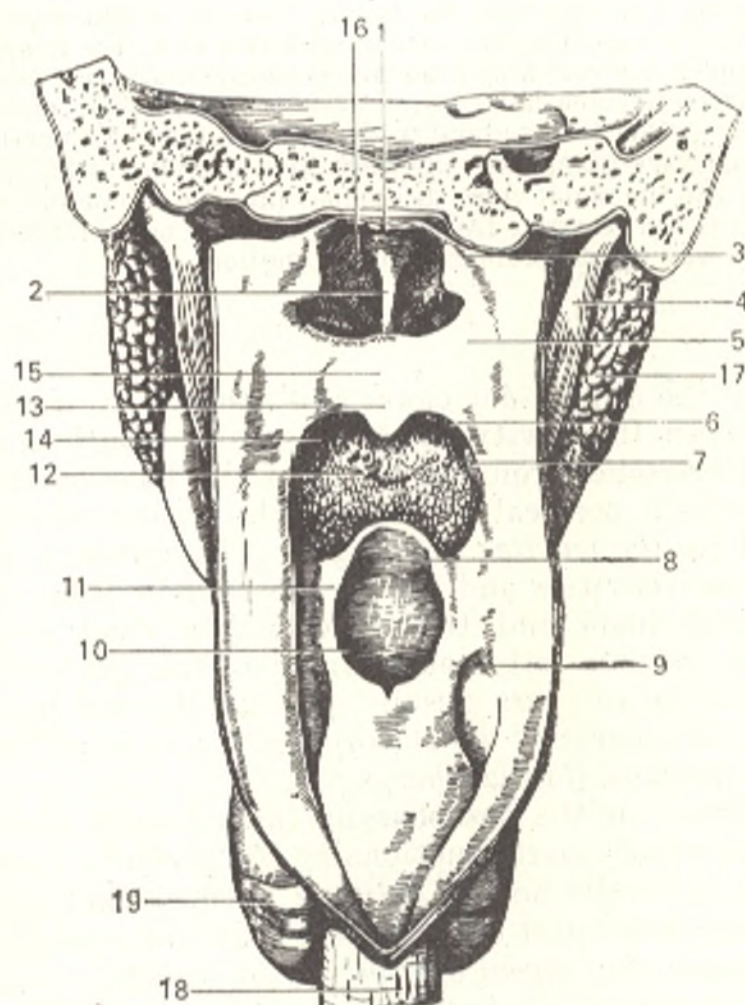


Fig. 190. Pharynx exposed posteriorly after removal of the spine and the posterior part of the skull.

- 1, fornix pharyngis;
- 2, septum nasi;
- 3, torus tubarius;
- 4, m. stylopharyngeus;
- 5, lateral pharyngeal wall;
- 6, arcus palatopharyngeus;
- 7, tonsilla palatina;
- 8, epiglottis;
- 9, recessus piriformis;
- 10, aditus laryngis;
- 11, plica aryepiglottica;
- 12, isthmus faucium through which the root of the lung is seen;
- 13, uvula;
- 14, arcus palatoglossus;
- 15, superior surface of palatum molle;
- 16, choana sinistra;
- 17, glandula parotis;
- 18, esophagus;
- 19, glandula thyroidea

ly and dorsally) and the respiratory tract (ventrally). As a result the alimentary and respiratory tracts intersect in the pharynx (see Fig. 233).

The **laryngeal part** (*pars laryngea*) begins behind the trachea and extends from the opening into the larynx to the opening into the oesophagus. In a state of rest, when there is no swallowing, the anterior and posterior walls of this part remain in contact and separate only when food passes in it, that is why the laryngeal part cannot be seen during laryngoscopy if the larynx is not pulled forward. On the anterior wall is the opening into the larynx bounded in front by the epiglottis and on the sides by the *aryepiglottic folds* (*plicae aryepiglotticae*). On either side of the folds lie paired pear-shaped fossae in the pharyngeal wall (*recessus piriformes*). The foundation of the *pharyngeal wall* is a well developed layer of fibrous tissue. This fibrous coat is lined inside with mucous membrane (mucous coat) and covered from the outside by a muscular coat. The muscular coat is in turn covered by a thinner layer of fibrous tissue connecting the pharyngeal wall with the adjoining organs; superiorly this fibrous tissue passes on to the buccinator muscle and is called the *buccopharyngeal fascia*. The fibrous coat of the pharynx, *pharyngobasilar fascia* (*fascia pharyngobasilaris*) is attached above to the basal part of the occipital bone and to the other bones of the base of the skull and stretches

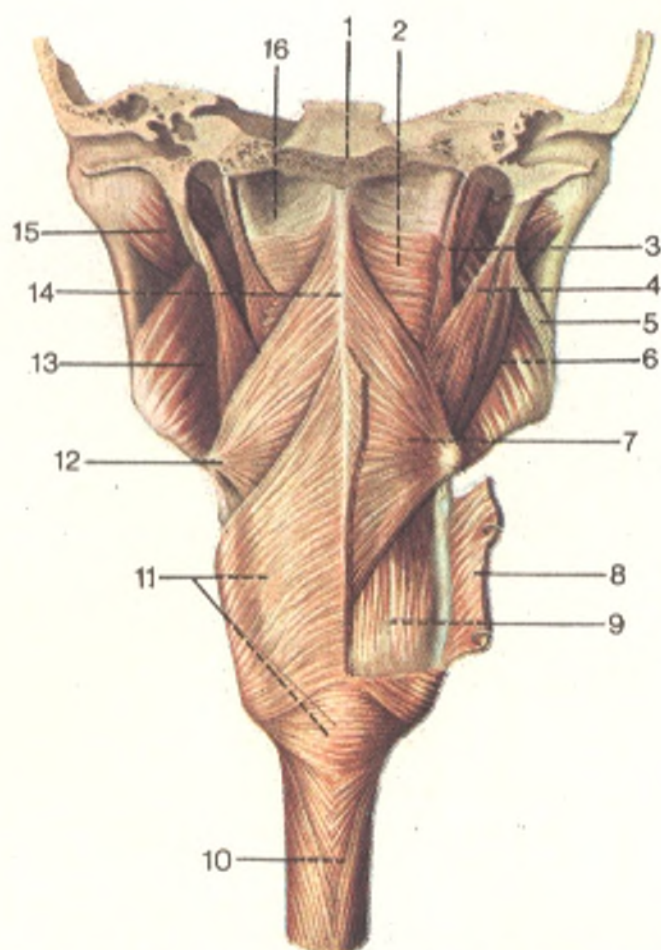


Fig. 191. Muscles of the pharynx, posterior aspect (after Sinelnikov).

- |  |  |
|--|--|
| 1, clivus;                                       | 9, m. palatopharyngeus;                |
| 2, m. constrictor pharyngis superior;            | 10, esophagus;                         |
| 3, m. petropharyngeus;                           | 11, m. constrictor pharyngis inferior; |
| 4, m. stylopharyngeus;                           | 12, cornu majus ossis hyoidei;         |
| 5, lig. stylomandibulare;                        | 13, m. pterygoideus medialis;          |
| 6, m. stylohyoideus;                             | 14, raphe pharyngis;                   |
| 7, m. constrictor pharyngis medius;              | 15, m. pterygoideus lateralis;         |
| 8, m. constrictor pharyngis inferior (cut. off); | 16, fascia pharyngobasilaris           |

forward to the medial pterygoid plate. The fibrous coat is especially well developed in the upper part where it is only partly covered by the superior constrictor. The *mucous coat* of the nasal part of the pharynx is covered with ciliated epithelium in accordance with the respiratory function of this part of the pharynx, whereas in the inferior parts it is covered with stratified squamous epithelium. The mucous coat of the inferior parts of the pharynx fuses with the underlying tissue and acquires a smooth surface, which promotes gliding of the bolus during swallowing. This is also aided by the secretion of mucous glands embedded in the mucosa and by the *pharyngeal muscles* arranged longitudinally (dilators) and circular (constrictors). The circular layer is much stronger and consists of three constrictors (Figs. 191 and 192) arranged in three storeys: the *superior constrictor muscle of the pharynx* (*m. constrictor pharyngis superior*), the *middle constrictor muscle of the pharynx*

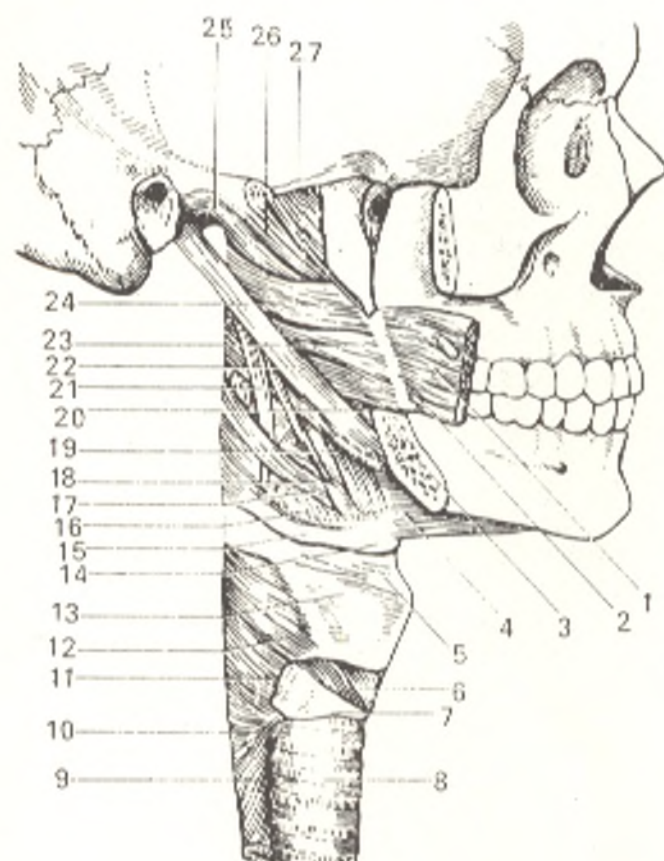


Fig. 192. Muscles of the pharynx, lateral aspect.

- 1, m. buccinator;
- 2, raphe pterygomandibularis;
- 3, mandibula;
- 4, m. mylohyoideus;
- 5, lig. thyrohyoideum;
- 6, m. cricothyroideus;
- 7, cartilago cricoidea;
- 8 and 10, trachea;
- 9, esophagus;
- 11 and 12, m. constrictor pharyngis inferior;
- 13, cartilago thyroidea;
- 14, os hyoideum;
- 15, cornu majus ossis hyoidei;
- 16 and 17, m. constrictor pharyngis medius;
- 18, lig. stylohyoideum;
- 19, 20, 23, and 24, m. constrictor pharyngis superior;
- 21, m. stylopharyngeus;
- 22, m. styloglossus;
- 25, fibrous coat of pharynx;
- 26, m. levator veli palatini;
- 27, m. tensor veli palatini

(*m. constrictor pharyngis medius*), and the *inferior constrictor muscle of the pharynx* (*m. constrictor pharyngis inferior*). Arising on different points, namely on the bones of the base of the skull (pharyngeal tubercle of the occipital bone and the pterygoid process of the sphenoid bone), on the mandible (the mylohyoid line), on the root of the tongue, on the hyoid bone, and on the pharyngeal cartilages (thyroid and cricoid) the fibres of the muscles on each side pass backward and join each other to form a seam on the midline of the pharynx, the *raphe of the pharynx* (*raphe pharyngis*). The lower fibres of the inferior pharyngeal constrictor are closely connected with the muscle fibres of the oesophagus. The longitudinal muscle fibres of the pharynx run in the following two muscles.

1. The *stylopharyngeus muscle* (*m. stylopharyngeus*) arises from the styloid process and descends to be inserted partly in the pharyngeal wall itself and partly on the superior edge of the thyroid cartilage.

2. The *palatopharyngeus muscle* (*m. palatopharyngeus*) is described above (see "Soft Palate").

**The act of swallowing, deglutition.** Since the respiratory and digestive tracts intersect in the pharynx, special devices exist, which separate these two tracts during swallowing. By contraction of the tongue muscles the bolus is pressed against the hard palate by the dorsum of the tongue and then pushed through the fauces. During this process, the soft palate is pulled upward (by contraction of the levator veli palatini and the tensor veli palatini muscles) and brought nearer to the posterior pharyngeal wall (by contraction of the



palatopharyngeus muscle). In this manner, the nasal (respiratory) part of the pharynx is completely separated from the oral part. At the same time, the suprahyoid muscles pull the pharynx upward, while the root of the tongue is pulled downward by contraction of the hyoglossus muscle; the root of the tongue presses against the epiglottis and depresses it and closes the opening into the larynx (into the respiratory tract) in this way. Then the pharyngeal constrictors contract in succession as a result of which the bolus is pushed toward the oesophagus. The longitudinal pharyngeal muscles act as elevators, they pull the pharynx to meet the bolus.

The pharynx receives *nutrients* mainly from the ascending pharyngeal artery and the branches of the facial and maxillary arteries from the external carotid artery. *Venous blood* drains into a plexus situated on the muscular coat of the pharynx and then into the system of the internal jugular vein by way of the pharyngeal veins. The *lymph flows* into the deep cervical and retropharyngeal lymph nodes. The pharynx is *innervated* from the pharyngeal plexus formed by branches of the glossopharyngeus and vagus nerves and branches of the sympathetic trunk. The sensory innervation is conducted along the glossopharyngeus and vagus nerves; the muscles of the pharynx are innervated by the vagus, except for the stylopharyngeus muscle, which is innervated by the glossopharyngeus nerve.

## THE OESOPHAGUS

The **oesophagus** (Fig. 193) is a narrow and long actively functioning tube inserted between the pharynx and the stomach. It aids the passage of food toward the stomach. The oesophagus begins at the level of the sixth cervical vertebra, which corresponds to the level of the inferior border of the cricoid cartilage of the pharynx, and ends at the level of the eleventh thoracic vertebra. Arising in the region of the neck, the oesophagus passes further into the thoracic cavity and, penetrating the diaphragm, enters the abdominal cavity; three parts are consequently distinguished in it: cervical (*pars cervicalis*), thoracic (*pars thoracica*), and abdominal (*pars abdominalis*). The oesophagus is 23 to 25 cm in length. The total length of the tract from the anterior teeth, through the oral cavity, the pharynx, and the oesophagus, ranges from 40 to 42 cm (in collecting the gastric secretions for tests the rubber gastric tube must be advanced into the oesophagus for this distance plus another 3.5 cm).

**Topography of the oesophagus**<sup>1</sup>. The *cervical part* of the oesophagus is projected between the sixth cervical and second thoracic vertebrae. In front of it is the trachea, behind it is the prevertebral fascia, and on both sides pass the recurrent laryngeal nerves and the common carotid arteries and, in addition, on the left side is also the left lobe of the thyroid gland.

The *syntopy* of the *thoracic part* of the oesophagus differs according to the levels: the upper third of the thoracic part is to the left of the trachea; the left recurrent laryngeal nerve and the left common carotid artery lie on the front surface of this part, the spinal column is behind it, and the media-

<sup>1</sup> Information on the topography of organs in this edition is supplemented by data from *Topographic Anatomy* written by V. N. Shevkunenko and manuals written by A. N. Maximenkov, G. E. Ostroverkhov, D. M. Lubotsky, and Yu. M. Bomash (in Russian).

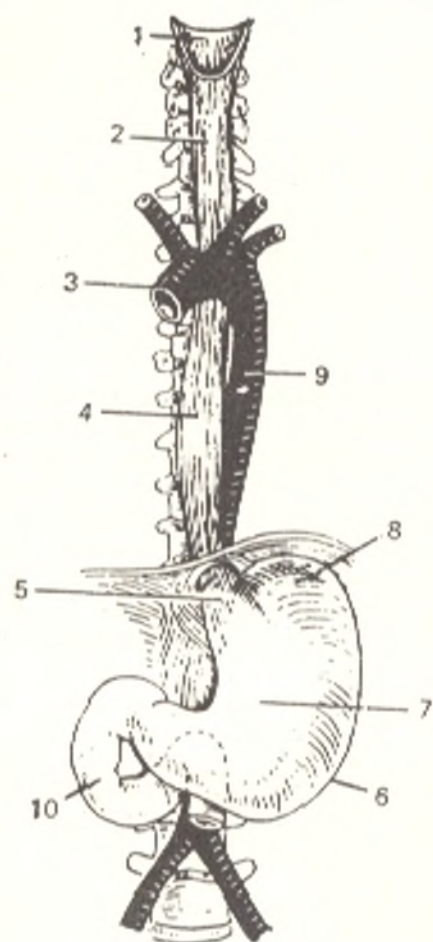


Fig. 193. Oesophagus and stomach.

- 1, lower part of pharynx;
- 2 and 4, oesophagus;
- 3, arcus aortae;
- 5, opening into the stomach;
- 6, *curvatura ventriculi major*;
- 7, *ventriculus* (paries anterior);
- 8, *fornix ventriculi*;
- 9, aorta;
- 10, duodenum

stinal pleura to the right. On the left side of the oesophagus are the thoracic duct and the left subclavian artery, which ascend obliquely from back to front.

In the middle third, the aortic arch is in front and to the left of the oesophagus on the level of the fourth thoracic vertebra; a little lower (fifth thoracic vertebra) are the bifurcation of the trachea and the left bronchus, and still lower is a group of tracheobronchial plexuses, with which the oesophagus is often closely fused; to the back of the oesophagus are the thoracic duct and the prevertebral fatty tissue; to the left and a little to the back is the descending aorta, to the right the right vagus nerve, and to the right and to the back the azygos vein.

In the lower third of the thoracic oesophagus the aorta is to the back and to the right, the pericardium and left vagus nerve with the plexus in front, the right vagus nerve is to the right but is displaced to the posterior surface of the oesophagus in the lower part; slightly to the back is the azygos vein; the right pleura covers this part of the oesophagus for the entire length; the left vagus nerve and the left pleura are to the left.

The *abdominal part* of the oesophagus is covered by the peritoneum in front and on the sides; in front and to the right is the left lobe of the liver; to the left the upper pole of the spleen; a group of lymph nodes is found at the junction of the oesophagus with the stomach.

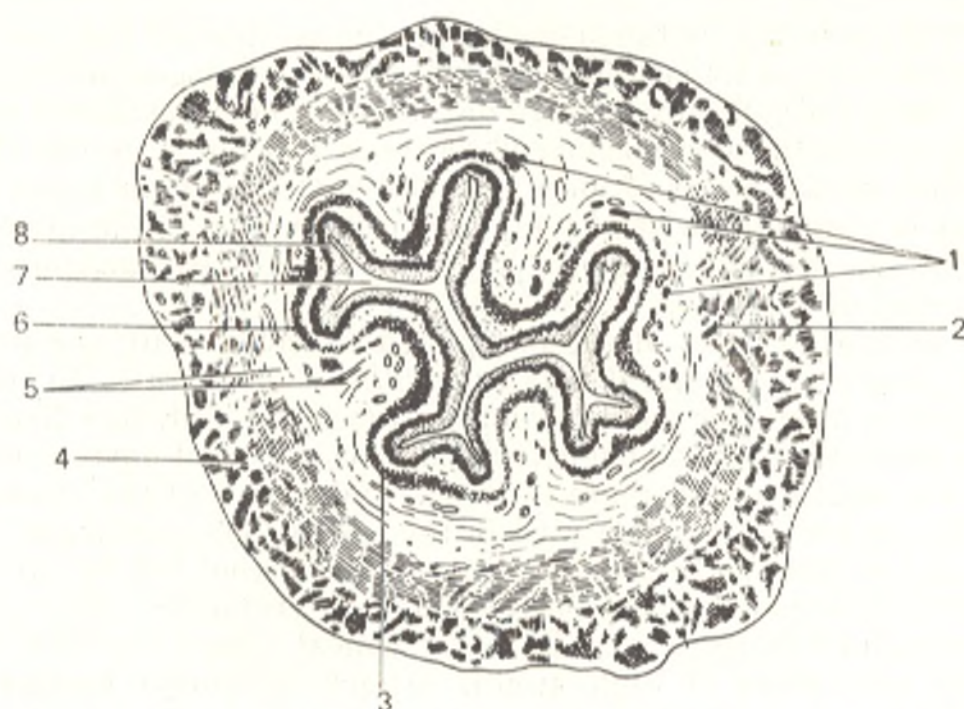


Fig. 194. Transverse section of the oesophagus (through the middle part).

- |  |                       |
|--|-----------------------|
| 1, glandulae mucosae esophageae;             | 5, tela submucosa;    |
| 2, stratum circulare tunicae muscularis;     | 7, oesophageal lumen; |
| 3 and 6, lamina muscularis mucosae;          | 8, tunica mucosa      |
| 4, stratum longitudinale tunicae muscularis; |                       |

**Structure.** On a transverse section, the oesophageal lumen is seen as a transverse gap in the cervical part (due to pressure exerted by the trachea) but it is rather round or stellate in the thoracic part (Fig. 194). The oesophageal wall consists of the following coats: the innermost, the *mucous coat (tunica mucosa)*, the middle, *muscular coat (tunica muscularis)* and the outer coat of a connective-tissue character, the *adventitious coat (tunica adventitia)*. The mucous coat contains mucous glands whose secretions facilitate gliding of the bolus during swallowing. When the oesophagus is not dilated, the mucosa gathers to form longitudinal folds, which can straighten out when food passes through the oesophagus. The longitudinal plication is a functional adaptation of the oesophagus, which facilitates movement of fluids along the oesophagus in the grooves between the folds and stretching of the oesophagus when a hard bolus passes in it. This is also aided by the loose *submucous coat (tela submucosa)* due to which the mucous coat possesses greater mobility and its folds now form, now are smoothed out easily. The layer of smooth muscle fibres of the mucous coat itself (*lamina muscularis mucosae*) also contributes to the formation of these folds.

The *muscular coat (tunica muscularis)* corresponds to the tubular shape of the oesophagus which, to accomplish the function of propelling the bolus, must dilate and contract. The muscular coat is arranged in two layers; the outer, longitudinal layer (dilating the oesophagus) and an inner, circular layer (constricting the oesophagus). In the upper third of the oesophagus, both layers consist of striated muscles but distally they are gradually replaced

by smooth fibres so that in the lower half of the oesophagus they are composed almost exclusively of smooth fibres. Of the two oesophageal muscular layers, the outer, longitudinal one, is more developed. The *adventitious coat* (*tunica adventitia*) invests the oesophagus and serves as a sort of fascia for the muscular coat. This coat consists of loose connective tissue by means of which the oesophagus is connected with the adjacent organs. Due to the loose character of this coat the oesophagus can change the size of its transverse diameter during passage of the bolus.

The abdominal part of the oesophagus is covered by the peritoneum.

The *glands of the oesophagus* (*glandulae esophageae*). In addition to mucous glands, there are small glands in the lower and, less frequently, in the upper parts of the oesophagus, which do not extend beyond the mucous coat and are similar in structure to the cardiac glands of the stomach. Lymphatic follicles are also encountered in the submucous membrane.

*X-ray examination of the digestive tube* is carried out by creating artificial contrasts because otherwise it cannot be visualized. The subject who is to be examined is given a "radiocontrast meal" (gruel, etc.) or suspension containing substances of high atomic weight; insoluble barium sulphate serves best for the purpose.

This radiocontrast meal retains the X-rays and produces on the film or the screen a shadow corresponding to the cavity of the organ filled with it. Watching by means of radioscopy or radiography the movement of such radiocontrast meal one can study the X-ray picture of the entire digestive canal. In complete, or as it is commonly accepted, "tight" filling of the stomach and intestine with the radiocontrast medium, the X-ray picture of the organs demonstrates their contours or "cast", when the organs are filled only slightly the medium is distributed between the folds of the mucosa and demonstrates its relief.

**The oesophagus of a live person.** On X-ray examination (Fig. 195) the oesophagus containing the radiocontrast medium is demonstrated as an intensive longitudinal shadow clearly seen against the light background of the pulmonary field between the heart and the spine. This shadow is the "silhouette" of the oesophagus, as it were. If the main mass of the radiocontrast meal passes into the stomach and swallowed air remains in the oesophagus, the contours of its walls will be seen as well as a low-density shadow at the site of its cavity and the relief of the mucosal longitudinal folds. From the X-ray findings it is evident that the oesophagus of a live subject differs from that of a cadaver in several features due to the presence of intravital muscular tonus in the live man. This concerns first of all the *position of the oesophagus*. In a cadaver the oesophagus forms curves: in the cervical part it passes at first on the midline, then curves slightly to the left, and returns to the midline at the level of the fifth thoracic vertebra; further distally it again curves to the left and forward to the oesophageal hiatus in the diaphragm. The oesophagus in a live subject passes straight in the cervical and thoracic parts and only its distal part deviates to the left toward the oesophageal hiatus. After passing through the diaphragm the abdominal part of the oesophagus deviates to the left to the stomach.

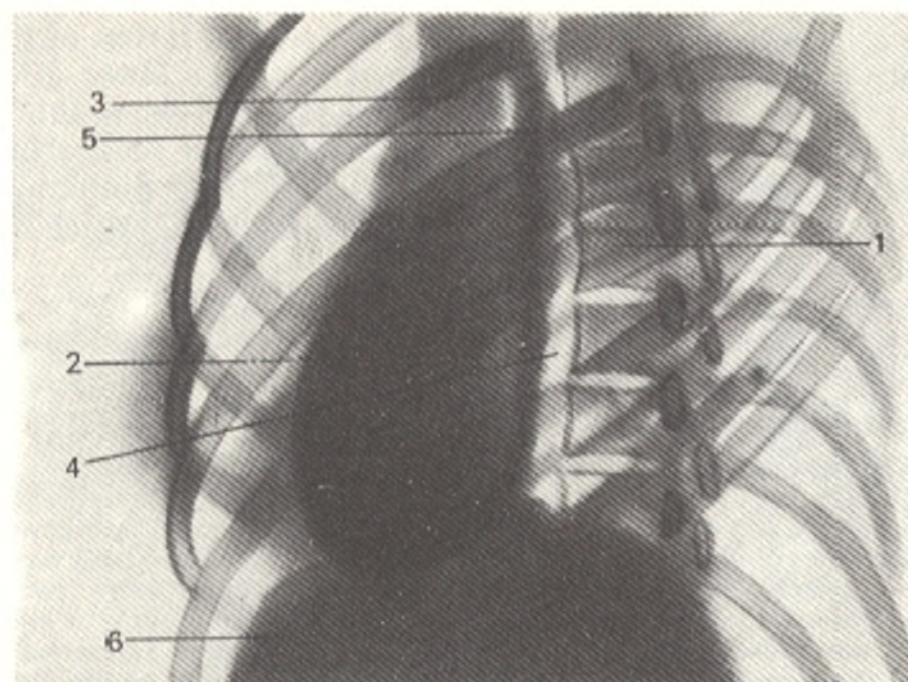


Fig. 195. Lateral view radiograph of the oesophagus.

- |                             |                                       |
|-----------------------------|---------------------------------------|
| 1, spine;                   | 5, aortic constriction of oesophagus; |
| 2, heart shadow;            | 6, diaphragm.                         |
| 3, shadow of large vessels; |                                       |
| 4, oesophagus;              |                                       |

The oesophagus has a number of constrictions and dilatations, which are significant in making the diagnosis of pathological processes. Three anatomical *constrictions* are clearly seen in a cadaver. They persist also in an isolated oesophagus: (1) pharyngeal (at the origin of the oesophagus), (2) bronchial (at the level of the tracheal bifurcation), and (3) a diaphragmatic constriction (where the oesophagus pierces the diaphragm). There are more constrictions in a live subject, those encountered most constantly are as follows: a superior constriction at the origin of the oesophagus, a second constriction 21-22 cm from the edges of the incisors, where the oesophagus is crossed by the arch of the aorta and the left bronchus (aortico-bifurcational constriction); a third constriction occupies the whole abdominal part of the oesophagus. The superior and inferior constrictions, i.e. the inlets into the oesophagus and the stomach, are sites of special physiological activity and as distinct from the other oesophageal constrictions they can be called physiological in the full sense of the word.

Between the constrictions are two *dilatations*, upper and lower. The upper dilatation is between the superior (at the entry into the oesophagus) and middle (aortico-bifurcational) constrictions. During oesophagoscopy movement of the oesophageal wall caused by respiratory excursions of the chest can be seen in this part.

The lower dilatation corresponds to the part of the oesophagus situated relatively freely in the mediastinal fatty tissue. Its walls are easily mobile. Under the effect of negative pressure in the thoracic cavity, pulsed move-

ments are clearly seen here as the result of the close relation of the oesophagus to the aorta, around which it curves spirally. The lower dilatation can be regarded as a kind of *vestibule of the stomach*, and from this standpoint it differs greatly from the upper dilatation. Ingested food stimulates the mucosa of the inferior constriction, reflex spasm of the diaphragmatic part occurs and the food accumulates in the lower dilatation, which can increase markedly in volume.

In *oesophagoscopy* (i.e. examination of the oesophagus of a live subject through a special instrument, the oesophagoscope), the mucous membrane is seen to be smooth, velvety, and moist. The longitudinal folds are soft and plastic. Longitudinal vessels run along them.

*Nutrition* of the oesophagus is accomplished from several sources; the arteries, which supply the nutrients, form copious anastomoses. The oesophageal arteries to the cervical part of the oesophagus originate from the inferior thyroid artery. The thoracic part receives several branches directly from the thoracic aorta. The abdominal part is supplied from the inferior phrenic and left gastric arteries. *Venous blood* flows from the cervical part into the brachiocephalic vein, from the thoracic part into the azygos and hemiazygos veins, and from the abdominal part into the veins draining into the portal vein.

The *lymphatic vessels* from the cervical part and upper third of the thoracic part of the oesophagus pass to the deep cervical nodes and to the tracheal, tracheobronchial, and posterior mediastinal nodes. Ascending vessels from the middle third of the thoracic part reach the above-named nodes of the chest and neck, while descending vessels (through the oesophageal hiatus) reach the abdominal nodes (gastric, pyloric, and pancreaticosplenic). Into these nodes also drain vessels from the other parts of the oesophagus (supradiaphragmatic and abdominal). The oesophagus is *innervated* from the vagus nerve and the sympathetic trunk. Pain sense is conducted along the branches of the sympathetic trunk; sympathetic innervation reduces peristalsis of the oesophagus. Parasympathetic innervation intensifies peristalsis and secretion by the glands.

## THE ABDOMINAL CAVITY

Beginning with the stomach, the parts of the digestive tract with its large glands (liver and pancreas) as well as the spleen and the urogenital system are located in the abdominal cavity.

The **abdominal cavity** (*cavitas abdominis*) is the space in the trunk below the diaphragm; it is completely filled with the abdominal organs. The diaphragm, serving as the superior wall of the abdominal cavity, separates it from the thoracic cavity. The anterior wall of the abdominal cavity is formed by the tendinous expansions of the three broad abdominal muscles and the straight abdominal muscles. The components of the lateral walls are the muscular portions of the three broad muscles of the abdomen. The posterior wall is formed by the lumbar segment of the spine and the psoas major and quadratus lumborum muscles. Below are the iliac bones and the pelvic diaphragm.

The abdominal cavity is subdivided into the abdominal cavity proper and the **pelvic cavity** (*cavitas pelvis*). The pelvic cavity is bounded posteriorly by the anterior surface of the sacrum covered on the sides by the piriform muscles, anteriorly and laterally by parts of the hip bones with the overlying internal obturator muscles, which are lined with fasciae. The floor of the pelvic cavity is formed by the pelvic diaphragm composed of two

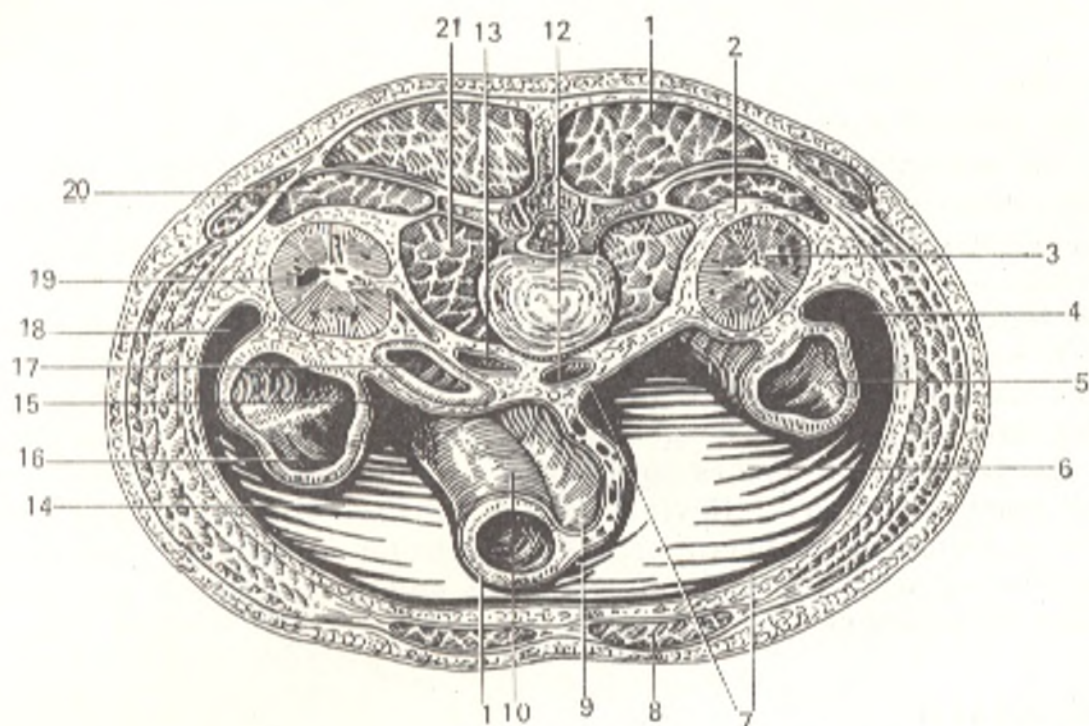


Fig. 196. Relation of organs to the peritoneum (horizontal section of the trunk through the level between the bodies of the second and third lumbar vertebrae, after Sinelnikov).

- |   |  |
|---|--|
| 1 (top), muscles of the back;                     | 11 (bottom), peritoneum viscerale;             |
| 2, spatium retroperitoneale;                      | 12, aorta abdominalis;                         |
| 3, ren sinister (extraperitoneal position);       | 13, v. cava inferior;                          |
| 4, canalis lateralis sinister;                    | 14, sinus mesentericus dexter;                 |
| 5, colon descendens (mesoperitoneal position);    | 15, colon ascendens (mesoperitoneal position); |
| 6, sinus mesentericus sinister;                   | 17, duodenum (extraperitoneal position);       |
| 7 and 15, peritoneum parietale;                   | 18, canalis lateralis dexter;                  |
| 8, m. rectus abdominis;                           | 19, ren dexter;                                |
| 9, mesenterium;                                   | 20, m. quadratus lumborum;                     |
| 10, intestinum tenue (intra-peritoneal position); | 21, m. psoas major                             |

pairs of muscles, the levatores ani and the coccygeal muscles (see below "*Muscles of the Perineum*"). Internally of the muscular layers (between them and the peritoneum), the abdominal cavity is lined with the subperitoneal fascia (fascia subperitonealis), which is divided into the following parts according to the regions: the transverse fascia (fascia transversalis) lines the inner surface of the transverse abdominal muscle and is then continuous with the pelvic fascia (fascia pelvis) on the walls of the pelvis; on the pelvic diaphragm the transverse fascia is continuous with the superior fascia of the pelvic diaphragm; on the inferior surface of the pelvic diaphragm is the inferior fascia of the pelvic diaphragm; the fascia iliaca covers the psoas and iliac muscles. In determining the position of the abdominal organs the abdomen is usually divided into regions. The abdominal cavity is lined with a serous membrane called the **peritoneum**, which also covers to a lesser or greater extent the abdominal viscera (see below "*The Peritoneum*"). The abdominal organs, developing between the peritoneum and the wall of

the abdominal cavity (mainly the posterior wall), with growth move away from the wall and grow into the peritoneum stretching it out after them. As a result a serous fold of two layers forms. Such peritoneal folds passing from the wall of the abdominal cavity to parts of the intestinal canal are called the *mesenterium*, while those passing from the wall to the organs (e.g. the liver) are called *ligament (ligamentum)*. An organ invested in the peritoneum is said to have an *intraperitoneal position* (e.g. the small intestine) (Fig. 196); a *mesoperitoneal position* is that when an organ is covered by the peritoneum on three sides (one side is devoid of a covering, e.g. the liver). If an organ is covered by the peritoneum only in front, its position is called *extraperitoneal* (e.g. the kidneys). Being smooth due its epithelial covering and moist because of the presence of a capillary layer of serous fluid, the peritoneum makes movement of the organs in relation to one another much easier by relieving friction between the contacting surfaces. Detailed information concerning the peritoneum is supplied below in the section dealing with the abdominal organs and in a separate account of it (see "The Peritoneum").

## THE STOMACH

The **stomach** (*ventriculus [gaster]*) is a sac-like expansion of the digestive tract (Figs. 193, 197, and 198). After passing through the oesophagus food accumulates in the stomach and undergoes here the first stages of digestion during which the hard components are converted to a liquid or pasty mixture. An **anterior wall** (*paries anterior*) and **posterior wall** (*paries posterior*) of the stomach are distinguished. The concave border of the stomach facing upward and to the right is called the **lesser curvature of the stomach** (*curvatura ventriculi minor*); the convex border facing downward and to the left is the **greater curvature** (*curvatura ventriculi major*). A gastric notch (*incisura angularis*) is seen on the lesser curvature, nearer to the caudal than to the cranial end of the stomach, where the two parts of the curvature meet at a sharp angle to form the *angulus ventriculi*.

The following **portions** are distinguished in the stomach: the opening of the oesophagus into the stomach, the **cardiac orifice** (*ostium cardiacum*) (Gk *kardia* heart; the opening of the oesophagus into the stomach is closer to the heart than the opening of the stomach into the duodenum); the adjoining, **cardiac portion**, of the stomach (*pars cardiaca*); the distal aperture of the stomach, **pylorus** and the adjacent **pyloric portion** of the stomach (*pars pylorica*); the dome-shaped part of the stomach to the left of ostium cardiacum is called the **fundus**, or to be more exact, the **fornix**. The **body of the stomach** (*corpus ventriculi*) stretches from the fundus to the physiological sphincter (*sphincter antri*) seen in a live person, and to the *pars pylorica* in a cadaver. *Pars pylorica* is in turn divided into the *pyloric antrum* (*antrum pyloricum*) and the *pyloric canal* (*canalis pyloricus*), a narrower tube-like part immediately adjoining the pylorus.

**Topography of the stomach.** The stomach is situated in the epigastrium; its greater portion (about five sixths) is to the left of the median plane;



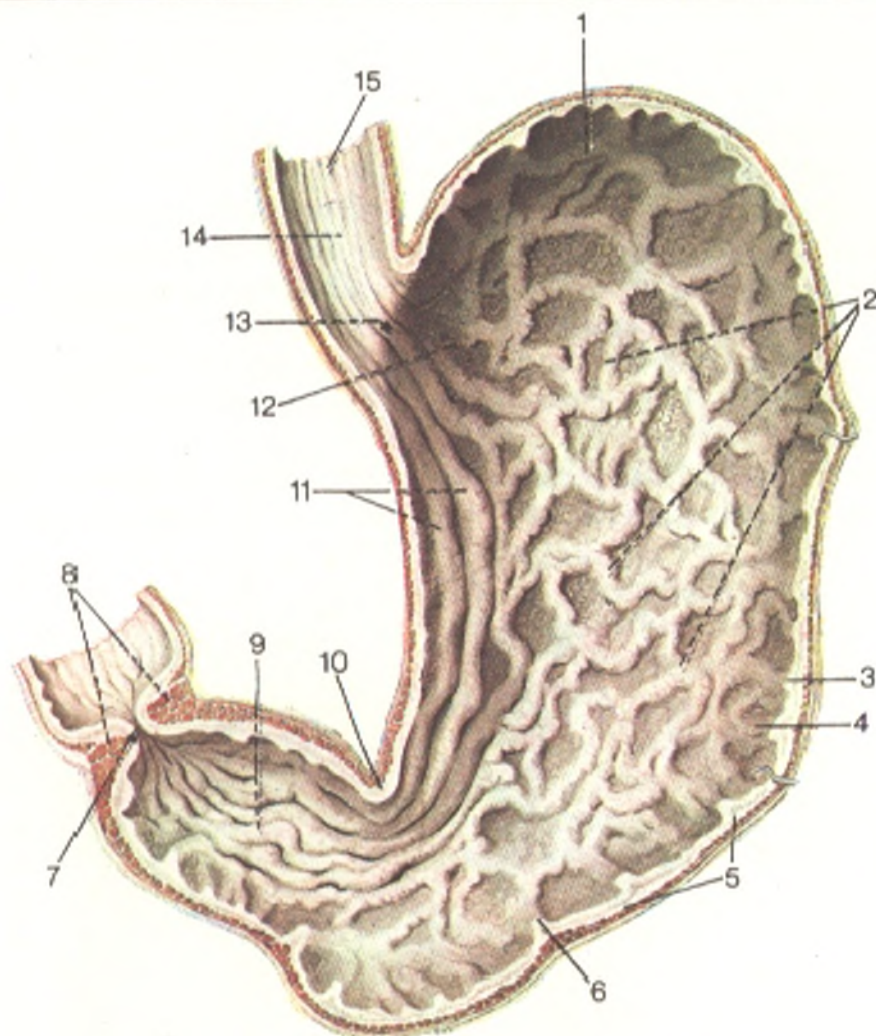


Fig. 197. Stomach (opened; after Sinelnikov).

1, fundus ventriculi (fornix);  
 2 and 11, plicae mucosae ventriculi;  
 3, curvatura major;  
 4, tunica mucosa ventriculi;  
 5, tela submucosa ventriculi;  
 6, tunica muscularis ventriculi;  
 7, valvula pylorica;

8, m. sphincter pylori;  
 9, pars pylorica (canalis egestorius);  
 10, incisura angularis;  
 12, pars cardiaca (antrum ventriculi);  
 13, ostium cardiacum;  
 14, plicae mucosae esophagi;  
 15, tunica muscularis esophagi

when the stomach is full the greater curvature is projected onto the umbilical region. The long axis of the stomach runs downward, from left to right, and from back to front; the cardiac orifice is to the left of the spine, behind the cartilage of the left seventh rib, 2.5-3.0 cm from the sternal border; its projection in the back corresponds to the level of the eleventh thoracic vertebra; it is at a considerable distance from the anterior abdominal wall. The fundus of the stomach reaches the inferior border of the fifth rib on the left mamillary line. The pylorus of an empty stomach is on the midline or a little to the right of it, opposite to the right eighth costal cartilage, which corresponds to the level of the twelfth thoracic or first lumbar vertebra. A full stomach comes in contact with the inferior surface of the left lobe of the liver and with the left dome of the diaphragm superiorly, with the upper pole of the left kidney and the adrenal gland, with the spleen, and

the anterior surface of the pancreas posteriorly, with the mesocolon and the transverse colon further downward, and with the abdominal wall between the liver on the right and the ribs on the left anteriorly. Due to the contraction of its walls, an empty stomach recedes within depth and the space thus vacated is occupied by the transverse colon, which can, therefore, lie in front of the stomach immediately under the diaphragm. The size of the stomach considerably varies both individually and depending on its filling. In average stretching it is about 21-25 cm long. The capacity of the stomach depends to a great extent on the dietary habits of the subject and may range from one to several litres. The newborn's stomach is very small (5 cm in length).

**Structure.** The wall of the stomach consists of the following four layers: (1) the mucous coat (tunica mucosa); (2) a submucous (tela submucosa);

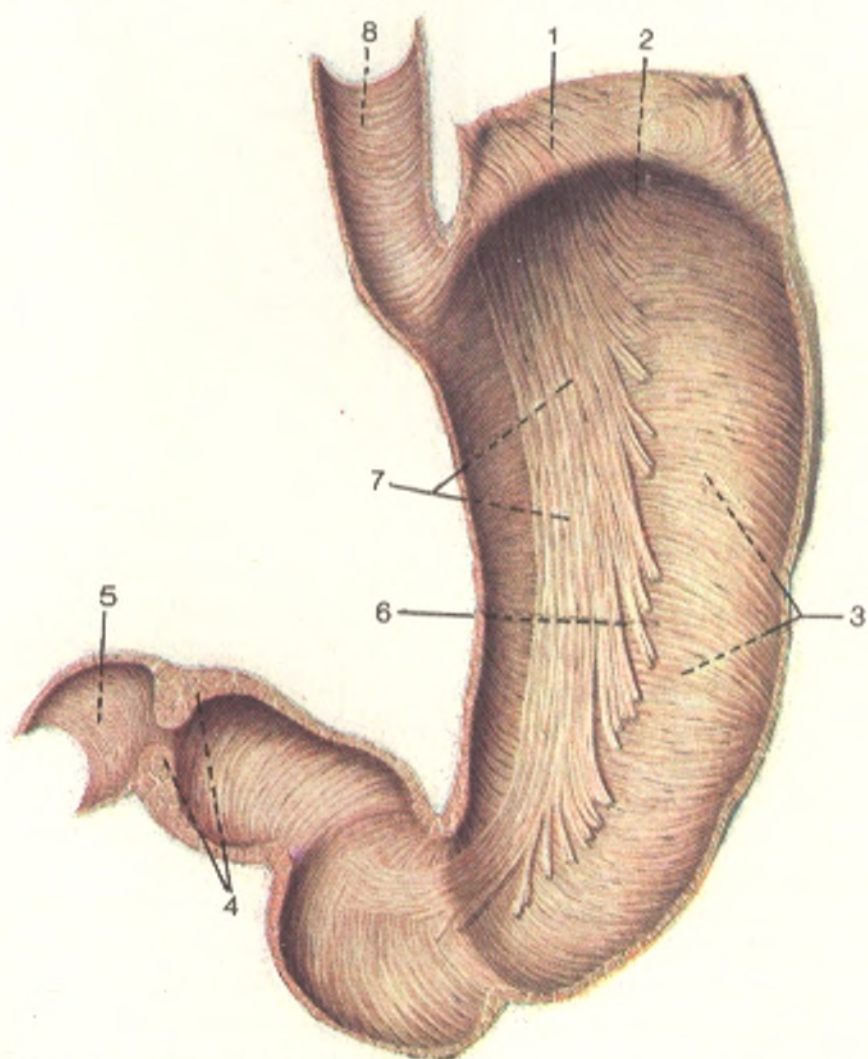


Fig. 198. Muscular coat of stomach, interior surface of posterior wall (the mucous and submucous coats are removed) (after Sinelnikov).

1, paries anterior ventriculi (divided and turned aside);  
2, fornix ventriculi;  
3, stratum circulare;  
4, m. sphincter pylori;

5, duodenum;  
6, paries posterior ventriculi;  
7, fibrae obliquae;  
8, tunica muscularis esophagi (stratum circulare)

(3) muscular coat (*tunica muscularis*); (4) serous coat (*tunica serosa*).

The *mucous coat (tunica mucosa)* (see Fig. 197) is built according to the principal function of the stomach, namely chemical treatment of the food in an acid medium. In view of this the mucosa contains special gastric glands, which produce gastric secretion, or *gastric juice (succus gastricus)* containing hydrochloric acid. Two types of glands are distinguished: (1) the *gastric glands proper (glandulae gastricae [propriae])*; they are numerous (approximately 100 glands per 1 mm<sup>2</sup> of the surface), located in the fundus and body of the stomach, and contain two types of cells: the chief (secreting pepsinogen) and parietal (responsible for the secretion of hydrochloric acid) cells; (2) the *pyloric glands (glandulae pyloricae)* consist of chief cells alone. Solitary *lymph nodules (nodulis folliculi lymphatici gastrici)* are scattered at places in the mucosa. The close contact of the bolus with the mucous membrane and its adequate saturation with the gastric juice occur because the mucosa is capable of gathering into  *folds (plicae gastricae)* due to contraction of its own musculature (*lamina muscularis mucosae*) and because of the presence of loose submucous tissue (*tela submucosa*) containing vessels and nerves and allowing the mucosa to smooth out and then to gather into folds of different directions. The folds on the lesser curvature are longitudinal and form the "gastric path", which, on contraction of the gastric muscles, may transform into a canal at the given moment in which the liquid parts of the food (water, salt solutions) pass from the oesophagus into the pylorus, by-passing the cardiac part of the stomach. In addition to folds, the stomach has rounded elevations (1-6 mm in diameter) called *gastric areas (areae gastricae)* on whose surface numerous tiny openings (0.2 mm in diameter) of the *gastric pits (foveolae gastricae)* can be seen. The gastric glands open into these pits. A fresh mucous coat is reddish-grey and at the junction of the oesophagus with the stomach a sharp borderline between the squamous epithelium of the oesophagus (skin type epithelium) and the columnar epithelium of the stomach (intestinal type epithelium) is noticeable macroscopically. In the region of the pyloric orifice (*ostium pylorica*) is a circular mucosal fold separating the acid medium of the stomach from the alkaline medium of the intestine; it is called *valvula pylorica* (BNA).

The *muscular coat (tunica muscularis)* (Fig. 198) is composed of unstriated muscle fibres, which contribute to the mixing and movement of food; according to the sac shape of the stomach, they are arranged not in two layers, like the fibres in the oesophageal tube, but in three: an *external longitudinal layer (stratum longitudinale)*; a *middle circular layer (stratum circulare)*, and an *internal oblique layer (stratum obliquae)*. The longitudinal fibres are continuation of similar fibres of the oesophagus. The circular layer is stronger than the longitudinal layer and is continuous with the circular fibres of the oesophagus. Toward the distal opening of the stomach, the circular layer increases in thickness and at the junction of the pylorus and the duodenum it forms a ring of muscular tissue, the *pyloric sphincter (m. sphincter pylori)*. *Valvula pylorica*, which corresponds to the pyloric sphincter, on contraction of the sphincter isolates completely the cavity of the stomach from the cavity of the duodenum. The pyloric sphincter and valvula

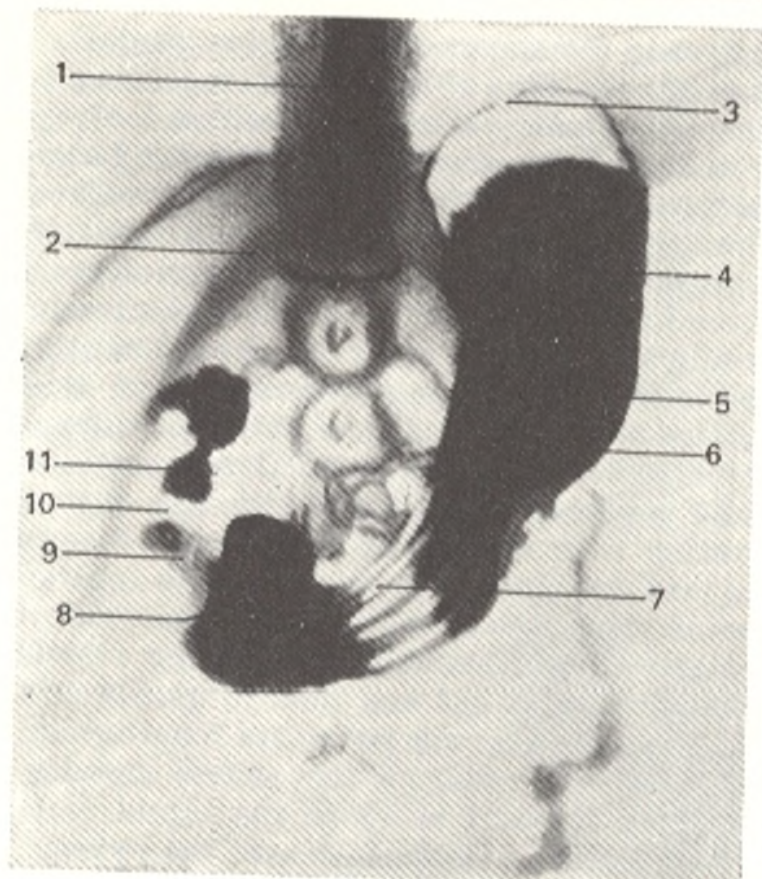


Fig. 199. Radiograph of stomach.

- 1, spine;
- 2, twelfth rib;
- 3, fundus (fovea) of stomach;
- 4, body of stomach;
- 5, lesser curvature;
- 6, greater curvature;
- 7, longitudinal mucosal folds;
- 8, angulus ventriculi;
- 9, physiological gastric sphincter (sphincter antri);
- 10, anatomic sphincter (pylorus);
- 11, bulbus duodeni

pylorica constitute a special adjustment regulating the passage of food from the stomach into the duodenum and preventing its return; otherwise the normal acid gastric medium would be neutralized.

The oblique muscle fibres (*fibrae obliquae*) are arranged in bundles, which loop over the cardiac orifice on the left and form a "supporting loop" that serves as the *punctum fixum* for the oblique muscles. The oblique muscles descend obliquely on the anterior and posterior surfaces of the stomach and on contraction pull the greater curvature toward the cardiac orifice.

The outermost layer of the gastric wall is formed by the *serous coat* (*tunica serosa*), which is a part of the peritoneum. The serous coat is closely attached to the whole surface of the stomach except for the curvatures where large vessels pass between the two peritoneal layers. On the posterior surface of the stomach, to the left of the cardiac orifice, is a small area not covered by the peritoneum (about 5 cm wide) where the stomach is in direct contact with the diaphragm and, sometimes, also with the upper pole of the left kidney and the adrenal gland. Despite its relatively simple shape, the human stomach, regulated by a complex innervation apparatus, is a very perfect organ enabling man to adapt himself to different dietary regimens quite easily. The shape of the stomach easily changes after death and the findings in a cadaver cannot be fully related to a live subject. Examination with a gastroscope and X-ray is, therefore, very valuable.

**The stomach of a live subject.** X-ray examination of the stomach (Fig. 199) of a live subject enables one to study the organ during various

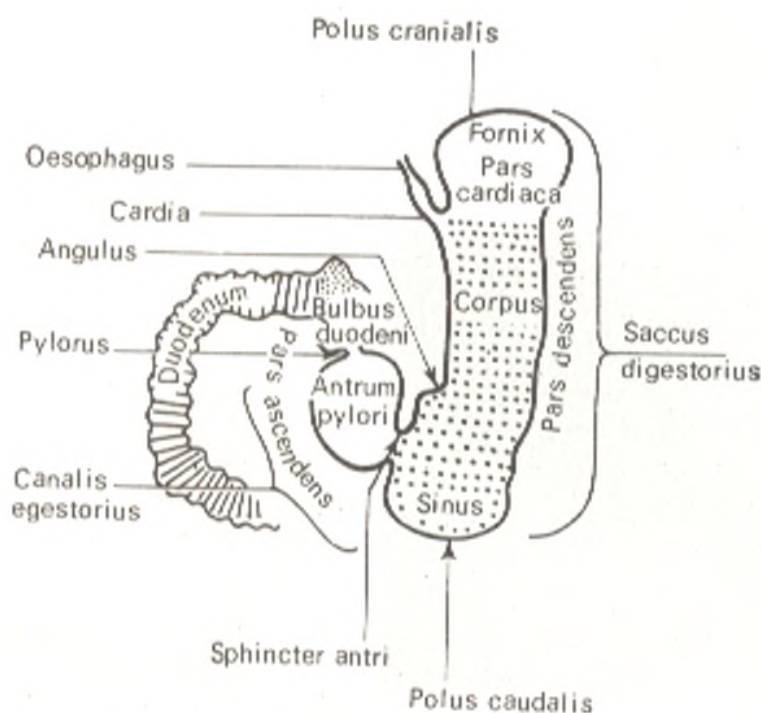


Fig. 200. Roentgenoanatomic nomenclature of the stomach

physiological states (the entry of food into the stomach, peristalsis, passage of food into the duodenum, etc.). It also discloses much greater variations in the shape and position of the stomach than those found in a cadaver. That is why the commonly accepted anatomical nomenclature described above is supplemented by some terms for designating areas of the stomach according to the anatomophysiological features of its different parts. These additional terms are as follows (Fig. 200).

1. *The gastric sac (sinus ventriculi)*, i.e. the most distally located part of the stomach, opposite the *angulus ventriculi*; the food falls on this area, like on the bottom. The upper vault-like part of the stomach shaped like a fornix should, therefore, be called the fornix and not the fundus, since food is not dropped here but gases rise and form the "air bubble" visible on X-ray.

2. *The physiological sphincter (sphincter antri)* is seen only in a live subject; it separates the body of the stomach from the pyloric antrum.

According to the predominance of either the digestive or the motor function of its parts, two unequal parts are distinguished in the stomach: (1) the *digestive sac (saccus digestorius)* (fundus, body, and sinus); (2) the *evacuation canal (canalis egestorius)*, i.e. the rest of the stomach (pylorus and pyloric part) (see Figs. 199 and 200).

The borderline between them are *sphincter antri* and *angulus ventriculi* (on the lesser curvature). *Saccus digestorius* extends downward, this is the descending part, whereas *canalis egestorius* usually extends upward, forming the ascending part of the stomach. A stomach shaped like a retort (as it is sometimes described) is found only in a cadaver; in a live subject a stomach of such shape can be encountered only in deep anaesthesia or in

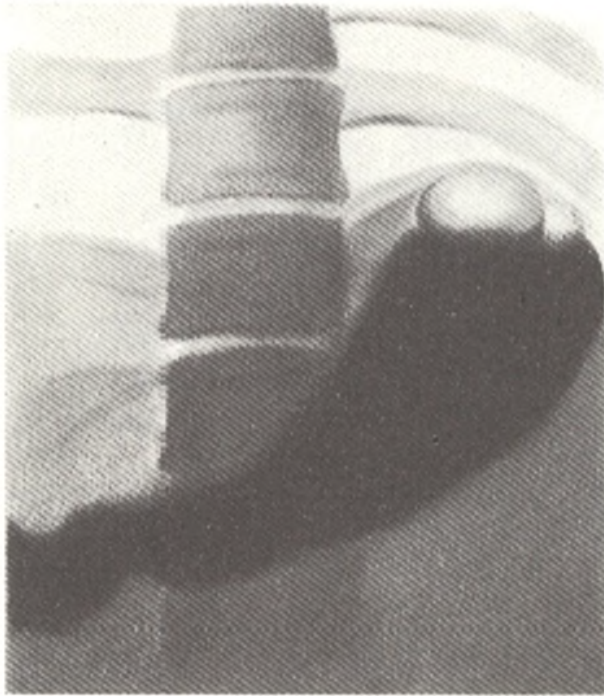


Fig. 201. Horn-shaped stomach (radiograph)

disappearance of the muscle tonus. *Three main normal shapes and positions of the stomach* are encountered in a live subject (see Figs. 201, 202, and 203).

1. *Horn-shaped stomach.* Saccus digestorius lies almost transversely and narrows gradually toward the pyloric part (canalis egestorius). The pylorus is to the right of the right spinal border and is the lowest point of the stomach. As a result, the angle between the descending and ascending parts of the stomach is absent. The entire stomach is situated almost transversely (Fig. 201).

2. *Stomach shaped like a fish hook.* The descending part of the stomach (saccus digestorius) extends downward obliquely or almost straight. The ascending part (canalis egestorius) lies obliquely, ascending to the right. The pylorus is at the right spinal border and above the lower pole of the stomach. An angle (angulus ventriculi), somewhat smaller than a right angle, forms between the ascending and descending parts. The whole stomach lies obliquely (Fig. 202).

3. *Stomach shaped like an elongated hook.* It resembles the hook-shaped stomach but has distinguishing features; as the name implies, the descending part (saccus digestorius) is elongated and descends vertically; the ascending part (canalis egestorius) ascends more steeply than the similar part in a hook-shaped stomach. The angle formed by the lesser curvature (angulus ventriculi) is more acute (Fig. 203). The whole stomach is to the left of the midline and passes only a little beyond. The general position of the stomach is vertical. A correlation is therefore noted between the shape and position of the stomach: a horn-shaped stomach usually lies transversely, a hook-shaped stomach lies obliquely, whereas an elongated stomach has a vertical position. The stomach of a live subject differs from the stomach of a cadaver in that the former has a tonus which is determined by the degree of contraction of the musculature depending on the innervation.

The muscle tonus is determined by the general constitution of the organism, and therefore the shape and position of the stomach depend on the type of body build. Subjects who have a brachymorphic type of constitution and a short and broad thoracic cage, a high position of the diaphragm, well developed musculature (particularly in the abdominal wall), high (within normal limits) tonus of the stomach and a high intra-abdominal pressure, and obese subjects with copious fat deposits on the abdomen often have a horn-shaped stomach and it lies transversely. The stomach in such cases is situated on a high level so that its lowest part is 4-5 cm above the line connecting the iliac crests, *linea biiliaca*.

In subjects with a dolichomorphic body build and features opposite to those mentioned above, the stomach is usually elongated and is in a vertical position. Almost the whole stomach lies to the left of the spine and is situated on a low level so that the pylorus is in line with the spine, while the lower pole of the stomach descends somewhat below *linea biiliaca*. In subjects with an intermediate (between the two extremes) type of constitution a hook-shaped stomach is encountered; it is situated obliquely and on an average level and its lower pole is on a level with the *linea biiliaca*. These shape and position are most common.

Since all the listed factors that determine the shape and position of the stomach vary and are encountered in a great variety of combinations, the shape and position of the stomach of a subject prove to be different during examination at different times. The concept of "norm" cannot therefore be restricted to a single type of structure, and all normal varieties should be taken into consideration. As to the age and sex features of the stomach, it is usually horn-shaped in children and old-aged subjects but elongated in females. The dependence of the shape and position of the stomach on the position of the body must be pointed out. All the above-described

Fig. 202. Hook-shaped stomach (radiograph)

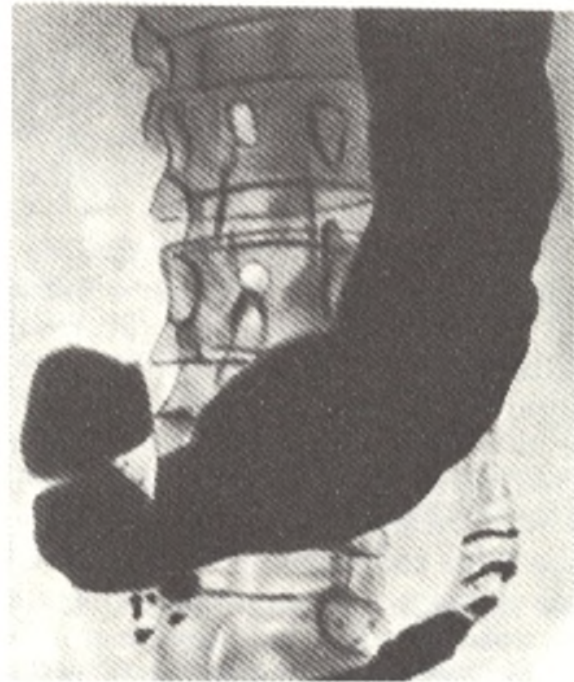




Fig. 203. Stomach shaped like an elongated hook (radiograph)

roentgenoanatomic signs of the stomach were demonstrated in examination in an erect position. Displacement of the stomach, mainly in the region of the greater curvature and the pylorus, is encountered.

Peristaltic waves of contraction of the stomach musculature, running along the greater curvature to the pylorus, are seen during X-ray examination. The folds of the gastric mucosa form due to contraction of the lamina muscularis mucosae, tissue turgor, swelling of the submucous layer, and dilatation of the vessels. All this constitutes the *autoplasty apparatus*, which lends the mucosa the capacity for moving independently of the other coats of the wall and for forming folds of different size and direction. The continuing activity of the apparatus ensures relative permanence of the folds (Fig. 204).

The predominating picture of the mucosal relief in the different parts of the stomach is as follows: a network pattern in the cardiac part; longitudinal folds in the lesser curvature; dentate contour in the greater curvature; longitudinal and oblique folds in saccus digestorius; predominantly longitudinal as well as radial and transverse folds in antrum pylori. At the junction of saccus digestorius and canalis egestorius is a boundary-line fold.

This picture of the mucosal relief is produced by the folds on the posterior wall because on the anterior wall they are few in number. The direction of the folds corresponds to the movement of the food, that is why the mucosal relief is very variable, which is a sign of norm. The *autoplasty apparatus* does not function in a cadaver as a consequence of which the picture of a "dead" stomach cannot be a reliable object for judging the norm.





Fig. 204. Radiograph of stomach.  
Relief of the mucous membrane.

1, fundus (fornix) of stomach;  
2, longitudinal folds in the body of the stomach

The cavity of the stomach can also be inspected directly in a live subject with a special optic instrument (a gastroscope) introduced into the stomach through the oesophagus; the interior of the stomach is thus examined (gastrosocopy).

During *gastrosocopy*, the stomach is inspected spatially. According to Sternberg, the axis of the stomach, i.e. the line connecting the centres of the separate transverse sections of the stomach, is a spiral, while the stomach itself is a right-hand screw tube. The cardiac orifice and the pylorus are very close to each other but a boundary line always exists between *saccus digestorius* and *canalis egestorius* due to contraction of the physiological antral sphincter; as a consequence, an obstacle occurs here for the advancement of the gastroscope and a boundary-line mucosal fold is seen. The other mucosal folds twist in different directions, resembling the brain gyri. Normally, the blood vessels cannot be seen. Four types of movements of the stomach can be watched: (1) pulsed; (2) movements related to respiration; (3) movements related to the tonus of the stomach, and (4) peristaltic movements. The findings of gastrosocopy, supplementing X-ray examination, give an idea of the anatomy of the stomach of live subjects.

The *arteries of the stomach* arise from the celiac trunk and the splenic artery. On the lesser curvature is the anastomosis between the left gastric artery (from the celiac trunk) and the right gastric artery (from the common hepatic artery); on the greater curvature

pass the left gastroepiploic artery (from the splenic artery) and the right gastroepiploic artery (from the gastroduodenal artery). The short gastric arteries from the splenic artery pass to the fundus of the stomach. The arterial arches surrounding the stomach are a functional adjustment necessary for the stomach as an organ that changes in shape and size; when the stomach contracts, the arteries become twisted, when it is distended they straighten out. The *veins* correspond to the arteries in their course and drain into the portal vein. The draining *lymphatic vessels* pass from different parts of the stomach in different directions.

1. From the greater area, including the medial two thirds of the fundus and body of the stomach, the lymphatic vessels pass to the chain of the left gastric lymph nodes lying on the lesser curvature along the course of the left gastric artery. Along the way the lymphatics of this area are interrupted by the constantly present anterior and inconstant posterior pericardial accessory nodules.

2. The lymphatics from the remaining part of the fundus and body of the stomach to the middle of the greater curvature follow the course of the left gastroepiploic and the short gastric arteries and pass to the nodes situated in the hilus of the spleen and on the tail and nearest part of the body of the pancreas (the pancreaticolienal lymph nodes). According to certain authors vessels carrying lymph from the pericardial zone may pass on the oesophagus to the nodes of the posterior mediastinum situated above the diaphragm.

3. The vessels from the area adjoining the right half of the greater curvature drain into a chain of gastric lymph nodes stretching along the course of the right gastroepiploic artery and into the pyloric nodes. The vessels carrying lymph from the pyloric nodes follow the course of the gastroduodenal artery and reach a large node of the hepatic chain near the common hepatic artery. Some of the vessels from this area of the stomach reach the superior mesenteric nodes.

4. From a small area of the lesser curvature and the pylorus the vessels follow the course of the right gastric artery and pass to the hepatic and pyloric nodes mentioned above. The boundaries between all these areas are relative.

The *nerves* of the stomach are branches of the vagus nerve and sympathetic trunk. The vagus nerve intensifies peristalsis of the stomach and the secretion of its glands, causes relaxation of m. sphincter pylori, and transmits the sense of nausea and hunger. The sympathetic nerves reduce peristalsis, induce contraction of the pyloric sphincter and constriction of the vessels, and transmit the sense of pain.

## DERIVATIVES OF THE MIDGUT

### THE SMALL INTESTINE

The small intestine (*intestinum tenue*) (Gk *enteron*, hence enteritis, inflammation of the intestinal mucosa) begins at the pylorus, makes a series of looped curves, and ends at the beginning of the large intestine. The small intestine is about 7 m long in male cadavers and about 6.5 m in female cadavers; its length exceeds the length of the body 4.3 times. It is always longer in cadavers than in live subjects due to postmortem relaxation of the muscles. Mechanical (movement) and further chemical treatment of food under conditions of an alkaline reaction occurs in the small intestine, as well as absorption of the nutrients. Accordingly, special adjustments for the secretion of digestive juices (glands situated both in and outside the intestinal wall) and for the absorption of the digested substances, are present in it.

Three parts are distinguished in the small intestine: (1) the duodenum, the part nearest to the stomach, 25-30 cm long; (2) the jejunum, which accounts for two fifth of the small intestine with the exception of the duode-

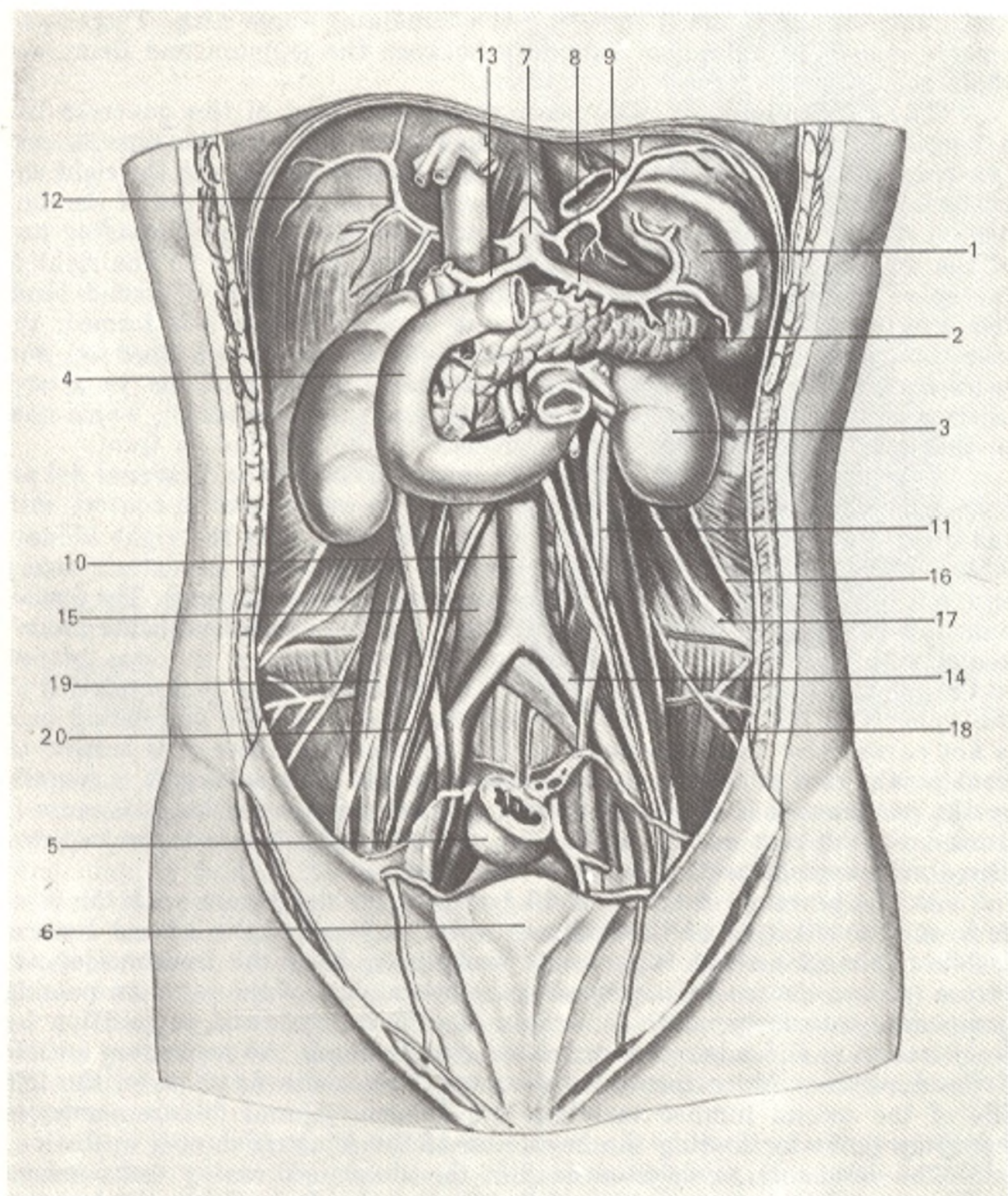


Fig. 205. Duodenum, pancreas, spleen, and kidneys.

1, lien;  
 2, pancreas;  
 3, ren sinister;  
 4, duodenum;  
 5, rectum;  
 6, vesica urinaria;  
 7, truncus celiacus;  
 8, a. lienalis;  
 9, a. phrenica inferior sinistra;  
 10, aorta abdominalis;  
 11, ureter;

12, a. phrenica inferior dextra;  
 13, a. hepatica communis;  
 14, a. iliaca communis;  
 15, v. cava inferior;  
 16, n. iliohypogastricus;  
 17, n. ilioinguinalis;  
 18, n. cutaneus femoris lateralis;  
 19, n. genitofemoralis;  
 20, a. testicularis

num; and (3) the ileum, composing the remaining three fifth. There is no clearly manifest anatomical boundary between the jejunum and ileum and their separation is therefore relative.

The **duodenum** (Fig. 205) runs around the head of the pancreas like a horseshoe. Four main parts are distinguished in it: (1) the *superior part* (*pars superior*) passes at the level of the first lumbar vertebra to the right and posteriorly and, forming a descending bend, the superior flexure of the duodenum (*flexura duodeni superior*) is continuous with (2) the *descending part* of the duodenum (*pars descendens*), which passes downward on the right of the spine to the level of the third lumbar vertebra where a second bend, the inferior flexure of duodenum (*flexure duodeni inferior*), is formed, the intestine passing to the left and forming (3) the *horizontal (inferior) part* (*pars horizontalis*), which stretches horizontally in front of the vena cava inferior and the aorta and (4) the *ascending part* (*pars ascendens*), which rises to the level of the first or second vertebra on the left and in front.

**Topography of the duodenum.** The inner surface of the duodenal flexure fuses with the head of the pancreas; the superior part comes in contact with the quadrate lobe of the liver, the descending part with the right kidney, whereas the horizontal part passes between the superior mesenteric artery and vein (in front) and the aorta and vena cava inferior (behind). The duodenum is devoid of the mesentery and is only partly covered with the peritoneum, mainly in front. The relation to the peritoneum of the area nearest to the pylorus (for a distance of about 2.5 cm) is the same as the relation of the pylorus to the peritoneum. The anterior surface of the descending part is not covered by the peritoneum in the middle area where it is crossed in front by the root of the transverse mesocolon; the horizontal part is covered by the peritoneum in front, except for a small area where the duodenum is crossed by the root of the mesentery of the small intestine (the superior mesenteric vessels are enclosed in the root).

At the junction of the ascending part of the duodenum with the jejunum on the left side of the first, or most frequently, the second lumbar vertebra, the intestinal tube bends sharply to form the **duodeno-jejunal flexure** (*flexura duodenojejunalis*) with the initial part of the jejunum passing downward, anteriorly, and to the left. This flexure is fixed in position by the peritoneum and a band of unstriated muscle fibres, the **suspensory muscle of the duodenum** (*m. suspensorius duodeni*). Due to its fixation on the left side of the second lumbar vertebra, the duodeno-jejunal flexure serves as a guiding point for finding the beginning of the jejunum during operation.

The duodenum is situated deep in the abdominal cavity and nowhere does it adjoin the anterior abdominal wall directly. It is within the boundaries of the epigastrium and the umbilical region proper.

**The duodenum of a live subject.** In X-ray examination (Figs. 203 and 206), the initial part of the duodenum is distinguished as a special part, the *duodenal bulb* (*bulbus s. ampulla duodeni*). It is seen as a triangular shadow with the base facing the pylorus. During the contraction of the pylorus the shadow of the bulb is separated from this part of the stomach by an area of diminished density corresponding to the contracted pylorus. The bulb is

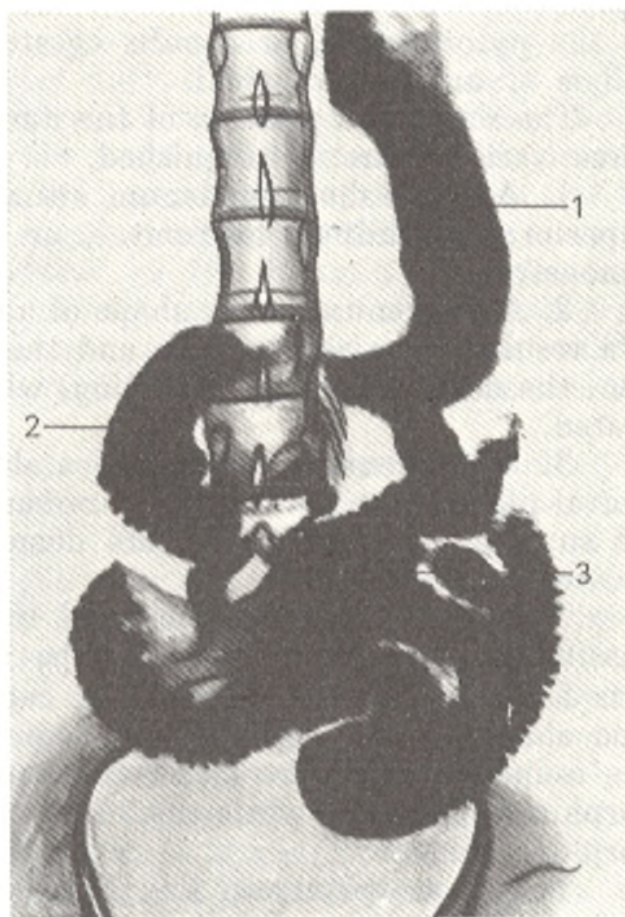


Fig. 206. Radiograph of the gastro-intestinal tract.

- 1, stomach;  
2, duodenum;  
3, jejunum and ileum

larger in diameter than the rest of the duodenum. Its X-ray boundaries are as follows: from the area of diminished density at the site of the pylorus to the base of its triangular shadow (in cadaver—from valvula pylori to the first circular fold of the mucosa). The mucous membrane in the bulb, like that in the pylorus, has longitudinal folds, whereas in the rest of the duodenum the folds are circular. These specific features in the structure of the bulb are due to its development from the foregut and not from the midgut, from which the rest of the duodenum develops.

There is therefore a definite anatomical difference between the shape of the initial part of the duodenum in a live subject and that in a cadaver. In a cadaver, it has the same shape and the same diameter as the rest of the duodenum.

In a live subject, the duodenum is much wider at the beginning than in its other parts. The duodenal bulb is so different from the remaining part of the duodenum and resembles the pyloric part of the stomach so closely that some radiologists consider it to be a part of the stomach and not the duodenum; they draw the boundary line between the stomach and the duodenum not along the valvula and sphincter pylori but at the junction of the duodenal bulb with the remaining part of the duodenum (externally) and where the longitudinal folds of the duodenal mucosa are continuous with the transverse folds (internally). As a result, they regard the stomach as an organ composed of three parts: (1) the body, or *saccus digestorius*;

(2) the pyloric part, or *canalis egestorius*, and (3) the duodenal bulb, or *bulbus s. ampulla duodeni*.

The *shape and position* of the duodenum vary greatly in live subjects. Three variants are distinguished.

1. A horse-shoe duodenum situated like in a cadaver; all its parts (superior, descending, horizontal, or inferior, and ascending) are clearly demonstrated.

2. A duodenum in the shape of a sharply bent loop situated vertically; as a result of the sharp curve and the vertical position only two parts are seen, the descending and ascending, while the remaining part is not demonstrated.

3. A duodenum shaped like a sharply bent loop but situated in the frontal plane. Due to the steep curve and horizontal position only two parts, the superior and horizontal, are demonstrated, while the other two parts are not seen.

Transient forms between the three types are encountered. Another classification of the duodenal shape has been suggested (Sokolov, 1958). It is based on the character of the curves: rounded shapes (circular, horse-shoe shape, etc.), angulated (C-shaped, U-shaped), plicated, and mixed. The rounded shapes are mostly encountered in individuals with a brachymorphic body build, while the angulated shapes usually occur in a dolichomorphic build.

The great variety in the shape and position of the duodenum is due to the different degree of its fixation to the abdominal wall (in some cases it even has a small mesentery in its initial segment) and the mobility of the stomach. Some developmental anomalies and malpositions of the duodenum are also encountered: (1) *situs inversus partialis duodeni*, in which the position of the duodenum is a mirror reflection of its normal position; (2) *duodenum mobile*, in which an elongated and mobile duodenum forms loops; (3) *inversio duodeni*, with the descending part stretching not downward, but upward and to the left to form an upside-down letter U. Only X-rays have provided the possibility for studying all these variants and anomalies in the shape and position of the duodenum.

**The jejunum and ileum.** The jejunum and ileum are embraced under the common name *intestinum tenue mesenteriale* because, in distinction from the duodenum, this segment is fully invested in the peritoneum and attached to the posterior abdominal wall by the mesentery. Though there is no manifest boundary between the jejunum (in a cadaver this part is usually found to be empty, hence the name, *L jejunum empty*) and the ileum, as it is pointed out above, the typical segments of both parts (the superior segment of the jejunum and the inferior segment of the ileum) are clearly distinct: the jejunum is larger in diameter, its walls are thicker, and it is richer in vessels (the difference on the part of the mucous coat is pointed out below). The loops of the mesenteric part of the small intestine occupy the mesogastrium and hypogastrium for the most part, those of the jejunum are mostly to the left of the midline, while the loops of the ileum lie mostly to the right of the midline. The mesenteric part of the small intestine is

covered in front for some distance by the omentum (a serous fold of the peritoneum descending from the greater curvature of the stomach) and is as if framed by the transverse colon above and the ascending and descending parts of the colon on the sides; below, the loops of the intestine may descend into the true pelvis; some of the loops are sometimes located in front of the colon. In approximately 2 per cent of cases, an appendage, Meckel's diverticulum (*diverticulum Meckelii*), is present on the ileum at a distance of about 1 cm from its end. The diverticulum is a remnant of the embryonic vitello-intestinal duct; it is 5-7 cm in length, approximately the same calibre as the ileum, and arises from the side opposite to that on which the mesentery is attached.

**Structure.** The *mucous coat* (*tunica mucosa*) of the small intestine has a lustreless, velvety appearance due to the numerous *intestinal villi* (*villi intestinalis*) (Fig. 207) covering it. The villi are projections of the mucous membrane about 1 mm in length; like the mucosa they are covered by prismatic epithelium and have a lymphatic sinus and blood vessels in the centre. The villi are concerned with the absorption of nutrients, which had been exposed to the effect of the intestinal juice secreted by the intestinal glands; proteins and carbohydrates are absorbed in the venous vessels and pass a control in the liver, whereas fats are absorbed in the lymphatic (lacteal) vessels. The number of villi is greater in the jejunum, where they are thinner and longer. Besides digestion in the intestinal cavity, there is *parietal digestion* which has been discovered recently. It occurs in the tiniest villi, which are demonstrated only with an electron microscope and contain digestive enzymes.

The large molecules of the nutrients cannot enter these submicroscopic villi and undergo routine digestion in the cavity of the intestine. The small molecules, however, penetrate these villi and disintegrate while the products of this disintegration are immediately absorbed. The absorbing surface of the mucous membrane of the small intestine is considerably enlarged due to the presence of the transverse, or *circular folds* (*plicae circulares*) (Fig. 208). These folds are formed only by the mucous coat and the submucous layer (the muscular coat does not take part in their formation) and are permanent structures, which do not disappear even when the intestinal tube is distended. The circular folds differ in character in the different parts of the small intestine; they are absent in the initial part of the duodenum close to the pylorus, in the rest of the duodenum and in the upper part of the jejunum they are high and placed closely to one another, while more distally they become lower and are set less closely and disappear completely in the end of the ileum. Besides the circular folds, the mucous membrane of the duodenum has longitudinal duplications in its initial part (in the region of the bulb) and a *longitudinal fold* (*plica longitudinalis duodeni*) on the medial wall of the descending part; this fold has the appearance of an elevation, which terminates as a papilla, the *greater duodenal papilla* (*papilla duodeni major*) (see Fig. 208). The opening of the conjoined common bile duct and the pancreatic duct is on the papilla. This explains the name of the dilatation found immediately proximal to the opening, the hepatopancreatic ampulla. Proxi-

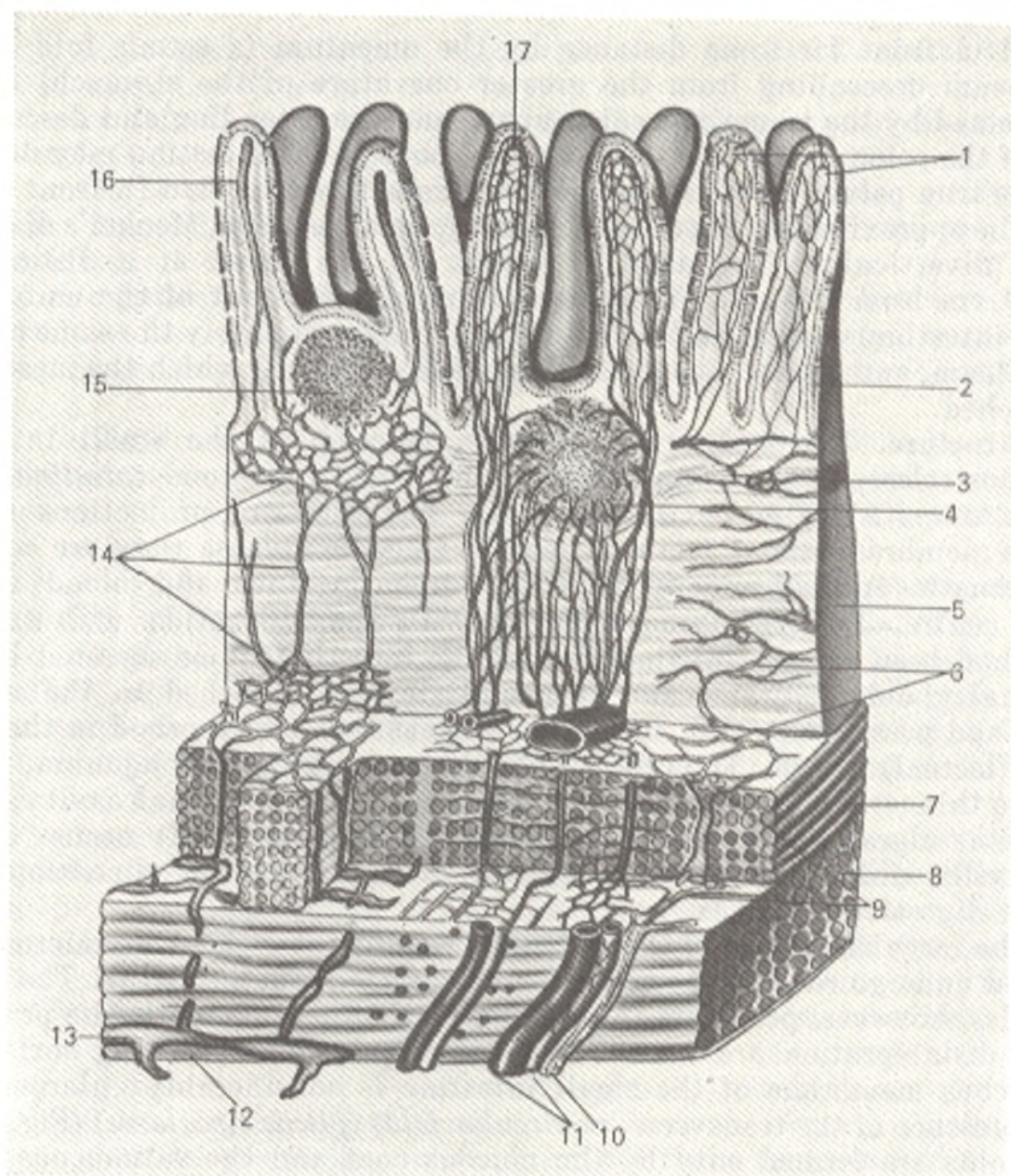


Fig. 207. Structure of villi of small intestine (after Kiss and Szentagóthai).

- |   |                                    |
|---|------------------------------------|
| 1, plexus nervosus villi;   | 9, plexus myentericus;             |
| 2, epithelium;  | 10, n. intestinalis;               |
| 3, tunica muscularis mucosae;   | 11, a. et v. intestini;            |
| 4 and 15, folliculi lymphatici solitarii;                                     | 12, tunica serosa;                 |
| 5, tunica submucosa;  | 13, plexus lymphaticus subserosa;  |
| 6, plexus submucosus;   | 14, plexus lymphaticus submucosus; |
| 7 and 8, stratum circulare and stratum<br>longitudinale of the muscular coat; | 15, vas lymphaticum centrale;      |
|   | 17, plexus vasculosus villi        |

mal to the greater duodenal papilla is a *smaller duodenal papilla* (*papilla duodeni minor*) (the accessory pancreatic duct opens on it) (see Fig. 208).

Numerous small simple tubular intestinal glands (*glandulae intestinales*) are embedded in the mucous membrane, without penetrating the submucosa, for the whole length of the small intestine and also, as it is stated below, the large intestine. They secrete intestinal juice. In the duode-



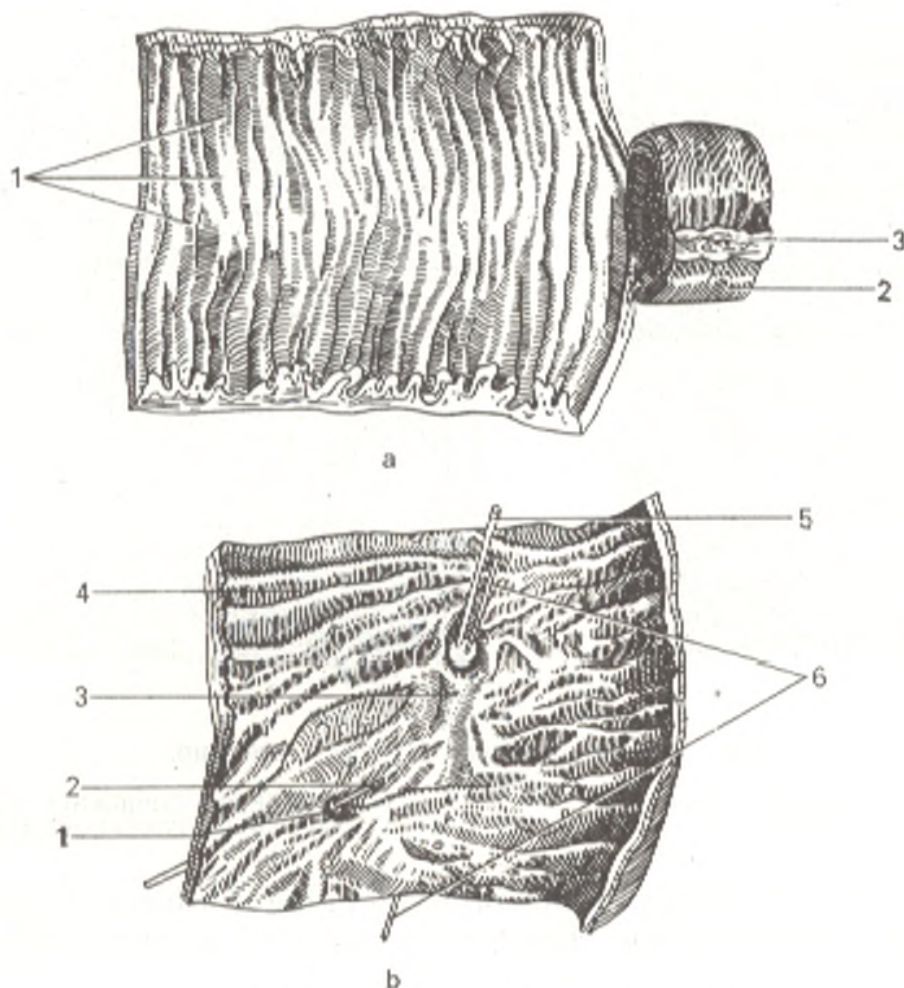


Fig. 208. Mucous coat of small intestine.

a, Jejunum:

1, plicae circulares;

2, tunica serosa;

3, the site of attachment of the mesentery;

b, descending part of duodenum:

1, papilla duodeni minor;

2, catheter introduced into ductus pancreaticus accessorius;

3, plica longitudinalis duodeni;

4, plicae circulares;

5 and 6, catheters introduced into ductus pancreaticus and ductus choledochus

num, in its upper segment for the most part, is another type of glands, the duodenal glands (*glandulae duodenalae*), which, in contrast to the intestinal glands, are lodged in the submucous layer. They resemble the pyloric glands of the stomach in structure. The small intestine has a lymphatic apparatus, which renders harmful substances and micro-organisms harmless. It consists of solitary lymphatic nodules (*folliculi lymphatici solitarii*) and their aggregations called Peyer's patches (*folliculi lymphatici aggregati* [Peyeri]).

The solitary lymphatic nodules are scattered throughout the small intestine as whitish elevations the size of a millet (Fig. 209). Peyer's patches are only found in the ileum. These are flat elongated patches whose longitudinal diameter coincides with the longitudinal axis of the intestine. Peyer's patches are arranged along the antimesenteric border of the ileum and can therefore be disclosed only by cutting a specimen of the intestine along the

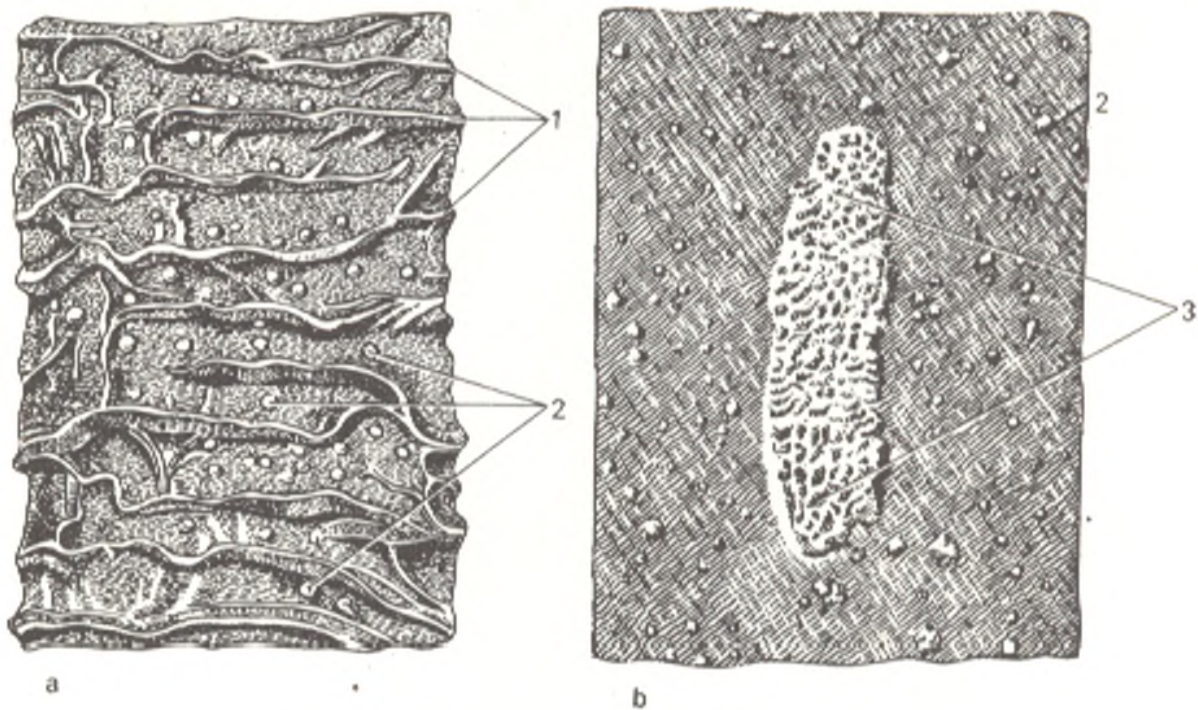


Fig. 209. Mucous coat of small intestine.

*a*, jejunum; *b*, ileum, distal part:  
1, plicae circulares;

2, folliculi lymphatici solitarii;  
3, folliculi lymphatici aggregati

mesenteric border. Neither villi nor intestinal glands are usually encountered on the surface of the patches. The total number of patches ranges from 20 to 30.

Biological (intracellular) digestion of food also occurs in the lymphatic apparatus of the small intestine.

The *muscular coat* (*tunica muscularis*), in accordance with the tubular shape of the small intestine, is composed of two layers of smooth muscles, an outer, longitudinal, and an inner, circular layer, which is developed better than the outer layer. The muscular coat is thinner in the distal segments of the intestine. An opinion exists to the effect that the circular layer of muscles contains also *spiral muscle fibres* forming a continuous layer of spiral musculature here and there. The contractions of the muscle fibres are peristaltic in character and spread successively toward the distal end of the intestine; the circular fibres constrict the lumen, while the longitudinal fibres shorten and so contribute to its distension (distal to the contracted ring of fibres). The spiral fibres promote movement of the peristaltic wave along the axis of the intestinal tube. Contractions in the opposite direction are called antiperistaltic.

The *serous coat* (*tunica serosa*) invests the small intestine except for a narrow strip on the posterior surface between the two layers of the mesentery where nerves and blood and lymphatic vessels approach the intestine.

The jejunum and ileum of a living person. Shadows of the loops of the small intestine are demonstrated by X-ray. The loops are situated partly horizontally and partly vertically on the left and in the middle of the abdo-

minal cavity. The loops of the ileum occupy the right iliac fossa and are for the most part arranged vertically and obliquely, forming conglomerates.

The *mucosal relief*. The transverse folds in the jejunum lend the outer contours of the shadow a scalloped or pinnate pattern, which is a characteristic sign of the small intestine; both longitudinal and oblique folds are seen at definite phases of peristalsis, like in the stomach, due to the autoplasty apparatus. The number of longitudinal folds in the ileum increases toward the large intestine. The transverse folds are anatomical and constant, the other folds are physiological and inconstant.

The longitudinal folds form grooves and canals for the passage of food while the transverse folds delay its movement to some extent. The movement of all these folds produces most diverse X-ray patterns.

X-ray examination of live subjects demonstrates different types of movement of the small intestine: (1) mixing movements produced by mucosal autoplasty; (2) pendulum-like, swinging movements of separate loops, and (3) peristaltic movements.

The entry of food from the small intestine into the caecum occurs rhythmically and is regulated by the ileocaecal valve (*valva ileocecalis*) situated in the caecum, which is opened and closed like the pylorus. The swallowed contrast medium reaches the jejunum in 30 minutes, fills the ileum in 90 minutes, starts entering the caecum in 4 hours, and is completely emptied into the large intestine in 7-8 hours.

The *arteries* of the small intestine, *aa. intestinales jejunales* and *ilei*, arise from the superior mesenteric artery. The duodenum is supplied from *aa. pancreaticoduodenalis* (from the gastroduodenal artery) and *aa. pancreaticoduodenales inferiores* (from the superior mesenteric artery). The *venous blood* flows along veins of the same name into the portal vein. The *lymphatic vessels* carry lymph to the coeliac and mesenteric lymph nodes (see the section dealing with the lymphatic system).

*Innervation* is accomplished from the vegetative nervous system. Three nerve plexuses are embedded in the intestinal wall: subserosal, myenteric, and submucous plexuses.

The sympathetic paths transmit the sense of pain and reduce peristalsis and secretion. The vagus nerve increases peristalsis and secretion.

## DERIVATIVES OF THE HINDGUT

### THE LARGE INTESTINE

The **large intestine** (*intestinum crassum*) extends from the end of the small intestine to the anus and is divided into the following parts: (1) **caecum**, the blind gut, with the vermiform process (*appendix vermiformis*); (2) **ascending colon** (*colon ascendens*); (3) **transverse colon** (*colon transversum*); (4) **descending colon** (*colon descendens*); (5) **sigmoid (pelvic) colon** (*colon sigmoideum*), and (6) **rectum**.

The total length of the large intestine varies from 1.0 to 1.5 m. Its width reaches 7 cm in the region of the caecum and then reduces gradually to about 4 cm in the descending colon. The large intestine is distinguished from the small intestine not only by a much larger diameter but also by its appearance characterized by the presence of: (1) specific longitudinal muscle

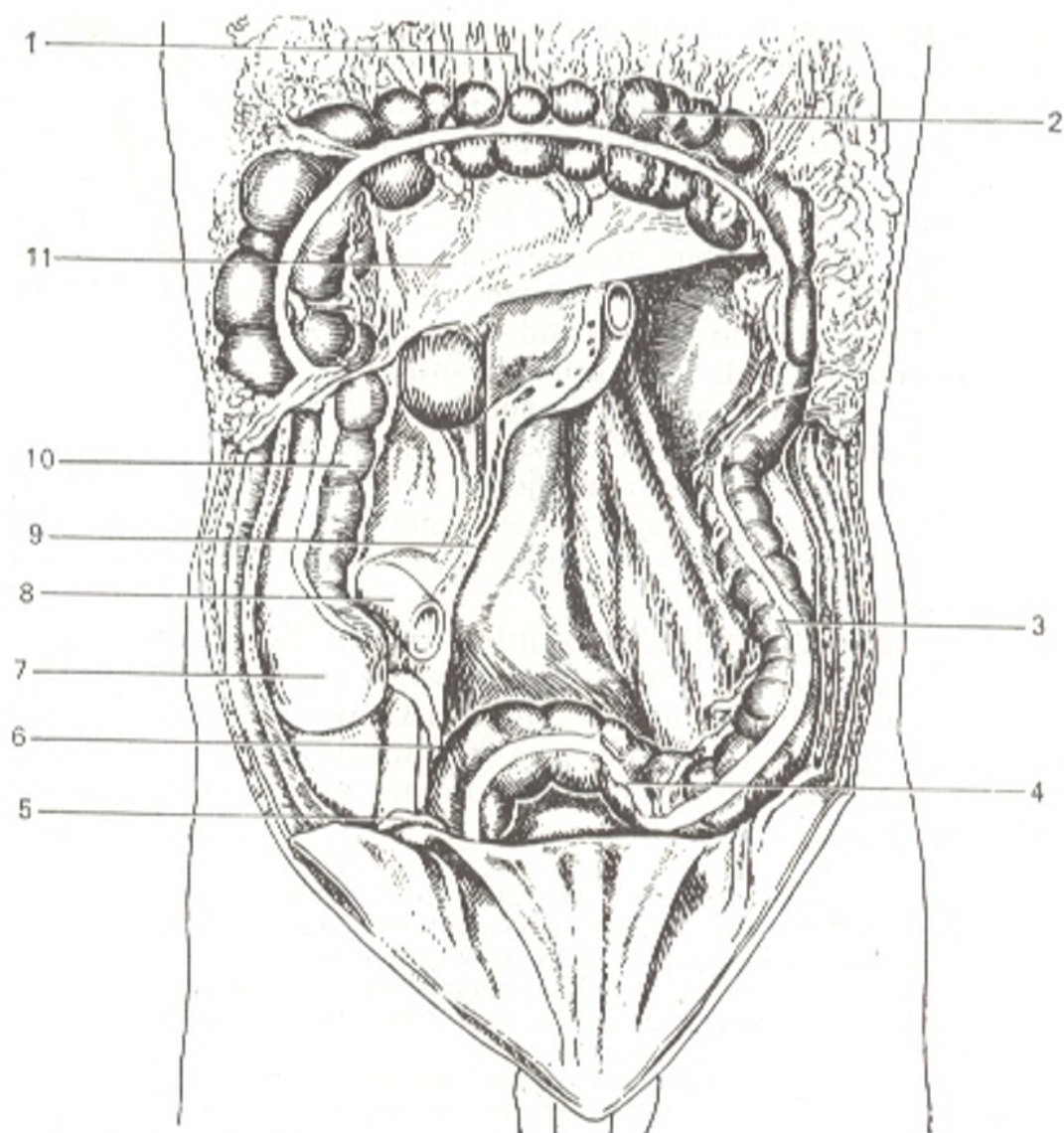


Fig. 210. Root of mesentery and the colon. The greater omentum and the transverse colon are pulled upward.

- |                          |                           |
|--------------------------|---------------------------|
| 1, omentum majus;        | 7, intestinum cecum;      |
| 2, coloa transversum;    | 8, intestinum ileum;      |
| 3, colon descendens;     | 9, radix mesenterii;      |
| 4, colon sigmoideum;     | 10, colon ascendens;      |
| 5, ductus deferens;      | 11, mesocolon transversum |
| 6, appendix vermiformis; |                           |

strips, or bands, *teniae coli*; (2) characteristic sacculations, *haustra coli*, and (3) fat-containing protrusions of the serous coat, *appendices epiploicae* (Fig. 210).

*Teniae coli*, three in number, begin at the base of the vermiform process and extend to the beginning of the rectum at approximately equal distances from each other. (To find the vermiform process in operation for appendicitis it is therefore necessary to find on the caecum the site where all the three bands as if come together.) *Teniae* substitute for the longitudinal muscular layer of the colon which does not form a single layer here but separates into three bands: (1) *tenia libera*, a free band which stretches on the anterior

surface of the caecum and ascending colon; on the transverse colon it runs on the posterior surface because the colon here turns about its axis; on the descending colon it returns to the anterior surface; (2) *tenia mesocolica* stretches along the line of attachment of the mesentery of the transverse colon, hence its name; (3) *tenia omentalis* runs along the line of attachment of the greater omentum on the transverse colon and along the continuation of this line on the other parts of the colon.

*Haustra coli* are seen from the inside as sacculations; from the outside they appear as protrusions between the bands. They promote the treatment of undigested food remnants. Haustra disappear if the teniae are removed because they are produced by the adaptation of the length of the teniae to the somewhat (by one sixth) longer length of the colon itself.

*Appendices epiploicae* are protrusions of the serous coat 4-5 cm in length found along the teniae libera and omentalis; in subjects who are not undernourished they contain fatty tissue.

*Haustra coli*, *teniae coli*, and *appendices epiploicae* serve as guiding points for distinguishing the large intestine from the small intestine during operation.

Since the process of absorption is diminished in the large intestine (water is absorbed for the most part), its *mucous membrane* is devoid of villi and is, therefore, distinguished from the mucosa of the small intestine by a smooth surface. The circular folds in the large intestine are broken up to form separate crescent folds called the semilunar folds of the colon (*plicae semilunares coli*). They are formed not only by the mucous coat but also by all the other coats of the wall. The semilunar folds are functional adjustments dependent on the activity of the intestinal nervous and muscular systems. Only intestinal glands and solitary follicles but no Peyer's patches are present in the mucous membrane.

The *muscle coat* is composed of two layers, an outer longitudinal and an inner circular layer. Only the inner circular layer is continuous; it is a constricting layer, which thickens when the hard faecal material has to be pushed distally. In contrast, the dilating longitudinal musculature (continuous in the small intestine) in the large intestine separates to form the three teniae described above because the pressure of the faecal material itself makes dilation of the lumen easier.

The *serous coat* covers some parts of the large intestine completely and others partly (see below).

**Caecum** (Gk *typhlon*, hence typhlitis, inflammation of the caecum) (Fig. 211) is the first segment of the large intestine from its origin to its junction with the small intestine. The caecum has the appearance of a sac with a vertical dimension of about 6 cm and a transverse dimension of 7.0-7.5 cm. It lies in the right iliac fossa directly above the lateral half of the inguinal ligament; sometimes it takes a higher position and may even be situated under the liver (persistence of the embryonic position). The anterior surface of the caecum adjoins directly the anterior abdominal wall or is separated from it by the greater omentum; the iliopsoas muscle is behind the caecum. The *vermiform process* (*appendix vermiformis*) arises from

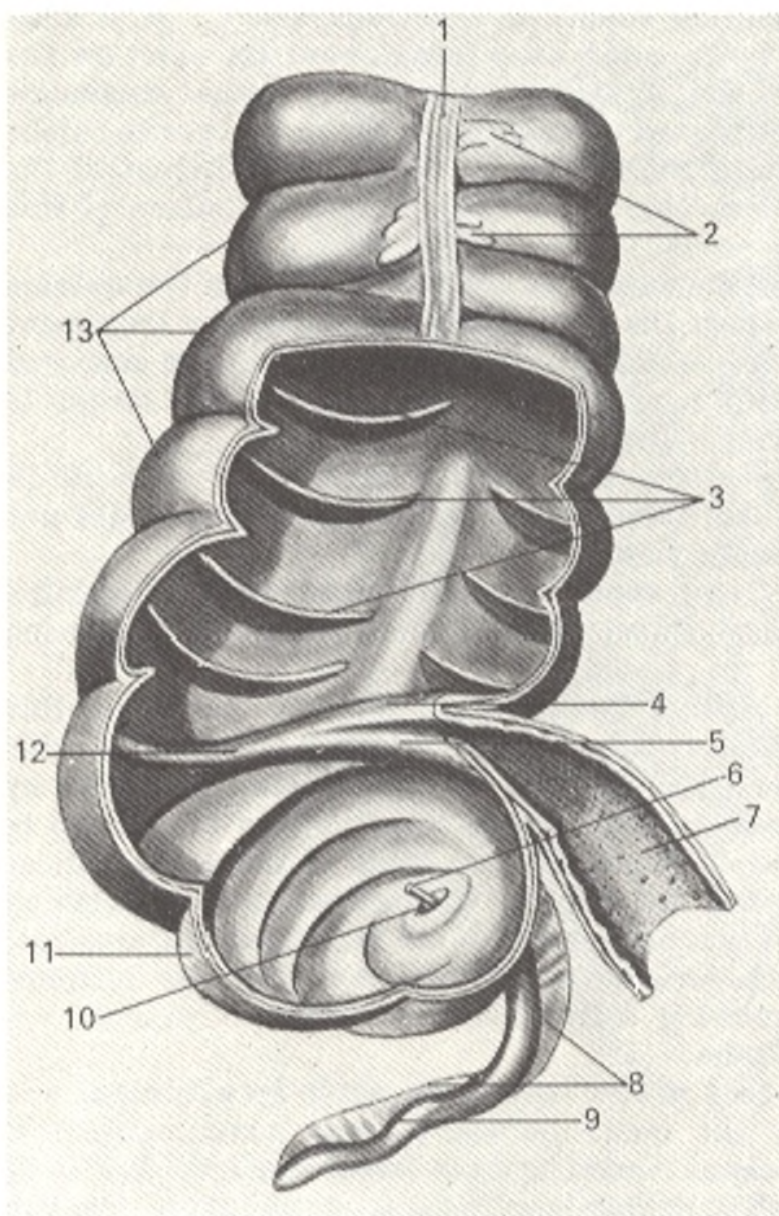


Fig. 211. Caecum, vermiform process, and ascending colon, anterior aspect (part of the wall is removed, after Sinelnikov).

- 1, tenia libera;
- 2, appendices epiploicae;
- 3, plicae semilunares coli;
- 4 and 5, labium superius and labium inferius, valvae ileocecalis;
- 6, catheter introduced into the lumen of the vermiform process;
- 7, intestinum ileum;
- 8, mesenteriolum appendicis vermiformis;
- 9, appendix vermiformis;
- 10, valvula processus vermiformis;
- 11, caecum;
- 12, frenulum valvae ileocecalis;
- 13, haustra coli

the medioposterior surface of the caecum, 2.5-3.5 cm below the iliocaecal junction. It varies greatly in length and position; its length is about 8.6 cm on the average, but in 2 per cent of cases it may be reduced to 3 cm. The vermiform process may be absent completely, but this is a rare occurrence. As to the position of the process, it is first of all closely associated with the position of the caecum. Just as the caecum, it lies, as a rule, in the right iliac fossa, but may also be located at a higher level with a higher position of the caecum or it may be found lower, in the true pelvis, with a low position of the caecum.

With a normally located caecum, the following four variants in the position of the vermiform process can be distinguished.

1. Descending position (most common, in 40-45 per cent of cases). The end of a long process descends into the true pelvis and in cases of inflammation it fuses with the urinary bladder and rectum.

2. Lateral position (approximately 25 per cent of cases).
3. Medial position (17-20 per cent of cases).
4. Ascending position behind the caecum (about 13 per cent of cases).

In all the diverse variants in the position of the process, its central part, i.e. the site of its origin from the caecum, remains constant. In appendicitis, the point of tenderness is projected on the surface of the abdomen at the junction of the lateral and middle third of a line connecting the umbilicus with the right anterior superior iliac spine (McBurney's point), or, to be more precise, at the junction of the right and middle third of a line connecting both anterior superior spines (Lanz's line).

The lumen of the vermiform process of elderly individuals may obturate partly or completely. The process opens into the caecum by the *ostium appendicis vermiformis*. The vermiform process forms as the result of the differentiation of the caecum into two parts, the caecum proper and the narrow part, the process. This differentiation exists in man and in the anthropoid apes (the end of the caecum in rodents also resembles the vermiform process in structure). The mucous membrane of the vermiform process is relatively rich in lymphoid tissue in the form of *folliculi lymphatici aggregati appendicis vermiformis*; some authors relate this to its functional importance (the "intestinal tonsil" that retains and destroys pathogenic micro-organisms, which explains the high appendicitis incidence). The walls of the process consist of the same coats as those of the intestinal wall.

The caecum and vermiform process are completely invested by the peritoneum. The mesentery of the vermiform process, *mesoappendix*, usually extends to its very end. In approximately 6 per cent of cases, the posterior surface of the caecum is not covered with the peritoneum and in such instances the intestine is separated from the posterior abdominal wall simply by a layer of connective tissue.

At the junction of the small and large intestines is the *ileocaecal valve* (*valva ileocecalis*). It is composed of two crescent folds at the base of which is a layer of circular muscles, the *ileocaecal sphincter* (*sphincter ileocecalis*). The ileocaecal valve and sphincter together form an adjustment regulating the passage of food from the small intestine, in which the reaction is alkaline, into the large intestine, where the medium is again acid; they also prevent the backward flow of the contents and the neutralization of the chemical medium (Fig. 212). The surface of the ileocaecal valve facing the small intestine is covered with villi, whereas the other surface has the features of the mucous membrane of the large intestine and bears no villi.

The **ascending colon** (*colon ascendens*) (see Fig. 210) is a direct continuation of the caecum and the boundary between them is the site where the small intestine empties into the colon (the ileocaecal valve in the lumen). From this junction it passes upward and slightly to the back and, on reaching the inferior surface of the liver, makes a bend to the left and forward to form the right, or hepatic flexure of the colon (*flexura coli dextra*, s. *flexura hepatica coli*) and is then continuous with the transverse colon. The posterior surface of the ascending colon, usually not covered with the peritoneum here, adjoins the iliac and quadratus lumborum muscles, while a little

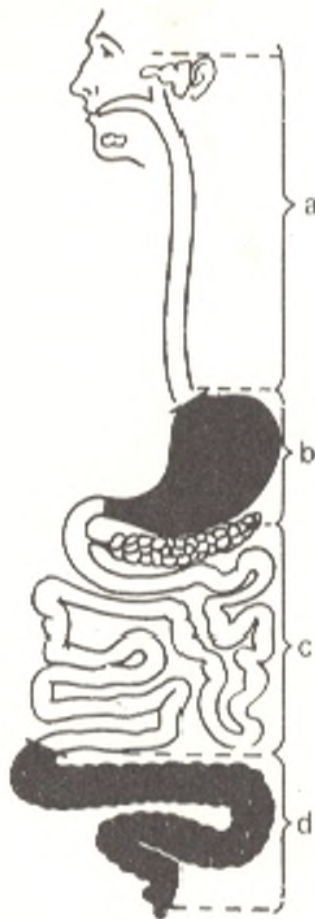


Fig. 212. Portion of the digestive tract in the region of the action of the saliva (alkaline reaction, *a*), gastric juice (acid reaction, *b*), intestinal juice (alkaline reaction, *c*), and the content of the large intestine (acid reaction, *d*)

higher it is in contact with the lower part of the right kidney; in front, the ascending colon is often separated from the anterior abdominal wall by the loops of the small intestine.

The **transverse colon** (*colon transversum*), the longest part of the colon (its length ranges from 25 to 30 cm, while that of the ascending part is about 12 cm and of the descending part approximately 10 cm), extends from the right flexure to the left flexure of the colon at the lower end of the spleen, where it is continuous with the descending colon. Between the two bends the transverse colon does not stretch strictly transversely but forms a shallow concave arch shifted slightly to the front; the left flexure is found at a higher level than the right flexure. The transverse colon is covered in front for a great length by the greater omentum, above it adjoins the liver, gall bladder, stomach, the tail of the pancreas, and the lower end of the spleen. Posteriorly, the transverse colon transects the descending part of the duodenum and the head of the pancreas and is attached to the posterior abdominal wall and the anterior border of the pancreas by means of its *mesentery* (*mesocolon transversum*). The great variability in the position of the transverse colon must be pointed out; though it often transects the median plane at the level of the umbilicus, this point of transection may be as high as the xyphoid process or at some distance below the umbilicus.

The **descending colon** (*colon descendens*) passes downward in the left side of the abdominal cavity from the left flexure of the colon in the left



hypochondrium and on the level of the iliac crest is continuous with the sigmoid (pelvic) colon. It is usually covered in front by the loops of the small intestine, which press it back to the posterior abdominal wall; its posterior surface comes in touch with the diaphragm and lower with the quadratus lumborum muscle where it also adjoins the lateral border of the left kidney.

The sigmoid (pelvic) colon (*colon sigmoideum*) is a continuation of the descending colon and stretches to the beginning of the rectum. The shape and size of its loop is marked by considerable individual variations, depending on its length and the degree of filling. An empty sigmoid (pelvic) colon of average size is usually located for the most part in the cavity of the true pelvis and reaches the right wall of this cavity; here it curves, descends to the left, and is then continuous with the rectum. When the urinary bladder of the sigmoid itself is full, it easily changes this position and lies above the pubic symphysis. In front, the sigmoid colon is covered by the loops of the small intestine.

The relations of the parts of the colon to the peritoneum are as follows: the ascending colon in most cases is covered by the peritoneum in front and on the sides, while its posterior surface is devoid of a serous coat; less frequently the ascending colon has a short mesentery (in about 35 per cent of cases). The transverse colon is completely invested by the peritoneum and has a long mesentery as a consequence of which it possesses considerable mobility. The relations of the descending colon to the peritoneum are approximately the same as those of the ascending colon; a mesentery is encountered less often (in about 25 per cent of cases). The sigmoid colon is covered by the peritoneum on all sides and has a well developed mesentery and is, therefore, easily mobile and forms an S-shaped curve, hence its name.

The projection of the parts of the colon on the anterior abdominal wall is as follows: the ascending colon is projected in the right lateral abdominal region, the transverse colon in the umbilical region, the descending colon in the left lateral abdominal region, and the sigmoid colon is projected in the left inguinal region. The distal part of the sigmoid colon which is continuous with the rectum is projected in the pubic region.

The rectum (Figs. 213 and 214) is the last part of the large intestine and serves for the accumulation and evacuation of the faecal material. It begins at the level of the promontory and descends into the true pelvis in front of the sacrum to form two anteroposterior flexures: an upper *sacral flexure* (*flexura sacralis*) convex to the back in conformity with the sacral concavity and a lower *perineal flexure* (*flexura perinealis*) convex to the front in the region of the coccyx. As a result the rectum is S-shaped, wide in the middle and narrow at the ends. The upper part of the rectum corresponding to the sacral flexure is in the pelvic cavity and is called the *pelvic part* (*pars pelvina*): it widens in the direction of the perineal flexure to form the *rectal ampulla* (*ampulla recti*) whose diameter ranges from 8 to 16 cm but may increase to 30-40 cm when rectum is overfilled or atonic. The terminal part of the rectum passing to the back and downward is called the *anal part of the rectum*, or the *anal canal* (*pars analis recti* s. *canalis analis*) because, on

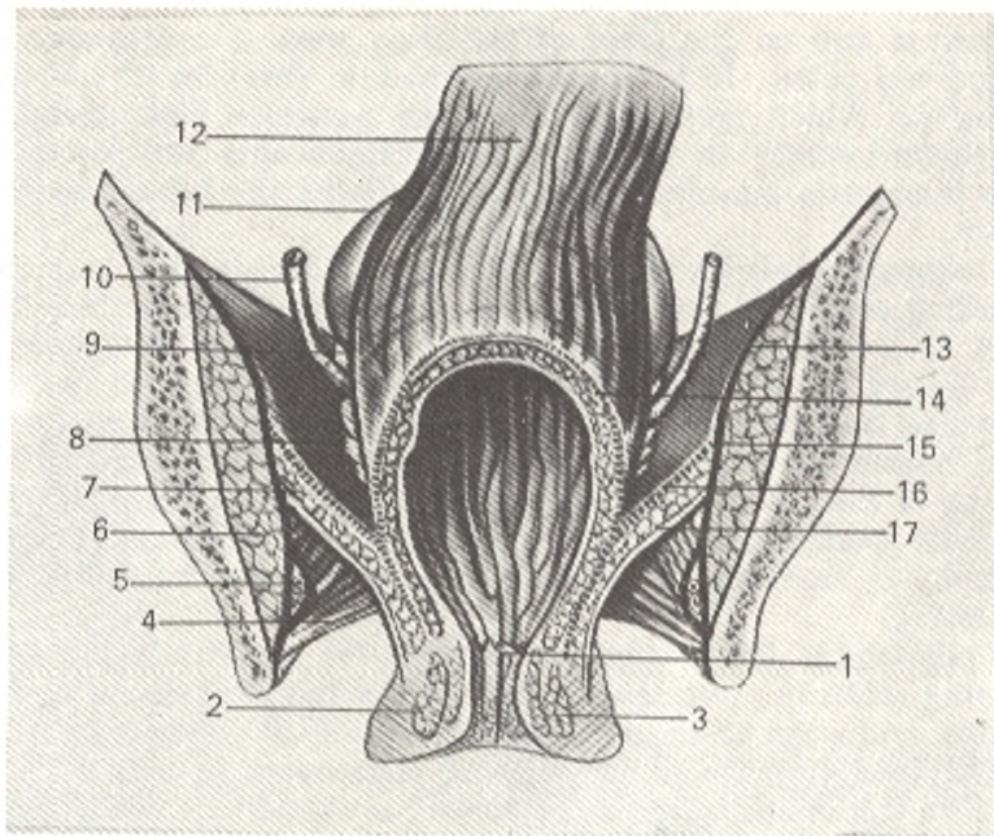


Fig. 213. Frontal section through the male pelvis, posterior aspect.

- |  |   |
|--|---|
| 1, anus;                                       | 9, ampulla ductus deferentis;             |
| 2, m. sphincter ani externus;                  | 10, ureter;                               |
| 3, m. sphincter ani internus;                  | 11, vesica urinaria;                      |
| 4, fascia diaphragmatis urogenitalis superior; | 12, pars ampullaris recti;                |
| 5, a., v., n. pudendales;                      | 13 and 15, fascia m. obturatorii interni; |
| 6, m. obturatorius internus;                   | 14, fascia pelvis visceralis;             |
| 7, m. levator ani;                             | 16, fascia diaphragmatis pelvis superior; |
| 8, vesica seminalis;                           | 17, fascia diaphragmatis pelvis inferior  |

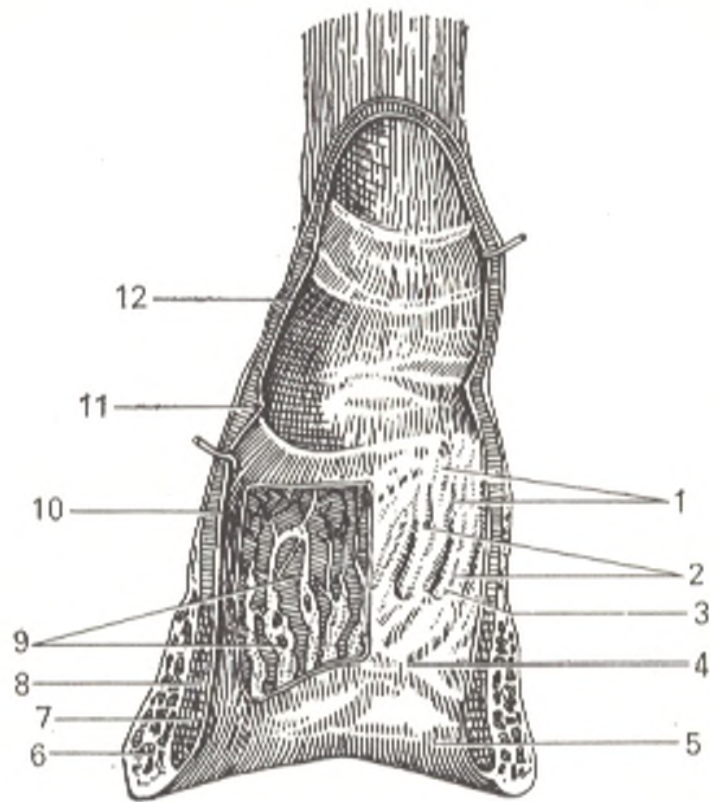
passing through the pelvic floor, it terminates as an orifice, the *anus* (the Greek name for the anus is *proktos*, hence *proctitis*, inflammation of the rectum). The circumference of this portion is more stable and measures 5-9 cm. The length of the rectum ranges from 13 to 16 cm, the pelvic part accounting for 10-13 cm and the anal part for 2.5-3.0 cm.

Different shapes of the rectum are encountered: (1) ampullar, with a manifest ampulla; (2) cylindric, with the ampulla not manifest, and (3) an intermediate shape. Three parts are distinguished in the rectum according to its peritoneal relations: an upper part, which is covered with the peritoneum intraperitoneally and has a short mesentery, *mesorectum*; a middle part situated mesoperitoneally; and a lower part found extraperitoneally.

The previously accepted division of the rectum into the peritoneal and subperitoneal parts was of definite importance. With the development of surgery of the rectum it is now more suitable to distinguish five parts in it: supra-ampullar (or rectosigmoid), superampullar, midampullar, inferoampullar, and perineal.

Fig. 214. Rectum, opened in front.

- 1, folliculi lymphatici;
- 2, columnae anales;
- 3, sinus analis;
- 4, zona hemorrhoidalis;
- 5, cutis;
- 6, m. sphincter ani externus;
- 7, m. sphincter ani internus;
- 8, tunica muscularis (stratum longitudinale);
- 9, plexus hemorrhoidalis;
- 10, tunica muscularis (stratum circulare);
- 11, plica transversalis recti;
- 12, tunica mucosa



The rectal wall is composed of three coats: mucous, submucous, and muscular. Due to a developed layer of submucosa, the *mucous coat* (*tunica mucosa*) gathers to form numerous longitudinal folds when the rectum is empty; these folds are easily smoothed out when the rectal walls are stretched. Only the most distal part of the rectum has eight to ten permanent longitudinal folds known as the *anal columns* (*columnae anales*). The depressions between them are called *anal sinuses* (*sinus anales*), which are particularly manifest in children. Mucus accumulating in the anal sinuses makes easier the passage of faeces through the narrow anal canal.

From the clinical standpoint, the anal sinuses, or the anal crypts, as they are called by clinicians, are of exceptional importance because they are the most common site of entry of pathogenic micro-organisms.

The circular space between the anal sinuses and the anus is called the *haemorrhoidal zone* (*zona hemorrhoidalis*), in its thickness is the venous haemorrhoidal plexus (*plexus hemorrhoidalis*, BNA). Painful dilatation of this plexus is known as haemorrhoids; it causes copious haemorrhage (*haemorrhoea*); hence the name of this region.

In addition to the longitudinal folds, transverse mucosal folds, *horizontal folds of the rectum* (*plicae transversales recti*) are present in the upper parts of the rectum, which are similar to the semilunar folds of the sigmoid colon. They differ from the latter, however, by their small number (3-7) and a spiral shape facilitating the forward movement of the faeces. The submucous layer, *tela submucosa*, is very well developed, which is conducive to the prolapse of the mucous membrane through the anus.

The *muscular coat* (*tunica muscularis*) consists of two layers; an inner circular and an outer longitudinal. The inner layer increases in thickness in the upper part of the perineal part to 5-6 cm and forms here the inner sphincter, the *sphincter ani internus muscle* (*m. sphincter ani internus*) 2-3 cm in height and terminating at the junction of the anal canal with the skin. (Directly under the skin is a ring of striated muscle fibres, the *sphincter ani externus muscle* [*m. sphincter ani externus*] which is among the muscles of the perineum.) The longitudinal muscle layer is not grouped into teniae as is the case in the colon, but is regularly distributed in the anterior and posterior walls of the rectum. Below, in the perineal part of the rectum, the longitudinal fibres intertwine with the fibres of the levator ani muscle (a muscle of the perineum) and partly with the sphincter ani externus muscle.

From the above described it is obvious that the last segment of the intestine, the rectum, acquires the features of a conducting part of the alimentary canal, like the initial segment, the oesophagus. In these two segments of the alimentary canal the mucous membrane forms longitudinal folds, the musculature is arranged in two continuous layers (an internal circular, constricting, and an external longitudinal, dilating); in the direction of the opening into the exterior the smooth muscle fibres are supplemented with striated fibres. There are also similar developmental features: rupture of both blind ends of the primary gut occurs during embryogenesis; the pharyngeal membrane ruptures in the formation of the oesophagus and the cloacal membrane in the formation of the rectum. The similarity in the development and function (conduction of the contents) of the oesophagus and rectum also determine, therefore, the certain similarity of their structure.

**Topography of the rectum.** Behind the rectum are the sacrum and coccyx; the anterior surface of the male rectum adjoins the seminal vesicles and the deferent ducts (vas deferens) where it is devoid of the peritoneum, the uncovered area of the urinary bladder between these organs, and still lower, the prostata. In females the rectum borders in front upon the uterus and the posterior wall of the vagina for its entire length and is separated from the vagina by a layer of connective tissue, the rectovaginal septum (septum rectovaginale). There are no strong fascial bands between the rectal fascia proper and the anterior surface of the sacrum and coccyx, which makes it easier to separate and remove during operation the rectum together with its fascia investing the blood and lymphatic vessels.

**The large intestine of a live person.** X-ray examination of the large intestine (Fig. 215) demonstrates that in strong contraction of the longitudinal muscles of any of its parts the length of this part decreases while the haustrae coli are clearly outlined so that its general pattern resembles a string of figs. In relaxation of the musculature and overfilling of the intestinal lumen with the contrast medium, the haustrae coli are smoothed out and disappear temporarily in this or that area, which is a characteristic sign of the large intestine.

The position of the large intestine is at a lower level in a live subject than in a cadaver. The transverse colon is never convex cranially, as it is sometimes encountered on postmortem examination of a supine cadaver. The transverse colon is usually situated transversely and obliquely and sags like a "garland" to the level of the iliac bones and forms a concave arch. The position of the vermiform process of the caecum also varies. If the point




Fig. 215. Radiograph of the large intestine. The silhouette of the large intestine filled with contrast medium is demonstrated

of origin of the process from the caecum is taken as the centre of a circle, then the process may lie on any radius, but most frequently it descends medially.

The variability of the position of the vermiform process in one and the same individual, i.e. its mobility caused by peristalsis and pressure exerted by the neighbouring organs, is a characteristic sign of a normal condition; an inflamed process is held fast by adhesions in one position.

Physiological constrictions are found at the junction of the parts of the large intestine, namely at the origin of the vermiform process (sphincter *appendicis vermiformis*) at the junction of the caecum and ascending colon, at the right flexure of the colon, in the region of the left flexure, at the junction of the descending and sigmoid colons, and at the junction of the sigmoid colon and rectum. Sphincters are described in these places; their location and terminology are shown in Fig. 216 (after Balli).

Due to the motor function, absent in a cadaver, the intestine of a live person is distinguished from that of a cadaver by the following features.

1. Due to contraction of the longitudinal musculature, the intestine of a live person is much shorter than the intestine of a cadaver, in which this musculature is relaxed; the length of the small intestine in a live subject does not exceed 2.7 m, while the length of the whole intestine is 5 m.

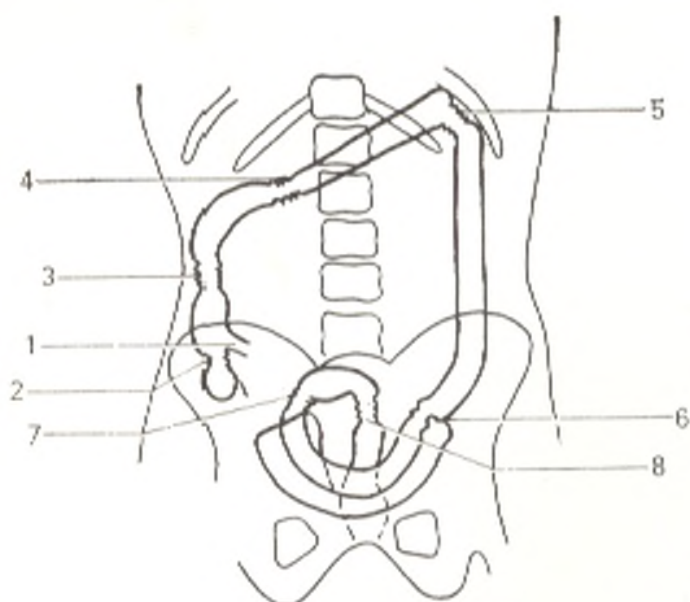


Fig. 216. Schematic representation of the location of sphincters of the large intestine (after Balli).

- 1, sphincter ileocecalis (Varolius);
- 2, sphincter cecocolicus (Busi);
- 3, Hirsch's sphincter;
- 4, Cannon's sphincter;
- 5, Payr's sphincter;
- 6, Balli's sphincter (colon sigmoideum);
- 7, Mutier's and Rossi's accessory sphincter;
- 8, Mutier's sphincter

2. The shape of some of the parts of the large intestine (in the absence of haustral segmentation) differs from the typical picture.

3. The large intestine (in marked "sagging" of the transverse colon) is at a lower level than the intestine of a cadaver.

4. In addition to the permanent anatomical folds, circular (in the small intestine) and semilunar (in the large intestine), physiological folds are encountered in a live subject: transverse, longitudinal, and oblique, and also physiological sphincters. Cases with duplicated rectum have been described. In *rectoromanoscopy* (i.e. inspection of the rectum and sigmoid colon of a live subject with a special instrument, the rectoromanoscope), the mucous membrane of the rectum and sigmoid colon is seen to be uniformly pink. The transverse and longitudinal folds and the sinuses of the rectum are clearly demonstrated.

The *arteries* of the large intestine are branches of the superior and inferior mesenteric arteries. Besides these, branches (medial and inferior rectal arteries) pass to the middle and inferior segments of the rectum from the internal iliac artery. The inferior rectal artery is a branch of the internal pudendal artery. The distribution of the *veins* in the large intestine differs with the different parts according to the structure, function, and development of the intestinal wall. They drain by way of the superior and inferior mesenteric veins into the portal vein. Venous blood from the middle and inferior parts of the rectum flows into the internal iliac vein (into the system of the inferior vena cava).

The *lymphatic vessels* of the large intestine drain into lymph nodes arranged along the arteries supplying it. These nodes, 20 to 50 in number, are separated into three groups according to their relation to the different parts of the large intestine.

1. Nodes of the caecum and vermiform process, the ileocolic lymph nodes (*nodi lymphatici ileocolici*).

2. Nodes of the colon, the right, middle and left colic lymph nodes (*nodi lymphatici colici dextri, medii et sinistri*) and the inferior mesenteric lymph nodes (*nodi lymphatici mesenterici inferiores*).

It has been found that vessels draining lymph from the transverse colon pass to nine groups of lymph nodes situated on the wall and in the mesentery of the intestine, in the gastrocolic ligament, in the greater omentum, and in the region of the stomach, pancreas and spleen.

3. Nodes of the rectum arranged in a chain in attendance to the superior rectal artery, the internal iliac lymph nodes (*nodi lymphatici iliaci interni*). Lymph from the skin of the anus is drained into the inguinal lymph nodes.

All parts of the large intestine receive *innervation* from the sympathetic (the superior and inferior mesenteric and the superior, middle, and inferior rectal plexuses) and parasympathetic (the vagus nerve and, for the sigmoid colon and rectum, the pelvic splanchnic nerves) systems. Because it has in its walls both smooth and striated (*sphincter ani externus* muscle) musculature, the rectum is innervated not only by vegetative nerves but also by an animal nerve, the pudendal nerve (anal part). This explains the low sensitivity of the rectal ampulla and the high sensitivity of the anal orifice.

## REGULAR FEATURES OF THE INTESTINAL STRUCTURE

1. The laws of intestinal peristalsis are explained by the structure of the intestinal wall. The intestine can be represented schematically as two tubes, one inserted into the other, as a gun tube constructed with due consideration for the strongest pressure produced in it. One tube (outer) consists of the serous and muscle coats, whereas the other (inner) is formed of the mucous coat and its lamina muscularis. Both tubes can slide one in relation

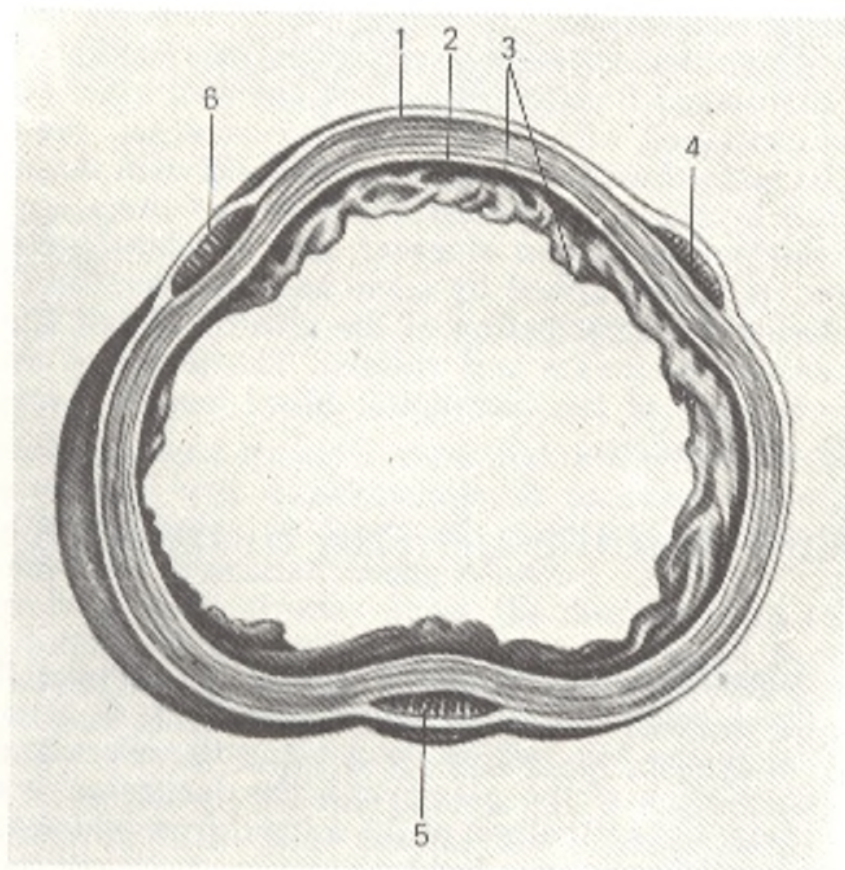


Fig. 217. Transverse section through the large intestine (after Kiss and Szentagóthai).

1, tunica serosa;  
2, tunical muscularis;  
3, tunica mucosa;  
4, 5, and 6, longitudinal layer of musculature in the form of three mus-

cular bands:  
tenia omentalis (4),  
tenia mesocolica (5),  
tenia libera (6)

to the other due to the presence of the submucous layer of connective tissue containing the main mass of the vessels and making movement easier. The connective-tissue fibres of the submucosa and of all the other coats pass spirally in the oral-caudal direction with which coincide the course of the muscle fibres of lamina muscularis and the direction of the spiral layer of the muscle coat. The tube experiences pressure from inside under the effect of the intestinal contents; the inner tube in such instances dilates uniformly because the bundles of connective and muscular tissues have the same direction; the outer tube dilates irregularly because the direction of its muscle layers (longitudinal and circular) differs from that of the connective-tissue fibres penetrating the muscles. Bearing in mind the spiral course of all the connective-tissue and some of the muscular fibres (the spiral layer of the muscular coat and the muscularis mucosae), the predominance of the spiral construction of the wall of the small intestine must be recognized. The spiral construction determines the polarity of the peristalsis of the small intestine from the oral to the anal pole and under normal conditions prevents antiperistalsis. The large intestine has circular musculature as the result of the marked predominance of the circular musculature (Fig. 217). Besides peristaltic movements, antiperistaltic movements occur, therefore, in the large intestine, which promote mixing and formation of the contents.

2. Both anatomical layers of the intestinal wall differ in function: the mucous coat is concerned with absorption and secretion, the muscular coat accomplishes the motor function. The correlation between these two functions change along the length of the intestinal tube and there are consequently areas with the predominance now of motor, now of other functions. In accordance with this, as it is claimed by some authors, there is the *alternation of segments* differing in the structure of the intestinal wall (its mucous and muscle coats, as well as nerves and vessels). The principal evidence of the alternation are changes of the intramural blood vessels, because these are associated with metabolism.

## THE LARGE GLANDS OF THE DIGESTIVE SYSTEM

### THE LIVER

The liver (*hepar*) is a large glandular organ (Figs. 218 and 219) weighing about 1500 g. The *functions* of the liver are diverse. It is primarily a large digestive gland secreting bile, which flows along the efferent duct into the duodenum. (This relation of the gland with the duodenum is explained by its development from the epithelium of the midgut from which the duodenum is also derived.) It accomplishes a barrier function: toxic products of protein metabolism brought to the liver in the blood are neutralized in it; moreover, the endothelium of the hepatic capillaries and the Kupffer cells possess phagocytic properties (the reticuloendothelial system), which is important for rendering harmless substances absorbed in the intestine. The liver takes part in all types of metabolism: in particular, carbohydrates absorbed by the intestinal mucosa are converted in the liver to glycogen (glycogen "de-



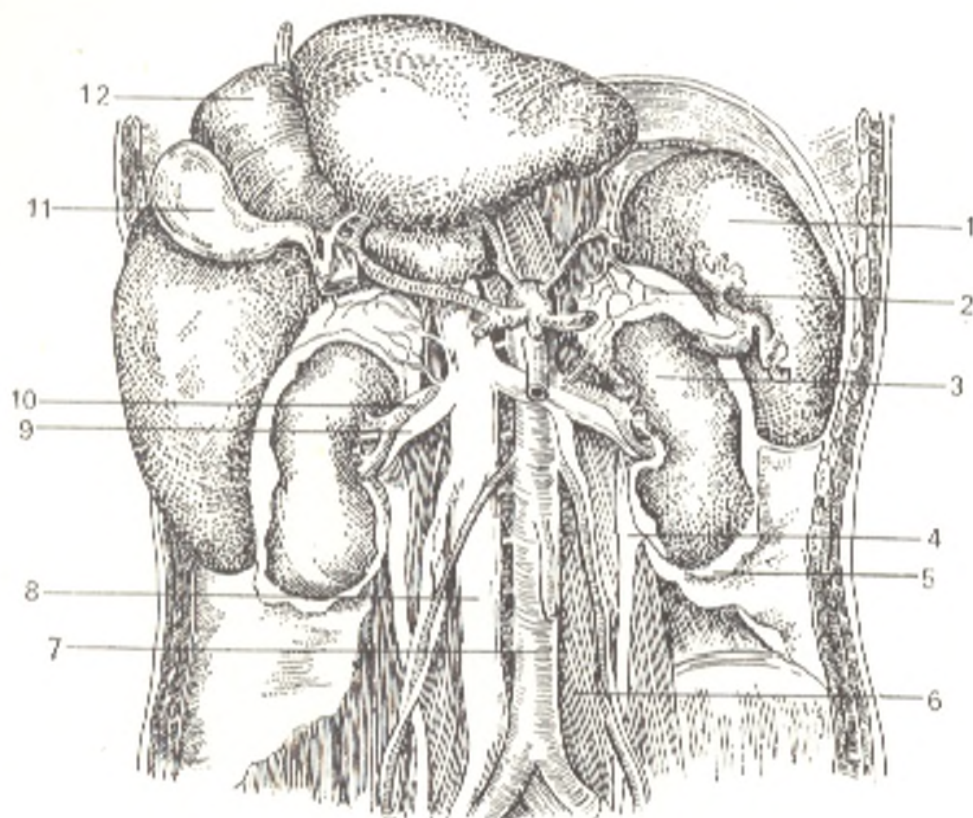


Fig. 218. The liver, spleen, and kidneys.

- |                               |                        |
|-------------------------------|------------------------|
| 1, spleen;                    | 7, aorta;              |
| 2, adrenal gland;             | 8, vena cava inferior; |
| 3, kidney;                    | 9, v. renalis;         |
| 4, ureter;                    | 10, a. renalis;        |
| 5, fibrous capsule of kidney; | 11, gall bladder;      |
| 6, m. psoas major;            | 12, liver              |

pot"). Hormonal functions are also attributed to the liver. In the embryonal period it is concerned with haemopoiesis, it produces the red blood cells. The liver is thus an organ of digestion, circulation of the blood, and all types of metabolism, hormonal among others.

The liver is situated directly under the diaphragm in the right upper part of the abdominal cavity and only a relatively small portion of it protrudes to the left of the midline in an adult. In the newborn the liver occupies the greater part of the abdominal cavity and accounts for one twentieth of the total body weight; in an adult this ratio reduces to approximately one fiftieth. Two surfaces and two borders are distinguished in the liver. The **upper surface**, or to be more precise, the anterosuperior surface (*facies diaphragmatica*) is convex in correspondence to the concavity of the diaphragm with which it is in contact. The **lower surface** (*facies visceralis*) faces downward and to the back and bears some depressions produced by the abdominal viscera with which it comes in contact. The upper and lower surfaces are separated by a sharp **lower border** (*margo inferior*). The other border of the liver, the superoposterior border, is in contrast so blunt that it can be regarded as the posterior surface of the organ.

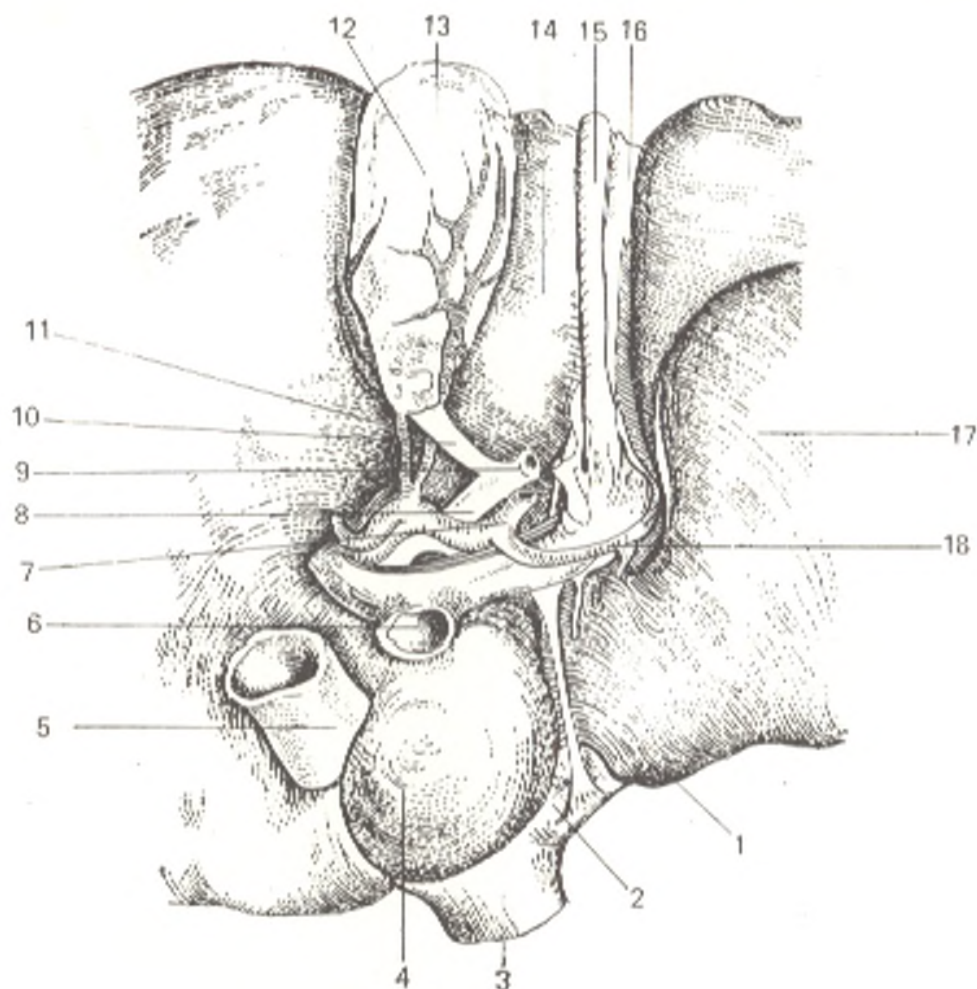


Fig. 219. Porta hepatis.

- |                               |   |
|-------------------------------|---|
| 1, lig. venosum;              | 11, a. cystica;                             |
| 2, v. hepatica sinistra;      | 12, vesica fellea;                          |
| 3 and 5, v. cava inferior;    | 13, fundus vesicae felleae;                 |
| 4, lobus caudatus;            | 14, lobus quadratus;                        |
| 6, v. portae;                 | 15, lig. teres hepatis;                     |
| 7, a. hepatica propria;       | 16, lig. falciforme hepatis;                |
| 8, ductus hepaticus communis; | 17, lobus sinister;                         |
| 9, ductus choledochus;        | 18, ramus sinister a. hepaticae<br>propriae |
| 10, ductus cysticus;          |   |

Two lobes are distinguished in the liver, the **right** (*lobus hepatis dexter*) and the **left** (*lobus hepatis sinister*) lobes, which are separated on the diaphragmatic surface by the *falciform ligament* (*ligamentum falciforme hepatis*). In the free edge of the falciform ligament is a hard fibrous cord, the *round ligament of the liver* (*ligamentum teres hepatis*) that extends from the umbilicus and is the obliterated remains of the umbilical vein. The ligamentum teres curves around the inferior border of the liver, forms a notch here (*incisura ligamenti teretis*), and then fits on the visceral surface into the left longitudinal fissure, which is the boundary between the right and left lobes of the liver on this surface. The ligamentum teres occupies the anterior part of this fissure (*sulcus venae umbilicalis*); the posterior part contains the continuation of the ligamentum teres, a thin fibrous cord of the obliterated ductus

venosus which functioned in the embryonal period; this part of the groove is known as *fossa ductus venosi* (Fig. 219).

The right hepatic lobe is separated on the visceral surface into two secondary lobes by two grooves, or depressions. One stretches parallel to the left longitudinal fissure and its anterior portion, in which the gall bladder (*vesica tellea*) is lodged, and is called the fossa for the gall bladder (*fossa vesicae felleae*); the posterior, deeper part of the groove contains the inferior vena cava and is called the groove for the vena cava (*sulcus venae cavae*). The fossa of the gall bladder and the sulcus of the vena cava are separated by a relatively narrow isthmus of hepatic tissue called the caudate process (*processus caudatus*). A deep transverse fissure connecting the posterior ends of the sulcus venae umbilicalis and fossa for the gall bladder is called the porta hepatis. Through the porta hepatis the hepatic artery, portal vein, and the attendant nerves enter the liver while the lymphatic vessels and the bile carrying common hepatic duct leave it. Part of the right lobe of the liver bounded posteriorly by the porta hepatis and laterally by grooves (the fossa of the gall bladder on the right and the sulcus of the vena cava on the left) is called the quadrate lobe (*lobus quadratus*). The area to the back of the porta hepatis and between the fossa ductus venosi (on the left) and the sulcus of the vena cava (on the right) constitutes the caudate lobe (*lobus caudatus*). On the left this lobe has a blunt papillary process (*processus papillaris*) while on the right it is continuous with the above-mentioned caudate process which bridges the right longitudinal fissure. Due to the more scrupulous study of the internal structure of the liver, the boundary between the right and left hepatic lobes has lately been considered to be formed by a plane drawn through the middle of the seat of the gall bladder, the left semicircumference of the vena cava inferior, and the middle hepatic vein. The organs, which come in contact with the liver, form impressions on its surface, which are named according to the contacting organ. The liver is covered by the peritoneum for the most part except for an area on its posterior surface where it is in direct contact with the diaphragm.

**Structure** (Fig. 220). Under the serous coat of the liver is a thin fibrous coat (*tunica fibrosa*). In the region of the porta hepatis it enters the hepatic substance together with the vessels and continues into thin layers of connective tissue surrounding the lobules of the liver (*lobuli hepatis*). The lobules in man are weakly separated from one another, but in some animals, e.g. pigs, the connective-tissue layers between the lobules are developed better.

The hepatic cells in the lobule are grouped in plates radiating from the axial part of the lobule to the periphery. The lobules are surrounded by interlobular veins (*venae interlobulares*), which are branches of the portal vein, and by interlobular arterial branches (*arteriae interlobulares*) arising from the proper hepatic artery. Between the liver cells forming the hepatic lobules pass the bile ductules, or canaliculi (*ductuli biliferi*) located between the contacting surfaces of the cells (Fig. 220). On leaving the lobule, the ductules drain into the interlobular ductules (*ductuli interlobulares*) which, according to some authors, join in each lobe of the liver to form first two and then one duct. From union of the right and left ducts forms the common

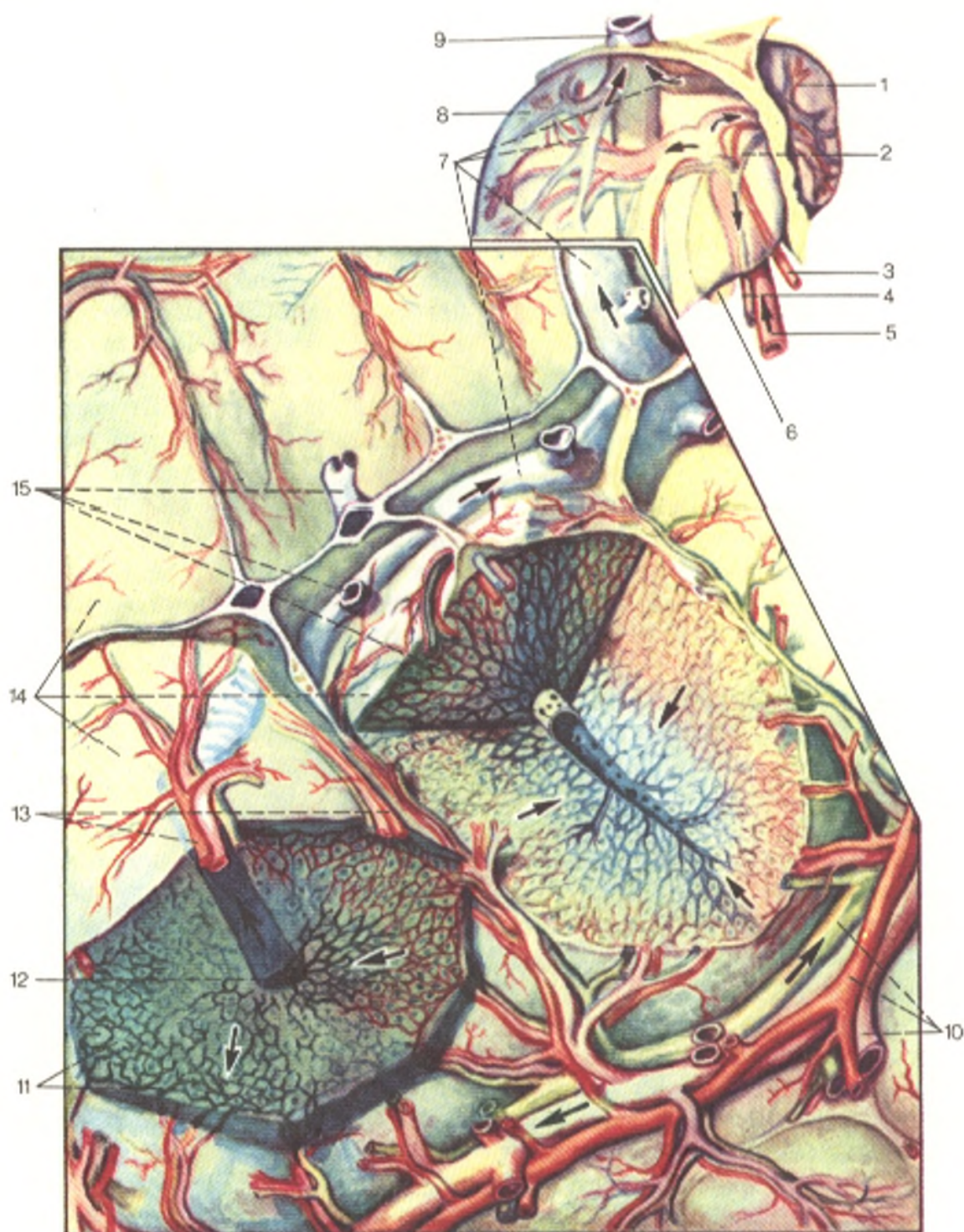


Fig. 220. Microstructure of the liver (after Sinelnikov).

1, hepar (lobus sinister);  
 2, ductus hepaticus communis;  
 3, a. hepatica propria;  
 4, ductus choledochus;  
 5, v. portae;  
 6, vesica fellea;  
 7, vv. hepaticae;  
 8, hepar (lobus dexter);  
 9, v. cava inferior;

10, interlobular blood vessels and bile ducts;  
 11, network of primary biliary canaliculi or ductules;  
 12, v. centralis;  
 13, aa. interlobulares;  
 14, lobuli hepatis;  
 15, vv. centrales

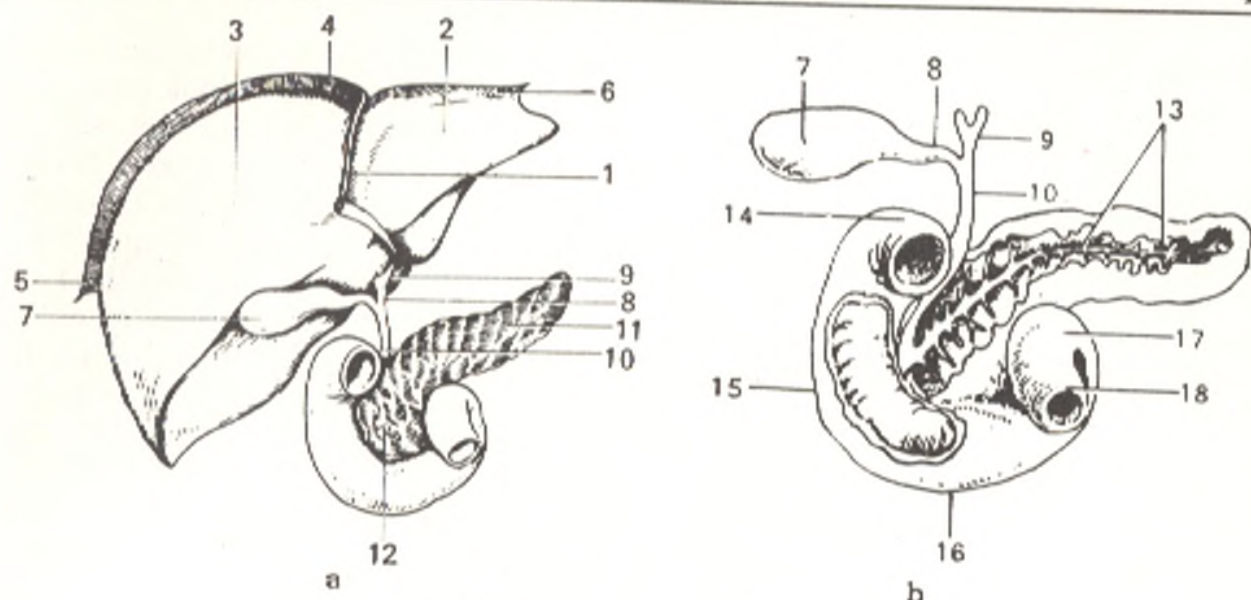


Fig. 221. Bile excretion paths.

a, liver, gall bladder, pancreas, and duodenum;  
 b, the liver is removed and the duodenum and pancreas opened;  
 1, lig. falciforme hepatis;  
 2, lobus sinister hepatis;  
 3, lobus dexter hepatis;  
 4, 5, and 6, lig. coronarium hepatis;  
 7, vesica fellea;  
 8, ductus cysticus;  
 9, ductus hepaticus communis;

10, ductus choledochus;  
 11, corpus pancreatis;  
 12, caput pancreatis;  
 13, ductus pancreaticus (the gland is opened);  
 14, pars superior duodeni;  
 15, pars descendens duodeni;  
 16, pars horizontalis (inferior) duodeni;  
 17, pars ascendens duodeni;  
 18, beginning of jejunum

**hepatic duct** (*ductus hepaticus communis*) carrying bile (*L fel s. bilis*) from the liver, which it leaves through the porta hepatis. The common hepatic duct is usually formed from two ducts, though sometimes from three, four and even five ducts. Cases have been described in which the intrahepatic ducts and the common hepatic duct were absent. The wall of the intralobular capillaries contains, in addition to endothelial cells, stellate cells (called Kupffer's cells) that possess phagocytic properties.

The hepatic tissue is marked by relative fragility; in injuries the liver is often damaged when the other organs remain intact.

The **gall bladder** (*vesica fellea s. biliaris*, or *cystic fellea*<sup>1</sup>) (Figs. 219 and 221) is pear-shaped. Its wide end extending slightly beyond the inferior border of the liver is called the **fundus** (*fundus vesicae felleae*). The opposite narrow end of the gall bladder is the **neck** (*collum vesicae felleae*); the middle part forms the **body** (*corpus vesicae felleae*). The neck is directly continuous with the **cystic duct** (*ductus cysticus*), which is about 3.5 cm in length. The cystic duct and the common hepatic duct join to form the **common bile duct** (*ductus choledochus*), the bile receptacle (*Gk dochos* receptacle). This duct is lodged between the two layers of the hepatoduodenal ligament, with the portal vein behind it and the common hepatic artery to the left of it; it then descends behind the superior part of the duodenum, pierces the medial wall of the descending part of the duodenum, and drains, together

<sup>1</sup> *Gk chole* bile, *kystis* bladder, hence cholecystitis, inflammation of the gall bladder.

with the duct of the pancreas, by means of an orifice into a dilatation inside the greater duodenal papilla, called the **ampulla of the bile duct** (*ampulla hepatopancreatica*). The circular layer of muscles in the wall of the ductus choledochus where it opens into the duodenum is very strong and forms **m. sphincter ductus choledochi**, which regulates the flow of bile into the duodenum; there is still another sphincter in the region of the ampulla, **m. sphincter ampullae hepatopancreaticae**. The ductus choledochus is about 7 cm in length. The gall bladder is covered by peritoneum only on the inferior surface; its fundus is adjacent to the anterior abdominal wall in the angle formed by the right rectus abdominis muscle and the inferior border of the ribs. The *muscular coat* (*tunica muscularis*) found under the *serous coat* consists of smooth fibres and an admixture of fibrous tissue. The *mucous coat* forms folds and contains many mucous glands. In the neck and in the cystic duct are folds arranged spirally and forming the **spiral valve** (*plica spiralis*).

**The gall bladder of a live person.** X-ray examination of the gall bladder (cholecystography) demonstrates its shadow, in which the neck, body, and fundus can be distinguished. The fundus faces caudally. The outlines of the gall bladder are clear, regular, and smooth. Depending on the amount of bile in it, the gall bladder may be pear-shaped, cylindrical, or egg-shaped. The position of the gall bladder varies between the levels of the twelfth thoracic and fifth lumbar vertebrae and is determined by the position and respiratory excursions of the liver, etc.

**Paths for bile excretion.** Since bile is produced in the liver continuously but enters the duodenum when needed, a reservoir for its storage is necessary. The gall bladder is this reservoir. Its presence determines the specific features of the structure of the bile ducts (see Fig. 221).

Bile produced in the liver flows from it in the common hepatic duct. Whenever needed, it enters the duodenum immediately along the ductus choledochus. If there is no such need, however, ductus choledochus and its sphincter remain contracted and do not allow the bile to enter the duodenum. As a result it can only be directed into the cystic duct and from there into the gall bladder, which is facilitated by the structure of the spiral valve.

As soon as food enters the stomach and the corresponding reflex is produced, the muscular wall of the gall bladder contracts while the musculature of the ductus choledochus and the sphincters relax at the same time as a result of which the bile enters the duodenum.

**Topography of the liver.** The liver is projected on the anterior abdominal wall in the epigastrium. The upper and lower boundaries of the liver projected on the anterolateral surface of the trunk join at two points: on the right and left. The upper boundary of the liver begins in the right tenth intercostal space on the midaxillary line; from there it steeply ascends to the left in line with the projection of the diaphragm (with which the liver comes in contact) and reaches the fourth intercostal space on the right mamillary line; then the boundary slopes slightly to the left, transecting the sternum somewhat above the base of the xyphoid process, and in the fifth intercostal space extends to the middle of the distance between the left sternal and

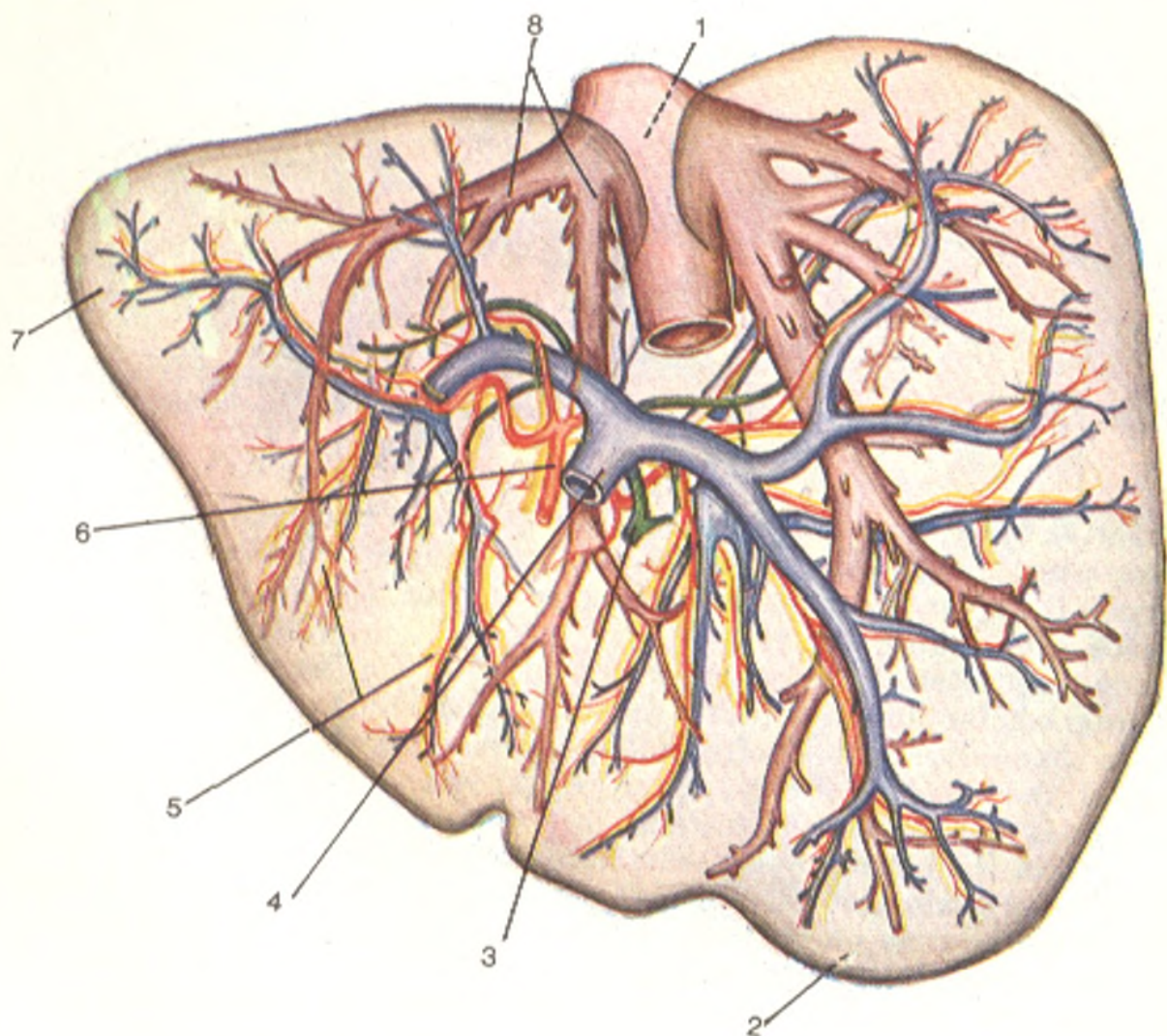


Fig. 222. Tubular systems of the liver (after Sinelnikov).

- |                               |                              |
|-------------------------------|------------------------------|
| 1, v. cava inferior;          | 5, lymphatic vessels;        |
| 2, lobus hepatis dexter;      | 6, a. hepatica;              |
| 3, ductus hepaticus communis; | 7, lobus hepaticus sinister; |
| 4, v. portae;                 | 8, vv. hepaticae             |

left mamillary lines. The lower boundary begins on the same point in the tenth intercostal space as the upper boundary, passes obliquely and to the left, transects the ninth or tenth right costal cartilage, ascends obliquely to the left in the region of the epigastrium, transects the costal arch at the level of the seventh left costal cartilage, and joins the upper boundary in the fifth intercostal space.

The liver is supplied with nutrients from the proper hepatic artery, in one fourth of cases also from the left gastric artery.

The *specific features of the vessels of the liver* are that, in addition to the arterial blood, it also receives venous blood. The proper hepatic artery and

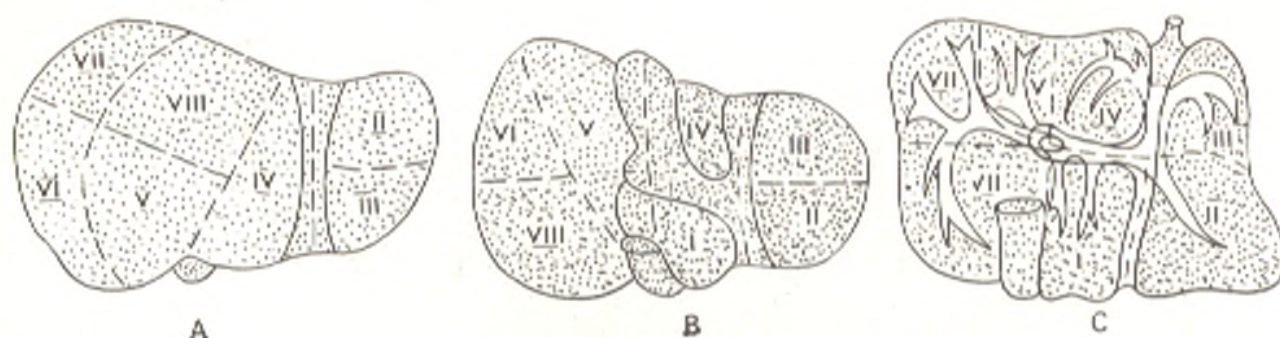


Fig. 222A. Segmental structure of the liver.

A, facies diaphragmatica hepatis; B, facies visceralis; C, segmental branches of vena portae (projection on facies visceralis). Segments of the liver are designated by Roman numerals.

the portal vein enter the substance of the liver through porta hepatica. On entering the porta, the portal vein carrying blood from the unpaired abdominal organs branches out gradually to form the finest branches lying between the lobules, the interlobular veins (vv. interlobulares). These are attended by interlobular arteries (branches of the proper hepatic artery) and interlobular ductules (ductuli interlobulares). In the substance of the lobules themselves, the arteries and veins produce capillary networks from which all the blood is collected in the central veins (vv. centrales). On leaving the lobules the central veins drain into collecting veins, which gradually fuse to form the hepatic veins. The hepatic veins have sphincters where the central veins drain into them. Three or four large and several small hepatic veins leave the liver on its lower surface and drain into the vena cava inferior. The intraorgan tubular systems of the liver are arranged in three rows: the upper and lower are occupied by systems entering the liver through the porta hepatis (the portal complex), i.e. arteries, bile ducts, and branches of the portal vein, whereas the middle row is represented by the hepatic veins. The hepatic veins carry blood from certain areas of the liver called zones. There are four such zones. There are no true lymphatic capillaries inside the lobules of the liver; they exist only in the interlobular connective tissue and drain into the plexuses of the lymphatic vessels attendant to the branches of the portal vein, hepatic artery, and bile ducts on the one side, and the roots of the hepatic veins on the other. The draining lymphatic vessels of the liver pass to the hepatic, coeliac, right gastric and pyloric lymph nodes, to the para-aortic lymph nodes in the abdominal cavity, and to the diaphragmatic and posterior mediastinal nodes in the thoracic cavity. The lymph flowing from the liver accounts for about half of the total volume of lymph in the body. Innervation of the liver is accomplished from the solar plexus through the sympathetic trunk and the vagus nerve.

**Segmental structure of the liver.** As is seen from what was stated above, the liver has five tubular systems: the bile ducts, arteries, branches of the portal vein, hepatic veins, and lymphatic vessels. Most branches of these systems stretch parallel to each other and form single vascular-secretory bundles (Fig. 222A). These bundles form the foundation of the internal topo-



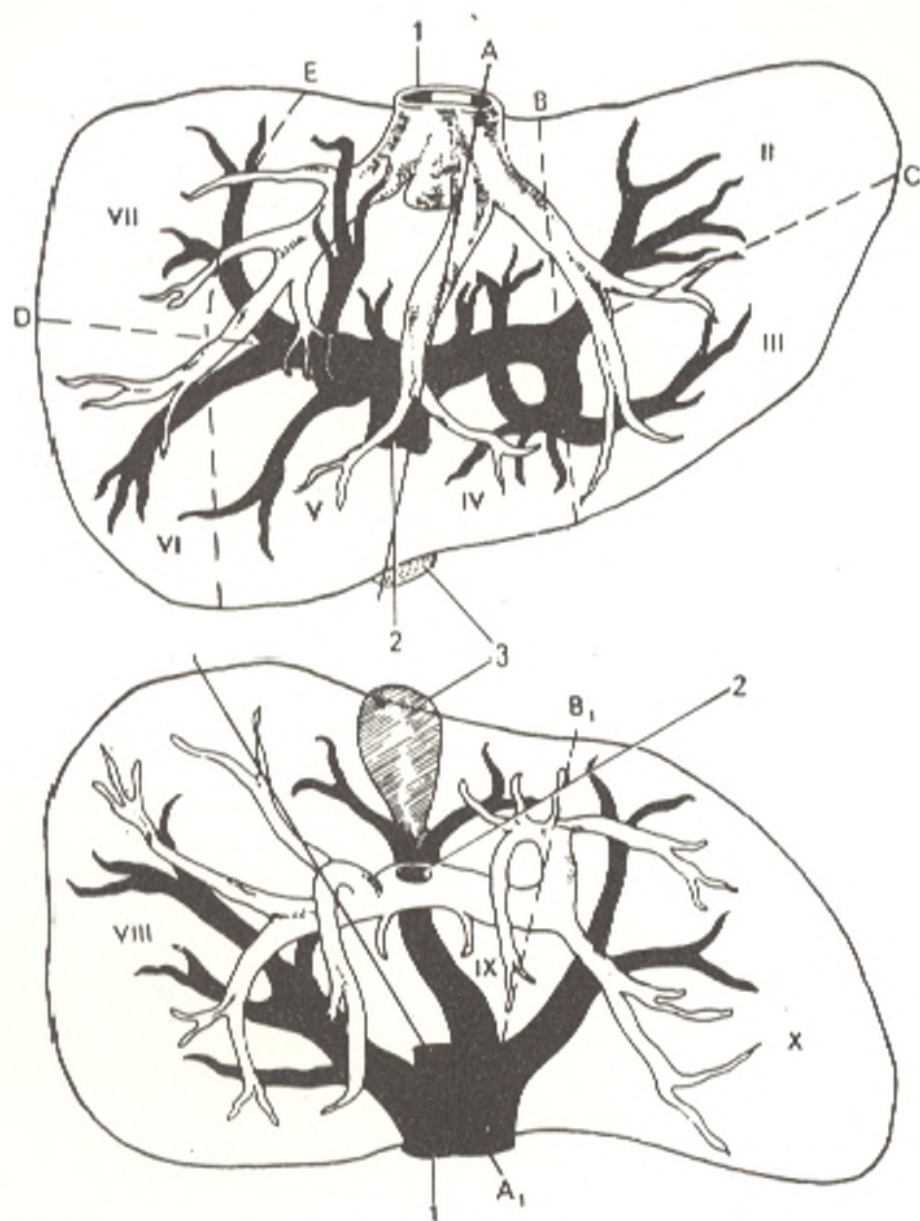

Fig. 222B. Above, segments of vena portae; below, segments of vena cava (schematic representation)

A, groove for portal vein; A<sub>1</sub>, sulcus venae cavae; B and B<sub>1</sub>, groove for umbilical vein; C, groove for portal vein; D, groove for right portal vein; E, intersegmental groove bounding portal segments VI and VII. 1, vena cava inferior; 2, vena porta; 3, gall bladder; I-VII, portal segments; IX, medial cava sector; X, left cava sector

graphy of the liver. According to the position of the vascular-secretory bundles, smaller parts of the organ, called segments, are distinguished in the liver, in addition to the lobes; these lend *segmental structure to the liver* (Fig. 222A).

A segment (a geometric but not an embryonic concept) is a part of the liver corresponding to a large branch of the portal vein and the attendant branches of the hepatic artery and bile ducts (Fig. 222B).

The number of segments varies, as a consequence of which different authors indicate their different number.

Most authors distinguish four segments; the anterior segment of the right lobe is projected on the anterior and superior parts of the diaphragmatic surface of the liver; the posterior segment corresponds to the posterior part of this surface and the whole visceral surface of the right lobe. The quadrate and caudate lobes form the medial segment, while the left lobe constitutes the lateral segment. According to certain authors, there are two lobes, five zones and seven to eight segments in the liver.

Soviet scientists Mikhailov, Kogan, and Arkhipova distinguish among the segments of the liver permanent segments, which are always encountered, and additional segments present only in some individuals; additional segments determine also a difference in the segmental structure of the liver.

The projection of the segments on the surface of the liver is characterized by marked individual variations.

## THE PANCREAS

The **pancreas** (Figs. 205 and 221) is situated behind the stomach<sup>1</sup> on the posterior abdominal wall in the epigastrium while its left part extends also to the left hypochondrium. Posteriorly it adjoins the vena cava inferior, the left renal vein, and the aorta.

The pancreas has a **head** (*caput pancreatis*) bearing the *uncinate process* (*processus uncinatus*), a **body** (*corpus pancreatis*), and a **tail** (*cauda pancreatis*). The *head* of the gland is embraced by the duodenum and is situated on the level of the first and upper part of the second lumbar vertebra. At its junction with the body is the *pancreatic notch* (*incisura pancreatis*), lodging the superior mesenteric artery and vein, and sometimes a constriction in the form of a neck. The *body* is prismatic in shape and has three surfaces, anterior, posterior, and inferior. The *anterior surface* (*facies anterior*) is concave and comes in contact with the stomach; close to the junction of the head and the body it usually has an elevation in the direction of the smaller omentum; this is the **tuber omentale of the pancreas**. The *posterior surface* (*facies posterior*) is directed to the posterior abdominal wall. The *inferior surface* (*facies inferior*) faces downward and slightly to the front. The three surfaces are separated from one another by three edges, *margo superior*, *anterior*, and *inferior*. The common hepatic artery passes on the right part of the anterior edge, while to the left stretches the splenic artery passing to the spleen. The gland is slightly raised from right to left as a consequence of which the *tail* is situated higher than the head and reaches the inferior part of the spleen. The pancreas has no capsule as a result of which its lobular structure strikes the eye. The total length of the pancreas varies from 12 to 15 cm.

The peritoneum covers the anterior and inferior surfaces of the pancreas, while the posterior surface is devoid of it. The **pancreatic duct** (*ductus*

<sup>1</sup> In postmortem examination of a supine cadaver the pancreas is actually found under the stomach. It is situated higher in the newborn than in an adult (on the level of the eleventh-twelfth thoracic vertebrae).

*pancreaticus*) receives numerous branches draining into it almost at a right angle. It joins the ductus choledochus and both open by means of a common orifice on the greater duodenal papilla. This constructive connection of the pancreatic duct with the ductus choledochus is determined by its functional significance (treatment of the duodenal contents with the pancreatic juice) as well as by the development of the pancreas from the part of the primary gut from which the duodenum also arises. In addition to the main duct, there is usually an **accessory pancreatic duct** (*ductus pancreaticus accessorius*), which opens on the smaller duodenal papilla (about 2 cm above the greater duodenal papilla). An *accessory pancreas* (*pancreas accessorium*) is sometimes encountered, mostly in the jejunal wall, less frequently in the wall of the stomach or ileum under the mucous or serous coat; its size varies from several millimetres to 4-5 cm (such is the normal position of the pancreas in some lower vertebrates). An annular pancreas is sometimes found, it causes compression of the duodenum.

**Structure.** According to structure, the pancreas is related to the group of acinar or acinar-tubular glands.

Two components are distinguished in it: the main bulk of the gland is concerned with external secretion and excretes its secretions into the duodenum by way of the ducts; the smaller part of the gland consists of the **islets of Langerhans** (*insulae pancreaticae*) and is an endocrine structure secreting insulin (*L insula* island) into the blood; insulin regulates the blood sugar content. There are indications that the pancreas contributes to haemopoiesis and regulation of blood pressure.

As a gland of mixed secretion, the pancreas receives numerous *sources of nutrition*, namely the superior and inferior pancreaticoduodenal arteries, the splenic and left gastro-epiploic arteries, etc. The *veins* of the same name drain into the portal vein and small veins draining into it. The *lymph* flows to the nearest nodes: coeliac, pancreaticolienal, and others.

*Innervation* is accomplished from the solar plexus.

## THE PERITONEUM

The **peritoneum** is a closed serous sac, which communicates with the external environment only in females by means of a very small abdominal opening of the uterine tubes. Like any serous sac, it consists of two layers, **parietal** (*peritoneum parietale*) and **visceral** (*peritoneum viscerale*). The parietal layer lines the abdominal wall, while the visceral layer invests the viscera and forms their serous covering for a shorter or longer distance. Both layers are in close contact and in an intact abdominal cavity there is only a narrow space between them called the **peritoneal cavity** (*cavum peritonei*) that contains a small amount of serous fluid; this fluid moistens the surface of the organs and so makes easier their movement against one another. When air enters the cavity during operation or postmortem examination or when pathological fluids accumulate in it, it acquires the appearance of a true, more or less large cavity.

The parietal peritoneum forms a continuous lining on the anterior and lateral walls of the abdomen and passes on to the diaphragm and the

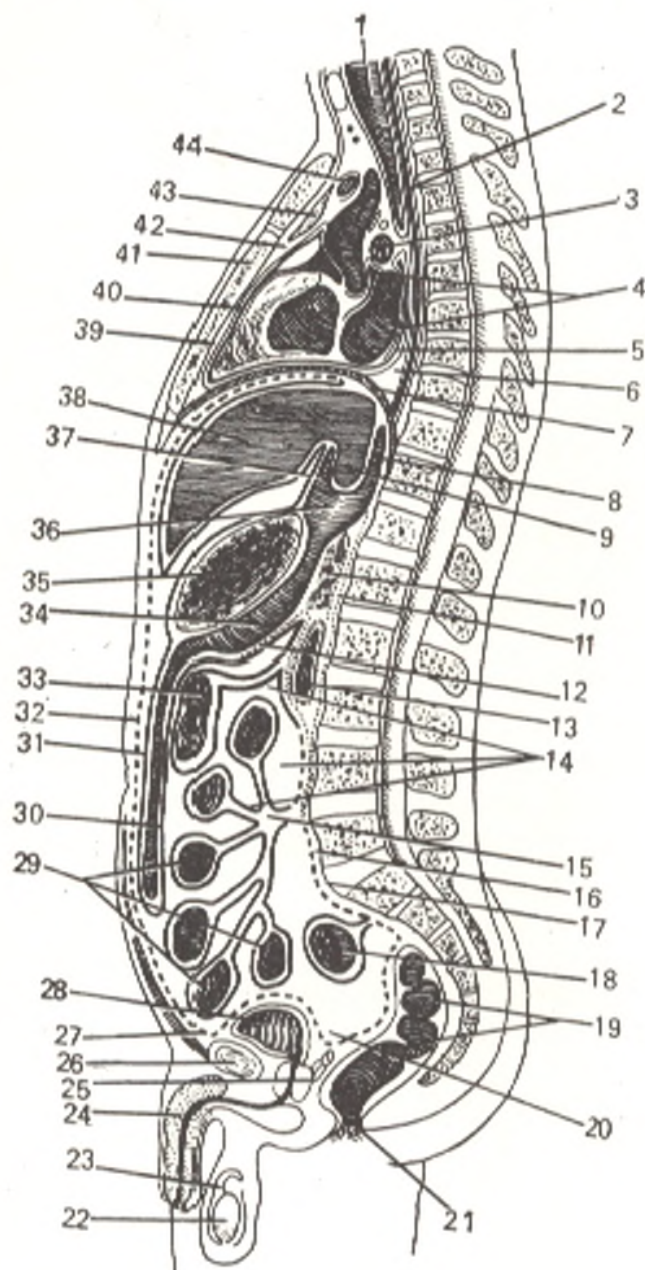


Fig. 223. Arrangement of the peritoneum and pericardium represented schematically.

- 1, trachea;
- 2, oesophagus;
- 3, right pulmonary artery;
- 4, pericardial cavity;
- 5, pericardium;
- 6, posterior mediastinum;
- 7, diaphragm;
- 8, superior recess of bursa omentalis;
- 9, caudate lobe of liver;
- 10, pancreas;
- 11 and 16, retroperitoneal space;
- 12, posterior layer of greater omentum;
- 13, duodenum;
- 14, peritoneal cavity;
- 15, root of mesentery;
- 17, promontory;
- 18, sigmoid colon;
- 19, rectum;
- 20, excavatio vesicorectale;
- 21, anus;
- 22, testis;
- 23, vaginal coat of testis;
- 24, penis;
- 25, prostata and seminal vesicle;
- 26, symphysis pubis;
- 27, prevesical space;
- 28, urinary bladder;
- 29, small intestine on the mesentery;
- 30, greater omentum (posterior layers);
- 31, greater omentum (anterior layers);
- 32, parietal peritoneum;
- 33, transverse colon with mesentery;
- 34 and 36, omental bursa;
- 35, stomach;
- 37, lesser omentum (hepatogastric ligament);
- 38, liver;
- 39, pericardium;
- 40, pericardial cavity;
- 41, body of sternum;
- 42, anterior mediastinum;
- 43, thymus;
- 44, left brachiocephalic vein

posterior abdominal wall. Here it is reflected on the viscera and is directly continuous with the visceral peritoneum investing them (Fig. 223).

Between the peritoneum and the abdominal walls is a connective-tissue layer containing a greater or lesser amount of fatty tissue. This is the *extraperitoneal tissue (tela subserosa)*, which is developed irregularly. It is absent, for instance, in the region of the diaphragm but is developed best on the posterior abdominal wall where it surrounds the kidneys, ureters, adrenal glands, the abdominal aorta and vena cava inferior and their branches. On a greater area of the anterior abdominal wall the extraperitoneal tissue is poorly developed, but in the pubic region the amount of fat increases in it and the peritoneum is joined here loosely with the abdominal wall. As a result, a distended urinary bladder pushes the peritoneum away from the anterior abdominal wall and at a distance of about 5 cm above the pubis

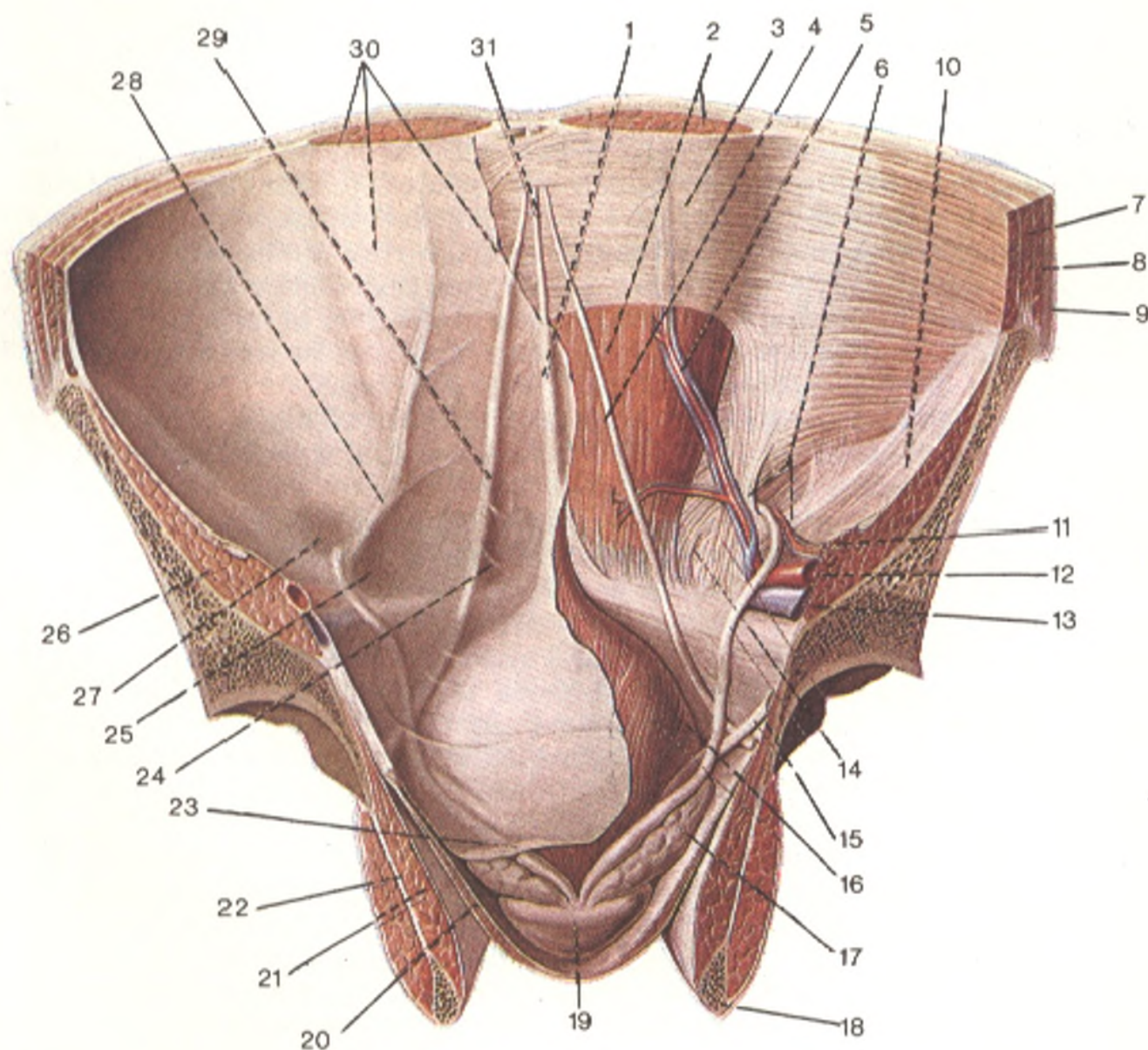


Fig. 224. Posterior surface of anterior abdominal wall and pelvis (the peritoneum and transverse fascia are removed on the right, after Sinelnikov).

- 1, plica umbilicalis mediana;  
 2, m. rectus abdominis;  
 3, vagina m. recti abdominis (paries posterior);  
 4, lig. umbilicale laterale;  
 5, a. and vv. epigastricae inferiores;  
 6, anulus inguinalis profundus;  
 7, m. transversus abdominis;  
 8, m. obliquus internus abdominis;  
 9, m. obliquus externus abdominis;  
 10, fascia iliaca;  
 11, vasa spermatica;  
 12, a. iliaca externa;  
 13, v. iliaca externa;  
 14, ductus deferens;  
 15, ureter;

- 16, vesica urinaria;  
 17, vesicula seminalis;  
 18, os ischii;  
 19, prostata;  
 20, m. levator ani;  
 21, m. obturatorius internus;  
 22, m. obturatorius externus;  
 23, peritoneum parietale;  
 24, fossa supravesicalis;  
 25, fossa inguinalis medialis;  
 26, fossa inguinalis lateralis;  
 27, m. iliopsoas;  
 28, plica umbilicalis lateralis;  
 29, plica umbilicalis media;  
 30, peritoneum parietale and m. rectus;  
 31, ligamentum umbilicale medianum

its anterior surface comes in direct contact with the abdominal wall. In the lower part of the anterior abdominal wall the peritoneum forms five folds converging on the umbilicus: one unpaired *medial umbilical fold* (*plica umbilicalis mediana*) and two paired *medial* and *lateral umbilical folds* (*plicae umbilicales mediales* and *plicae umbilicales laterales*) (Fig. 224).

These folds bound on each side two *inguinal fossae* (*fossae inguinales*) above the inguinal ligament, which are related to the inguinal canal. Immediately below the medial part of the inguinal ligament is the femoral fossa, which corresponds to the position of the ring of the femoral canal. Above the umbilicus the peritoneum passes from the anterior abdominal wall and diaphragm to the diaphragmatic surface of the liver to form the *falciform ligament of the liver* between the two layers of which, at its free edge is lodged *ligamentum teres hepatis* (obliterated umbilical vein).

Posteriorly of the falciform ligament the peritoneum is reflected from the inferior surface of the diaphragm onto the diaphragmatic surface of the liver to form the *coronary ligament of the liver* (*lig. coronarium hepatis*) whose edges have the shape of triangular plates, which are known as the **right and left triangular ligaments of the liver** (*lig. triangulare dextrum* and *sinistrum*). From the diaphragmatic surface of the liver the peritoneum folds over its sharp border to the visceral surface; then from the right lobe it passes to the upper end of the right kidney as the **hepatorenal ligament** (*lig. hepatorenale*), from the hepatic porta to the lesser curvature of the stomach as a thin **hepatogastric ligament** (*lig. hepatogastricum*), and to the part of the duodenum nearest to the stomach as the **hepatoduodenal ligament** (*lig. hepatoduodenale*). The hepatogastric and hepatoduodenal ligaments are duplications of the peritoneum because two peritoneal layers are encountered in the region of the porta hepatis, one passing to the porta from the anterior part of the visceral surface of the liver and the other from the posterior part. The hepatoduodenal and hepatogastric ligaments are a continuation of one another and form together the **lesser omentum** (*omentum minus*). On the lesser curvature of the stomach both layers of the lesser omentum separate, one to cover the anterior and the other the posterior surface of the stomach. On the greater curvature they again join and descend in front of the transverse colon and the loops of the small intestine to form the anterior lamina of the **greater omentum** (*omentum majus*). On some level both layers fold over to ascend and form its posterior lamina (the greater omentum consists, therefore, of four layers). On reaching the transverse colon the two layers forming the posterior lamina of the greater omentum blend with the transverse colon<sup>1</sup> and its mesentery and together with the last named pass posteriorly to the anterior border of the pancreas; here they separate, one passes upward and the other downward. One covers the anterior surface of the pancreas and then ascends onto the diaphragm, the other, having covered the inferior surface of the pancreas, is continuous with the mesentery of the transverse colon, *transverse mesocolon* (*mesocolon transversum*).

<sup>1</sup> In total adhesion of the anterior and posterior laminae of the greater omentum with the transverse colon in an adult, five peritoneal layers (four omental layers and the visceral peritoneum of the intestine) are thus fused on the tenia mesocolica.

We shall now trace the course taken by the peritoneum, proceeding from the same layer on the anterior abdominal wall, but not upward to the diaphragm, but in the transverse direction. From the anterior abdominal wall the peritoneum extends to line the lateral walls of the abdominal cavity, passes to the posterior wall on the right and thus surrounds completely the caecum and its vermiform process, which acquires a mesentery, the *mesentery of the vermiform appendix* (*mesenteriolum appendicis vermiformis*). The peritoneum covers the ascending colon in front and on the sides, then the lower part of the anterior surface of the right kidney, passes medially over the psoas muscle and ureter, and at the *root of the mesentery* of the small intestine (*radix mesenterii*) is reflected to be continuous with the right layer of this mesentery. Having supplied the small intestine with a complete serous covering, the peritoneum is continuous with the left layer of the mesentery. At the root of the mesentery the left layer of the mesentery is continuous with the parietal peritoneum on the posterior abdominal wall. Then the peritoneum on the left covers the lower part of the left kidney and approaches the descending colon, which is related to the peritoneum in the same manner as the ascending colon. Still further laterally, on the lateral abdominal wall, the peritoneum is again reflected on the anterior abdominal wall. For easier understanding of the complex relations, the whole peritoneal cavity can be separated into three regions, or *storeys*: (1) an upper storey bounded superiorly by the diaphragm, and inferiorly by the mesocolon transversum; (2) a middle storey extending downward from the mesocolon transversum to the entry into the true pelvis; the posterior margin of the mesocolon transversum is attached to the posterior abdominal wall on a line passing from the upper part of the right kidney through the beginning of the descending part of the duodenum and the head of the pancreas and along the anterior border of the pancreas to the upper part of the left kidney. On the anterior margin of the mesocolon transversum stretches the transverse colon, which comes in contact with the anterior abdominal wall. As a result, the upper storey of the abdominal cavity, for the whole distance from the anterior to the posterior abdominal wall, is separated from the middle storey by the mesocolon and the transverse colon suspended on it (the separation is not complete, however, because the two storeys communicate by a narrow space between the transverse colon and the anterior abdominal wall); (3) the lower storey begins at the line of entry into the true pelvis and corresponds to the cavity of the true pelvis which is the lowest part of the abdominal cavity.

1. The *upper storey* of the peritoneal cavity separates into three sacs: hepatic bursa (*bursa hepatica*), pregastric bursa (*bursa pregastrica*), and omental bursa (*bursa omentalis*). The *hepatic bursa* is related to the right lobe of the liver and is separated from the pregastric bursa by the falciform ligament of the liver; it is bounded posteriorly by the coronary ligament of the liver. The upper end of the right kidney with the adrenal gland is palpated under the liver deep in the hepatic bursa. The *pregastric bursa* is related to the left lobe of the liver, anterior surface of the stomach, and the spleen; the left part of the coronary ligament passes on the posterior border of the left lobe of the liver; the spleen is completely invested with the peritoneum except

for the hilus, where the peritoneum passes from the spleen to the stomach as the gastrosplenic ligament (*ligamentum gastrosplenicum*) and to the diaphragm as the lienorenal ligament (*ligamentum phrenicolienale*).

The omental bursa, *lesser sac of the peritoneum (bursa omentalis)*, is part of the general peritoneal cavity lying behind the stomach and the lesser omentum. As it is indicated above, the lesser omentum consists of two peritoneal ligaments, the hepatogastric ligament passing from the visceral surface of the liver and the porta hepatis to the lesser curvature of the stomach, and the hepatoduodenal ligament connecting the hepatic porta with the superior part of the duodenum. *Between the layers of the hepatoduodenal ligament pass the common bile duct (on the right), the common hepatic artery (on the left) and the portal vein (posteriorly and between these structures), as well as lymphatic vessels, nodes and nerves.*

The cavity of the omental bursa communicates with the general peritoneal cavity only by means of a relatively narrow epiploic foramen, *opening into the lesser sac (foramen epiploicum)*. The foramen is bounded above by the caudate lobe of the liver, in front by the free margin of the hepatoduodenal ligament, below by the superior part of the duodenum, behind by the peritoneal layer covering the vena cava inferior, which passes here, and more laterally it is bounded by a ligament passing from the posterior border of the liver to the right kidney, the hepatorenal ligament (*lig. hepatorenale*). Part of the omental bursa directly adjoining the epiploic foramen and situated behind the hepatoduodenal ligament is known as the *vestibule of the omental bursa (vestibulum bursae omentalis)*; it is bounded by the caudate lobe of the liver above and by the duodenum and head of the pancreas below. The upper wall of the omental bursa is formed by the inferior surface of the caudate lobe, with the papillary process suspended in the bursa itself. The parietal peritoneum forming here the posterior wall of the omental bursa covers the abdominal aorta, vena cava inferior, and the pancreas; it leaves the anterior border of the pancreas and continues forward and downward as the anterior layer of the mesocolon transversum, or, to be more precise, the posterior lamina of the greater omentum, fused with the mesocolon transversum.

The **greater omentum** (*omentum majus, s. epiploon*)<sup>1</sup> hangs like an apron from the transverse colon and covers the loops of the small intestine for a greater or lesser distance; it is thus named because fat is present in its tissues (*L omentum fat skin*). It is formed of four peritoneal layers fused to form two laminae. The anterior lamina of the greater omentum consists of two peritoneal layers descending from the greater curvature of the stomach in front of the transverse colon with which they are fused; the part between the stomach and the transverse colon is called the *gastrocolic ligament (ligamentum gastrocolicum)*. These two layers of the omentum may descend in front of the loops of the small intestine almost to the level of the pubic bones and are then reflected to be continuous with the posterior lamina of

<sup>1</sup> Galen described the omentum as a peritoneal fold swimming (*epipleo*) on the intestine.



the omentum so that the entire thickness of the greater omentum consists of four layers. Normally, the omental layers do not fuse with the loops of the small intestine. There is a slit-like cavity between the anterior and posterior layers of the omentum, which communicates above with the cavity of the omental bursa. In an adult, however, the layers usually adhere one to another and the cavity of the greater omentum is obliterated on a considerable distance, though in some cases it exists for some length between the layers of the greater omentum along the greater curvature of the stomach.

2. The *middle storey* of the peritoneal cavity can be visualized when the greater omentum and transverse colon are raised. Using as the boundaries the ascending and descending parts of the colon on the sides and the mesentery of the small intestine in the middle, this storey can be subdivided into four compartments; between the lateral abdominal walls and the colon ascendens and colon descendens are the right and left lateral canals (*canales laterales dexter and sinister*); the space bounded by the colon is divided by the mesentery of the small intestine, descending obliquely from left to right, into the *right and left mesenteric sinuses* (*sinus mesentericus dexter and sinus mesentericus sinister*).

The *mesentery* (*mesenterium*) is a fold of two peritoneal layers by means of which the small intestine is attached to the posterior abdominal wall (Fig. 225). The posterior margin of the mesentery attached to the abdominal wall is the root of the mesentery (*radix mesenterii*). It is relatively short (15-17 cm), whereas the opposite free end related to the mesenteric part of the small intestine (jejunum and ileum) is the length of these two segments. The line of attachment of the root passes obliquely from the left side of the second lumbar vertebra to the right iliac fossa, transecting the terminal part of the duodenum, the aorta, vena cava inferior, right ureter and psoas major muscle. With a change in the position of the alimentary canal and growth of the adjacent organs, the root of the mesentery changes from a vertical position in the embryonic period to an oblique position by the time of birth. Blood vessels, nerves, lymphatic vessels and lymph nodes pass in the thickness of the mesentery between the two serous layers containing more or less fatty tissue.

A series of peritoneal recesses are seen on the posterior parietal peritoneum; these have practical importance because they may be the place where retroperitoneal hernias form. Small pockets form at the junction of the duodenum and jejunum; they are the superior and inferior duodenal recesses (*recessus duodenalis superior and inferior*). They are bounded on the right by the duodenojejunal flexure, on the left by a peritoneal fold, the duodenojejunal plica, passing from the apex of the flexure to the posterior abdominal wall directly below the body of the pancreas and containing the inferior mesenteric vein.

At the junction of the small intestine and the colon are two recesses, the *inferior and superior ileocaecal recesses* (*recessus ileocecalis inferior and superior*), situated below and above the ileocaecal fold passing from the ileum to the medial surface of the caecum.

A recess in the parietal peritoneum lodging the caecum is called the

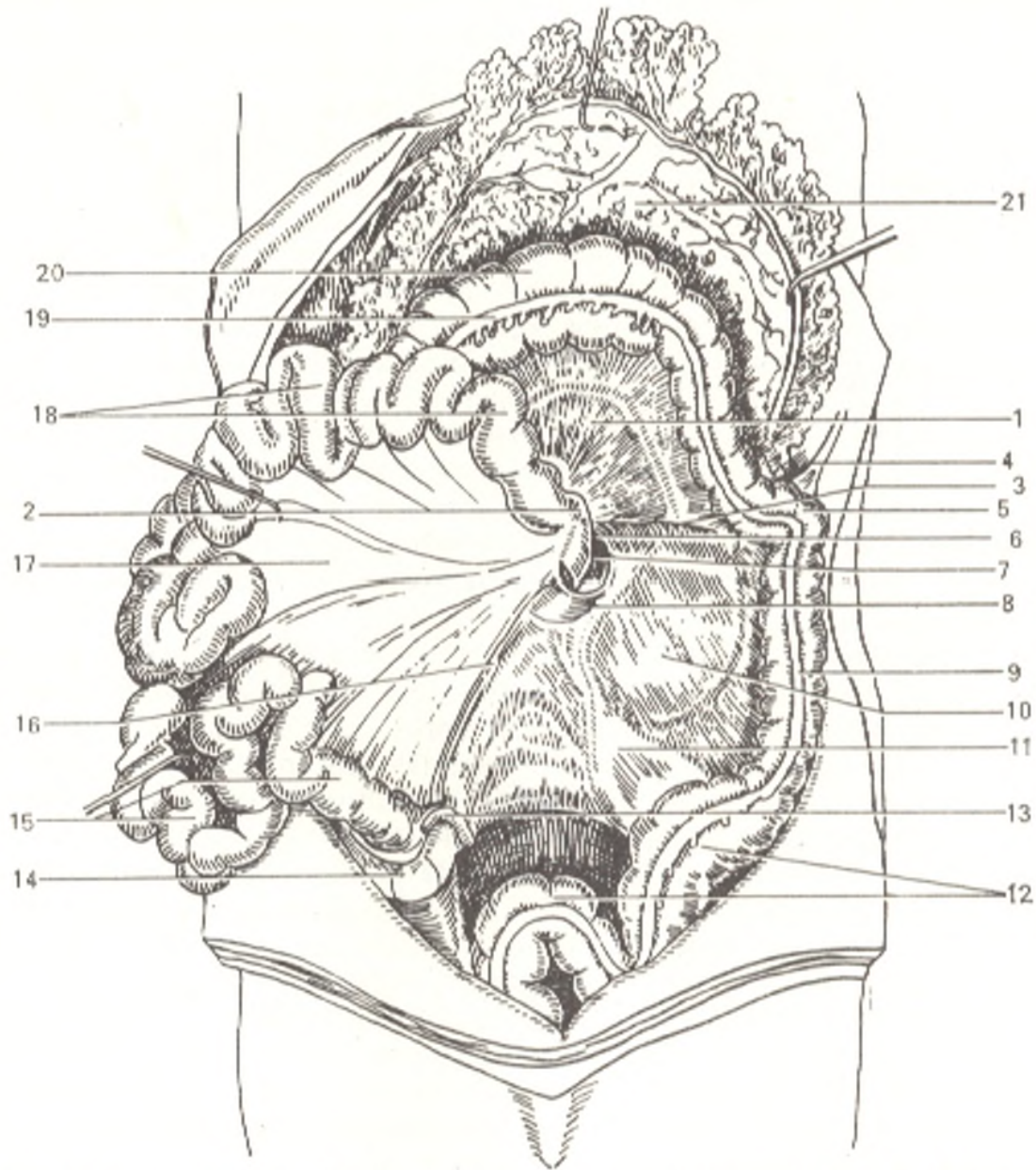


Fig. 225. Organs of the abdominal cavity; the mesentery of the small intestine is drawn aside and upward and the greater omentum is lifted.

- |                                  |                                       |
|----------------------------------|---------------------------------------|
| 1, mesocolon transversum;        | 13, appendix vermiformis;             |
| 2, flexura duodenojejunalis;     | 14, intestinum cecum;                 |
| 3, radix mesocolonis;            | 15, intestinum ileum;                 |
| 4, lig. phrenicocolicum;         | 16, radix mesenterii;                 |
| 5, flexura coli sinistra;        | 17, mesenterium;                      |
| 6 and 8, plica duodenojejunalis; | 18, jejunum;                          |
| 7, recessus duodenalis superior; | 19, tenia libera;                     |
| 9, colon descendens;             | 20, colon transversum;                |
| 10, peritoneum parietale;        | 21, omentum majus (posterior surface) |
| 11, mesocolon sigmoideum;        |                                       |
| 12, colon sigmoideum;            |                                       |

fossa of the caecum; it can be seen when the caecum and the adjacent part of the ileum are raised. The fold of the peritoneum forming them between the surface of the iliacus muscle and the lateral surface of the caecum is known as the *caecal fold* (*plica cecalis*). A small opening extending upward

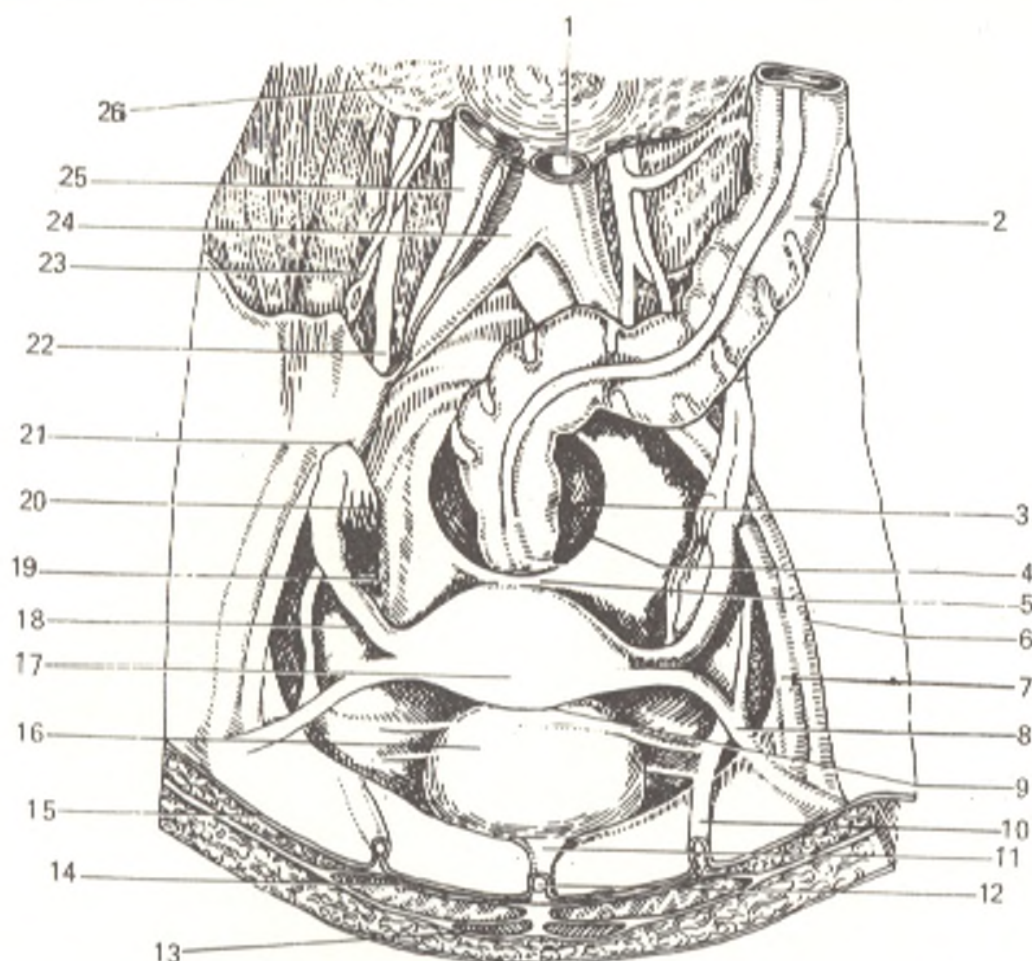


Fig. 226. Relation of peritoneum to the organs of the female true pelvis, viewed from above (after Sinelnikov).

- |                                 |                                 |
|---------------------------------|---------------------------------|
| 1, aorta abdominalis;           | 14, m. rectus abdominis;        |
| 2, colon sigmoideum;            | 15, peritoneum parietale;       |
| 3, rectum;                      | 16, plica vesicalis transversa; |
| 4, excavatio rectouterina;      | 17, fundus uteri;               |
| 5, plica rectouterina;          | 18, tuba uterina;               |
| 6, a. iliaca externa sinistra;  | 19, ovarium;                    |
| 7, v. iliaca externa sinistra;  | 20, fimbriae tubae;             |
| 8, lig. teres uteri;            | 21, lig. suspensorium ovarii;   |
| 9, excavatio vesicouterina;     | 22, ureter;                     |
| 10, plica umbilicalis medialis; | 23, vasa ovarica;               |
| 11, apex vesicae;               | 24, a. iliaca communis dextra;  |
| 12, plica umbilicalis mediana;  | 25, v. cava inferior;           |
| 13, m. pyramidalis;             | 26, m. psoas major              |

between the posterior abdominal wall and the ascending colon and leading into the *retrocaecal recess* (*recessus retrocecalis*) is sometimes seen in the caeca ossa behind the caecum. On the left side is the recess of the pelvic mesocolon (*recessus intersigmoideus*); it becomes visible on the lower (left) surface of the raised mesentery of the sigmoid colon. Peritoneal pockets are sometimes encountered lateral of the descending colon, these are the *paracolic grooves* (*sulci paracolici*). Higher, between the diaphragm and the left colic flexure is a peritoneal fold, the phrenicocolic ligament (*lig. phrenicocolicum*); it lies exactly under the lower end of the spleen and is also known as the splenic sac.

3. The *Lower storey*. On descending into the cavity of the true pelvis

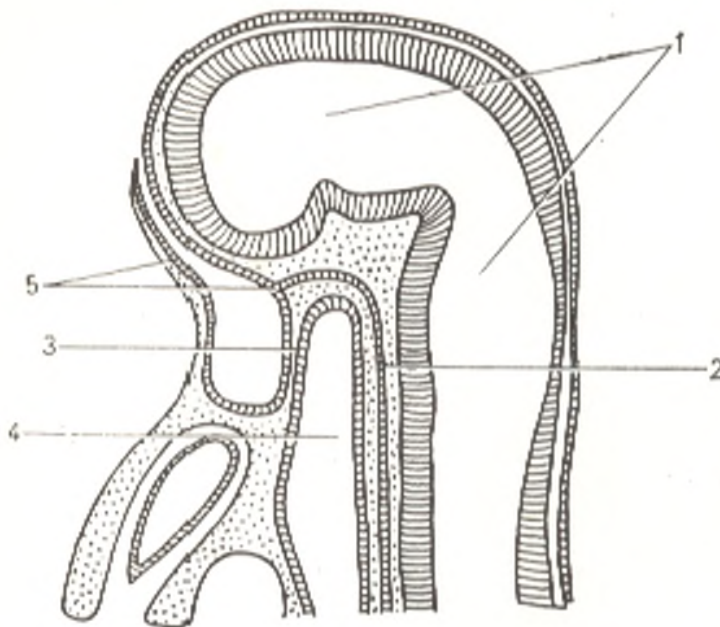


Fig. 227. Formation of the oral region in a rabbit (longitudinal section).

- 1, ventricles of the brain;
- 2, chorda;
- 3, pharyngeal membrane;
- 4, foregut;
- 5, the ectoderm is pulled in

the peritoneum covers its walls and the organs contained in it, the urogenital organs among others. The relations of the peritoneum here are therefore determined by the sex. The pelvic part of the sigmoid colon and the beginning of the rectum are completely invested in the peritoneum and have a mesentery (intraperitoneal localization).

The middle part of the rectum is covered by the peritoneum only on the anterior and lateral surfaces (mesoperitoneal localization), while the lower part of the rectum is not covered by the peritoneum at all (extraperitoneal localization). On passing from the anterior surface of the rectum to the posterior surface of the urinary bladder in males, the peritoneum forms a pouch between its layers behind the bladder; this is the *rectovesical pouch* (*excavatio rectovesicalis*). A transverse vesical fold (*plica vesicalis transversa*) is formed by the peritoneum on the superoposterior surface of an empty bladder, which is straightened out when the bladder is filled. In females, the relations of the peritoneum in the pelvis are different because between the urinary bladder and the rectum is the uterus, which is also covered by the peritoneum. As a result there are two peritoneal pouches in the female pelvis, namely the *recto-uterine pouch* (*excavatio recto-uterina*) between the rectum and uterus and the *utero-vesical pouch* (*excavatio vesico-uterina*) between the uterus and the urinary bladder (Fig. 226).

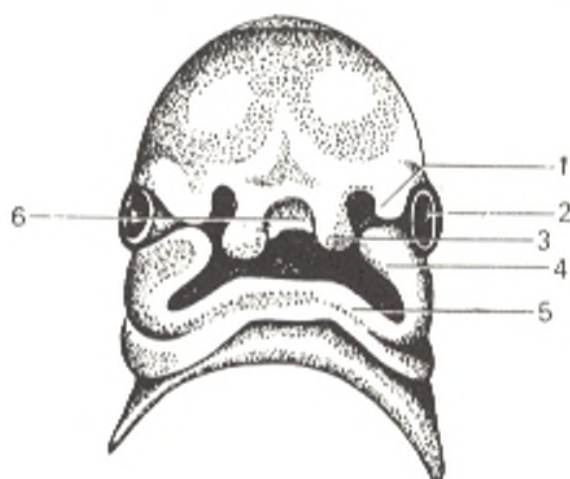
#### MAIN STAGES IN THE DEVELOPMENT OF THE DIGESTIVE SYSTEM AND THE PERITONEUM AND THEIR DEVELOPMENTAL ANOMALIES

Most of the alimentary canal develops from the entoderm<sup>1</sup> though the ectoderm contributes to the formation of its both ends. It is exactly at the anterior end that due to the intensified growth of the anterior part of the brain a depression lined with ectoderm (the

<sup>1</sup> To be more precise, the entoderm gives rise to the epithelium of the alimentary canal, while its muscular and connective-tissue structures are derived from the mesenchyma.

Fig. 228. The head of a human embryo (anterior aspect).

- 1, lateral nasal process;
- 2, eye bud;
- 3, globular process;
- 4, maxillary process;
- 5, mandibular process;
- 6, median nasal process



oral pit) forms between the brain (above) and the region of the pericardium (below). The oral pit grows deeper until it meets the anterior end of the primary alimentary canal of entodermal origin from which it is at first separated by the *pharyngeal membrane* (*membrana pharyngea*) (Fig. 227).

On the third week of embryonic life, the pharyngeal membrane consisting of two layers (ectodermal and entodermal) ruptures and the cavity of the primary oral pit thus communicates with the cavity of the intestine, which is of entodermal origin. A pouch (Rathke's) forms before the membrane ruptures; this is a protrusion toward the brain; it is located in front of the membrane (the anterior part of the hypophysis, or pituitary gland, develops from it). The oral pit is bounded on the sides by derivatives of the first visceral arch, which is separated into two processes on each side, the *maxillary* and *mandibular processes* (Fig. 228). The paired mandibular processes fuse on the midline to form the mandible and the parts of the face corresponding to it (the upper lip also) and thus form the inferior border of the entry into the oral cavity. The maxillary processes give rise to the maxillae with the palate and the corresponding soft tissues of the face, the lateral segments of the upper lip in particular.

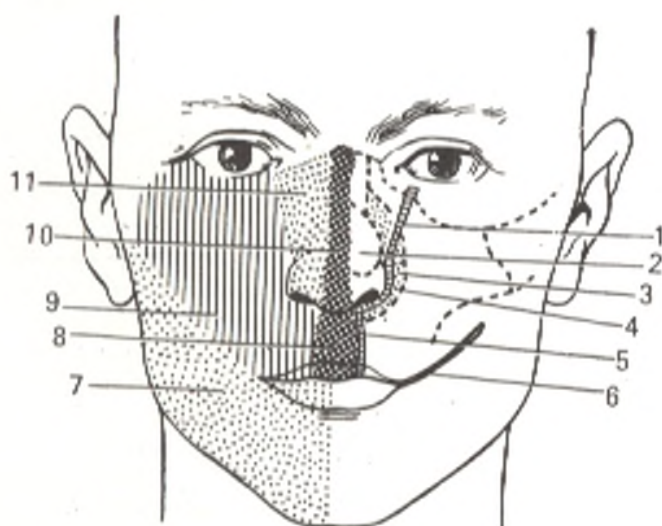


Fig. 229. Schematical representation of development and union of parts of the face from the corresponding embryonic structures.

- |                                   |                             |
|-----------------------------------|-----------------------------|
| 1, nasolacrimal sulcus;           | 7, mandible;                |
| 2, piriform orifice;              | 8, strainer of lip;         |
| 3, maxilla;                       | 9, maxillary process;       |
| 4, incisive bone;                 | 10, median (nasal) process; |
| 5, site of formation of hare-lip; | 11, lateral nasal process   |
| 6, transverse oral cleft;         |                             |

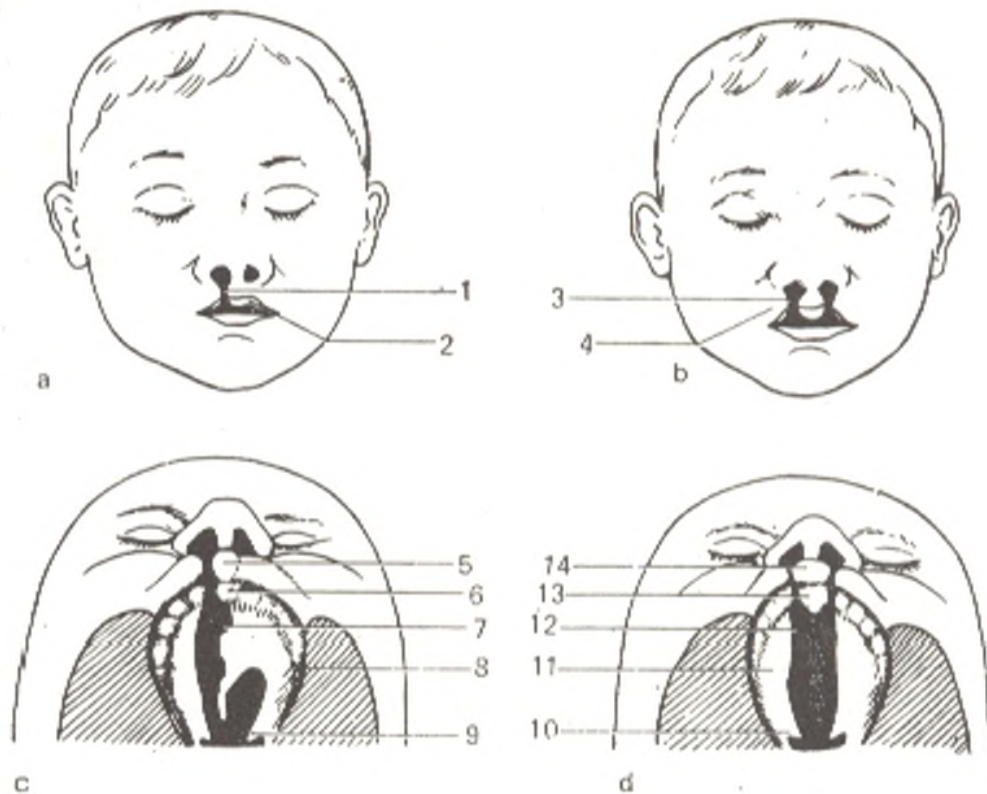


Fig. 230. Developmental anomalies of the upper lip and hard palate (schematical representation).

a, unilateral cleft of upper lip;  
 b, bilateral cleft of upper lip;  
 c, cleft of lip and hard palate, right side;  
 d, bilateral cleft of lip and hard palate.  
 1 and 3, cleft between the median nasal  
 and maxillary (2 and 4) processes;

5 and 14, strainer of lip;  
 6 and 13, intermaxillary region;  
 7 and 12, defective palatine septum;  
 8 and 11, palatine process;  
 9 and 10, uvula

The maxillary processes do not fuse with one another (see Fig. 228); wedged between them on the midline is the median nasal process of the frontal tuber (eminence) of the embryo, which bounds the primary oral pit above. This nasal process gives rise to the nasal septum, the incisive part of the hard palate and the corresponding middle part of the lip (the strainer). It joins the maxillary processes to form the upper border of the oral cavity (Fig. 229). A ridge forms on the internal surface of the maxillary process and grows toward the median plane; it is called the *palatine plate*. At first there is a cleft between the right and left palatine plates but later they fuse to form the palate (hard and soft). The palate separates the primary oral cavity into two parts; an upper part, the *nasal cavity*, and a lower part, the *oral cavity proper*. The maxillary and mandibular processes on each side fuse to form the angles of the mouth. If they fail to unite, a transverse cleft of the face is formed with a considerable increase of the oral orifice (macrostomia), but if the union is very close, then a very small mouth is formed (microstomia). The palatine plates of the maxillary process may remain ununited after birth, in which case a cleft is left in the hard palate, a condition known as the *cleft palate* (*palatum fissum*, or *faux lupina*). The nasal process may also fail to unite with the maxillary process as a result of which the upper lip is divided and resembles the lip of a hare, hence the name *hare-lip* (*labium leporinum*). Since the site of union of these processes is lateral of the midline, the cleft on the upper lip is situated laterally and may be unilateral or bilateral (Fig. 230). The final oral cavity of an adult is derived partly from the ectoderm (oral pit) and partly from the entoderm (the primary gut); the dental enamel and the smaller peripheral part of the oral cavity with its epithelium develop from the ectoderm; the tongue epithelium and the salivary glands are entodermal in origin.

## THE FOREGUT

The pharynx. The ventral wall of the primary pharynx (from the bronchial pouches) gives rise to the tongue epithelium (see p. 410) and the thyroid gland growing in the region of foramen caecum linguae. The connection between these two organs may persist as an anomaly called the thyroglossal duct (ductus thyroglossus). Four entodermal pharyngeal (branchial) pouches form on each lateral wall of the pharynx; on the external surface of the embryo corresponding in position to these pouches are the external pharyngeal (branchial) grooves lying between the branchial arches (Fig. 231). The fifth pharyngeal pouch is usually underdeveloped. Different organs develop from the pharyngeal pouches. The first pharyngeal pouch gives rise to the Eustachian (auditory) tube and the middle ear (the tympanic membrane). The second pouch produces the tonsillar sinus with the palatine tonsil. The thymus and the parathyroid gland are derived from the third and fourth pouches. Slits, congenital fistula of the neck (fistulae colli congenitae), persist as anomalies in rare cases in place of the pharyngeal pouches; these are kind of an echo of the previously existing branchial grooves.

In the early developmental stages, the *oesophagus* has smooth musculature (like in the entire primary gut), which arises from the mesenchyme. Later, after rupture of the pharyngeal membrane, striated musculature of mesodermal origin forms a layer above. As a result the upper part of the *oesophagus* contains striated muscle tissue, while the middle and lower parts contain smooth muscles.

The first signs of the differentiation of the *stomach* (Fig. 232a, b, and c) appear in the fourth week of embryonic life as a spindle-shaped distension of the foregut. At first

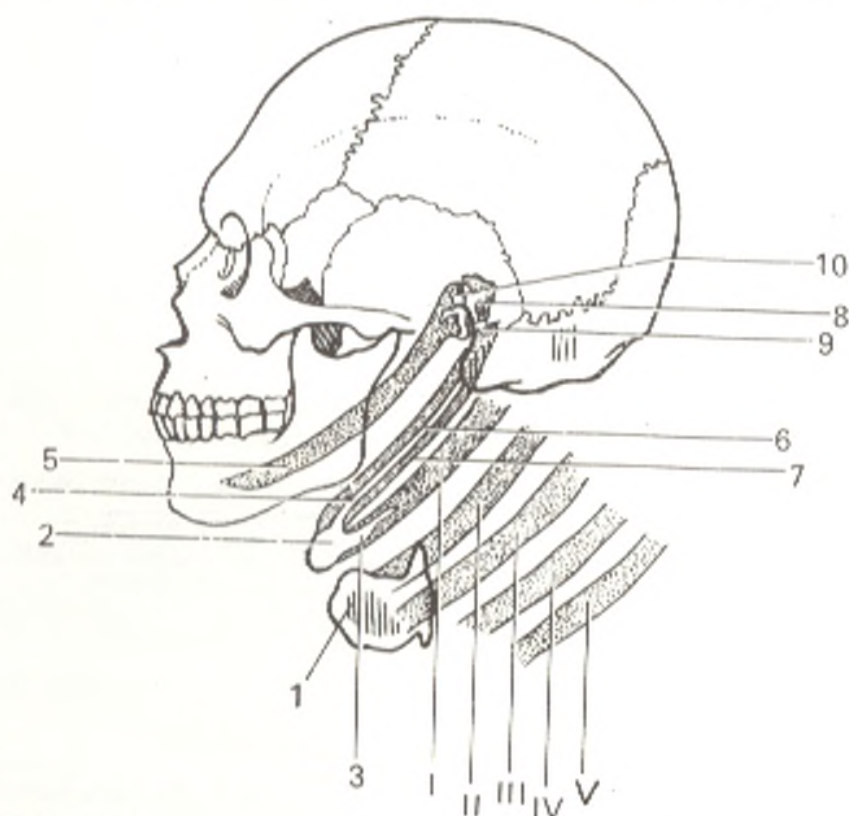


Fig. 231. Branchial arches and structures developing from them (Bystrov's modified schematical representation).

- |   |  |
|---|--|
| 1, thyroid cartilage;                                       | 6, styloid process;                                  |
| 2, body of hyoid bone;                                      | 7, hyoid arch;                                       |
| 3, greater horn, derivative of first branchial arch proper; | 8, incus;  |
| 4, lesser horn of hyoid bone;                               | 9, stapes;   |
| 5, Meckel's cartilage (derivative of mandibular arch);      | 10, malleus. I, II, III, IV, and V, branchial arches |

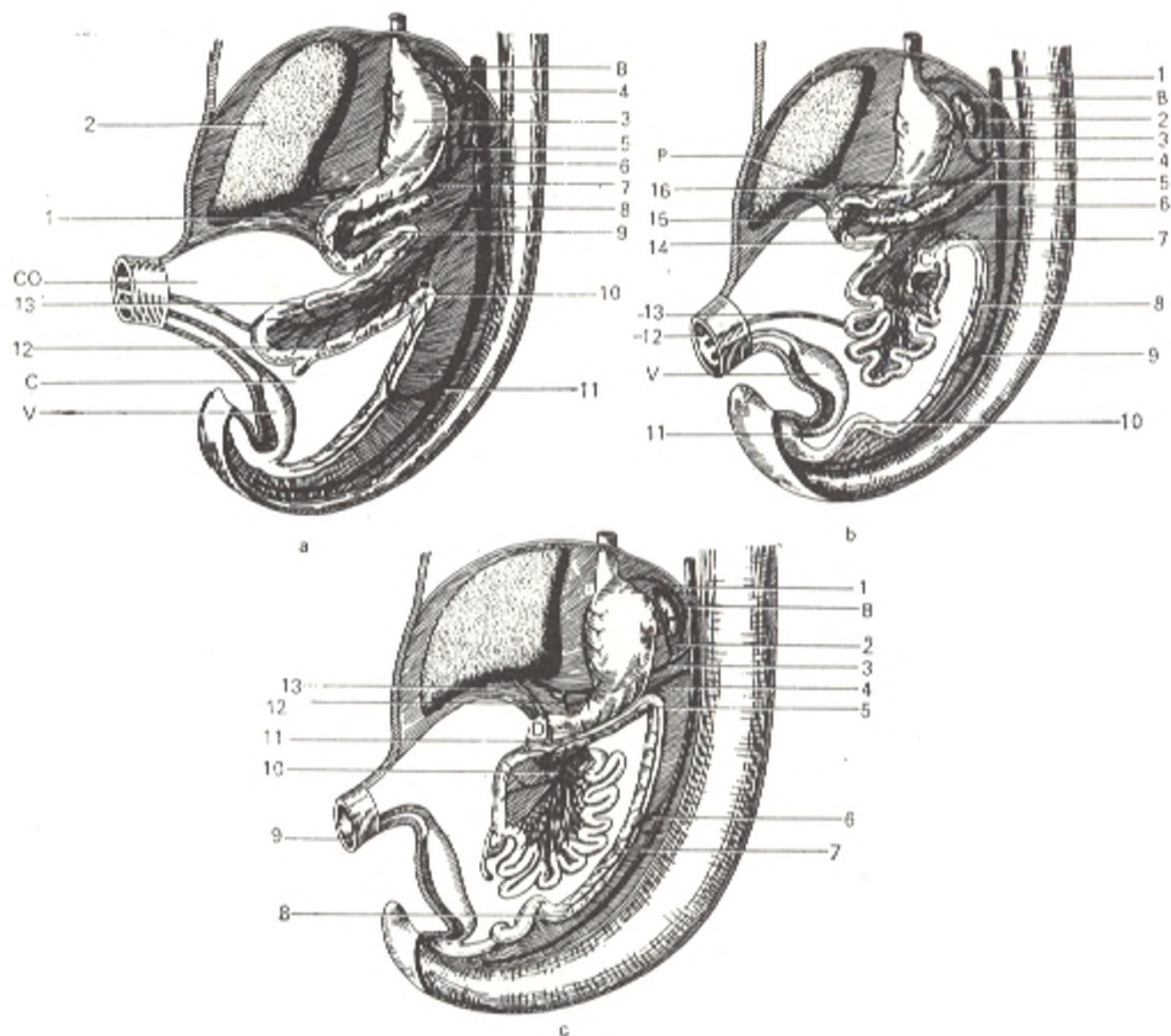


Fig. 232. Development of separate segments of the alimentary tube and the branching of vessels in it, represented schematically.

a, stage I: C, caecum; CO (D.V.), ductus vitellinus (omphaloentericus); V, vesica urinaria; B(L), lien.

- |                          |  |
|--------------------------|--|
| 1, ductus choledochus;   | 8, a. mesenterica superior;                  |
| 2, hepar;                | 9, flexura duodenojejunalis;                 |
| 3, ventriculus;          | 10, flexura coli sinistra (lienalis);        |
| 4, a. gastrica sinistra; | 11, a. mesenterica inferior;                 |
| 5, truncus celiacus;     | 12, lower (distal) limb of vitelline loop;   |
| 6, a. lienalis;          | 13, upper (proximal) limb of vitelline loop. |
| 7, a. hepatica;          |  |

b, stage II: D, duodenum; B(L), lien; C, caecum; V, vesica urinaria; P, pancreas.

- |                             |   |
|-----------------------------|---|
| 1, aorta;                   | 9, a. mesenterica inferior;               |
| 2, a. gastrica sinistra;    | 10, colon sigmoideum;                     |
| 3, a. lienalis;             | 11, cloaca;                               |
| 4, truncus celiacus;        | 12, ductus vitellinus (omphaloentericus); |
| 5, a. hepatica;             | 13, umbilicus;                            |
| 6, a. mesenterica superior; | 14, flexura duodenojejunalis;             |
| 7, flexura coli sinistra;   | 15, a. pancreaticoduodenalis superior;    |
| 8, colon descendens;        | 16, a. hepatica.                          |

c, stage III: B(L), lien; C, caecum; D, duodenum.

- |                             |                              |
|-----------------------------|------------------------------|
| 1, a. gastrica sinistra;    | 8, colon sigmoideum;         |
| 2, a. lienalis;             | 9, urachus;                  |
| 3, a. hepatica;             | 10, a. mesenterica superior; |
| 4, a. mesenterica superior; | 11, colon transversum;       |
| 5, flexura coli sinistra;   | 12, a. gastrica dextra;      |
| 6, a. mesenterica inferior; | 13, ductus choledochus       |
| 7, colon descendens;        |                              |



the stomach, like the remaining part of the alimentary tube, is suspended on the dorsal and ventral mesenteries and is situated in the median plane so that one of its sides is the right and the other the left. With the intensified growth of the dorsal border of the stomach and the resulting curvature, the stomach rotates about its longitudinal axis so that its left side becomes the anterior, and the right side the posterior surface. At the same time the stomach acquires an oblique position; ostium cardiacum is displaced to the left of the median plane. The rotation of the stomach about the longitudinal axis is also transmitted to the inferior segment of the oesophagus.

## THE MIDGUT

The part of the *alimentary canal* between the stomach and the orifice of the vitelline duct is at first a short straight segment on which a diverticulum forms (the rudiment of the liver). With the growth of the liver the alimentary tract grows in length and forms a loop consisting of two limbs, a proximal descending and a distal ascending. It is called the vitelline loop because the vitelline duct joining the intestinal loop with the umbilicus opens on its apex. The vitelline duct soon atrophies and the connection between the intestine and the anterior wall of the body is lost. A blind process, a diverticulum, persists throughout life here as an anomaly; it is a protrusion of the ileum close to its junction with the large intestine. The segment of the descending limb nearest to the stomach is transformed into the duodenum, while the remaining (greater) part of this limb and the beginning of the ascending limb give rise to the mesenteric part of the small intestine. The remaining, greater part of the ascending limb is transformed into the large intestine (Fig. 233). Besides, from that part of the primary gut, which is transformed into the duodenum, also develop the large digestive glands, the liver and pancreas, owing to which their connection with the duodenum is retained through the choledochus and the pancreatic duct.

The *liver* develops in the third week as a diverticulum of the ventral wall of the primary gut below the stomach. The bile duct and the gall bladder develop from the posterior part of the diverticulum which gives rise to the liver.

The *pancreas* develops from two rudiments, dorsal and ventral. The dorsal rudiment appears as a diverticulum on the duodenum opposite the bile duct; the ventral rudiment consists of two lateral pouches on the terminal segment of the bile duct. The dorsal diverticulum gives rise to the accessory pancreatic duct, the ventral, to the pancreatic duct; both rudiments fuse to form the body of the pancreas.

## THE HINDGUT

In a very early stage, the vitelline loop rotates about its longitudinal axis as a result of which the distal limb lies above the proximal. In an embryo 11-12 mm long (5 weeks), a protrusion, a rudiment of the caecum, forms in the initial part of the distal limb. The junction of the small and large intestine becomes detectable from this moment. When the loop rotates, its posterior end (distal limb) lies on the terminal part of the duodenal flexure and is transformed into the transverse colon. The ascending colon is still absent and the caecum is situated high above the liver; the vermiform process is also absent. The ascending colon begins growing later and the caecum gradually descends to its final position in the right iliac fossa. As an anomaly, when the ascending colon fails to develop, the caecum may remain above the iliac fossa or even under the liver. Thus, the caecum, ascending colon, and transverse colon form from the greater part of the ascending (distal) limb of the intestinal loop. The caudal segment of the primary gut is differentiated into the descending colon, sigmoid colon, and rectum (Fig. 233). This is how all the parts of the large intestine develop. The posterior end of the alimentary tube entodermal in origin, like the anterior end, at first terminates blindly; correspondingly to it at the site of the future anus an external pit appears whose floor is lined with ectoderm. The pit is separated from the gut by a cloacal membrane (*membrana cloacalis*). With further development, this membrane ruptures and the anus forms. An adjustment forms around it for closure of the anus and retention of faeces in the rectum until defaecation occurs. The adjustment

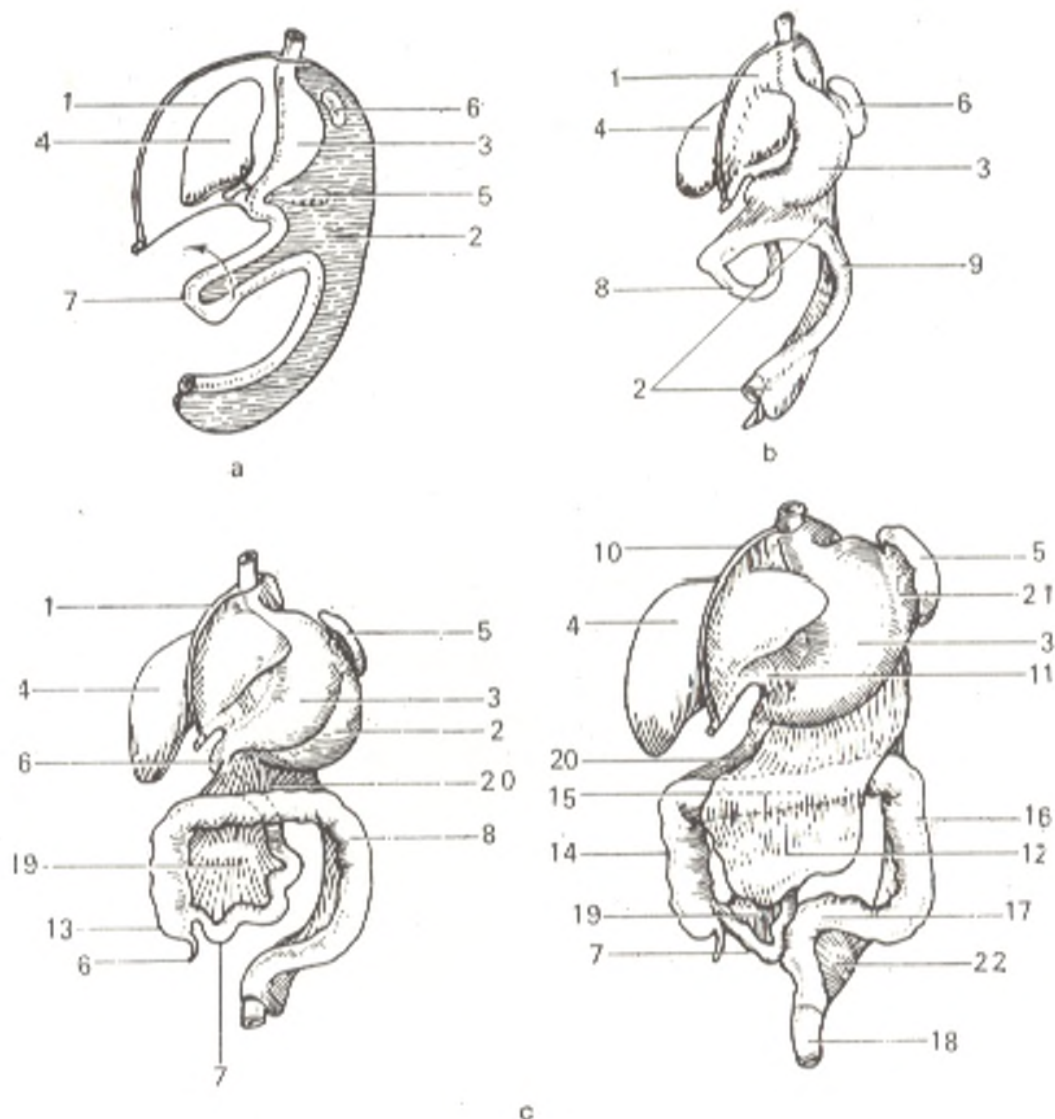


Fig. 233. Development of the stomach, intestine, and duodenum (schematic representation).

- |  |                              |
|--|------------------------------|
| a, lateral aspect (left);                                      | 6, duodenum;                 |
| b, a later stage, anterior and slightly lateral aspect (left): | 7, ileum;                    |
| 1, mesenterium ventrale;                                       | 8, intestinum crassum;       |
| 2, mesenterium dorsale;  | 9, appendix vermiformis;     |
| 3, ventriculus;  | 10, lig. falciforme hepatis; |
| 4, hepar;  | 11, omentum minus;           |
| 5, pancreas;   | 12, omentum majus;           |
| 6, (above), lien;  | 13, caecum;                  |
| 7, intestinum;   | 14, colon ascendens;         |
| 8, intestinum tenue;   | 15, colon transversum;       |
| 6, (below), intestinum crassum.                                | 16, colon descendens;        |
| c, later stages (anterior aspect):                             | 17, colon sigmoideum;        |
| 1, mesenterium ventrale;                                       | 18, rectum;                  |
| 2, mesenterium dorsale;  | 19, mesenterium;             |
| 3, ventriculus;  | 20, mesocolon transversus;   |
| 4, hepar;  | 21, lig. gastrolienale;      |
| 5, lien;   | 22, mesocolon sigmoideum     |

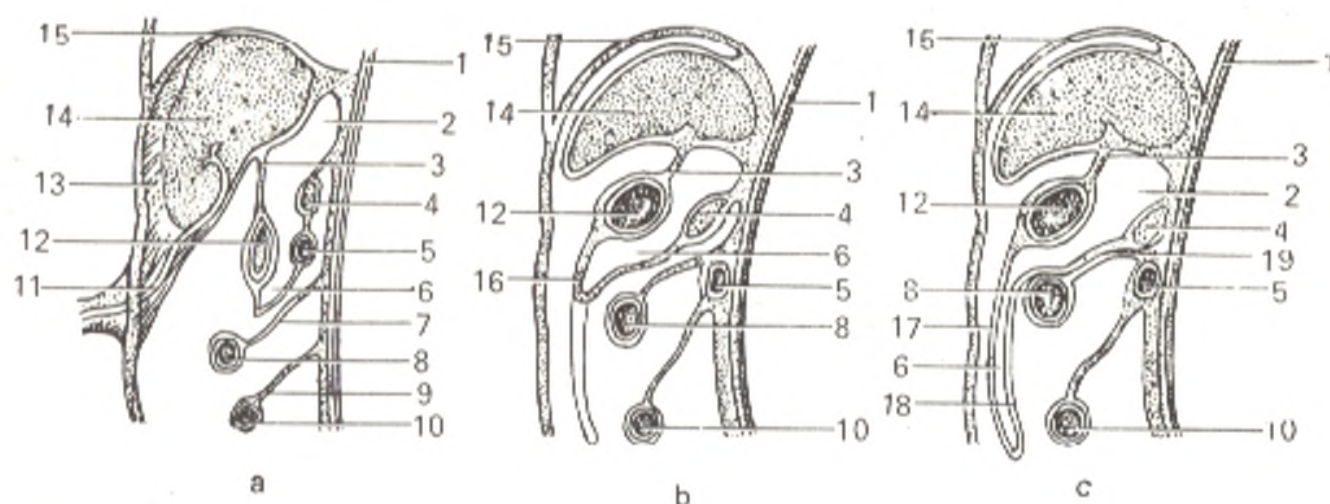


Fig. 234. Development of the great omentum and omental bursa represented schematically (after Collman and Hertwig).

- a, duodenum and pancreas invested in the mesogastrium but still not in contact with the posterior abdominal wall;  
 b, duodenum and pancreas lying on the posterior abdominal wall but the posterior wall of the omental bursa is still free;  
 c, the posterior wall of the omental bursa is fused with mesocolon transversum.
- 1, aorta;  
 2, cavity of omental bursa;  
 3, lesser omentum;  
 4, pancreas;  
 5, duodenum;  
 6, cavity of greater omentum;

- 7 mesocolon transversum;  
 8 colon transversum;  
 9 mesentery of small intestine;  
 10, small intestine;  
 11, umbilical vein;  
 12, stomach;  
 13, lig. falciforme;  
 14 liver;  
 15 diaphragm;  
 16, greater omentum;  
 17, anterior wall of greater omentum;  
 18, posterior wall of greater omentum;  
 19 fusion of posterior wall of omental bursa with mesocolon transversum

consists of two muscular sphincters, an involuntary smooth internal sphincter muscle (sphincter ani internus) developing, like all the intestinal musculature, from the mesenchyme, and a voluntary striated external sphincter muscle (sphincter ani externus) developing, like the skeletal muscles, from the mesoderm, which contributes to the formation of the pelvic diaphragm.

Knowledge of the main features of the development of the peritoneum is necessary for understanding the complicated relations of the serous coat of the abdominal cavity. The primary alimentary canal is at first suspended in the median plane from the posterior abdominal wall by means of the dorsal mesentery (*mesenterium dorsale*). Besides, in the upper part for the distance of the stomach and duodenum is a ventral mesentery (*mesenterium ventrale*), which passes from the stomach and duodenum to the liver (the future lesser omentum) and from the liver to the anterior abdominal wall and diaphragm (lig. falciforme). The part of the dorsal mesentery between the stomach and the posterior abdominal wall is called *mesogastrium dorsale*. When the stomach rotates, as it is described above, the mesogastrium is elongated, folds in two and hangs like a fold; the space between its layers gives rise to the cavity of the greater omentum, while the layers form the greater omentum.

The *greater omentum* passes separately from the transverse colon and its mesentery until the third or fourth month, but then unites with them and after fusion of the adjacent layers the final stage, encountered in the adult, occurs (Figs. 233 and 234).

As to the mesenteries of the small and large intestine, at first they form the *common mesentery* (*mesenterium dorsale commune*) as a part of the above-mentioned dorsal mesentery. When the vitelline loop of the primary gut rotates and the beginning of the large intestine is placed on the duodenum, part of the mesentery is framed by the large intestine. From this part forms the mesentery of the small intestine after the right area joined with large intestine disappears (that is why the ascending colon is devoid of the mesentery).

The mesentery of the descending colon also disappears while that of the sigmoid colon remains. An anomaly may be encountered, in which mesenterium commune persists after birth; as a result all the parts of the intestine retain their mesentery and are situated intraperitoneally.

The *peritoneal ligaments* can be subdivided into primary and secondary. The primary ligaments are derived directly from the ventral and dorsal mesenteries of the embryo and consist therefore of two layers. As it can be seen from what is said above, these are the gastrohepatic, hepatoduodenal, and falciform ligaments. The secondary ligaments form as the result of the reflection of the peritoneum from the wall to an organ (e.g. the coronary ligament of the liver) or from an organ to another organ (e.g. the hepatorenal ligament).

The *spleen* develops in the upper part of mesogastrium dorsale. Only that part of the dorsal mesentery finally remains, which is stretched between the stomach and spleen (as the gastrosplenic ligament) and between the upper end of the spleen and the diaphragm (as a small lienorenal ligament). A rare anomaly is encountered marked by a reverse or distorted position of the viscera, known as *situs viscerum inversus*, with the stomach and spleen situated on the right and the liver and caecum on the left. This anomaly is attributed to rotation of the alimentary tube in embryogenesis to the side opposite to that to which it is normally rotated.

## THE RESPIRATORY SYSTEM (SYSTEMA RESPIRATORIUM)

The respiratory organs are concerned with the supply of oxygen to the blood, by which it is brought to the tissues of the body, and with the removal of carbon dioxide into the atmosphere. In aqueous animals the gills are the organs of respiration; these are special adjustments of the primary gut. On both sides of it form gill slits on whose edges are leaflets with a great number of blood capillaries. The water passing through the slits flows around the gills as a result of which oxygen is extracted from it and enters directly into the blood, and carbon dioxide is discharged into the water. With the evolution of animals to terrestrial life respiratory organs of the aqueous type (the gills) are replaced by those of the air type (the lungs) that are adapted to respiration in the atmosphere. This replacement occurs gradually. The amphibians, for instance, breathe with the gills in a larval state but with the lungs in an adult state. In animals living on the ground, beginning with the reptiles, the gills lose their importance and become the source of the formation of other organs, while the respiratory function is accomplished by the lungs alone, which, like the gills, are derived from the primary gut<sup>1</sup>. The respiratory organs in mammals develop from the ventral wall of the foregut and retain their connection with it throughout life. This explains the existence of the intersection of the respiratory and digestive tracts in the pharynx also in man (Fig. 235), a fact mentioned above. To accomplish the act of respiration, an adjustment providing for the flow of fresh air current along the respiratory surface, i.e. the circulation of air, is necessary. In view of this, air passages exist, in addition to the lungs, namely the nasal cavity and pharynx (upper air passage) and then the larynx, trachea,

<sup>1</sup> The lungs formed phylogenetically from the air bladder of fishes, which in the ganoids and dipnoans is a paired organ communicating with the ventral surface of the oesophagus like lungs.

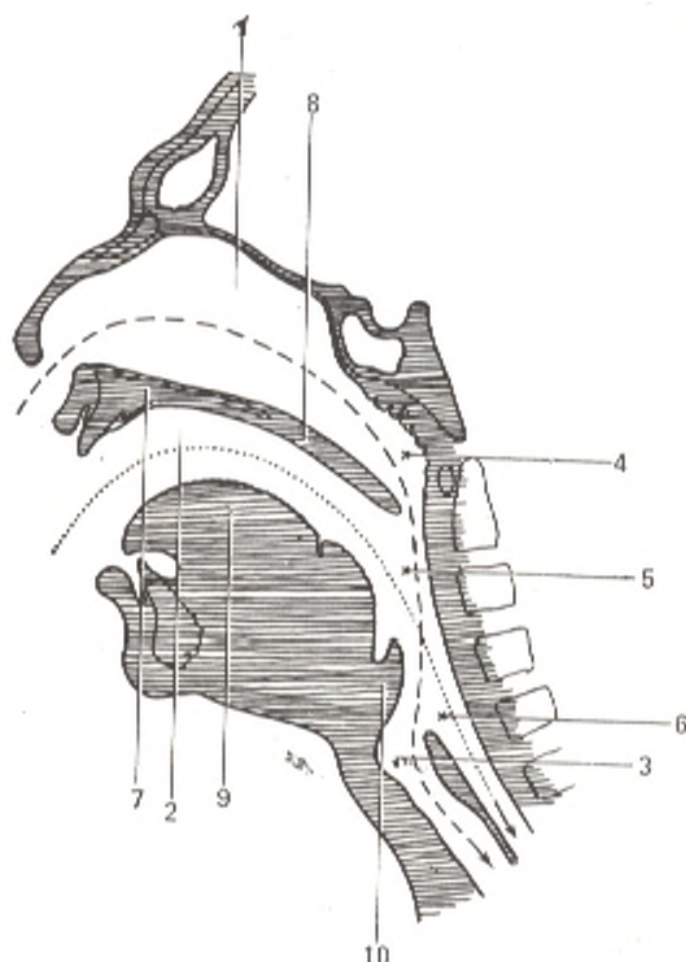


Fig. 235. Intersection of respiratory and alimentary tracts.

- 1, cavum nasi;
- 2, cavum oris;
- 3, cavum laryngis;
- 4, pars nasalis pharyngis;
- 5, pars oralis pharyngis;
- 6, pars laryngea pharyngis;
- 7, palatum durum;
- 8, palatum molle;
- 9, lingua;
- 10, epiglottis

and bronchi (the lower air passage). The formation of their walls of inflexible tissues (bone and cartilage) is a specific feature of these passages; as a result the walls do not collapse and, despite the sharp change of pressure from positive to negative, air freely circulates in both directions on inspiration and expiration.

The inspired air passes to the larynx by way of the cavity of the nose (or mouth) and the pharynx. The structure of the mouth and pharynx is described above in the chapter dealing with the digestive system, and that of the bone foundation of the nasal cavity in the chapter on osteology.

Here we shall describe the first part of the respiratory tract, the nasal cavity.

## THE CAVITY OF THE NOSE

Before coming in contact with the fine tissue of the lungs the inspired air must be cleansed of dust, warmed, and humidified. This is accomplished in the **nasal cavity** (*cavitas nasi*). There is also the **external nose** (*nasus externus*) whose skeleton is partly osseous and partly cartilaginous. As it is indicated in the chapter concerned with osteology, the cavity of the nose is separated by the nasal septum (osseous at the back and cartilaginous in front) into two symmetric halves, which communicate anteriorly with the

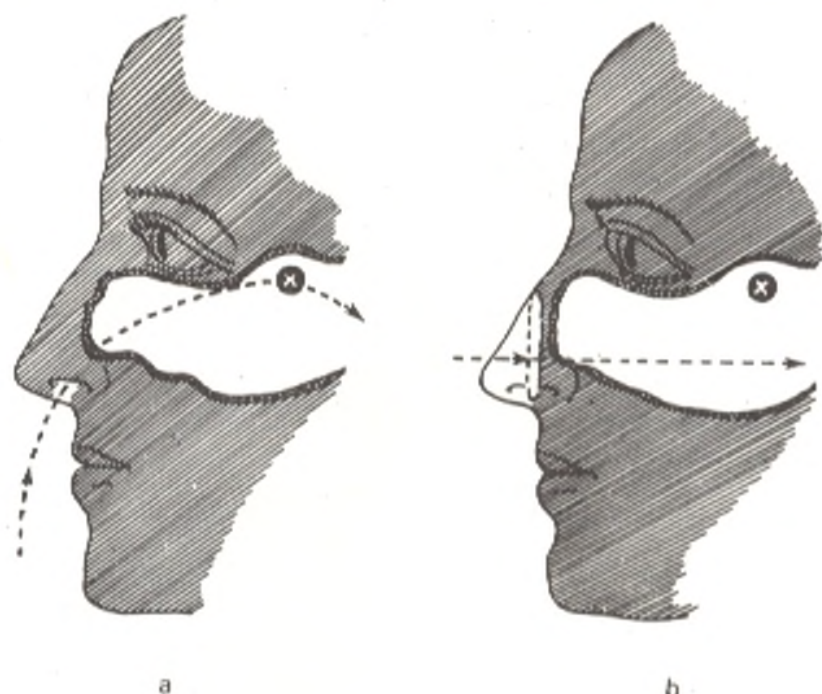


Fig. 236. Function of the nasal orifices.

*a*, the downward directed orifice of the nose deviates the air current toward the olfactory region (marked *x*); *b*, in destruction of the nostrils, the current of air passes through the inferior nasal meatus without coming in contact with the olfactory region, as the result of which the person cannot perceive odours

atmosphere through the external nose by means of the nostrils and posteriorly with the pharynx by means of the choanae. The walls of the cavity as well as the septum and conchae are lined with mucous membrane, which is continuous with the skin in the region of the nostrils and with the pharyngeal mucosa posteriorly.

The nasal mucosa contains a series of adjustments for treatment of the inspired air: (1) it is covered with ciliated epithelium whose cilia form a carpet on which dust settles. The vibration of the cilia in the direction of the choanae drives out the settled dust; (2) the mucous membrane contains mucous glands (*glandulae nasi*) whose secretions wrap around the dust and make its expulsion easier and also humidify the air; (3) the submucous tissue is rich in veins, which form thick networks (resembling cavernous bodies) on the inferior concha and the lower border of the middle concha; under different conditions these networks may swell and be the cause of nose bleeding. These structures are concerned with warming the current of air passing through the nose.

The described adjustments of the mucous membrane for the mechanical treatment of the air are situated on the level of the middle and inferior conchae and nasal passages (*meatuses*). This part of the nasal cavity is therefore called the *respiratory region* (*regio respiratoria*). In the upper part of the nasal cavity, at the level of the superior concha, is an adjustment for the control of the inspired air, namely the olfactory organ, that is why the upper part of the internal nose is called the *olfactory region* (*regio olfac-*

*toria*). The peripheral endings of the olfactory nerve, the olfactory cells composing the receptor of the olfactory analyser, are embedded here (see Vol. II). A person cannot perceive odours when his nostrils are destroyed by some pathological process and the current of inspired air is directed along the inferior nasal passage, i.e. does not come in contact with the olfactory region (Fig. 236). An additional adjustment for ventilation of the air are the *paranasal sinuses* (*sinus paranasales*), which are also lined with mucous membrane, a direct continuation of the nasal mucosa. These are the structures described in the chapter "Osteology": (1) the maxillary sinus (*sinus maxillaris* s. *Highmori*) whose orifice (wide on a skelitized skull) is closed by mucous membrane except for a small slit; (2) the frontal sinus (*sinus frontalis*); (3) the air spaces of the ethmoid bone (*cellulae ethmoidales*) composing the ethmoidal sinus (*sinus ethmoidalis*); (4) the sphenoidal sinus (*sinus sphenoidalis*).

On inspection of the nasal cavity of a live person (rhinoscopy) the mucous membrane is pink. The nasal conchae, nasal passages (meatuses), air spaces of the ethmoid bone, and the orifices of the frontal and maxillary sinuses are visible. The conchae and paranasal sinuses increase the surface of the mucous membrane, contact with which improves the treatment of the inspired air. Free circulation of air, necessary in breathing, is ensured by the inflexibility of the walls of the nasal cavity composed of bones (see "Osteology") complemented by cartilages.

The *cartilages of the nose* are remnants of the cartilaginous nasal capsule and are hyaline in structure. The unpaired cartilage of the nasal septum, *septal cartilage* (*cartilage septi nasi*) is a component of the anterior part of the septum, its posterior edge adjoining the vomer and the anterior edge, the perpendicular plate of the ethmoid bone. The other cartilages are paired. The *upper nasal cartilage* (*cartilago nasi lateralis*) is a triangular plate in the middle part of the side of the nose. It forms the foundation of the dorsum of the nose. The *lower and small cartilages of the nose* (*cartilago alaris major and cartilago alaris minor*) form the cartilaginous foundation of the ala, the nostril, and the movable part of the septum. The bones and cartilages, covered with skin, form the *external nose* (*nasus externus*). In it are distinguished the *root* (*radix nasi*), which is at the top, the *apex* (*apex nasi*) directed downward, and two lateral walls, which unite to form the *dorsum of the nose* (*dorsum nasi*) facing anteriorly. The inferior parts of the lateral walls separated by grooves form the *alae of the nose* (*alae nasi*) whose inferior margins bind the nostrils, or nares, through which air passes into the nasal cavity. The nostrils of all animals, including primates, are directed to the front, while the nostrils of man, in distinction, are directed downward. As a result, the current of inspired air instead of passing straight to the back, like in monkeys, flows upward to the olfactory region and follows a long and arched path to the nasopharynx, which facilitates its treatment. The expired air passes on a straight line in the inferior nasal meatus. The protruding nose is, in general, a specific feature of man because even anthropoid apes do not have a nose; this is evidently linked with the upright position of the human body and the changes in the facial skeleton due to the

weaker masticating activity, on the one hand, and to the development of speech, on the other.

The main artery supplying the walls of the nasal cavity is the sphenopalatine artery (from the maxillary artery). The anterior and posterior ethmoidal arteries (from the ophthalmic artery) branch out in the anterior part of the cavity. The veins of the external nose drain into the facial and ophthalmic veins; those carrying blood from the mucous membrane of the nasal cavity drain into the sphenopalatine vein, which in turn drains into the pterygoid process through the sphenopalatine foramen. The lymphatic vessels carrying lymph from the external ear and nostrils drain into the submandibular, mandibular, and submental lymph nodes. The nerves of the external nose, and those of the nasal cavity are related to the region of the branching of the first and second divisions of the trigeminal nerve. The mucosa of the anterior part of the nasal cavity is innervated from the anterior ethmoidal nerve (originating from the nasociliary nerve of the first division of the trigeminal nerve), while the remaining part of the mucosa (that of the concha and septum) receives innervation from the sphenopalatine ganglion, second division of the trigeminal nerve (the posterior nasal nerves), and the long sphenopalatine nerve.

The inspired air passes from the nasal cavity through the choanae into the nasopharynx, into the oral part of the pharynx, and then into the larynx. Respiration can also occur through the mouth, but the absence in the oral cavity of adjustments for controlling and treating the air causes frequent development of diseases in such instances. (Some animals, for instance rabbits, die of infection if they are forced to breathe through the mouth by plugging the nostrils with cotton wool). It is therefore necessary to see to it that breathing occurs through the nose.

## THE LARYNX

The larynx (Figs. 237 and 238) is situated on the level of the fourth, fifth, and sixth cervical vertebrae immediately below the hyoid bone, on the anterior surface of the neck and form here a clearly visible eminence. To the back of it is the pharynx with which it communicates directly through an opening called the inlet of the larynx (*aditus laryngis*). On both sides of the larynx pass large vessels of the neck while in front it is covered with muscles of the infrahyoid group (sternohyoid, sternothyroid, and omohyoid muscles), the cervical fascia, and the superior parts of the lateral lobes of the thyroid. Below the larynx is continuous with the trachea.

The human larynx is an amazing musical instrument, a combination of a wind instrument and stringed instrument. The air expired through the larynx causes vibration of the vocal cords, which are stretched tight like strings. As a result a sound forms. Unlike musical instruments, in the larynx the degree of stretching of the strings and the size and shape of the cavity, in which the air circulates, alter due to contraction of the muscles of the oral cavity, tongue, pharynx and the larynx itself; the contraction of the muscles is controlled by the nervous system. In this man differs from the anthropoids who are absolutely incapable of regulating the current of the expired air that is necessary in singing and speaking. Only the gibbon can to some measure produce musical sounds with its voice ("the scale of the gibbon"). Besides, "vocal sacs", continuing under the skin and serving as



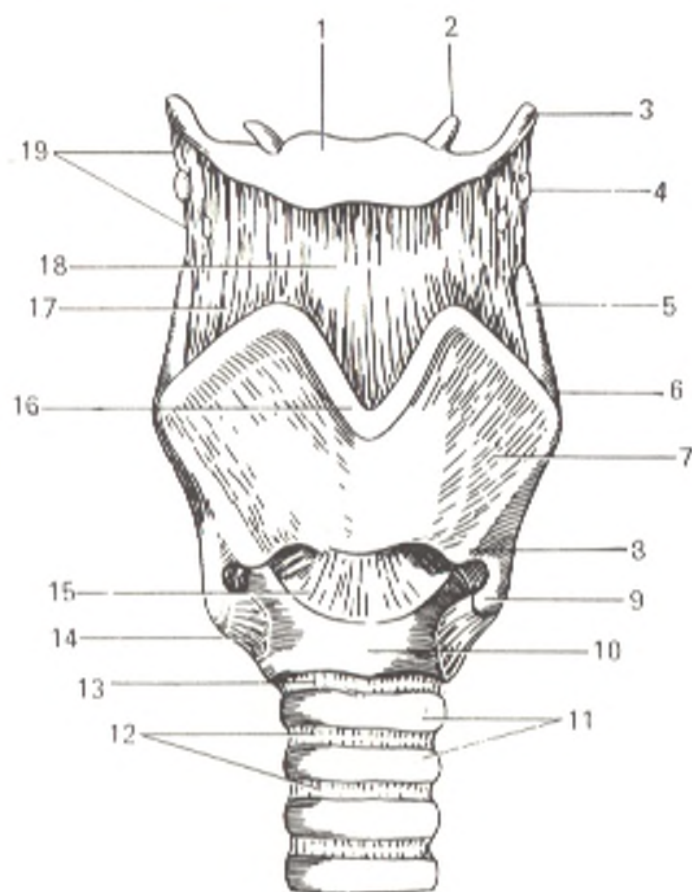


Fig. 237. Ligaments and joints of the larynx, anterior aspect (after Sinelnikov).

- 1, os hyoideum;
- 2, cornu minus ossis hyoidei;
- 3, cornu majus ossis hyoidei;
- 4, cartilago triticea;
- 5, cornu superius cartilaginis thyroideae;
- 6, tuberculum thyroideum superius;
- 7, cartilago thyroidea;
- 8, tuberculum thyroideum inferius;
- 9, cornu inferius cartilaginis thyroideae;
- 10, cartilago cricoidea;
- 11, cartilagine tracheales;
- 12, ligamenta anularia (trachealia);
- 13, lig. cricotracheale;
- 14, lig. ceratocricoidaeum anterius;
- 15, lig. cricothyroideum medium;
- 16, incisura thyroidea superior;
- 17, membrana thyrohyoidea;
- 18, lig. thyrohyoideum medianum;
- 19, lig. thyrohyoideum laterale

resonators, are greatly developed in the monkeys. In man they are rudimentary structures (ventricles of the larynx). Thousands of years were needed for the undeveloped larynx of the monkey to be transformed into the human larynx by gradually intensifying modulations and "the organs of the mouth gradually learned to pronounce one articulate letter after another".<sup>1</sup>

Being a peculiar musical instrument, the larynx is at the same time built according to the principle of a motor apparatus and is therefore marked by a skeleton in the form of cartilages, unions in the form of ligaments and articulations, and muscles which move the cartilages as a result of which the size of the rima vocalis and the degree of stretching of the vocal cord change.

## CARTILAGES OF THE LARYNX

The **cricoid cartilage** (*cartilago cricoidea*) is hyaline and shaped like a signet ring with a wide *plate* (*lamina*) at the back and an *arch* (*arcus*) in front and on the sides. The border of the lamina and its lateral surface bear articular fossae for uniting with the arytenoid and thyroid cartilages.

The **thyroid cartilage** (*cartilago thyroidea*) is the largest of the laryngeal cartilages; it is hyaline in structure and consists of two laminae, which fuse

<sup>1</sup> F. Engels. *Dialectics of Nature*. Foreign Languages Publishing House, Moscow, 1954, p. 232.

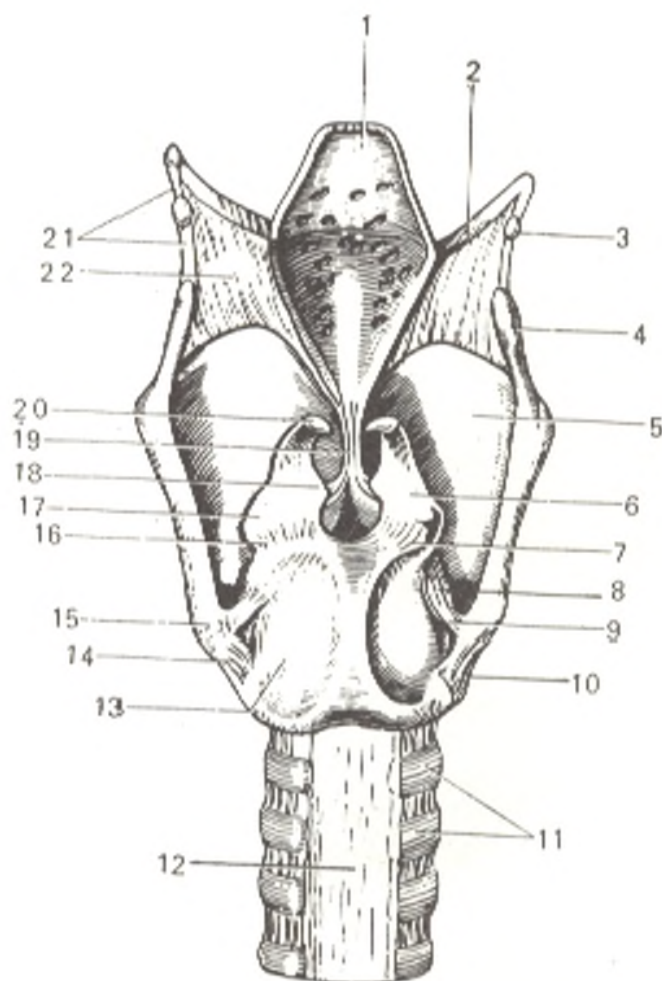


Fig. 238. Ligaments and joints of the larynx, posterior aspect (after Sinelnikov).

- 1, epiglottis;
- 2, cornu majus ossis hyoidei;
- 3, cartilago triticea;
- 4, cornu superius cartilaginis thyroideae;
- 5, cartilago thyroidea (lamina dextra);
- 6, cartilago arytenoidea;
- 7 and 14, art. cricoarytenoidea (dext. and sin.);
- 8, lig. ceratocricoidae posterius;
- 9, cartilagine tracheales;
- 10, paries membranaceus tracheae;
- 11, cartilago cricoidea (lamina);
- 12, cornu inferius cartilaginis thyroideae;
- 13, processus muscularis cartilaginis arytenoideae;
- 15, processus vocalis cartilaginis arytenoideae;
- 16, processus vocalis cartilaginis arytenoideae;
- 17, lig. thyroepiglotticum;
- 18, cartilago corniculata;
- 19, lig. thyrohyoideum laterale;
- 20, membrana thyrohyoidea

in front at an angle. The site of union of the laminae in children and females is rounded and there is, therefore, no conspicuous prominence in them as in adult males (Adam's apple). In the superior border on the midline is the *thyroid notch* (*incisura thyroidea superius*). The posterior, thickened border of each plate is continuous with a larger *superior horn* (*cornu superius*) and a shorter *inferior horn* (*cornu inferius*). The inferior horn bears on the inner surface of its apex an area for articulating with the cricoid cartilage. An oblique line (*linea obliqua*) is visible on the outer surface of each lamina; it descends from the posterior part of the superior border of the cartilage obliquely and medially (the site of attachment of the sternothyroid and thyrohyoid muscles).

The **arytenoid cartilages** (*cartilagine arytenoideae*) are directly related to the vocal cords and muscles. They are pyramidal in shape with the *base* (*basis*) sitting on the superior border of the cricoid cartilage while the *apex* faces upward. Of the three surfaces of the arytenoid cartilage, the dorsal is concave and the transverse arytenoid muscle lies on it. The medial surface is covered by the laryngeal mucosa. The anterolateral surface is the largest of the three surfaces. Two processes arise from the base: (1) an anterior process (of elastic cartilage) is the site of attachment of the vocal cord and is therefore called vocal (*processus vocalis*) and (2) a lateral, muscular, process

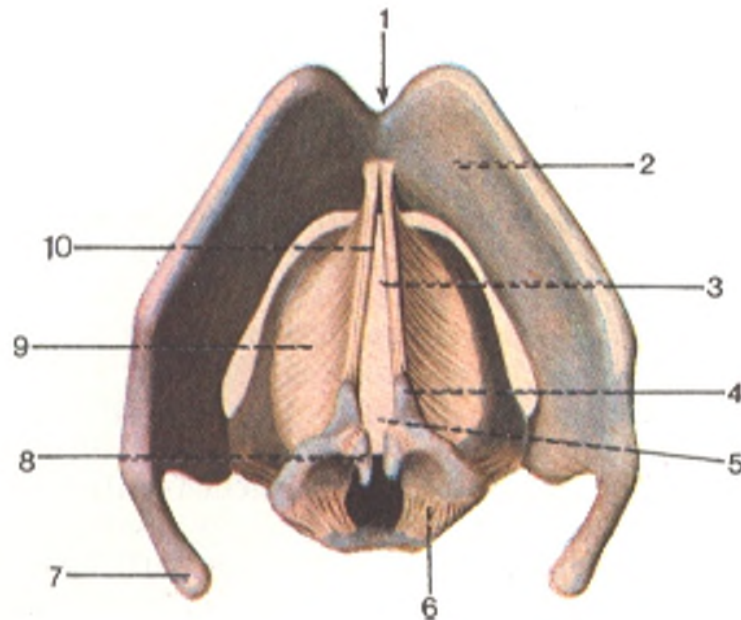


Fig. 239. Elastic cone of larynx and the vocal cords (seen from above).

- |   |   |
|---|---|
| 1, incisura thyroidea superior;             | 6, ligaments of art. cricoarytenoidea;    |
| 2, cartilago thyroidea;                     | 7, cornu superius cartilaginis thyroidea; |
| 3, rima glottidis (pars intermembranacea);  | 8, cartilago corniculata;                 |
| 4, processus vocalis;                       | 9, conus elasticus;                       |
| 5, rima glottidis (pars intercartilaginea); | 10, lig. vocale                           |

(of hyaline cartilage) for the attachment of muscles (*processus muscularis*).

The **corniculate cartilages** (*cartilagine corniculatae*) are seated on the apices of the arytenoid cartilages in the thickness of the aryepiglottic folds.

The **cuneiform cartilages** (*cartilagine cuneiformes*) are directly in front of the corniculate cartilages, also in the aryepiglottic folds. Sometimes they are absent.

The **epiglottis cartilage** (*cartilago epiglottica*) is a leaf-shaped lamina of elastic cartilaginous tissue situated in front of aditus laryngis and directly behind the root of the tongue. It narrows downward to form the *stalk of the epiglottis* (*petiolus epiglottidis*). The opposite wide end faces upward. The convexoconcave dorsal surface facing the larynx is entirely covered with mucous membrane; the inferior concave part protrudes into the laryngeal cavity and is called the *epiglottic tubercle* (*tuberculum epiglotticum*). The anterior, or ventral, surface facing the tongue has no ligaments attached to it only in its upper part (Figs. 237, 238, and 239).

## LIGAMENTS AND JOINTS OF THE LARYNX

The larynx appears to be suspended from the hyoid bone on the **thyroid membrane** (*membrana thyreohyoidea*) stretching between this bone and the thyroid cartilage (see Figs. 237 and 238). The membrane consists of an unpaired *median thyrohyoid ligament* (*lig. thyreohyoideum medianum*) and the paired *lateral thyrohyoid ligaments* (*ligamenta thyreohyoideum*) stretched

between the ends of greater horns of the hyoid bone and the superior horns of the thyroid cartilage in the thickness of which a small *cartilago triticea*, resembling a grain of wheat, is embedded. The hyoid bone is also connected with the epiglottis by the **hyoepiglottic ligament** (*lig. hyoepiglotticum*); the epiglottis is in turn attached to the thyroid cartilage by the **thyroepiglottic ligament** (*lig. thyroepiglotticum*).

Between the arch of the cricoid cartilage and the margin of the thyroid cartilage stretches on the midline a strong **cricothyroid ligament** (*lig. cricothyroideum*) composed of elastic fibres. The lateral fibres arising from the superior margin of the cricoid cartilage pass medially and unite posteriorly with the arytenoid cartilage; these bundles together with the cricothyroid ligament form the **cricovocal membrane** (*conus elasticus*) which narrows toward the top; its superior free margin is the **vocal ligament** (*lig. vocale*).

The **vocal ligament** (*lig. vocale*) is attached anteriorly to the angle of the thyroid cartilage in close vicinity to its contralateral fellow, and posteriorly to the vocal process of the arytenoid cartilage. The ligament is formed of yellowish elastic fibres passing parallel to one another. Children and young boys have in addition intersecting elastic fibres, which disappear in adults. The medial margin of the vocal ligament is pointed and free; laterally and downward the ligament is continuous with the cricovocal membrane mentioned above (Fig. 239).

Above and parallel to the vocal ligament is the paired **vestibular ligament** (*lig. vestibulare*). It is so called because it bounds inferiorly the vestibule of the larynx.

Besides ligaments, there are *joints* between the cartilages at the junction of the thyroid and arytenoid cartilages with the cricoid cartilage.

1. The paired combined **cricothyroid joint** (*art. cricothyroidea*) forms between the inferior horns of the thyroid cartilage and the cricoid cartilage; it has a transverse pivotal axis. In this joint the thyroid cartilage moves forward and to the back, drawing further away from or coming nearer to the arytenoid cartilages. As a result the vocal ligament stretched between them is now tensed (when the thyroid cartilage is tilted forward), now relaxed.

2. The paired **cricoarytenoid joints** (*articulationes cricoarytenoideae*) form between the base of each arytenoid cartilage and the cricoid cartilage; it has a vertical axis about which the arytenoid cartilage accomplishes lateral rotation. Sliding movements, with the arytenoid cartilages now coming together now moving apart, can also occur in this joint.

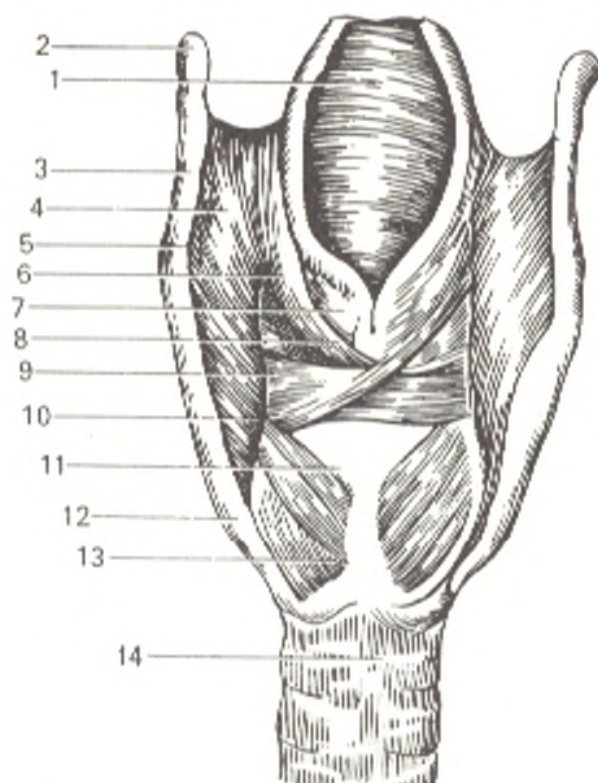
3. The corniculate cartilages articulate with the apices of the arytenoid cartilages by means of small joints or **symphyses** (*synchondrosis arycorniculata*).

## MUSCLES OF THE LARYNX

The *muscles of the larynx* (Figs. 240 and 241) move its cartilages and thus change the width of its cavity and the width of the rima glottidis bounded by the vocal ligaments. According to function, they may, therefore, be grouped as follows: (1) constrictors; (2) dilators; (3) muscles altering the

Fig. 240. Muscles of the larynx (posterior aspect).

- 1, epiglottis;
- 2, cornu majus ossis hyoidel;
- 3, lig. thyrohyoideum;
- 4, membrana thyrohyoidea;
- 5, cornu superius cartilaginis thyroidea;
- 6 and 8, m. aryepiglotticus;
- 7, cartilago arytenoidea;
- 9, m. arytenoideus transversus;
- 10, processus muscularis cartilaginis arytenoidea;
- 11, cartilago cricoidea;
- 12, cornu inferius cartilaginis thyroideae;
- 13, m. cricoarytenoideus posterior;
- 14, trachea



tension of the vocal ligaments. Some of the muscles can be related to more than one group because of their mixed character. The following muscles form the first group.

The lateral cricoarytenoid muscle (*m. cricoarytenoideus lateralis*) originates on the arch of the cricoid cartilage, passes upward and to the

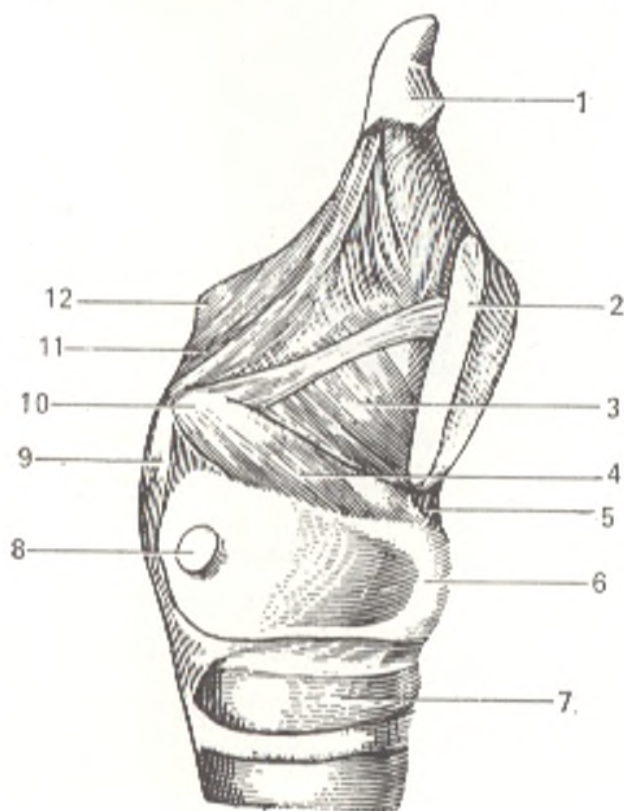


Fig. 241. Muscles of the larynx (lateral aspect).

- 1, epiglottis;
- 2, cartilago thyroidea (divided);
- 3, m. thyroarytenoideus;
- 4, m. cricoarytenoideus lateralis;
- 5, lig. cricothyroideum;
- 6, cartilago cricoidea;
- 7, trachea;
- 8, articular fossa of cricoid cartilage;
- 9, m. cricoarytenoideus posterior;
- 10, proc. muscularis cartilaginis arytenoideae;
- 11, m. aryepiglotticus;
- 12, cartilago corniculata

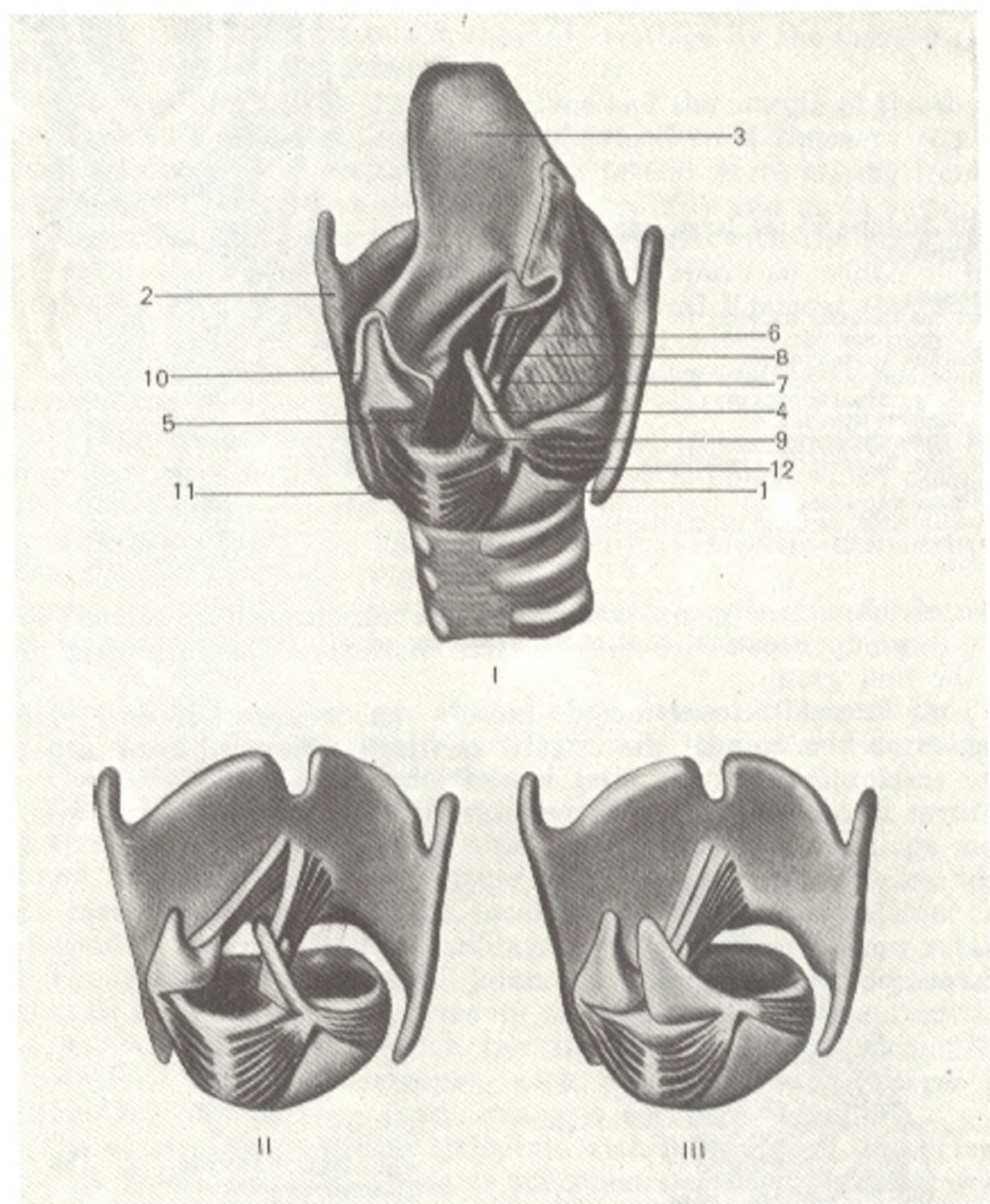


Fig. 242. Semischematic representation of the larynx.

*I*, posterior view:  
 1, cricoid cartilage;  
 2, thyroid cartilage;  
 3, epiglottis;  
 4, right arytenoid cartilage;  
 5, rima glottidis;  
 6, vocal ligament;  
 7, vocal process of arytenoid cartilage;  
 8, muscle relaxing the vocal ligament;

9, muscular process of arytenoid cartilage;  
 10, mucous membrane covering the larynx;  
 11, posterior cricoarytenoid muscle;  
 12, lateral cricoarytenoid muscle.  
*II* and *III*, mechanism of vocal apparatus adjustment

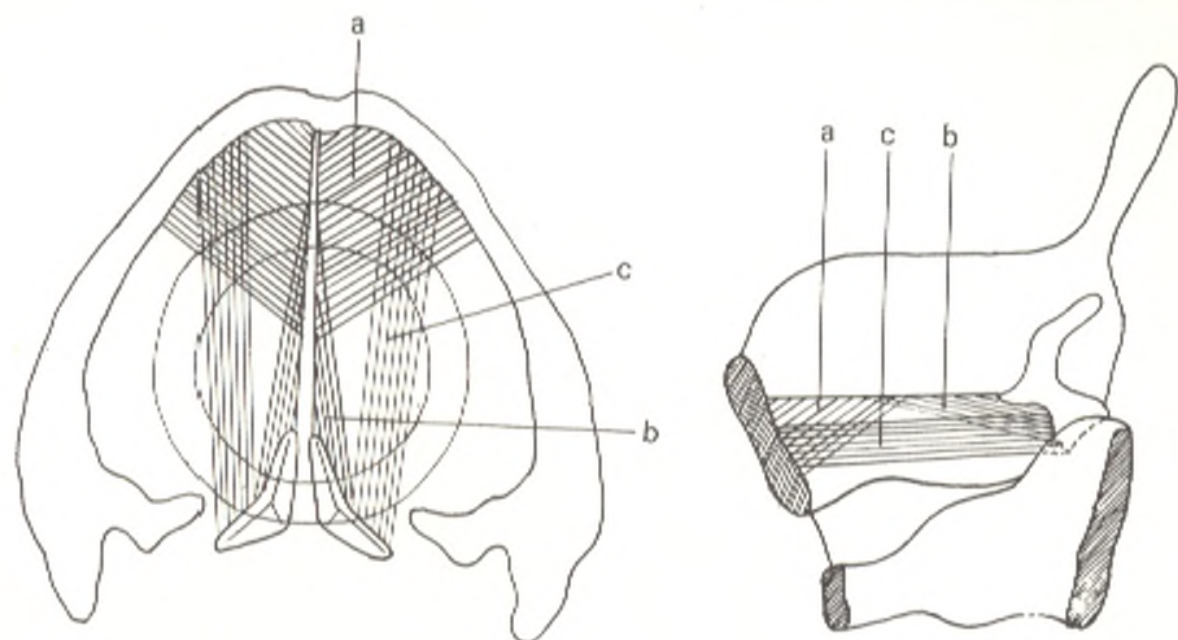


Fig. 242A. Schematical representation of parts (a, b, c) of vocalis muscle.

back, and is inserted on the muscular process of the arytenoid cartilage. It pulls the muscular process forward and downward as the result of which the vocal process swings medially, the vocal ligaments approximate and the opening between them becomes narrower (in which instance the vocal ligaments are rather tensed).

The **thyroarytenoid muscle** (*m. thyrecarytenoideus*) is quadrate in shape. It originates from the inner surface of the laminae of the thyroid cartilages, passes posteriorly and upward, and is inserted into the muscular process of the arytenoid cartilage. On contraction of the muscles on both sides, the part of the laryngeal cavity directly above the vocal ligaments (*regio supraglottica*) narrows and at the same time the vocal process is pulled ventrally as the result of which the vocal ligaments slightly relax.

The **transverse arytenoid muscle** (*m. arytenoideus transversus*) is an unpaired muscle lying on the dorsal concave surfaces of the arytenoid cartilages. On contraction it approximates the arytenoid cartilages and thus narrows the posterior part of the rima glottidis.

The **oblique arytenoid muscles** (*mm. arytenoidei obliqui*) are a pair of muscle fascicles lying directly behind the transverse muscle and intersecting one another at an acute angle. At the apex of the arytenoid cartilage the oblique muscle is continuous with muscle fascicles, which pass forward and upward in the aryepiglottic fold and are inserted on the margin of the epiglottis, thus forming the aryepiglottic muscle. On simultaneous contraction, the oblique arytenoid and aryepiglottic muscles narrow the laryngeal inlet and vestibule. The aryepiglotticus muscle also pulls the epiglottis downward.

The group of dilators is formed of the following muscles.

The **posterior cricoarytenoid muscle** (*m. cricoarytenoideus posterior*) is triangular in shape. It lies on the dorsal surface of the lamina of the cricoid cartilage and is inserted on the muscular process. On contraction it pulls the muscular process posteriorly and medially so that the vocal process swings laterally and the rima glottidis becomes wider.

The **thyroepiglottic muscle** (*m. thyroepiglotticus*) is situated laterally of the thyroepiglottic ligament. It originates from the inner surface of the lamina of the thyroid cartilage and is inserted on the margin of the epiglottis and is partly continuous with the aryepiglottic fold. It acts as the dilator of the laryngeal inlet and vestibule.

The muscles related to the group, which alters the tensivity of the vocal ligaments, are as follows.

The **cricothyroid muscle** (*m. cricothyreoideus*) is short but rather thick. It arises from the arch of the cricoid cartilage and is inserted on the lamina and inferior horn of the thyroid cartilage. The cricothyroid muscle tenses the vocal ligaments by pulling the thyroid cartilage forward. As a result the distance between the cartilage and the vocal process of the arytenoid cartilage increases.

The **vocalis muscle** (*m. vocalis*) is embedded in the vocal fold and closely adjoins the vocal ligament. Its fibres blend laterally with the fibres of the thyroarytenoid muscle. It originates from the inferior part of the angle of the thyroid cartilage and, passing posteriorly, is inserted on the lateral surface of the vocal process. On contraction it pulls the vocal process forward causing the vocal ligaments to relax (Fig. 242).

According to the latest data, the main constrictors of the rima glottidis are the cricothyroid muscles, while its main dilators are the posterior cricoarytenoid muscles. All these muscles are innervated from the vagus nerve, but from its different branches: the former from the superior and the latter from the inferior laryngeal nerves.

The transverse and oblique arytenoid and the lateral cricoarytenoid muscles are assistant muscles and each receives motor innervation from both of the above-named nerves.

In the group of muscles regulating the vocal ligaments, the vocal and thyroarytenoid muscles are relaxers, while the cricothyroid muscle is a tensor. They are innervated similarly, but from different laryngeal nerves: the relaxers from the inferior and the tensors from the superior laryngeal nerves.

Muscles regulating the mobility of the larynx, the aryepiglottic, oblique arytenoid, and thyroepiglottic, are innervated in the same manner as the assistant muscles, i.e. each is supplied with nerve fibres from the superior and inferior laryngeal nerves.

## THE CAVITY OF THE LARYNX

The **cavity of the larynx** (*cavum laryngis*) opens by means of an *inlet of the larynx* (*aditus laryngis*) bounded anteriorly by the free margin of the epiglottis, posteriorly by the apices of the arytenoid cartilages and the fold of mucosa, interarytenoid fold (*plica interarytenoidea*) stretching between them, and laterally by mucosal folds stretched between the epiglottis and the arytenoid cartilages, the aryepiglottic fold (*plica aryepiglottica*). The cavity itself resembles an hourglass in shape; it is narrowed in the middle but expands upward and downward. The upper, expanded part of the cavity



is called the *vestibule of the larynx* (*vestibulum laryngis*). It extends from the laryngeal inlet to a paired mucosal fold on the lateral wall of the cavity; this is the *vestibular fold* (*plica vestibularis*), or the false vocal cord, in the thickness of which is the vestibular ligament. The walls of the vestibule are formed: anteriorly, by the dorsal surface of the epiglottis, posteriorly, by the upper parts of the arytenoid cartilages and the interarytenoid fold, and laterally, by a paired *elastic membrane of the larynx* (*membrana fibroelastica laryngis*) extending from the vestibular fold to the aryepiglottic fold.

The middle, constricted part of the laryngeal cavity is most complex in structure. It is bounded above and below by mucosal folds situated on the lateral walls of the larynx. The upper fold is the paired vestibular fold mentioned above. The free margins of these folds form the boundaries of an unpaired rather wide *rima vestibuli*. The lower, *vocal fold* (*plica vocalis*), or true vocal cord, protrudes into the cavity more than the upper fold does and contains the vocal ligament and the vocal muscle. The recess between the vestibular and vocal folds is the *sinus of the larynx* (*ventriculus laryngis*).

A sagittally lying fissure of the glottis, *rima glottidis*, is formed between the two vocal folds; it is the narrowest part of the laryngeal cavity. In it are distinguished an anterior, larger part between the folds themselves, the *intermembranous part* (*pars intermembranacea*), and a posterior, smaller one, between the vocal processes of the arytenoid cartilage, the *intercartilaginous part* (*pars intercartilaginea*).

The lower expanded part of the larynx, the *infraglottic cavity* (*cavum infraglotticum*) gradually narrows inferiorly and is continuous with the trachea.

The shape of the *rima glottidis* and the changes in it can be seen in a live person during laryngoscopy (examination of the larynx with a laryngeal mirror). During the act of phonation (the formation of vocal sounds), the intermembranous part takes the shape of a narrow fissure, while the intercartilaginous part becomes triangular; in quiet breathing, the intermembranous part widens and the whole *rima glottidis* is shaped like a triangle with the base lying between the arytenoid cartilages (Fig. 243). On inspection, the laryngeal mucosa is smooth, evenly pink, and with no changes in its relief or mobility. In the region of the vocal cords the mucosa is pink, in the region of the vestibular folds it is reddish.

The laryngeal mucosa above the vocal cords is highly sensitive; a foreign body coming in touch with it induces immediately a reaction in the form of severe coughing.

Vocal sounds are produced during expiration as the result of vibration of the vocal cords. Until recently it was thought that the vocal cords vibrate under the effect of the respiratory air stream absolutely passively, just like a flag waving in the wind. It has been recently established, however, that due to the close relationship with the vocal muscle the human vocal cords contract actively under the effect of rhythmic impulses arriving along nerves from the cerebral centres with sound frequency. It is not that the air causes vibration of the vocal cords, on the contrary, it is the vocal cords that on vibrating rhythmically impart the air stream a vibrating character.

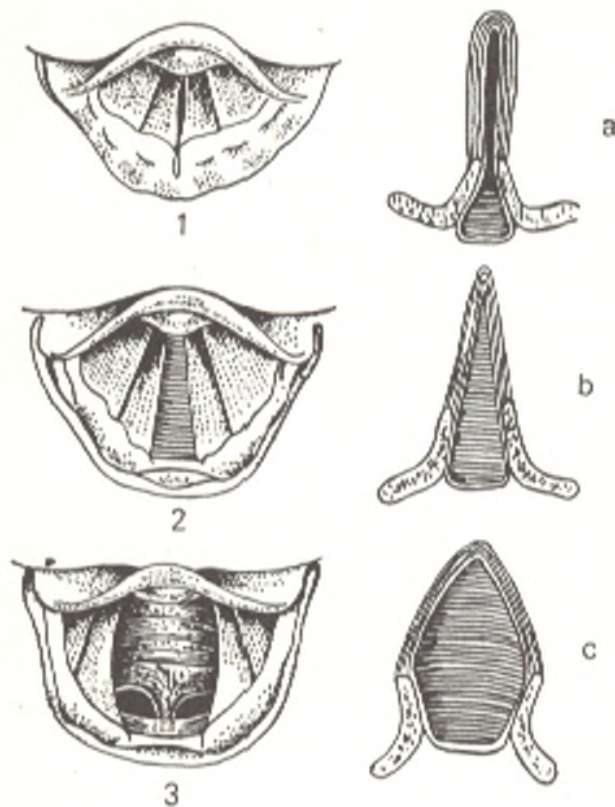


Fig. 243. View of the larynx in different states of the rima glottidis.

- 1, rima glottidis in singing on a high note;  
 2, rima glottidis in quiet inspiration of air;  
 3, maximum dilation of rima glottidis in very deep inspiration;  
 a, b, and c, horizontal sections of rima glottidis, vocal cords, and arytenoid cartilages in all the three cases

The sound produced by the vocal cords has, in addition to the main tone, a series of overtones. This "cord-produced" tone, however, still in no way resembles the sounds of a voice; the voice acquires the natural human timbre only due to a system of resonators. Since nature is a very economical constructor, the role of the resonators is played by the different air cavities of the respiratory tract, which surround the vocal cords. The larynx and the oral cavity are the most important resonators.

*The vessels and nerves.* The arteries are the superior and inferior laryngeal arteries (from the superior and inferior thyroid arteries). *Venous blood* is drained by way of plexuses into the superior and inferior laryngeal veins. The *lymph* is drained into the deep cervical lymph nodes. The larynx is *innervated* by the superior and inferior laryngeal nerves (from the vagus nerve) and the sympathetic trunk.

## THE TRACHEA

The **trachea** is a continuation of the larynx. It begins at the level of the lower border of the sixth cervical vertebra and terminates at the level of the upper border of the fifth thoracic vertebra by separating into two bronchi, right and left. The place of the separation is called the bifurcation of the trachea (*bifurcatio tracheae*). The length of the trachea ranges from 9 to 11 cm, the transverse diameter from 15 to 18 mm on the average.

**Topography of the trachea.** The cervical segment is embraced above by the thyroid gland. Posteriorly the trachea is related to the oesophagus, while on both sides of it stretch the common carotid arteries. Anteriorly the trachea is covered by the isthmus of the thyroid gland and the sterno-

hyoid and the sternothyroid muscles, except for the midline where the medial borders of these muscles diverge. The space between the posterior surfaces of these muscles with the fascia covering them and the anterior surface of the trachea is called the pretracheal space (*spatium pretracheale*) and is filled with loose pretracheal fat and blood vessels of the thyroid gland (the lowest thyroid artery and venous plexus). The thoracic segment of the trachea is covered in front by the manubrium sterni, remnants of the thymus, and by vessels. The position of the trachea in front of the oesophagus is associated with its development from the ventral wall of the foregut. In persons with a narrow chest and a narrow superior aperture, the level of the tracheal bifurcation corresponds to that of the fourth thoracic vertebra. In contrast, in individuals with a wide superior aperture of the thorax, the bifurcation is on the level of the fifth thoracic vertebra in most females, whereas in males it is usually on the level between the fifth and sixth vertebrae.

The projection of the bifurcation on the anterior thoracic wall corresponds in adults to the level of the second-third ribs.

**Structure of the trachea.** The trachea is formed of 16 to 20 incomplete rings of cartilage (*cartilagine tracheales*) united by means of fibrous annular ligaments (*ligamenta anularia*); each ring extends only over two thirds of the circumference. The posterior, membranous wall of the trachea (*paries membranaceus*), is flat and contains transverse and longitudinal fascicles of smooth muscle tissue, which cause active movement of the trachea in respiration, coughing, etc. The mucous membrane of the larynx (with the exception of that of the vocal cords and part of the epiglottis) and trachea is covered with ciliated epithelium and is rich in lymphoid tissue and mucous glands.

**Vessels.** The trachea is supplied with *arteries* from the inferior thyroid and internal thoracic arteries as well as from the bronchial branches of the thoracic aorta. *Venous blood* drains into venous plexuses surrounding the trachea and particularly into the veins of the thyroid gland. The *lymphatic vessels* of the trachea on its entire length pass to two chains of nodes arranged on both sides of it (tracheal nodes). Besides, lymphatics from the upper segment pass to the prelaryngeal and the superior deep cervical nodes, those from the middle segment to the last named and the subclavian nodes, and from the lower segment to the anterior mediastinal nodes.

The *nerves* of the trachea arise from the sympathetic trunk and the vagus nerve, as well as from a vagal branch, the inferior laryngeal nerve.

## THE BRONCHI

The **principal bronchi** (*Gk bronchos* windpipe), right and left (*bronchi principales dexter* and *sinister*) arise from the tracheal bifurcation almost at a right angle and pass to the hilum of the corresponding lung. The right bronchus is a little larger than the left because of the larger volume of the right lung. At the same time, the left bronchus is almost twice the length of the right and contains 9 to 12 cartilaginous rings while the right bronchus is formed of 6 to 8 rings. The right bronchus takes a more vertical direction than the left and is as if a continuation of the trachea. The azygos vein passing to the vena cava superior crosses the right bronchus like an arch

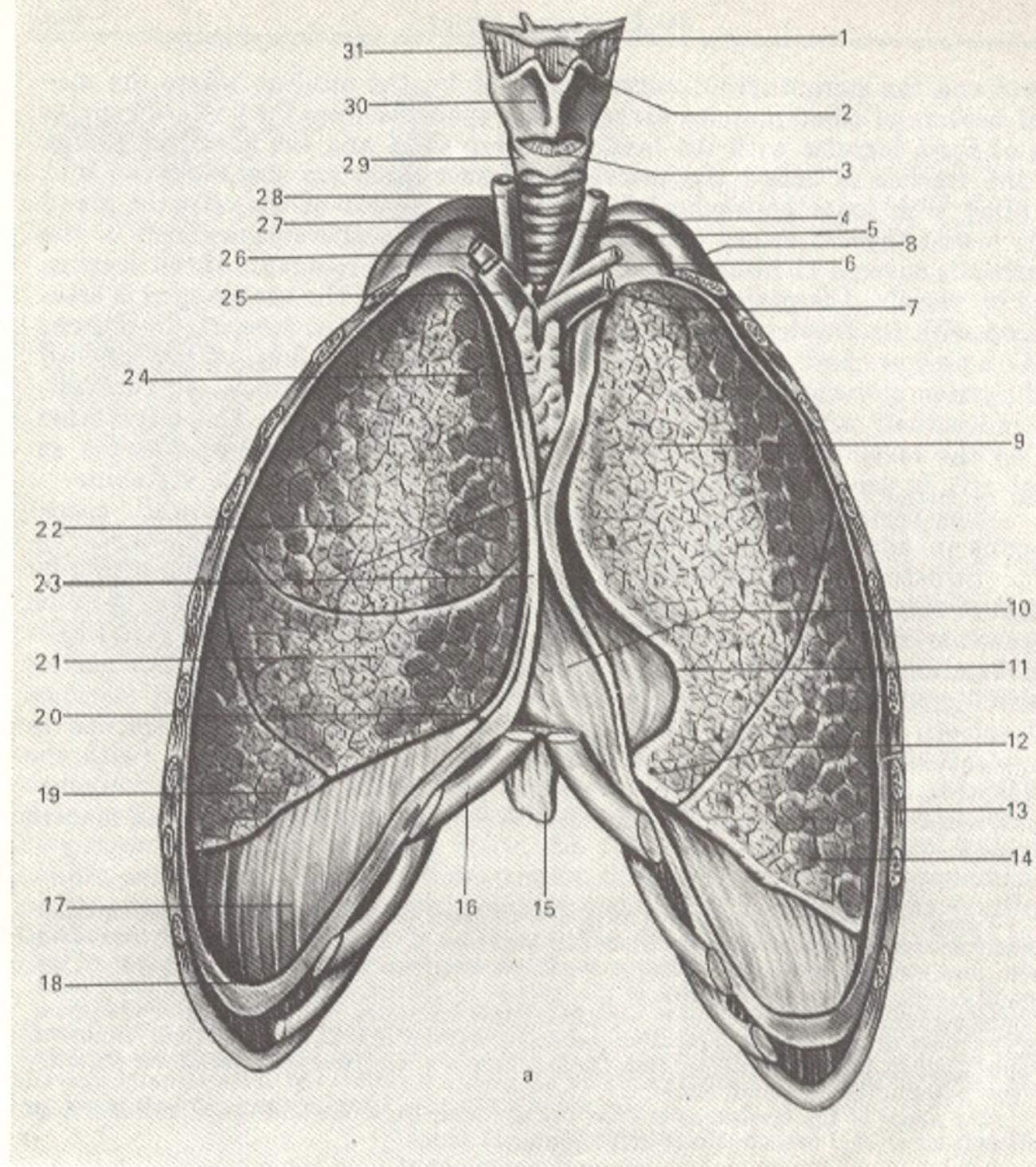


Fig. 244. a, lungs (pulmones), anterior aspect; anterolateral parts of thoracic cage are removed (after Sinelnikov).

1, os hyoideum;  
 2, lig. thyrohyoideum medianum;  
 3, lig. cricothyroideum;  
 4, trachea;  
 5, a. carotis communis sinistra;  
 6, a. subclavia sinistra;  
 7, v. brachiocephalica sinistra;  
 8, first rib;  
 9, lobus superior pulmonis (sinistri);  
 10, cor (covered by pericardium);

11, incisura cardiaca of left lung;  
 12, lingua pulmonis sinistri;  
 13, pleura costalis (cut off);  
 14, lobus inferior (pulm. sin.);  
 15, processus xiphoideus;  
 16, cartilago costae VII;  
 17, pleura diaphragmatica;  
 18, recessus costodiaphragmaticus;  
 19, lobus inferior (pulmonis dextri);  
 20, recessus costomediastinalis;

21, lobus medius;  
 22, lobus superior (pulmonis dextri);  
 23, sites where the pleura is cut away;  
 24, glandula thymus;  
 25, v. brachiocephalica dextra;  
 26, a. subclavia dextra;  
 27, cupula pleurae;  
 28, a. carotis communis dextra;  
 29, cartilago cricoidea;  
 30, cartilago thyroidea;  
 31, membrana thyrohyoidea;

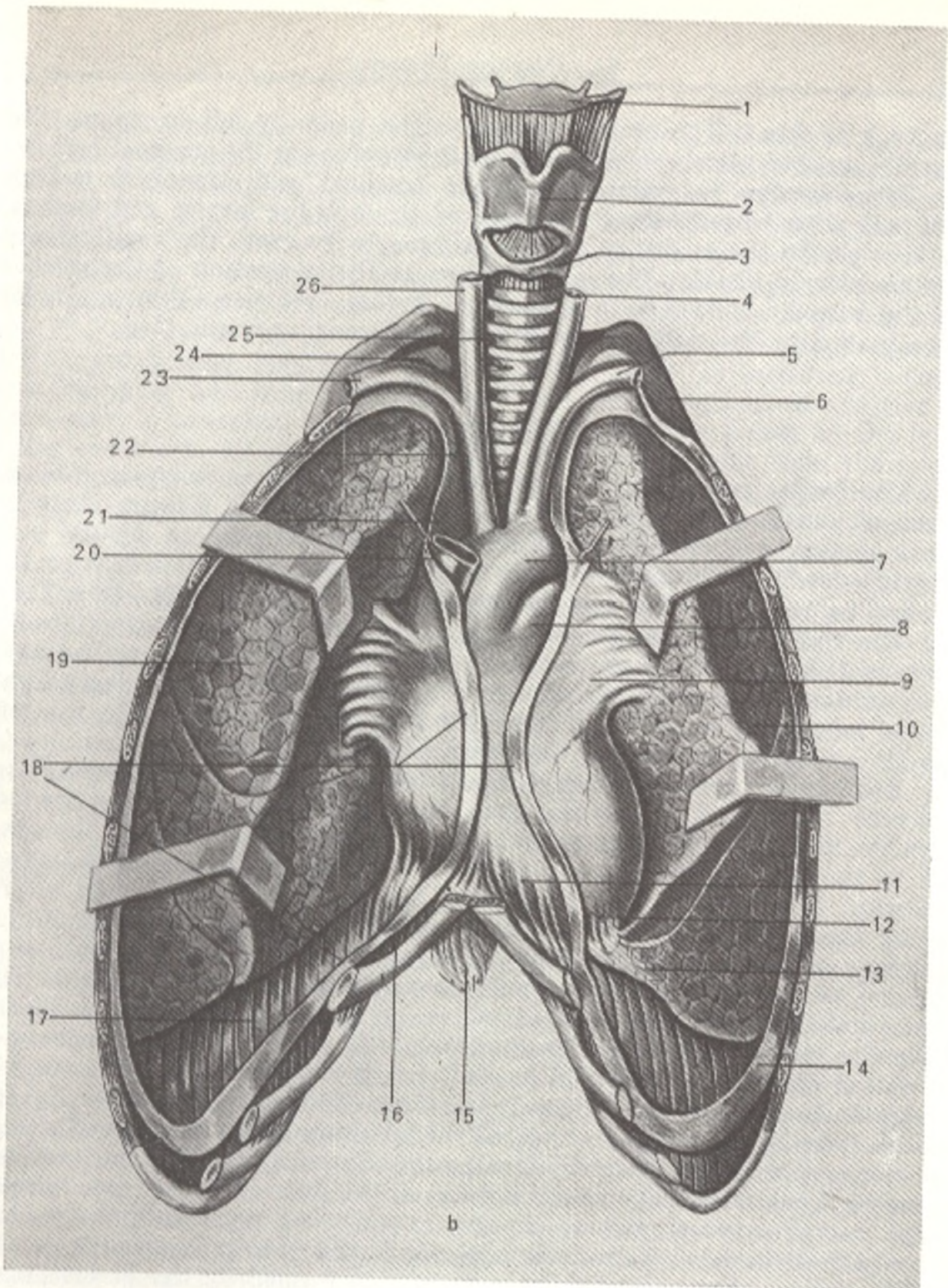


Fig. 244. *b*, lungs (pulmones), anterior aspect. The anterior borders of the lungs are drawn aside; the mediastinal surface is visible (after Sinelnikov).

- |  |                               |                                    |
|--|-------------------------------|------------------------------------|
| 1, larynx;   | 10, pulmo sinister;           | 17, pleura diaphragmatica;         |
| 2, cartilago thyroidea;  | 11, pericardium;              | 18, site where pleura is cut away; |
| 3, cartilago cricoidea;  | 12, apex cordis;              | 19, pulmo dexter;                  |
| 4, a. carotis communis sinistra;   | 13, lingua pulmonis sinistri; | 20, v. cava superior;              |
| 5, a. subclavia sinistra;  | 14, pleura costalis;          | 21, pleura mediastinalis;          |
| 6, first rib;  | 15, processus xiphoideus;     | 22, truncus brachiocephalicus;     |
| 7, arcus aortae;   | 16, cartilago costae VII;     | 23, a. subclavia dextra;           |
| 8, truncus pulmonalis;   |                               | 24, cupula pleurae;                |
| 9, site where pleura pulmonalis is continuous with pleura pericardiac (part of pleurae mediastinalis); |                               | 25, trachea;                       |
|  |                               | 26, a. carotis communis dextra     |

from back to front. The arch of the aorta lies over the left bronchus. The bronchial mucous membrane is the same in structure as the tracheal mucosa.

Bronchoscopy (examination of the tracheal and bronchial mucous membrane with a bronchoscope introduced through the larynx and trachea) in a live person shows the mucous membrane to be grey; the cartilaginous rings are clearly visible. The angle formed at the separation of the trachea into the bronchi is seen as a projection, carina, between them; normally it is situated on the midline and moves freely during respiration.

## THE LUNGS

The lungs (*pulmones*) (Gk *pneumon* lung, hence pneumonia, inflammation of the lungs) are situated in the thoracic cavity (*cavum thoracis*) lateral of the heart and large vessels. They are invested in pleural sacs separated one from the other by the mediastinum, which extends from the vertebral column at the back to the anterior thoracic wall in front (Fig. 244).

The right lung is larger in volume than the left (approximately by 10 per cent) but is a little shorter and wider, firstly because the right diaphragmatic dome is situated higher than the left (the effect of the large right hepatic lobe) and, secondly, because the heart is located more to the left than to the right. As a result the width of the left lung is reduced.

Each lung (*pulmo*) has an irregular conical shape with a base (*basis pulmonis*) below and a rounded apex (*apex pulmonis*) protruding 3-4 cm above the first rib or 2-3 cm above the clavicle in front; posteriorly the apex rises to the level of the seventh cervical vertebra. A small groove, *sulcus subclavius*, is formed on the apex from pressure of the subclavian artery passing here. Three surfaces are distinguished in the lungs. The inferior diaphragmatic surface (*facies diaphragmatica*) is concave and fits the convexity of the superior surface of the diaphragm to which it is adjacent. The large costal surface (*facies costalis*) is convex in accordance with the concavity of the ribs, which, together with the intercostal muscles, are components of the wall of the thoracic cavity. The medial surface (*facies medialis*) is concave in adaptation of its greater part to the outlines of the heart sac and is divided into an anterior part adjacent to the mediastinum (*pars mediastinalis*) and a posterior part (*pars vertebralis*) adjacent to the spine. The surfaces are separated by borders: the sharp border of the base is called the inferior border (*margo inferior*), the other, also a sharp one separating the medial and costal surfaces, is called the anterior border (*margo anterior*). On the medial surface, above and behind a depression formed by the pericardium, is the hilum of the lung (*hilus pulmonis*) through which the bronchi and pulmonary artery (as well as nerves) enter the lungs and the two pulmonary veins (and lymphatic vessels) leave them; the whole complex forms the root of the lung (*radix pulmonis*). The bronchus is situated dorsally in the root while the position of the pulmonary artery on the right side differs from that on the left. In the root of the right lung, the pulmonary artery is below the bronchus, whereas in the root of the left lung it crosses the bronchus and

lies above it. The pulmonary veins on both sides lie in the root of the lung below the pulmonary artery and bronchus. There is no sharp border at the junction of the costal and medial surfaces; the rounded part of each lung is lodged in a groove in the thoracic cavity on both sides of the spine; this is the pulmonary sulcus of the thorax (*sulci pulmonales*).

Each lung is divided by interlobar sutures into **lobes** (*lobi*). The *oblique fissure* (*fissura obliqua*) is present in both lungs; it arises at a relatively high level (6-7 cm below the apex) and descends obliquely to the diaphragmatic surface, penetrating deeply into the pulmonary tissue. In each lung it separates the upper lobe from the lower one. The right lung has, in addition to this fissure, a *horizontal fissure* (*fissura horizontalis*) that passes on the level of the fourth rib. It separates a wedge-shaped middle lobe from the upper lobe of the right lung. There is, therefore, three lobes in the *right lung*: **upper lobe** (*lobus superior*), **middle lobe** (*lobus medius*), and **lower lobe** (*lobus inferior*). The *left lung* has only two lobes: an **upper lobe** (*lobus superior*), which includes the apex, and a larger, **lower lobe** (*lobus inferior*). The lower lobe includes almost the whole diaphragmatic surface and a greater part of the posterior blunt border of the lung. In the lower part of the anterior border of the left lung is the *cardiac notch* (*incisura cardiaca pulmonis sinistra*) where the lung is as if pushed aside by the heart and leaves a large area of the pericardium uncovered. This notch is bounded below by a projection of the anterior border, the *lingula pulmonis* (*lingula pulmonis sinistri*). The *lingula pulmonis* and the adjacent part of the lung correspond to the middle lobe of the right lung.

## STRUCTURE OF THE LUNGS

**Branching of the bronchi** (Figs. 245 and 246). Correspondingly to the separation of the lungs into lobes, each of the principal bronchi on reaching the pulmonary hilum begins separating into **lobar bronchi** (*bronchi lobares*). The right upper lobe bronchus running to the centre of the upper lobe passes above the pulmonary artery and is, therefore, called an *eparterial bronchus*; all the other lobe bronchi of the right lung and all the lobe bronchi of the left lung pass below the level of the pulmonary artery and are called *hyparterial*. On entering the substance of the lung, the lobe bronchi give off several smaller, tertiary bronchi called **segmental bronchi** (*bronchi segmentales*) because they ventilate definite areas of the lung, the *pulmonary segments*. The segmental bronchi divide in turn dichotomously (each into two parts) into smaller bronchi of the fourth and next orders to end as terminal and respiratory bronchioles (see p. 511).

The *skeleton* of the extrapulmonary bronchi differs from that of the intrapulmonary bronchi in accordance with the different mechanical effect exerted on the walls of the bronchi outside and within the lung. The skeleton of extrapulmonary bronchi consists of cartilaginous semirings; as the bronchi approach the hilum of the lung, cartilaginous bonds form between the cartilaginous semirings as a result of which the annular structure is replaced by a latticed structure.

The cartilages of the segmental bronchi and those of their branchings no longer have the shape of semirings but break down into separate laminae whose size reduces with the diminution of the calibre of the bronchi; in the terminal bronchioles the cartilages disappear completely. The mucous glands also disappear in the terminal bronchioles, but the ciliary epithelium remains.

The muscular layer is composed of smooth muscle fibres arranged circularly on the inner surface of the cartilages. Special circular muscle fibres resembling sliding loops in shape are found at the site of separation of the bronchi. On contraction they may constrict partly or completely the entrance into this or that bronchus.

Possessing a neurovascular apparatus of a complex structure and being in close functional union with the lungs, the trachea and bronchi actively contribute to the respiratory act and to the discharge of the secretions. The tracheobronchial tree possesses a permanent tonus and can actively change

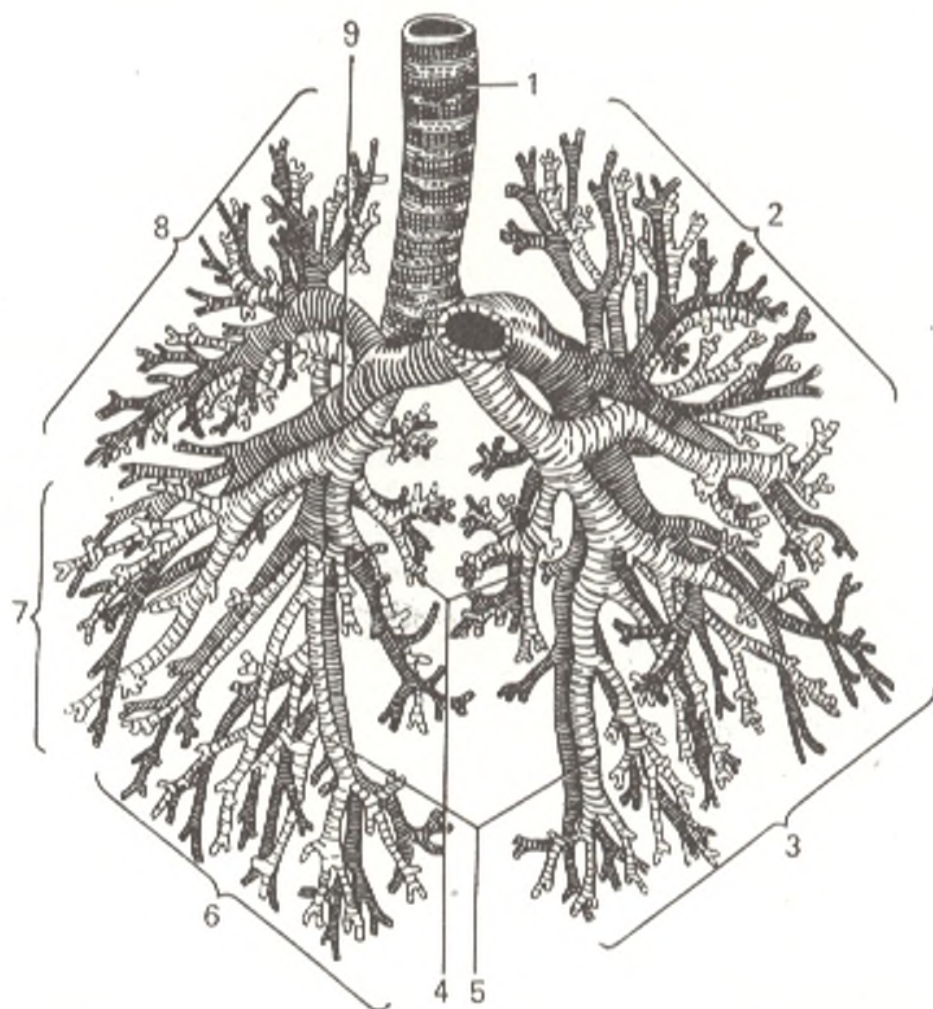


Fig. 245. The bronchial tree and the relations of the right and left pulmonary arteries to it.

1, trachea;  
2 and 3, lobus superior;  
5 and 6, lobus inferior;  
4, ramifications of the segmental bronchi;

5, segmental bronchi;  
7, lobus medius;  
9, the right pulmonary artery lies behind the bronchus



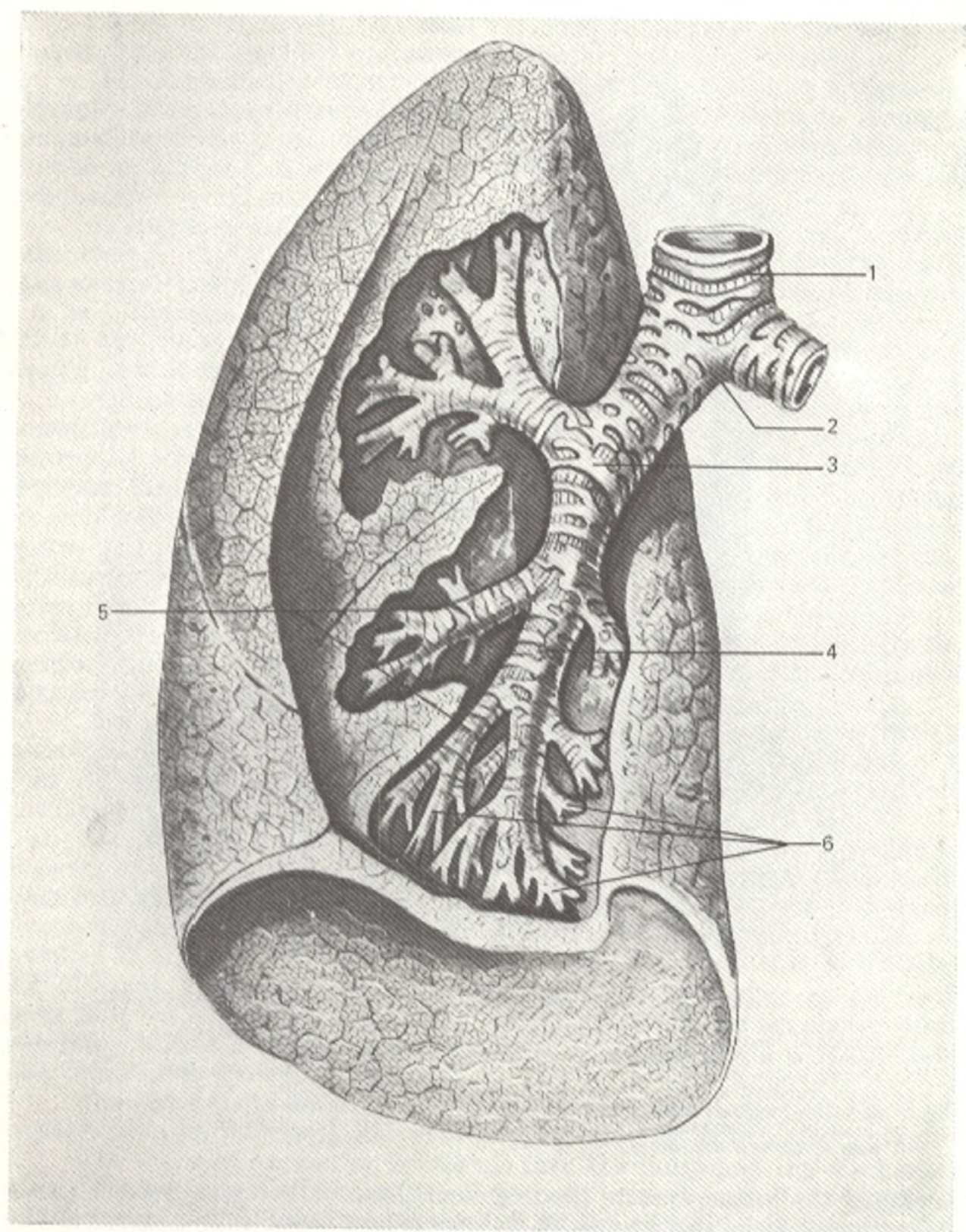


Fig. 246. The bronchial tree (represented semischematically, after Filatova).

1, trachea;  
 2, bifurcatio tracheae;  
 3, bronchus principalis sinister;  
 4, bronchus lobaris inferior sinister;

5, bronchi segmentales;  
 6, ramifications of the segmental  
 bronchi

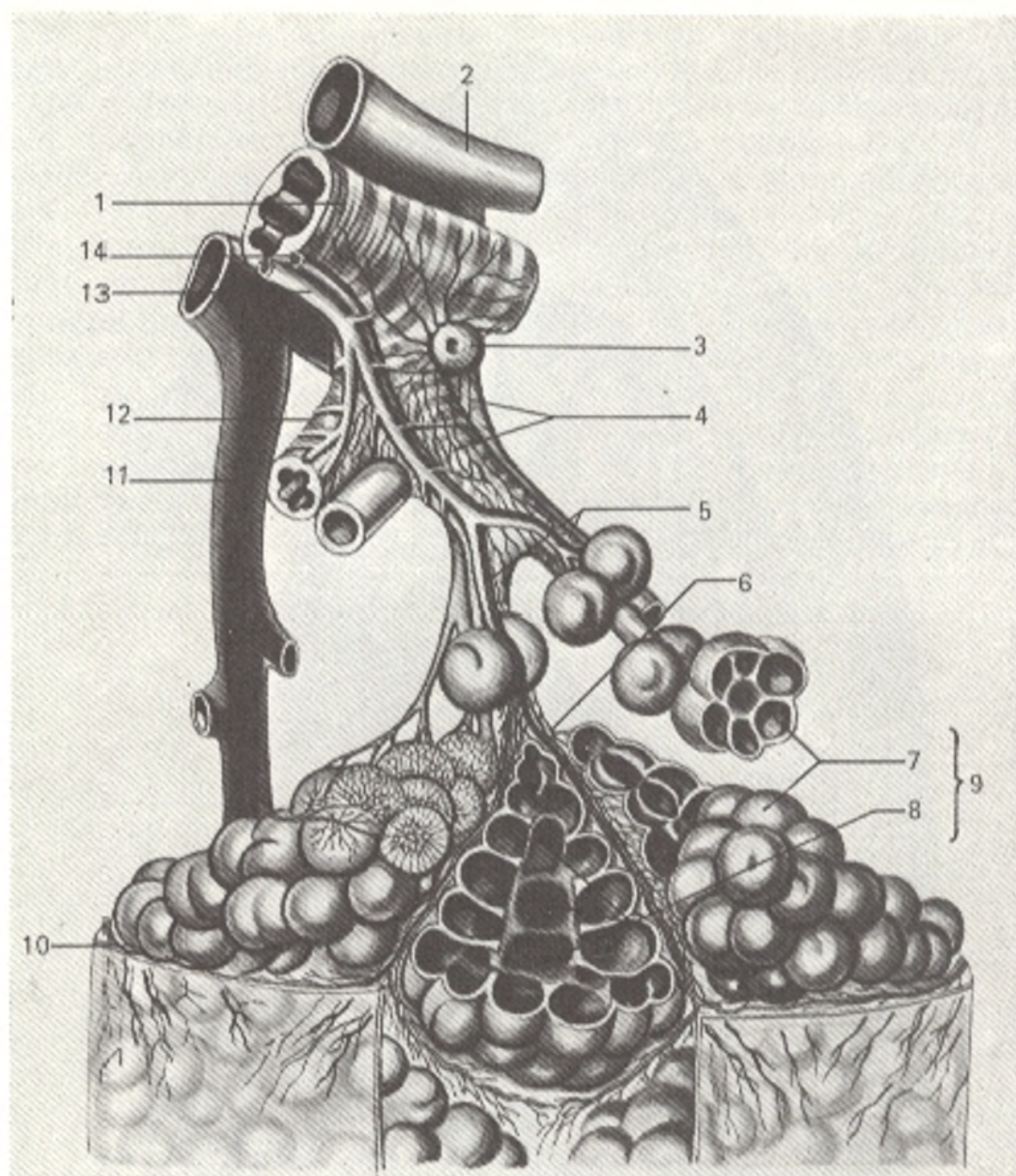


Fig. 247. Structure of the lung alveolus (after Kiss and Szentagóthai).

- |                                  |                                       |
|----------------------------------|---------------------------------------|
| 1, bronchus lobaris;             | 8, alveoli pulmonum;                  |
| 2, branch of a. pulmonalis;      | 10, pleura;                           |
| 3, lymphonodus pulmonalis;       | 11, vein draining into v. pulmonalis; |
| 4, vasa lymphatica;              | 13, branch of a. bronchialis;         |
| 5 and 12, bronchiole terminales; | 14, vein draining into v. bronchialis |
| 6, bronchiole respiratorii;      |                                       |
| 7 and 9, ductuli alveolares;     |                                       |

the size of the lumen even to the degree of sharp pathological spasms (bronchial asthma). It is also known that bronchi are capable of peristaltic and spiral movements, narrowing and dilating synchronously with respiration. The structure of the tracheal and bronchial skeleton, consisting of alternating immobile and mobile elements, is also conducive to movement.

**The macromicroscopic structure of the lung (Fig. 247).** The pulmonary segments consist of *pulmonary lobules (lobuli pulmonales)*, which are small

(0.5-1.0 cm in diameter) pyramidal areas of pulmonary parenchyma separated from one another by connective-tissue (interlobular) septa.

The interlobular connective tissue contains veins and a network of lymphatic capillaries and aids the mobility of the lobules in respiratory excursions of the lung. Inspired carbon dust is very often deposited in this tissue as a result of which the boundaries of the lobules become clearly visible.

A single small (1 mm in diameter) bronchus (of the eighth order on the average) still containing cartilage in its walls (*lobular bronchus*) enters the apex of each lobule. The number of lobular bronchi in both lungs comes up to a thousand. Each lobular bronchus branches out in the lobule into 12-18 finer (0.3-0.5 mm in diameter) *terminal bronchioles* (*bronchioli terminales*), which contain neither cartilage nor glands.

All the bronchi, from the principal bronchi to the terminal bronchioli, constitute a single **bronchial tree** and serve as passages for conducting the stream of air in inspiration and expiration; respiratory exchange of gases between the air and the blood does not take place in them. The terminal bronchioles branch dichotomously to give origin to the *respiratory bronchioles* (*bronchioli respiratorii*) which are characterized by the appearance of *alveoli of the lung* (*alveoli pulmonum*) on their walls. *Alveolar ducts* (*ductuli alveolares*) arise radially from each respiratory bronchiole and terminate as blind *air saccules* (*sacculi alveolares*). The wall of each saccule is surrounded by a thick network of blood capillaries. The exchange of gases takes place through the alveolar walls.

The respiratory bronchioles, alveolar ducts, and air saccules with the alveoli compose a single **alveolar tree**, or the respiratory parenchyma of the lung. They form the functional and anatomical unit of the parenchyma called the **acinus** (L grape).

According to some authors, an acinus is a part of the alveolar tree formed by the branching of a single terminal bronchiole. Other authors believe that it is much smaller and is composed of only a group of alveolar ducts with air saccules branching from one respiratory bronchiole. The number of acini in both lungs amounts to 800 000 while that of alveoli to 300-500 mln. The area of the respiratory surface of the lungs ranges in size from 30 m<sup>2</sup> in expiration to 100 m<sup>2</sup> in deep inspiration. An aggregate of acini composes lobules, lobules form segments, segments group to form lobes, and lobes form a whole lung.

*Functions of the lungs.* The main function of the lungs is the exchange of gases (they enrich the blood with oxygen and free it of carbon dioxide).

The entry of oxygen-saturated air into the lungs and the discharge of air to the exterior are accomplished both by active expiratory excursions of the thoracic wall and diaphragm and by the contractile property of the lung itself together with the activity of the respiratory passages. The contractility and ventilation of the inferior lobes are determined mostly by the diaphragm and the lower parts of the thoracic cage, whereas ventilation and changes in volume of the upper lobes are mainly accomplished with the aid of excursions of the upper part of the thorax.

These features allow surgeons to differentiate their approach to division of the phrenic nerve in removal of the pulmonary lobes.

In addition to normal pulmonary respiration, collateral respiration, i.e. the movement of air by-passing the bronchi and bronchioles, is distinguished. It takes place between peculiarly constructed acini through pores in the walls of the pulmonary alveoli. The lungs of adults, predominantly the lower lobes (mostly in old-aged individuals), contain, in addition to lobular structures, structural complexes of alveoli and alveolar ducts indistinctly grouped into pulmonary lobules and acini and producing a cord-like trabecular structure. These alveolar cords make collateral respiration possible. Since such atypical alveolar complexes connect separate bronchopulmonary segments, collateral respiration is not limited to them but spreads more extensively.

The physiological role of the lungs is not restricted merely to the exchange of gases. A great variety of functional manifestations corresponds to their complex anatomical structure: activity of the bronchial walls in respiration, a secreting-excreting activity, and the participation in metabolism (water, lipoid, and salt with regulation of chlorine balance), which is important in maintaining the acid-base equilibrium in the body.

There are also data pointing to the existence of a combined mutually complementary activity of the lungs and the liver, united under the concept "hepatopulmonary system". It is considered firmly established that the lungs have a powerfully developed system of cells possessing phagocytic properties.

*Pulmonary circulation* is marked by specific features. Being concerned with gas exchange, the lungs receive both arterial and venous blood. Venous blood reaches the lungs by way of the branches of the pulmonary artery; each branch (right and left pulmonary artery) enters the hilum of the corresponding lung and then divides in accordance with the ramification of the bronchi. The smallest branches of the pulmonary artery form a network of capillaries around the alveoli (respiratory capillaries). Venous blood brought thus to the pulmonary capillaries enters into an osmotic (gas) exchange with the air contained in the alveoli; it gives off its carbon dioxide into the alveoli and receives oxygen instead. The capillaries unite to form veins carrying oxygen-enriched (arterial) blood and uniting to form larger veins, which finally form the pulmonary veins.

Arterial blood is conveyed to the lungs by the bronchial branches of the aorta, posterior intercostal arteries, and subclavian artery. They supply with nutrients the bronchial walls and the pulmonary tissue. From the capillary network produced by the ramification of these arteries form the bronchial veins draining partly into the azygos and hemiazygos veins and partly into the pulmonary veins. Thus, the systems of the pulmonary and bronchial veins anastomose.

Superficial *lymphatic vessels* embedded in the deep layer of the pleura and deep intrapulmonary lymphatic veins are distinguished in the lungs. The roots of the deep vessels are the lymphatic capillaries around the respiratory and terminal bronchioles, in the interacinar and interlobular septa. These networks are continuous with plexuses of lymphatic vessels found around the branchings of the pulmonary artery, pulmonary veins, and bronchi.

The lymphatics draining lymph from the lungs pass partly through the pulmonary lymph nodes to the root of the lung and the regional lymph nodes located here. Three territories—upper, middle, and lower—can be distinguished in the lung, which, however, do not correspond with its division into the upper, middle and lower lobes. Lymph from the upper territory of the right lung flows into the right tracheal nodes, lymph from the lower territory flows into the tracheobronchial nodes, while lymph from the middle territory drains into the tracheal and the tracheobronchial nodes. From the upper territory of the left lung lymph drains into the left tracheal and anterior mediastinal nodes, from the lower territory it flows into all the lymph nodes mentioned above.

Since all vessels of the tracheobronchial nodes pass to the right venous angle, most of the lymph from the lower lobe of the left lung drains into the right lymphatic duct.

The nerves of the lungs originate from the pulmonary plexus formed by branches of the vagus nerve and sympathetic trunk.

On leaving the pulmonary plexus, the nerves spread in the lobes, segments, and lobules of the lung in attendance to the bronchi and blood vessels composing the bronchovascular bundles. In these bundles the nerves form plexuses, in which microscopic intraorganic nerve ganglia are encountered; these are the sites where the preganglionic parasympathetic fibres change to the postganglionic fibres.

Three nerve plexuses are distinguished in the bronchi: in the adventitia, in the muscle layer, and under the epithelium. The subepithelial plexus reaches the alveoli. In addition to efferent sympathetic and parasympathetic innervation, the lung is also supplied with afferent innervation arriving from the bronchi along the vagus and from the visceral pleura along sympathetic nerves passing through the stellate ganglion.

## THE SEGMENTAL STRUCTURE OF THE LUNGS

There are six tubular systems in the lungs: the bronchi, the pulmonary arteries and veins, the bronchial arteries and veins, and the lymphatic vessels (Fig. 248).

Most ramifications of these systems stretch parallel to one another and form bronchovascular bundles composing the framework of the inner topography of the lung. In correspondence with the bronchovascular bundles, each pulmonary lobe is formed of separate areas called bronchopulmonary segments.

A *bronchopulmonary segment* is part of the lung corresponding to a primary lobe bronchus and the attendant branches of the pulmonary artery and other vessels. It is separated from the adjacent segments by more or less pronounced connective-tissue septa, in which the segmental veins pass. These veins have tributaries in half of the territory of each of the adjacent segments. The pulmonary segments have the shape of irregular cones or pyramids whose apices face the hilum of the lung while the bases face the lung surface, where the boundaries between the segments are sometimes detectable due to the difference in pigmentation. The bronchopulmonary segments are the functional and anatomical units of the lung. Within them some pathological processes are first localized. Therefore, in sparing operations for treating such processes only the segment is removed instead of the whole lobe or the whole lung. Many classifications of segments have been suggested.

The representatives of different specialities (surgeons, radiologists, anatomists) distinguish a different number of segments (from 4 to 12). A Soviet specialist Rokhlin, for instance, suggested a schematical representation of the segmental structure for the purposes of radiodiagnosis, according to

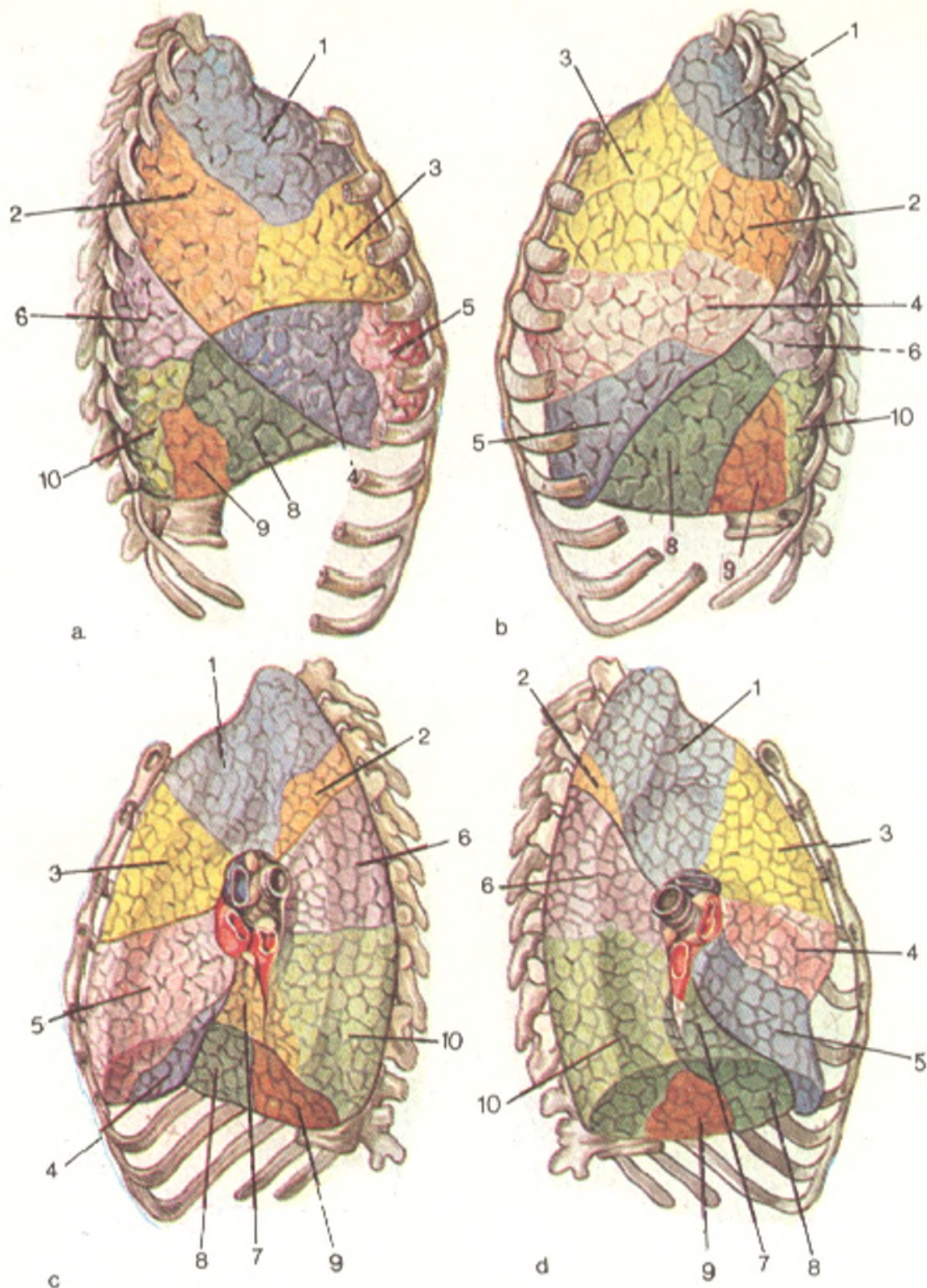


Fig. 248. Segments of the right (a and b) and left (c and d) lungs (after Zhdanov).

- 1, apical segment;
- 2, posterior segment (in the left lung 1 and 2 may fuse to form the apicoposterior segment);
- 3, anterior segment;
- 4, lateral segment (right lung) and superior lingular segment (left lung);
- 5, medial segment (right lung) and inferior lingular segment (left lung);

- 6, apical segment of inferior lobe;
- 7, medial basal segment;
- 8, anterior basal segment (? and 8 in the left lung usually have a common bronchus);
- 9, lateral basal segment;
- 10, posterior basal segment

which there are 12 segments in the right lung (three in the upper, two in the middle, and seven in the lower lobe) and 11 in the left lung (4 in the upper and 7 in the lower lobe).

According to the International (Paris) Anatomical Nomenclature (PNA), 11 bronchopulmonary segments are distinguished in the right lung and 10 segments in the left lung.

Each segment is designated according to topography. The segments are as follows.

**The right lung.** Three segments are distinguished in the upper lobe of the right lung: apical (*segmentum apicale*), posterior (*segmentum posterius*), and anterior (*segmentum anterius*).

The *apical segment* occupies the superomedial area of the upper lobe, enters the superior aperture of the thoracic cage, and fills the cervical pleura.

The base of the *posterior segment* is directed laterally and to the back where it is adjacent to the second, third, and fourth ribs: its apex faces the superolobar bronchus.

The base of the *anterior segment* comes in contact with the anterior thoracic wall along the area between the first and fourth costal cartilages; the segment is adjacent to the right atrium and vena cava superior.

The **middle lobe** has two segments: lateral (*segmentum laterale*) and medial (*segmentum mediale*).

The base of the *lateral segment* faces anteriorly and laterally, the apex, upward and medially.

The *medial segment* comes in contact with the anterior thoracic wall near the sternum, between the fourth and sixth ribs, and with the heart and the diaphragm.

Five or six segments are distinguished in the lower lobe: one apical (*segmentum apicale*), four basal among which are the medial, or cardiac, basal (*segmentum basale mediale s. cardiacum*), anterior basal (*segmentum basale anterius*), lateral basal (*segmentum basale laterale*), and posterior basal (*segmentum basale posterius*); there is also one inconstant subapical segment (*segmentum subapicale s. subsuperius*).

The *apical segment* (superior) occupies the wedge-shaped apex of the lower lobe and is in the paravertebral region.

The base of the *medial basal segment* occupies the mediastinal and partly the diaphragmatic surfaces of the lower lobe. It is adjacent to the right atrium and vena cava inferior.

The base of the *anterior basal segment* is on the diaphragmatic surface of the lower lobe, while the larger part of its lateral surface adjoins the thoracic wall in the axilla between the sixth and eighth ribs.

The *lateral basal segment* is wedged between the other segments of the lower lobe in such a manner that its base is in contact with the diaphragm and its lateral surface is in contact with the thoracic wall in the axillary region, between the seventh and ninth ribs.

The *posterior basal segment* is situated paravertebrally to the back of all the other segments of the lower lobe and penetrates deeply into the poste-

rior region of the pleural costodiaphragmatic sinus. Sometimes a *subapical segment* separates from the posterior basal segment.

The **left lung**. The **upper lobe** of the left lung has four segments: apicoposterior (*segmentum apicoposterius*), anterior (*segmentum anterius*), and two lingular, superior (*segmentum lingulare superius*) and inferior (*segmentum lingulare inferius*).

The apicoposterior segment corresponds in shape and position to the apical and posterior segments of the right upper lobe. Its base comes in contact with the posterior parts of the third, fourth, and fifth ribs. The segment adjoins medially the aortic arch and the subclavian artery. It may be encountered as two segments.

The *anterior segment* is the largest. It occupies a considerable area of the costal surface of the upper lobe between the first and fourth ribs and part of the mediastinal surface where it comes in contact with the pulmonary trunk.

The *superior lingular segment* is a part of the upper lobe between the third and fifth ribs anteriorly and between the fourth and sixth ribs in the axillary region.

The *inferior lingular segment* is below the superior lingular segment but hardly comes in contact with the diaphragm.

Both lingular segments correspond to the middle lobe of the right lung; they adjoin the left ventricle of the heart by penetrating between the pericardium and thoracic wall in the pleural costomediastinal sinus.

Five or six segments are distinguished in the **lower lobe** of the left lung; they are symmetrical with the segments of the right lower lobe and are, therefore, similarly designated.

The *apical (superior) segment* has a paravertebral position.

The *medial (cardiac) basal segment* in 83 per cent of cases has a bronchus in common with the next segment, the *anterior basal segment*. The last named is separated from the lingular segments of the upper lobe by the oblique fissure and contributes to the formation of the costal, diaphragmatic, and mediastinal surfaces of the lung.

The *lateral basal segment* occupies the costal surface of the lower lobe laterally on an area between the seventh and tenth ribs.

The *posterior basal segment* is a large area of the left lower lobe situated posteriorly of the other segments; it comes in contact with the seventh, eighth, ninth, and tenth ribs, the diaphragm, the descending aorta, and the oesophagus.

The *subapical segment* is inconstant.

## THE PLEURAL SACS AND THE MEDIASTINUM

Three absolutely isolated serous sacs are present in the thoracic cavity, one for each lung and one, middle, sac, for the heart. The serous covering of the lung is called the **pleura**. It has two layers: the **visceral pleura** (*pleura visceralis*) and the **parietal pleura** (*pleura parietalis*).



The **visceral, or pulmonary pleura**, covers the lung itself and fuses with the pulmonary substance so closely that it cannot be removed without injury to the tissue. It enters the pulmonary fissures and separates in this manner the pulmonary lobes one from another. Villi-like projections of the pleura are encountered on the sharp borders of the lungs. The pulmonary pleura invests the lung completely and is continuous with the parietal pleura at the root of the lung. On the inferior margin of the root the serous layers of its anterior and posterior surfaces fuse to form the pulmonary ligament (*ligamentum pulmonale*), which descends vertically on the medial surface of the lung and is attached to the diaphragm.

The **parietal pleura** is the outer part of the pulmonary serous sac. The outer surface of the parietal pleura fuses with the thoracic walls, while the inner surface faces directly the visceral pleura. Its inner surface is covered with mesothelium and moistened with a small amount of serous fluid making it shiny and reducing traction between the two pleural layers, visceral and parietal, during respiratory excursions.

The pleura plays a most important part in processes of transudation (excretion) and resorption (absorption), the normal relations between which are drastically disturbed in morbid conditions of the thoracic cavity.

Although they are macroscopically homogeneous and of the same histological structure, the parietal and visceral pleurae differ in their function, which is evidently associated with their different embryonic origin. The visceral pleura, in which blood vessels predominate greatly over the lymphatic vessels, is mainly concerned with the function of excretion. The parietal pleura, in contrast, having in its costal part specific apparatuses for absorption from the serous cavities and being marked by the predominance of lymphatics over the blood vessels, accomplishes the function of resorption. The potential space between the adjoining parietal and visceral pleurae is called the **pleural cavity** (*cavum pleurae*). In a healthy subject the pleural cavity is not visible macroscopically; under normal conditions, at rest, it contains 1 or 2 ml of fluid separating the adjoining pleural layers by means of a capillary layer. This fluid is responsible for cohesion between two surfaces experiencing the action of opposed forces: the inspiratory expansion of the thoracic cage and the elastic pull of the pulmonary tissue. The presence of these two opposing forces produces in the pleural cavity pressure, which is not the pressure of any gas. When the thorax is opened, the pleural cavity increases artificially because the lungs collapse due to equilibration of the atmospheric pressure exerted both on the outer surface and from the inside, from the direction of the bronchi.

The parietal pleura is a single closed sac, but for descriptive purposes it is subdivided into the costal, diaphragmatic, and mediastinal pleurae. Besides, the superior part of each pleural sac is distinguished as the cervical pleura, or *cupula of pleura* (*cupula pleurae*). The cervical pleura covers the apex of the corresponding lung and protrudes from the thoracic cavity in the region of the neck 3-4 cm above the anterior end of the first rib. The cervical pleura is bounded laterally by the anterior and middle scalene

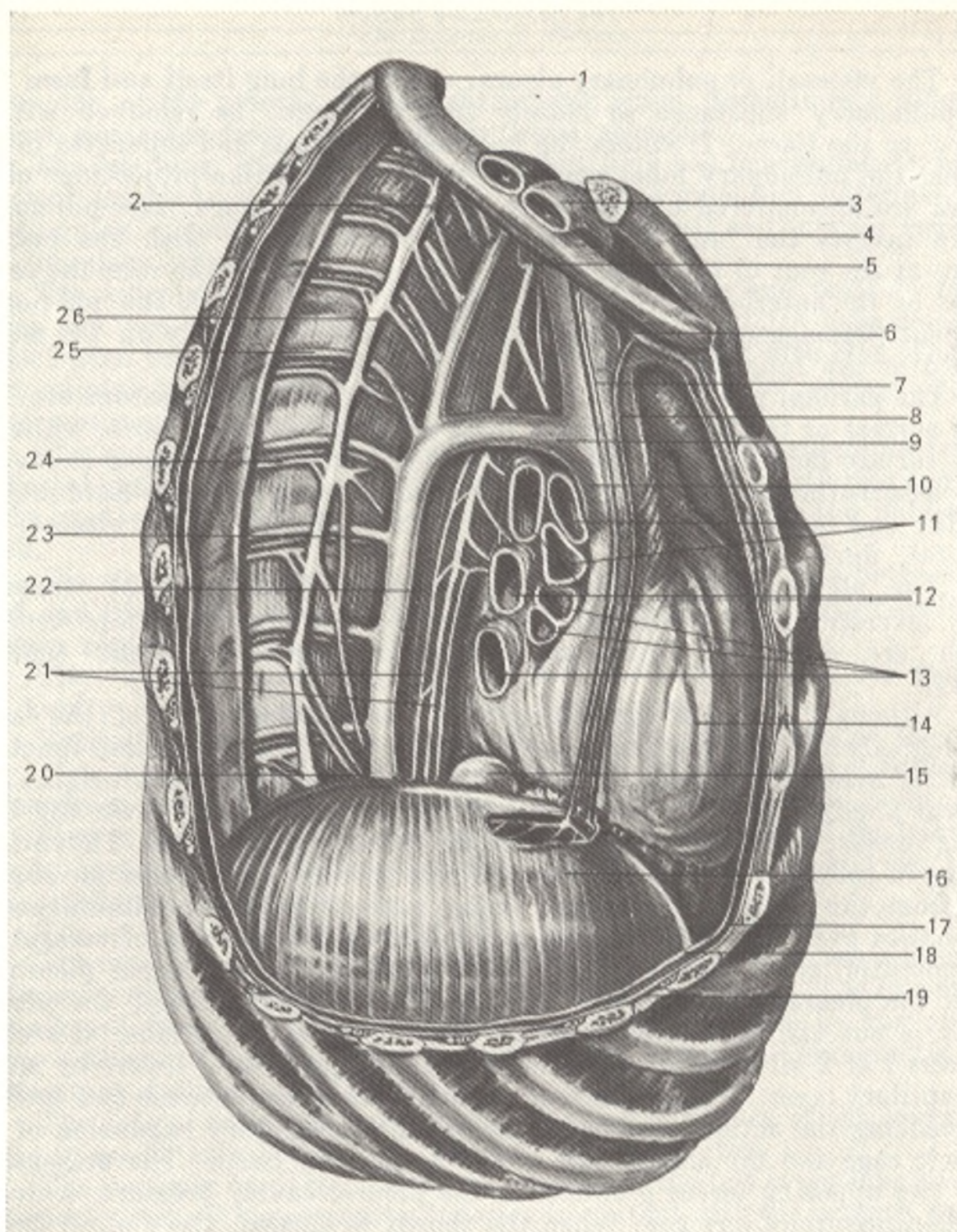


Fig. 249. Organs of the posterior mediastinum, viewed from the right (after Kiss and Szentagóthai).

- |   |                                     |
|---|-------------------------------------|
| 1, costa I;   | 13, bronchus lobaris (dexter);      |
| 2 and 26, truncus sympathicus;                              | 14, vv. pulmonales (dextrae);       |
| 3, a. subclavia (dextra);                                   | 15, pericardium;                    |
| 4, v. subclavia (dextra);                                   | 16, v. cava inferior;               |
| 5, clavicula;   | 17, diaphragma;                     |
| 6, n. vagus (dexter);                                       | 18, pleura parietalis;              |
| 7, a. thoracica interna (dextra);                           | 19, fascia endotheracica;           |
| 8, m. phrenicus;  | 20, n. splanchnicus minor;          |
| 9, a. pericardiophrenica;                                   | 21, plexus esophageus;              |
| 10, v. azygos (site of its drainage into v. cava superior); | 22, esophagus;                      |
| 11, v. cava superior;                                       | 23, n. splanchnicus major (dexter); |
| 12, branches of a. pulmonalis (dextrae);                    | 24, a. intercostalis posterior;     |
|   | 25, v. intercostalis posterior      |

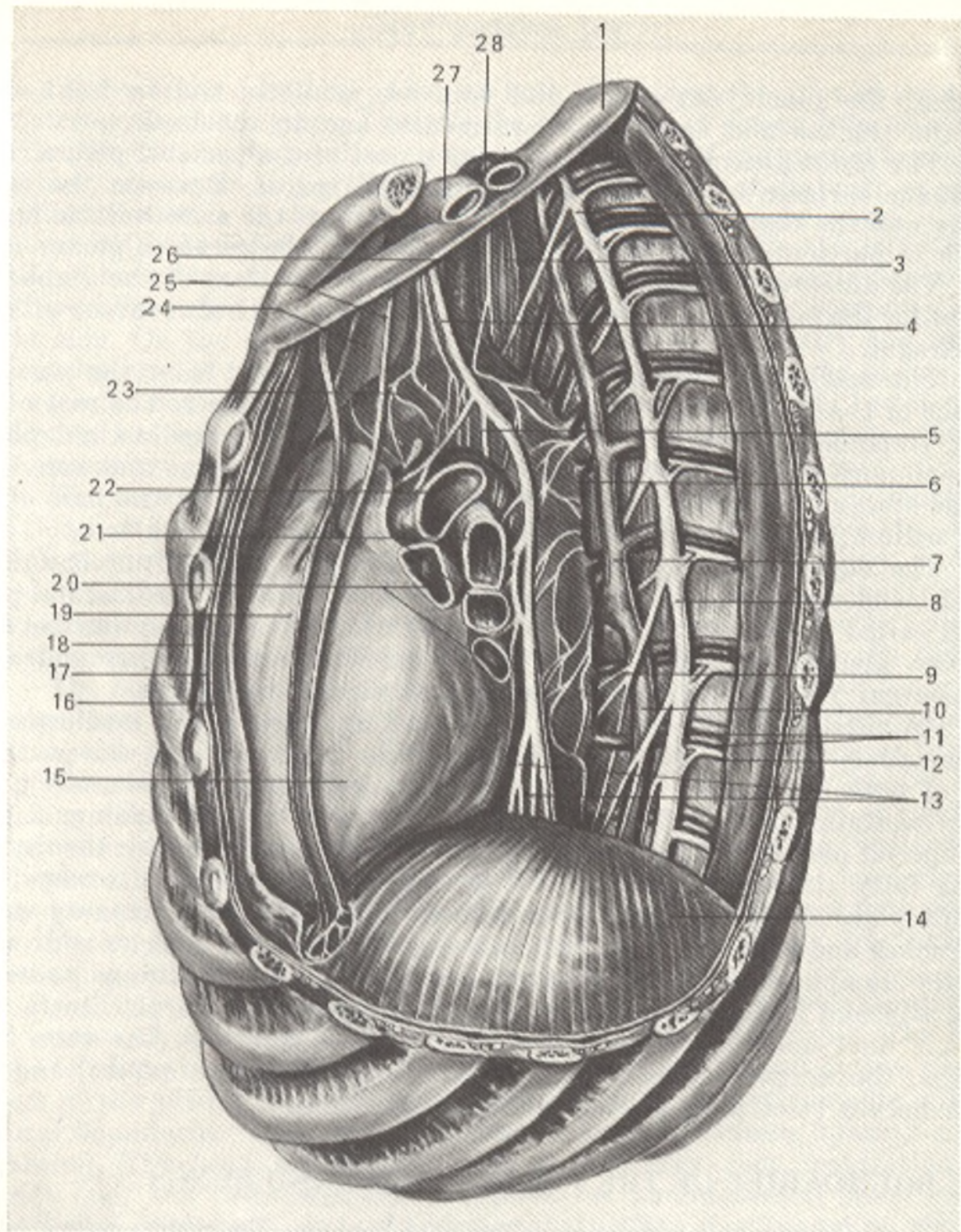


Fig. 250. Organs of the posterior mediastinum, viewed from the left (after Kiss and Szentagóthai).

- |   |   |
|---|---|
| 1, costa I;                             | 16, pleura mediastinalis;                       |
| 2 and 8, truncus sympathicus;           | 17, pleura costalis;                            |
| 3, esophagus;                           | 18, fascia endothoracica;                       |
| 4, n. vagus (sinister);                 | 19, a. pericardiacophrenica;                    |
| 5, n. laryngeus recurrens (sinister);   | 20, vv. pulmonales (sinistrae);                 |
| 6, aorta thoracica;                     | 21, bronchi principalis and lobaris (sinistri); |
| 7, v. hemiazygos accessoria;            | 22, a. pulmonalis (sinistra);                   |
| 9, n. splanchnicus major (sinister);    | 23, arcus aortae;                               |
| 10, hemiazygos;                         | 24, v. cava superior;                           |
| 11, v. et a. intercostales posteriores; | 25, n. phrenicus (sinister);                    |
| 12, n. intercostalis;                   | 26 and 28, a. subclavia (sinister);             |
| 13, plexus esophageus;                  | 27, v. subclavia (sinistra)                     |
| 14, diaphragma;                         |   |
| 15, pericardium;                        |   |

muscles; the subclavian artery and vein are medially and in front of it, and the trachea and oesophagus are medial and to the back.

The *costal pleura*, the most extensive part of the parietal pleura, lines the inner surfaces of the ribs and intercostal spaces. Between the costal pleura and the thoracic wall is a thin fibrous sheet, the endothoracic fascia, which is particularly developed in the region of the cervical pleura.

The *diaphragmatic pleura* covers the superior surface of the diaphragm except for the middle part where the pericardium is in direct contact with the diaphragm.

The *mediastinal pleura* stretches anteroposteriorly from the posterior surface of the sternum and the lateral surface of the spine to the root of the lung; it bounds laterally the mediastinal organs. The mediastinal pleura is continuous with the costal pleura posteriorly on the spine and anteriorly on the sternum with the diaphragmatic pleura inferiorly at the base of the pericardium, and with the visceral pleura on the root of the lung.

The complex of organs (the heart with the pericardium and large vessels, and other organs) occupying the space between the mediastinal pleurae is called the **mediastinum**. This complex forms as if a septum between the two pleural sacs. The organs of the mediastinum are surrounded by mediastinal fat containing complex neurovascular structures.

An anterior and posterior parts are distinguished in the mediastinum, the boundary between which is a frontal plane drawn through the posterior part of both pulmonary roots. The **anterior mediastinum** (*mediastinum anterius*) contains in its inferior part the heart with the pericardium and in the superior part the following organs (named from front to back): the thymus or the fatty tissue replacing it, the vena cava superior and its roots, the ascending aorta and the aortic arch with its branches, the pulmonary veins, the trachea and bronchi, the phrenic nerves, the bronchial arteries and veins, and the lymph nodes. The **posterior mediastinum** (*mediastinum posterius*) (Figs. 249 and 250) is occupied by the oesophagus, the thoracic aorta, the thoracic duct and the lymph nodes, and veins and nerves (the vena cava inferior, the azygos and hemiazygos veins, the splanchnic nerves, and the vagus nerves stretching on the oesophageal walls).

## THE BOUNDARIES OF THE PLEURAL SACS AND LUNGS

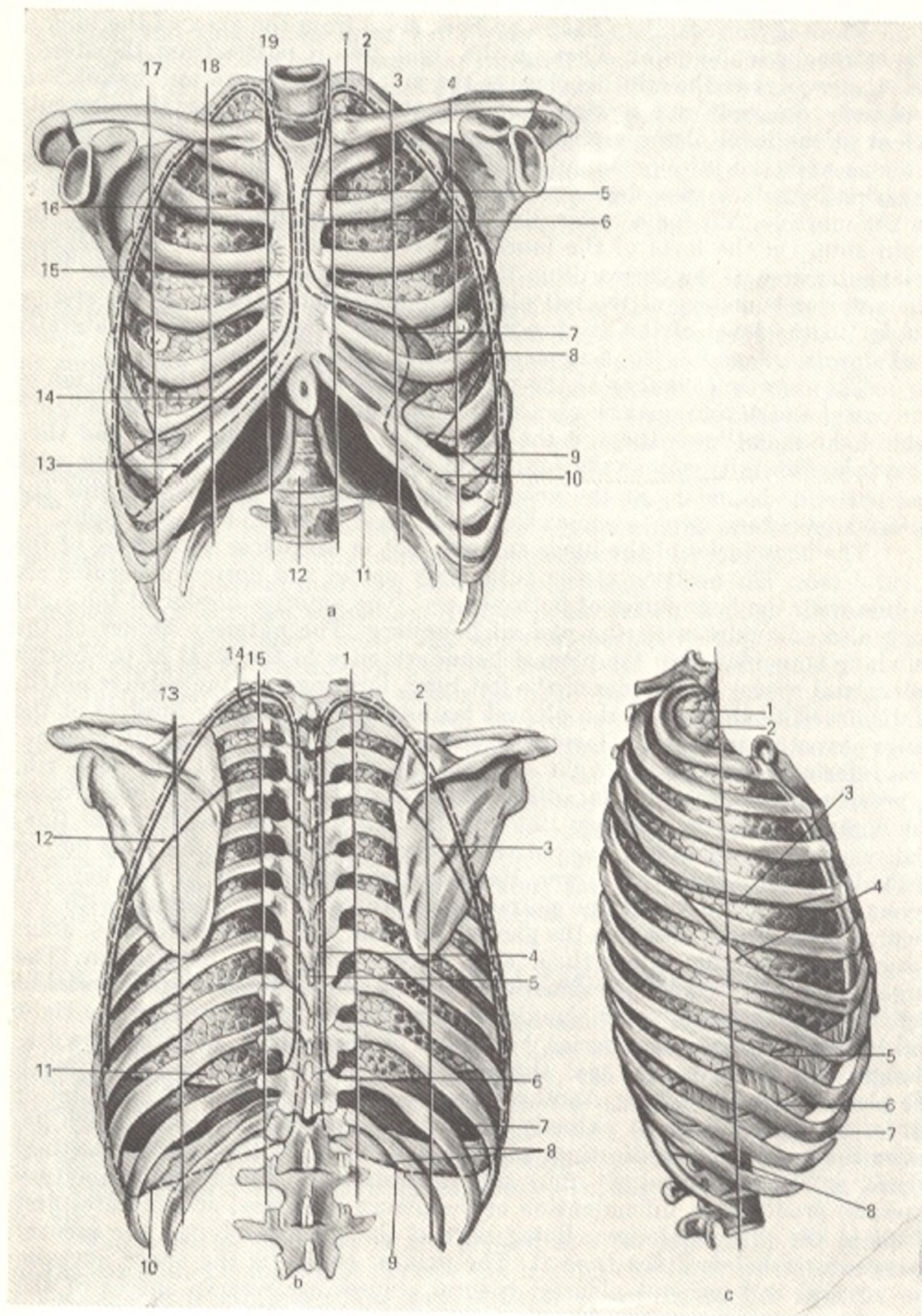
The right and left pleural sacs are asymmetric. The right sac is a little shorter and wider than the left. The outlines of their anterior margins are also asymmetric. As it is mentioned above, the apices of the pleural sacs extend above the superior thoracic aperture to the level of the head of the first rib (this point approximately coincides with the spinous process of the seventh cervical vertebra, or vertebra prominens, which can be palpated on a live subject) or 3-4 cm above the anterior end of the first rib (see Fig. 251, a, b, c).

The *posterior boundary* of the pleural sacs corresponds to the junction of the costal and mediastinal pleurae and is quite constant; it stretches along the spine and terminates at the level of the heads of the twelfth ribs.

The *anterior boundary* passes on both sides from the apex of the lung to the sternoclavicular joint. Then on the right side it passes from the sternoclavicular joint to the midline close to the junction of the sternal manubrium and body, descends on a straight line, and at the level of the sixth or seventh rib or at the level of the xiphoid process turns to the right where it is continuous with the inferior boundary of the pleural sac. On the left side, the anterior boundary also descends obliquely from the sternoclavicular joint to the midline, but for a lesser distance than the anterior boundary on the right side. On the level of the fourth rib it deviates laterally and leaves a triangular area of the pericardium that is not covered with the pleura. Then the anterior boundary of the left pleural sac descends parallel to the sternal border to the level of the sixth costal cartilage where it deviates laterally and downward and is continuous with the inferior boundary.

The *inferior boundary* of the pleural sacs is the line of the junction of the costal and diaphragmatic pleurae. On the right side it crosses the seventh rib on the mamillary line and the ninth rib on the axillary line, and then passes horizontally across the tenth and eleventh ribs to its junction with the posterior boundary at the head of the twelfth rib. On the left side the inferior boundary is on a somewhat lower level than that on the right.

The boundaries of the lungs coincide not in all places with those of the pleural sacs. The position of the pulmonary apices and posterior borders are in line with the boundaries of both pleurae. The anterior border of the right lung also coincides with the pleural boundary. The anterior border of the left lung coincides with the pleural boundary only to the level of the fourth intercostal space. The border of the left lung, forming here the cardiac notch, is displaced to the left of the pleural boundary. The inferior borders of the lungs pass at a much higher level than the inferior boundaries of both pleurae. The inferior border of the right lung passes in front behind the sixth rib, approaches the inferior border of the sixth rib on the mamillary line, crosses the eighth rib on the axillary line and the tenth rib on the scapular line, and reaches the superior border of the eleventh rib at the spine. The border of the left lung is somewhat lower. Reserve spaces are formed by two parietal layers of the pleura where the pulmonary borders do not coincide with the pleural boundaries; these are the **pleural recesses**, or **sinuses** (*recessus s. sinus pleurales*). The lung enters them only during very deep inspiration. The largest one, the **costodiaphragmatic recess** or **phrenicocostal sinus** (*recessus costodiaphragmaticus s. sinus phrenicocostalis*) (BNA), is situated on the right and left sides along the inferior boundary of the pleura, between the diaphragm and the thoracic cage; the inferior pulmonary borders do not reach the pleural boundaries here. Another, smaller, reserve space is at the anterior border of the left lung. It extends for the distance of the cardiac notch between the costal and mediastinal pleurae and is called the **costomediastinal recess**, or **sinus** (*recessus s. sinus costomediastinalis*). Fluid (inflammatory exudate) produced in inflammation of the pleura (pleurisy) accumulates first of all in the pleural sinuses. Being part of the pleural cavity, the pleural sinuses nevertheless differ from it. The pleural cavity is the space between the visceral and parietal pleurae; pleural sinuses are reserve spaces of the pleural cavity between two layers of the parietal pleura.



## DEVELOPMENT OF THE RESPIRATORY ORGANS

The organs of respiration are laid down at the end of the third week of embryonic life as a protrusion of the ventral wall of the foregut directly behind the germ of the thyroid gland. This hollow protrusion is soon subdivided in the caudal end into two parts corresponding to the future two lungs; the cranial end forms the larynx, caudally to it, the trachea (Fig. 252).

The laying down of the laryngeal cartilages begins in the surrounding mesoderm of the visceral arches as early as the end of the first month. The cartilaginous rings of the trachea form later. The larynx reaches final development after birth, in the period of puberty; it grows more intensely in males and is larger than the female larynx. The growth of the larynx in boys intensifies considerably just before puberty and at this time their voice alters ("breaks"). The male larynx is larger than the female larynx by one third, on the average, and produces a prominence on the neck (Adam's apple), which is never encountered in females. The average length of the larynx is 44 mm in males and 36 mm in females. The fact that the voice of eunuchs preserves a high tone like that of the female voice is also evidence of the effect of the sexual glands on the larynx.

The germs of both lungs are asymmetric, the germ of the right lung is larger than that of the left. Spherical diverticuli appear later on each pulmonary germ, which correspond to the future pulmonary lobes; there are three diverticuli on the germ of the right lung and two on that of the left lung. On the ends of these diverticuli appear new ones, and on the ends of the latter still newer diverticuli so that the picture resembles the development of an acinar gland. The bronchial tree develops on the sixth month in this manner; acini and alveoli form on the ends of its ramifications. The mesenchyme investing each pulmonary germ penetrates between the parts that are forming and gives rise to the connective tissue, smooth muscles, and the cartilaginous laminae in the bronchi. The epithelium of the mucous membrane and glands arises from the entoderm. The pulmonary pleura is derived from the splanchnopleura, while the formation of the pleural sacs parallels the development of the lungs, heart, and pericardium.

**The lungs of a live person.** On X-ray examination of the chest (Fig. 253) the shadows of two "lung fields" of low density are clearly visible. These fields characterize the lungs, which, being filled with air, permit easy passage for the X-rays and produce white but not dark shadows. The lungs are separated one from the other by an intensive median shadow produced by the sternum, spine, heart, and large vessels. This shadow forms the medial

Fig. 251. Boundaries of the lungs and pleura (after Sinelnikov).

- |   |                                      |
|---|--------------------------------------|
| a, anterior aspect:                     | b, posterior aspect:                 |
| 1, cupula pleurae;                      | 1, linea paravertebralis;            |
| 2, apex pulmonis;                       | 2 and 13, linea scapularis;          |
| 3, linea parasternalis (sinistra);      | 3 and 12, fissa obliqua;             |
| 4, linea medioclavicularis (sinistra);  | 4, posterior border of right lung;   |
| 5, anterior pleural boundary;           | 5, posterior pleural boundary;       |
| 6, anterior border of left lung;        | 6, inferior border of right lung;    |
| 7, pleura pericardiaca;                 | 7, pleura diaphragmatica;            |
| 8, incisura cardiaca pulmonis sinistri; | 8, pleura costalis (cut off);        |
| 9, inferior border of left lung;        | 9 and 10, inferior pleural boundary; |
| 10, inferior pleural boundary;          | 11, inferior border of left lung;    |
| 11, pleura diaphragmatica;              | 14, apex pulmonis;                   |
| 12, vertebra thoracica XII;             | 15, cupula pleurae.                  |
| 13, inferior pleural boundary;          | c, lateral aspect (right lung):      |
| 14, inferior border of right lung;      | 1, apex pulmonis;                    |
| 15, anterior border of right lung;      | 2, linea axillaris;                  |
| 16, anterior pleural boundary;          | 3, fissa horizontalis;               |
| 17, linea medioclavicularis (dextra);   | 4, fissa obliqua;                    |
| 18, linea parasternalis (dextra);       | 5, inferior border of lung;          |
| 19, linea sternalis.                    | 6, pleura diaphragmatica;            |
|   | 7, inferior pleural boundary;        |
|   | 8, pleura costalis (cut off);        |
|   | 9, linea axillaris                   |

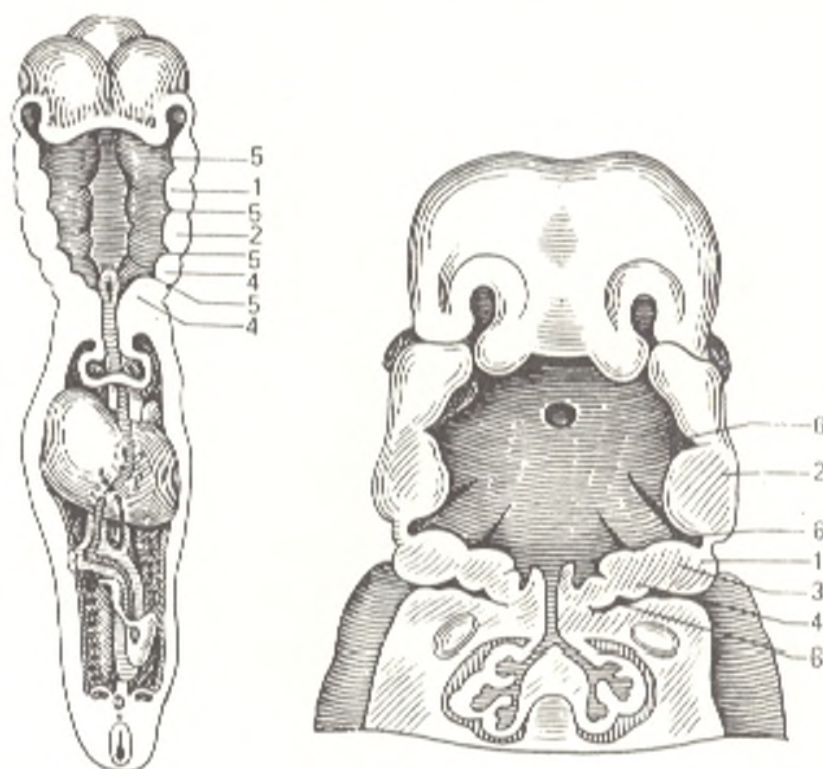


Fig. 252. Formation of branchial pouches in a human embryo (frontal section).

1, 2, 3, and 4, branchial arches; 5 and 6, branchial pouches

boundary of the lung fields; the superior and lateral boundaries are formed by the ribs. Below is the diaphragm.

The superior part of the lung field is crossed by the clavicle, which separates the supraclavicular region from the subclavicular region. The intersecting anterior and posterior segments of the ribs are superimposed on the lung field below the clavicle. They run obliquely: the anterior segments upward and medially, and the posterior segments downward and laterally<sup>1</sup>. The spaces between the anterior costal segments are used as guiding points in determining the different sites in the lung field.

The pulmonary tissue proper is seen in low-density rhomboid spaces between the ribs. A net-like or spotty pattern is noticeable here; it consists of more or less narrow strand-like shadows of higher density in the region of the pulmonary hili and gradually diminishing in density from the midline of the heart to the periphery of the lung fields. This is the lung pattern. On either side of the heart for the distance of the anterior segments of the second, third, fourth, and fifth ribs, are peculiar intensive shadows of the pulmonary roots; they are called the hilar or root shadows. They are separated from the shadow of the heart by a low-density band produced by the principal bronchi. The shadow of the left root is a little shorter and narrower because it is covered more than the shadow of the right root by the heart shadow.

<sup>1</sup> Here we have in view only the osseous parts of the ribs, because the cartilaginous parts, the costal cartilages, are not demonstrated by X-ray.



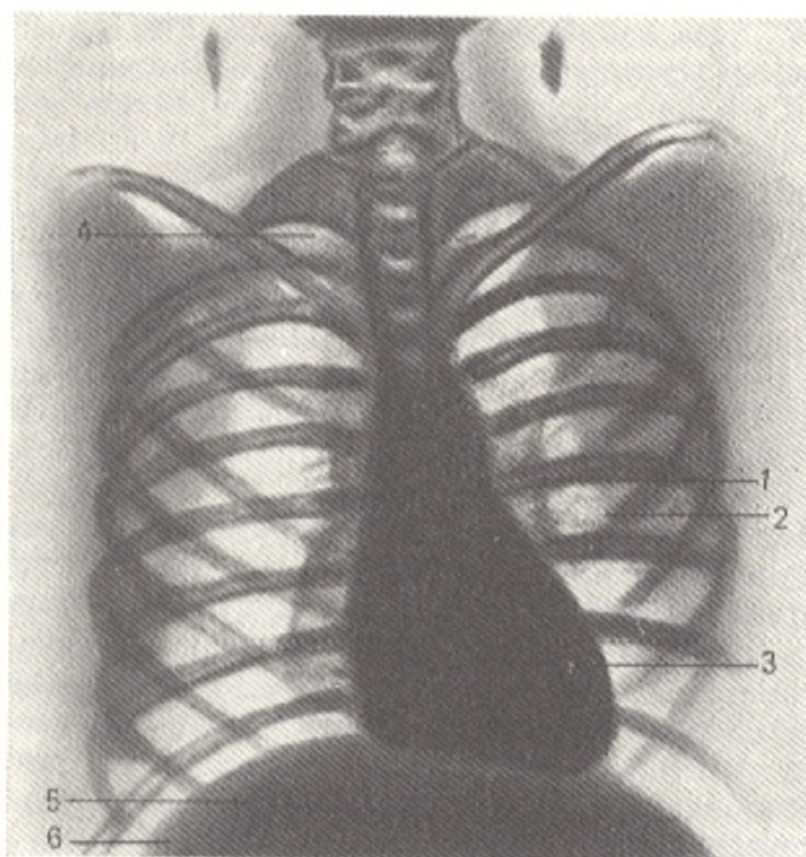


Fig. 253. Radiograph of thoracic cage.

1, shadow of hilum;  
2, pulmonary pattern;  
3, median shadow of heart and large vessels;

4, region of pulmonary apex;  
5, diaphragm;  
6, pleural sinus

The anatomical foundation of the hilar shadow and of the lung pattern is the vascular system of pulmonary circulation, the pulmonary arteries and veins and their branches arising radially from them and in turn ramifying into smaller branches. (The lymph nodes produce no shadow normally; they are demonstrated only if they are enlarged or had undergone calcification of a pathological character.)

The anatomical substrate of the lung pattern and the shadows of the hili is particularly clearly visible in tomography (body section radiography), which makes it possible to take radiographs of separate layers of the lung without the ribs being superimposed on the lung field. The lung pattern and the shadows of the roots are signs of a normal X-ray picture of the lungs at any age, including early childhood. Areas of low density corresponding to the pleural sinuses are seen in inspiration.

The *diaphragm* is also examined during X-ray of the chest of a live person. It is demonstrated as two arched lines convex upward, these are its cupulae. The right cupula is more convex and higher than the left (due to the liver). The outlines of the diaphragm are regular, but in deep inspiration they are wavy due to contraction of the muscles.

The position and shape of the diaphragm vary considerably and depend on: (1) respiration (in inspiration the diaphragm descends and flattens out,

in expiration it rises and becomes convex); (2) the tonus of its muscles; (3) intra-abdominal pressure and the condition of the muscles of the anterior abdominal wall (if the muscles are weak the diaphragm is situated lower); (4) position of the body (the diaphragm is higher in a sitting position than when a person is in a recumbent position); (5) the shape of the thorax (the diaphragm is higher in a short and broad chest than in a narrow and long chest); (6) the degree of nourishment of the person examined (the diaphragm is higher in obese than in lean individuals); (7) general constitution (it is higher in the brachymorphic than in the dolichomorphic type); (8) age (higher in young boys than in adults); (9) sex (the diaphragm is higher in females than in males). The height of the level of the diaphragm, therefore, varies depending on the ratio in the given individual of the factors listed. This explains the variability of the skeletopy of the diaphragm.

In a cadaver, the diaphragm always occupies an extreme position: it descends to the lowest level (at maximum contraction as a consequence of rigor mortis) soon after death, but then takes the highest position (passive overstretching). The last named position is explained by (1) the suction action of the collapsing lungs and (2) pressure exerted on the diaphragm by gases produced in the gastro-intestinal tract. This is the position, in which it is found in a cadaver. In a live person the diaphragm never reaches the extreme level encountered in a cadaver. The tendinous centre is displaced a little in respiration.

X-ray examination makes it possible to study changes in the relations of the thoracic organs in *respiration*. On inspiration, the diaphragm descends, its cupulae flatten out, and the centre moves somewhat downward. The ribs are raised and the intercostal spaces become wider. The shadows of the lung fields become less dense and the lung pattern is more clear. The pleural sinuses become "whiter" and visible. The heart takes a more vertical position and a shape closer to triangular. In expiration, the relations are of an opposite character. Radiokymography can also be used for studying the activity of the diaphragm in breathing, singing, speaking, etc.

The structure of the lung is demonstrated better in body section radiography (tomography) than in ordinary radiography or radioscopy. Separate pulmonary structures, however, cannot be differentiated on tomograms. This becomes possible with the use of another method of X-ray examination, namely electroradiography. The radiographs produced by this method without injection demonstrate not only the tubular systems of the lung (bronchi and blood vessels) but also the connective-tissue foundation of the lung. As a result the structure of the parenchyma of the whole lung can be studied in a living subject.

## THE UROGENITAL SYSTEM

The urogenital system (*system urogenitale*) consists of the urinary organs (*organa uropoietica*) and the reproductive, or genital organs (*organa genitalia*). These organs are closely related developmentally and, in addition,

their excretory ducts either unite to form a single urogenital tube (the urethra in males) or drain into a common space (the vestibule of the vagina in females).

## THE URINARY ORGANS

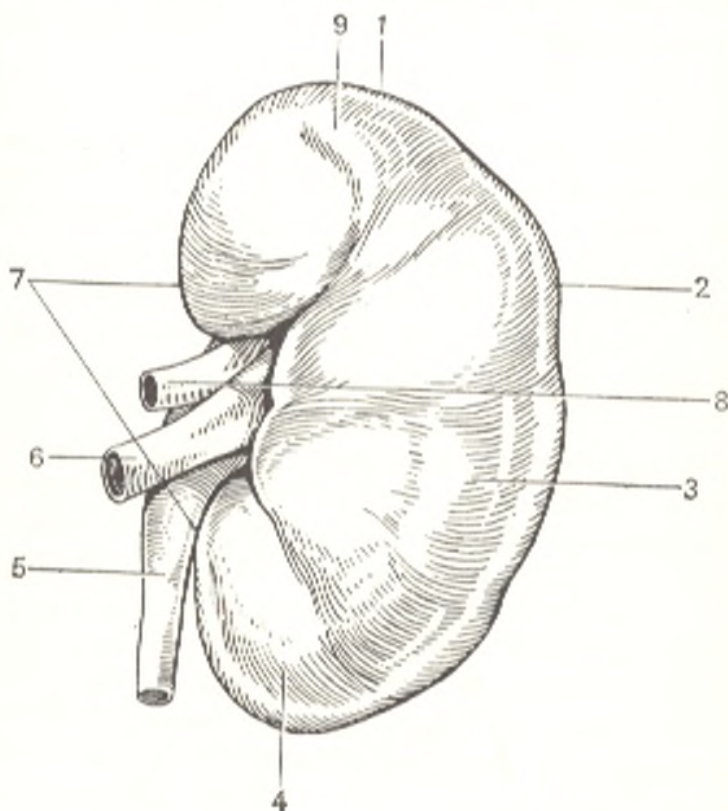
The **urinary organs** (*organa uropoietica*) are, firstly, two glands (the kidneys whose excretion is the urine) and, secondly, organs concerned with the storage and excretion of the urine (the ureters, urinary bladder, and urethra).

### THE KIDNEY

The **kidney** (*ren*, Gk *nephros*) is a paired excretory organ producing the urine (Fig. 254). The kidneys are situated on the posterior abdominal wall behind the peritoneum on either side of the vertebral column on the level of the last thoracic and upper two lumbar vertebrae (see Fig. 218). The right kidney is a little lower than the left, by 1.0-1.5 cm on the average (depending on the pressure exerted by the right lobe of the liver). The upper end of the kidney reaches to the level of the eleventh rib, the lower end is 3-5 cm from the iliac crest. Individual variations are encountered, however, in the position of the kidneys: upper boundary often rises to the level of the superior border of the eleventh thoracic vertebra, the lower boundary may descend for the length of half or a whole vertebra. The kidney is bean-shaped (see Fig. 251), its surface is smooth and dark red. In the kidney are distin-

Fig. 254. Left kidney (outer aspect).

- 1, extremitas superior;
- 2, margo lateralis;
- 3, facies anterior;
- 4, extremitas inferior;
- 5, ureter;
- 6, v. renalis;
- 7, hilus renalis;
- 8, a. renalis;
- 9, impressio lienalis



guished the **upper and lower inferior ends** (poles) or **extremities** (*extremitas superior* and *extremitas inferior*), the **lateral and the medial margins** (*margo lateralis* and *margo medialis*), and the **anterior and the posterior surfaces** (*facies anterior* and *facies posterior*). The lateral margin is convex, while the medial margin has a concavity in the middle and faces not only medially, but slightly downward and to the front. The middle concave part of the medial margin contains the *hilum of the kidney* (*hilus renalis*) through which arteries and nerves enter the kidney and veins and the urethra leave it. The hilum opens into a narrow hollow extending into the renal substance; it is called the *sinus of the kidney* (*sinus renalis*) and its longitudinal axis coincides with the longitudinal axis of the kidney. The anterior surface of the kidney is more convex than the posterior surface.

**Topography of the kidneys.** The relations of the anterior surfaces of the right and left kidneys to the organs are different. The right kidney is projected on the anterior abdominal wall in the epigastric, umbilical, and right lateral abdominal regions, the left kidney is projected in the epigastric and left lateral abdominal regions. A small area of the anterior surface of the *right kidney* is related to the suprarenal gland, further downward a greater part of this surface adjoins the liver, while its lower third comes in contact with the right flexure of the colon; the descending part of the duodenum passes on the medial border of the kidney; the latter two areas are not covered by peritoneum. The distal end of the right kidney has a serous covering. Near to the upper end, part of the anterior surface of the *left kidney* like that of the right kidney, is covered by the suprarenal gland, immediately below this area the upper third of the surface is related to the stomach, the middle third to the pancreas, and the upper part of the lateral border of the anterior surface to the spleen. The lower end of the anterior surface is related to the jejunal loops medially and the left flexure of the colon or the initial part of the descending colon laterally. The upper part of the posterior surface of both kidneys lies on the diaphragm, which separates the kidney from the pleura; below the twelfth rib the posterior surface is related to the *psoas major* and *quadratus lumborum* muscles forming the seat for the kidney.

**The capsules of the kidney.** The kidney is invested in its own **fibrous capsule** (*capsula fibrosa*), a fine smooth lamina intimately attached to the renal substance. Normally it can be separated from the renal substance quite easily. The fibrous capsule consists of three layers: (1) an outer fibrous layer; (2) a middle muscular layer (an incomplete layer of smooth muscle fibres), and (3) an inner supraparenchymatous layer. Due to such structure the fibrous capsule accomplishes its functions: mechanical (fixation of the kidney and protection of its parenchyma) and contractile, facilitating filtration. Outside this fibrous capsule, particularly in the region of the hilum and on the posterior surface, is a layer of loose fatty tissue forming the **fatty capsule** (renal fat) (*capsula adiposa*) of the kidney; the anterior surface is quite often not covered by fat. Outside, each kidney is invested in a connective-tissue **fascia** (*fascia renalis*), which is connected with the fibrous capsule by means of fibres and separates into two layers, one covering the anterior and the other the posterior surface. On the lateral border of the

kidney, both layers unite and are continuous with a layer of retroperitoneal connective tissue, which had given origin to them. On the medial margin of the kidney, the layers do not unite but pass separately to the midline: the anterior layer passes in front of the renal vessels, aorta, and vena cava inferior to unite with its fellow layer of the contralateral side; the posterior layer passes in front of the vertebral bodies and is attached to them. At the upper extremity of the kidney, both layers also invest the suprarenal gland and unite, thus limiting movement of the kidney in this direction. Such union of the layers is usually not noticeable on the lower extremity.

A complex of the following structures is responsible for **fixation of the kidney** in place: (1) fascia renalis, which fuses with the renal capsules; (2) the muscular seat of the kidney formed by the psoas major and quadratus lumborum muscles; (3) the renal vessels, which prevent the kidney from moving away from the aorta and vena cava inferior, and, finally, (4) intra-abdominal pressure produced by contraction of the muscles of the abdominal wall. If this fixation apparatus is weak, the kidney may descend (mobile, or wandering kidney), which calls for its operative fixation with sutures. Normally, the long axes of both kidneys, being directed upward and medially, meet above the kidneys at an angle open downward. In nephroptosis, the kidneys being held in place on the midline by the vessels are displaced downward and medially, like on the periphery of a circle. As a result, the long axes of the kidneys intersect below them, forming an angle open upward.

**Structure.** On a longitudinal section (Figs. 255 and 256) through the kidney it can be seen that it is composed of a cavity, the renal sinus, containing the calyces and the upper part of the renal pelvis, and of the renal substance proper adjoining the sinus on all sides except for the hilus. The **cortex** (*cortex renis*) and the **medulla** (*medulla renis*) are distinguished in the kidney.

The cortex occupies the peripheral layer of the organ and is about 4 mm thick. The medulla is formed of conical structures called the *renal pyramids* (*pyramides renales*), or pyramids of Malpighi. The wide *bases* of the pyramids face the surface of the organ, the *apices* are directed toward the sinus. Two or more apices join to form rounded eminences termed the *renal papillae* (*papillae renales*); less frequently a single apex constitutes one separate papilla. There are a total of about 12 papillae on the average. Each papilla is dotted with small openings, *papillary foramina* (*foramina papillaria*), through which urine is discharged into the initial parts of the urinary tract (the calyces). The cortex penetrates between the pyramids and separates one from another; these parts of the cortex are known as the *renal columns* (*columnae renales*). The pyramids appear striated because the urinary tubules and the vessels are arranged in them in a straight direction. The presence of the pyramids reflects the lobular structure of the kidney, which is characteristic of most animals. Kidneys of different structure are encountered in mammals, they reflect the different phases of the fusion of the separate lobes to form a single organ. Among them are:

(1) kidneys composed of separate lobules (*reniculi*)—lobular kidney, e.g. in a bear;

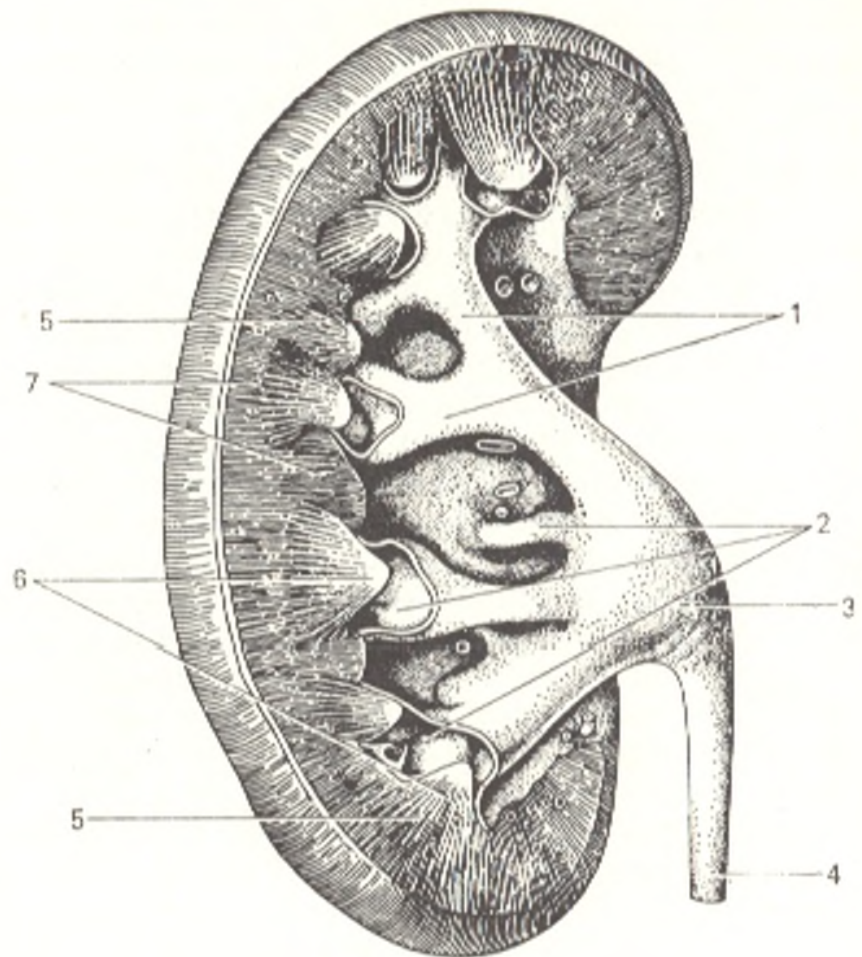


Fig. 255. Longitudinal section through kidney.

- 1, calyces renales majores;  
 2, calyces renales minores;  
 3, pelvis renalis;  
 4, ureter;  
 5, medulla renalis (pyramides renales);  
 6, papillae renalis;  
 7, cortex renalis

(2) kidneys fused to form a single organ but bearing traces of separation, both inside in the form of lobules and on the outer surface in the form of grooves—grooved kidneys, e.g. in cattle;

(3) kidneys fused to form a single organ with a smooth outer surface and divided inside into pyramids and papillae—smooth multipapillary kidneys, e.g. in the pig;

(4) kidneys fused both outside and inside with the formation of a single papilla—monopapillary kidneys of some mammals, e.g. the horse.

The human kidney belongs to the group of smooth multipapillary kidneys. Evidence of this is the presence of grooves on the outer surface of the kidney of the newborn as signs of the original separation (grooved kidney of the foetus and the newborn). In an adult, the kidney is smooth on the outside but inside it remains separated into lobules, pyramids, though several pyramids fuse to form a single papilla (which explains why the number of papillae is less than the number of pyramids).

The striae of the medulla continue also in the cortex but are less distinct here; they form the *radiate part* (*pars radiata*) of the cortex, whereas the part between them is the *convoluted part* (*pars convoluta*) (L *convolvere* to roll together). The radiate and convoluted parts are united under the term *cortical lobules* (*lobulus corticalis*).

The kidney is a complex excretory organ. It contains tubules called

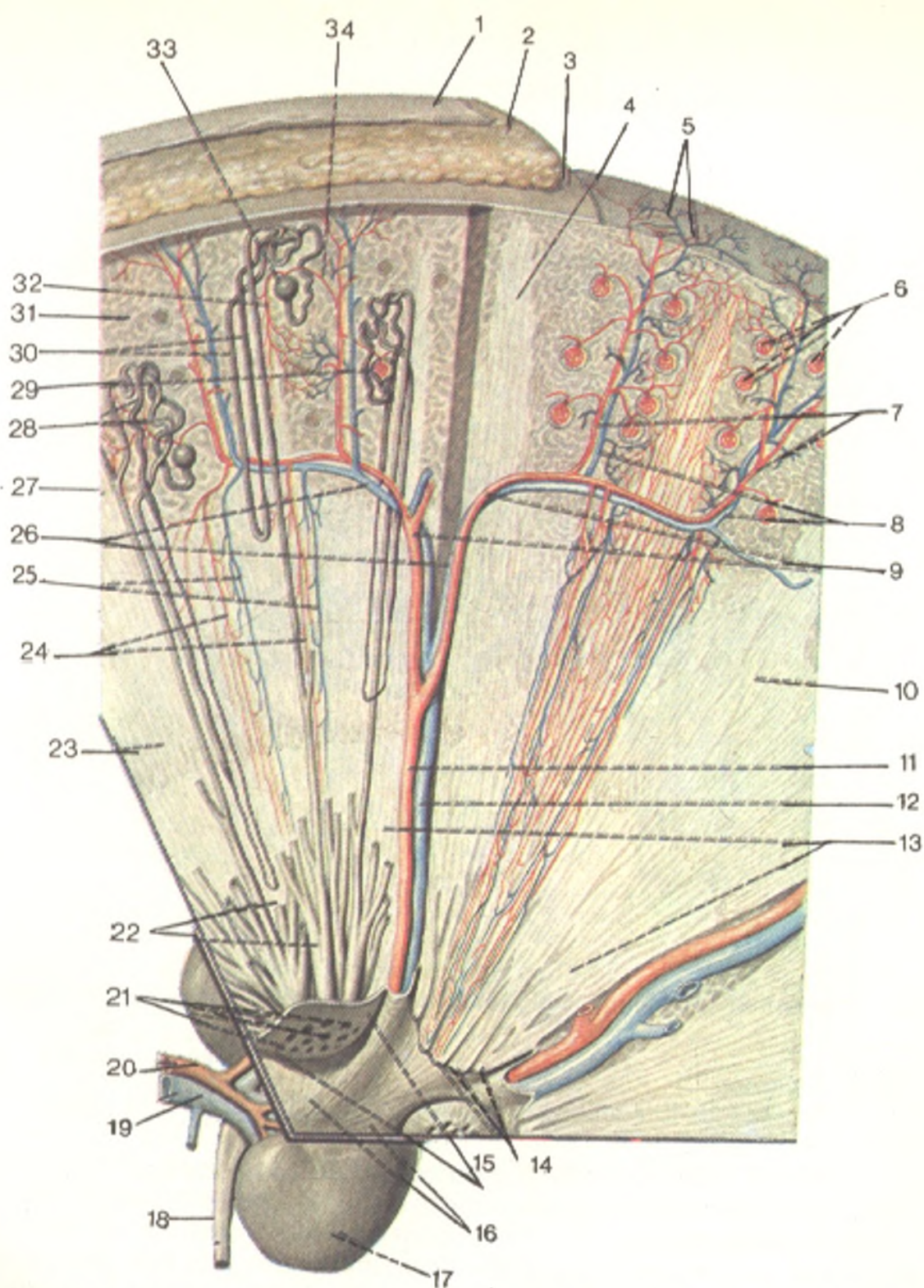


Fig. 256. Structure of the kidney (represented schematically, after Sinelnikov).

- |                              |  |
|------------------------------|--|
| 1, fascia renalis;           | 19, v. renalis;                                |
| 2, capsula adiposa;          | 20, a. renalis;                                |
| 3, capsula fibrosa;          | 21, foramina papillaria;                       |
| 4, pars radiata;             | 22, ductus papillares;                         |
| 5, vv. stellatae;            | 23, medulla renalis;                           |
| 6, glomeruli;                | 24, arteriolae rectae;                         |
| 7, aa. interlobares;         | 25, venulae rectae;                            |
| 8, vv. interlobares;         | 26, vv. arcuatae;                              |
| 9, aa. arcuatae;             | 27, boundary between renal cortex and medulla; |
| 10, pyramis;                 | 28, tubuli renales contorti;                   |
| 11, a. interlobaris renalis; | 29, capsula glomeruli;                         |
| 12, v. interlobaris;         | 30, tubuli renales recti;                      |
| 13, pyramides renales;       | 31, pars convoluta;                            |
| 14, papilla renalis;         | 32, vas efferens;                              |
| 15, area cribrosa;           | 33, corpusculum renalis;                       |
| 16, calyces renales minores; | 34, vas afferens;                              |
| 17, ren;                     |  |
| 18, ureter;                  |  |

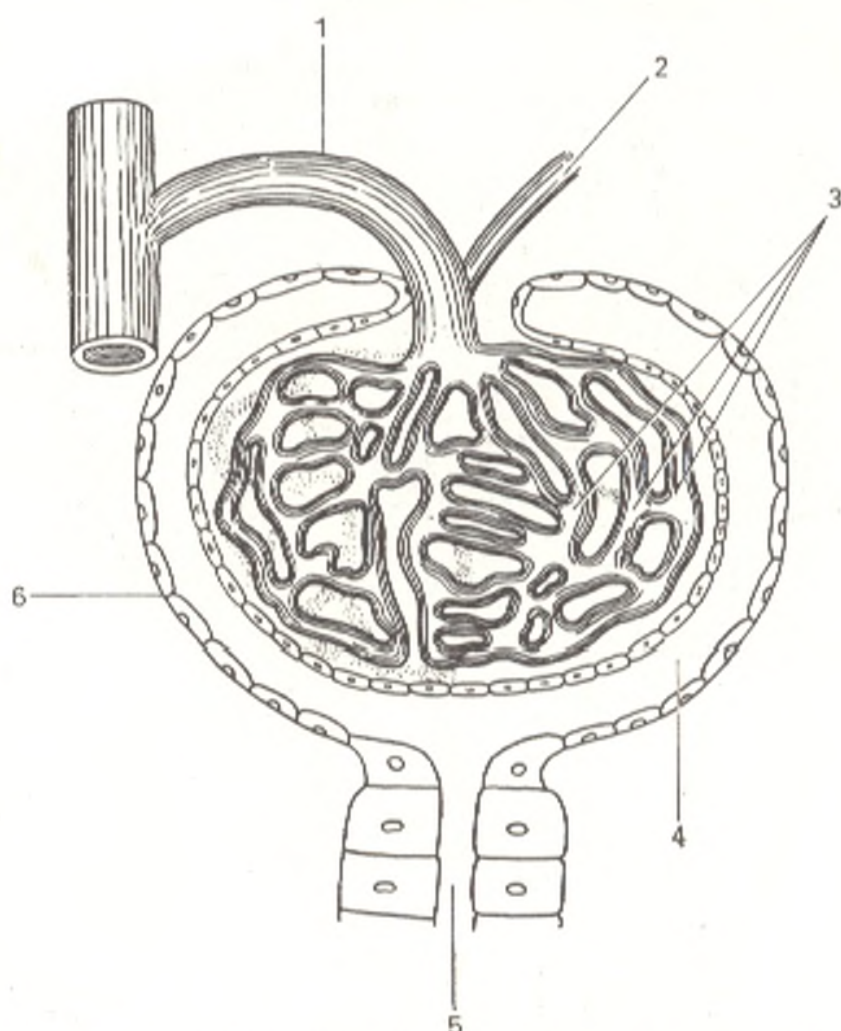


Fig. 257. Structure of the Malpighian-Shumlyansky corpuscle represented schematically.

1, vas afferens;  
2, vas efferens;  
3, glomerular capillaries;

4, cavity of capsule of Malpighian-Shumlyansky corpuscle bounded by the layers of the capsule;  
5, convoluted tubule;  
6, Shumlyansky-Bowman capsule

urinary, or renal tubules (*tubuli renales*). The blind ends of these tubules surround, as double-walled capsules, tufts of capillary blood vessels (Fig. 257). Each tuft, or **glomerulus**, lies in a deep bowl-like hollow of the capsule known as the *glomerular capsule* (*capsula glomeruli*), or the Shumlyansky-Bowman capsule; the space between the two layers of the capsule is its cavity and the beginning of the renal tubule. The glomerulus together with the capsule enclosing it forms the *renal corpuscle* (*corpusculum renis*), or the Malpighian-Shumlyansky corpuscle<sup>1</sup>. The renal corpuscles are in the convoluted part of the cortex and can be seen in it with the naked eye as red dots. The renal corpuscle (the Shumlyansky-Bowman capsule, to be more precise) gives rise to the *convoluted tubule* (*tubulus renalis contortus*) (Fig. 258),

<sup>1</sup> The true nature of the renal corpuscle was discovered by Shumlyansky and not Malpighi who believed it to be a gland. Therefore, the term Malpighian-Shumlyansky corpuscle is more correct than the name Malpighian corpuscle.



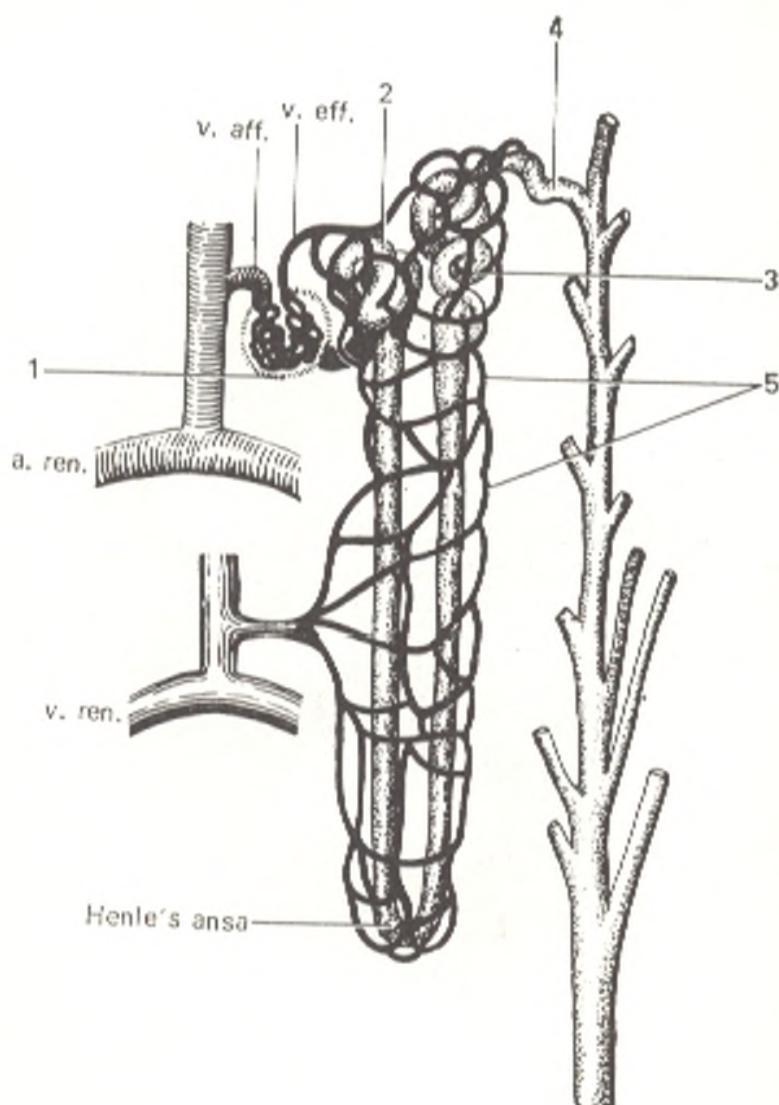


Fig. 258. Structure of nephron represented schematically.

- 1, renal corpuscle;  
 2 and 3, convoluted tubules;  
 4, junctional segment draining into collecting tubule;  
 5, capillaries of convoluted tubules;  
 v. aff., vas afferens; v. eff., vas efferens; a. ren., a. renalis; v. ren., v. renalis.

which passes in the radiate part of the cortex. The tubule then descends into the pyramid, bends upon itself to form Henle's loop (*ansa*) (*ansa nephroni*) and returns into the cortex. The terminal segment of the renal tubule, the junctional segment, drains into the *collecting tubule* (*tubulus renalis colligens*), which receives several tubules and passes in a straight direction (*tubulus renalis rectus*) through the radiate part of the cortex and the pyramid. The straight tubules gradually fuse with one another to form 15 to 20 short *papillary ductules* (*ductus papillares*) opening by means of the papillary foramina in the cribriform area on the apex of the papilla.

The structural unit of the kidney is the nephron. According to the findings of microscopic anatomy, it consists of the following parts.

1. The **corpuscle of the kidney** (*corpusculum renis*).
2. The renal corpuscle gives rise to the **proximal segment** consisting of the **proximal convoluted tubule** (the beginning of the segment), which is continuous with the **proximal straight tubule**.
3. The proximal straight segment is continuous with a thin loop, **Henle's loop**, which has two limbs, **descending** and **ascending**.

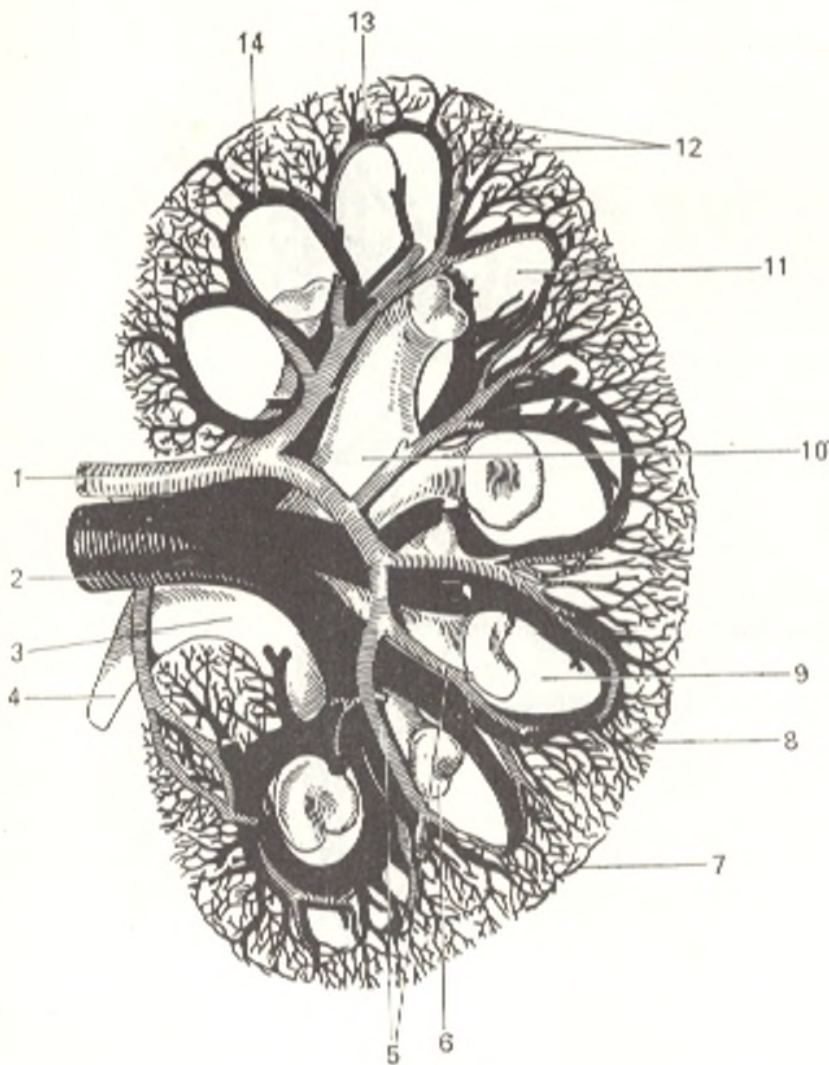


Fig. 259. Excretory tree and vessels of kidney (after Kiss and Szentagóthai).

- 1, a. renalis;  
 2, v. renalis;  
 3, ureter;  
 4, pelvis renalis;  
 5, aa. interlobares;  
 6, calyx renalis minor;  
 7, v. stellata;  
 8 and 11, pyramides renales;  
 9, v. interlobaris;  
 10, calyx renalis major;  
 12, aa. interlobulares;  
 13, a. arcuata;  
 14, v. arcuata

4. The ascending limb of Henle's loop is continuous with the distal segment consisting of a thick ascending limb in turn continuous with the distal convoluted tubule and then with the junctional tubule.

The junctional tubule drains into the collecting tubule.

These structural components of the nephron are arranged in the kidney parenchyma in the following order.

The renal corpuscle, the convoluted and straight tubules of the proximal segment, the thick ascending limb of the nephron loop, and the distal convoluted and junctional tubules are situated in the cortex. The thin ascending and descending limbs of Henle's loop, the thick ascending limb of the nephron, and the collecting tubule are situated in the medulla.

The nephron is concerned with the production of urine: ultrafiltration takes place in the glomeruli, reabsorption and secretion in the tubules.

Each kidney contains up to one million nephrons, the totality of which constitutes the main bulk of the renal substance. To understand the structure of the kidney and its structural unit, the nephron, one must know

its *vascular system* (Fig. 259). The renal artery arises from the aorta and has a large calibre, which corresponds to the urogenous function of the organ associated with "filtration" of blood.

At the renal hilum, the renal artery separates into arteries according to the parts of the kidney, namely vessels for the upper pole, the superior polar arteries, for the lower pole, inferior polar arteries, and for the middle part of the kidney, the central arteries. In the kidney parenchyma, these arteries pass between the pyramids, i.e. between the lobes of the kidney, and are, therefore, called the interlobar arteries (aa. interlobares renis). At the base of the pyramid at the junction of the medulla and cortex, they form arterial arches, the arciform arteries (aa. arcuatae), which give rise to the interlobular arteries (aa. interlobulares) piercing the cortex. Each interlobular artery gives origin to vas afferens, which ramifies to form a tuft of convoluted capillaries, the glomerulus, invaginated in the initial part of the renal tubule, the Shumlyansky-Bowman capsule. The vas efferens emerging from the glomerulus again breaks up into capillaries, which first surround the renal tubules and only after that they are continuous with the veins. The veins accompany the corresponding arteries and leave the renal hilum as a common trunk, the renal vein (vena renalis) draining into the vena cava inferior.

Venous blood drains from the cortex first into the stellate veins (venulae stellatae), then into the interlobular veins accompanying the interlobular arteries, and then into the arcuate veins. Venous blood from the medulla flows in the venulae rectae. The large venous tributaries unite to form the renal vein. In the region of the renal sinus, the veins are in front of the arteries.

The kidney, therefore, contains two capillary systems: one connects the arteries with the veins while the other is of a special character comprising a vascular tuft, in which blood is isolated from the capsular cavity by only two layers of squamous cells (the endothelium of the capillaries and the endothelium of the capsule). This provides favourable conditions for the excretion of water and metabolites from blood.

The *lymphatic vessels* of the kidney are divided into superficial vessels arising from the capillary networks of the renal capsules and from the peritoneum covering the kidney, and deep vessels passing between the lobules. There are no lymphatics within the lobules or in the glomeruli.

Both vascular systems merge for the most part at the renal sinus, then pass in attendance to the renal blood vessels to the regional lymph nodes, but to different nodes from each kidney: vessels from the right kidney drain into nodes around the vena cava inferior (the pre- and retrocaval nodes), into nodes situated between the vena cava inferior and the aorta (interaortacaval nodes), and into nodes lying in front of the aorta (preaortic nodes); lymphatic vessels from the left kidney drain into nodes situated to the left of the aorta (left latero-aortic nodes) and in front of it (pre-aortic nodes).

The *nerves* of the kidney are derived from the paired renal plexus formed by the splanchnic nerves, branches of the sympathetic ganglia, branches of the solar plexus with fibres of the vagus nerves contained in them, and the afferent fibres of the inferior thoracic and superior lumbar spinal ganglia.

## THE RENAL PELVIS, CALYCES, AND URETER

Urine flowing from the papillary foramina passes on the way to the urinary bladder through the lesser calyces, the greater calyces, the renal pelvis, and the ureter.

The **lesser calyces** (*calyces renales minores*), about eight or nine in number, enclose one, two, rarely three renal papillae with one end and drain into one of the major calyces with the other. There are usually two **greater calyces** (*calyces renales majores*): a superior calyx and an inferior calyx; they merge in the renal sinus to form a single **renal pelvis** (*pelvis renalis*) (Gk *pyelos* pelvis, hence *pyelitis*, inflammation of the renal pelvis), which leaves the kidney through the hilum behind the renal vessels and, curving downward, is continuous with the ureter directly below the renal hilus.

**The fornical apparatus of the calyces.** Each renal calyx surrounds the conical renal papilla like a double-walled goblet. As a result the proximal part of the calyx around the base of the papilla is elevated above the axis of the papilla as a vault, or *fornix*. The wall of the fornix contains smooth muscle fibres (*m. sphincter fornicis*), which, together with the connective tissue embedded here and the adjoining nerves and blood and lymphatic vessels, constitute the *fornical apparatus* of the kidney. It plays an important role in excretion of urine from the renal parenchyma into the renal calyces and prevents the return of urine from the calyces into the renal tubules. Since vessels are in close relation with the wall of the fornix, haemorrhages occur here more easily than in other places and urine passes into the blood (pyelovenous reflux), which is conducive to the penetration of infection. Four muscles are distinguished in the wall of the renal calyx, which are situated above the fornix (*m. levator fornicis*), around it (*m. sphincter fornicis*), along the calyx (*m. longitudinalis calycis*), and around the calyx (*m. spiralis calycis*). The levator fornicis and longitudinal calycis muscles dilate the cavity of the calyx and facilitate urine accumulation (diastole), while the sphincter fornicis and spiral calycis muscles cause constriction of the calyx and evacuation of its contents (systole). The activity of the calyx is connected with the similar activity of the renal pelvis.

The calyces, renal pelvis, and ureters constitute the macroscopically visible part of the *excretory tract of the kidney*.

Three types of the excretory tree can be distinguished, which reflect the successive developmental stages (Fig. 260, *a*, *b*, and *c*).

1. *Embryonal type*, marked by a wide sac-like pelvis, into which the lesser calyces drain directly; the greater calyces are absent.

2. *Foetal type* with many lesser and greater calyces, which are continuous with the ureter; the renal pelvis is absent.

3. *Mature type* with few lesser calyces, which merge to form two greater calyces continuous with a moderately developed pelvis that drains into the ureter. All three components of the excretory tree are present here: the lesser and greater calyces, the renal pelvis, and the ureter. Knowledge of these types makes it easier to interpret the X-ray picture of the excretory tree seen in a **live subject** (in pyelography).

The outlines of the lower half of the kidney can be seen in ordinary radiography of the lumbar region. To demonstrate the whole kidney air must be introduced into the pararenal fat (pneumoradiography).

Skeletopy of the kidney can be determined radiologically. In this case, the twelfth rib is superimposed on the middle of a sabre-shaped kidney and on the upper pole of a stylet-shaped one.

The upper extremities of the kidneys are slightly tilted medially so that the continuations of the longitudinal axes of the organs intersect above them at the level of the ninth or tenth thoracic vertebrae.

X-rays can be used to demonstrate the excretory tree in a living subject (see Fig. 260). For this purpose, a contrast medium is injected into the blood, it is excreted through the kidneys and, mixing with the urine, it produces the outlines of the renal pelvis and ureter on the radiograph (the contrast medium can also be directly infused into the renal pelvis by means of an ureteral catheter and a special instrument, a cystoscope). This method is called ureteropyelography.

The renal pelvis is projected on the radiograph at the level between the first and second lumbar vertebrae, the right a little lower than the left pelvis.

Two types of position of the pelvis in relation to the renal parenchyma are distinguished: extrarenal, in which part of the pelvis is outside the kidney, and intrarenal, in which the renal pelvis does not extend beyond the kidney.

X-ray examination shows peristalsis of the renal pelvis. A series of radiographs demonstrate contraction and relaxation of the separate calyces and the ampulla and the opening and closure of the superior ureteral opening. These functional changes are rhythmic in character and systole and diastole of the excretory tree of the kidney are, therefore, distinguished. Evacuation of the contents of the excretory tree so occurs that the greater calyces contract (systole) while the ampulla relaxes (diastole), and vice versa. Complete evacuation takes 6 to 8 minutes.

**Segmental structure of the kidney.** The kidney contains four tubular systems: arteries, veins, lymphatic vessels, and renal tubules. Parallelism between the vessels and the excretory tree is noted (they form the vascular-excretory bundles) (see Fig. 259). The correspondence between the intra-organic branches of the renal artery and the renal calyces is most manifest. Based on this correspondence, segments are distinguished in the kidney for surgical purposes; they constitute the *segmental structure of the kidney*. Five segments are distinguished: (1) apical, corresponding to the upper extremity of the kidney, and on its surface the area covered by the supra-renal gland; (2) upper anteropelvic, and (3) medial anteropelvic segments situated one above the other and each occupying one quarter of the anterior half of the kidney; (4) lower, extending over the caudal part of the anterior and posterior halves of the organ, i.e. the whole lower extremity; (5) posteropelvic, occupying two middle quarters of the posterior half of the organ between the apical and lower segments. Kidneys are encountered, in which

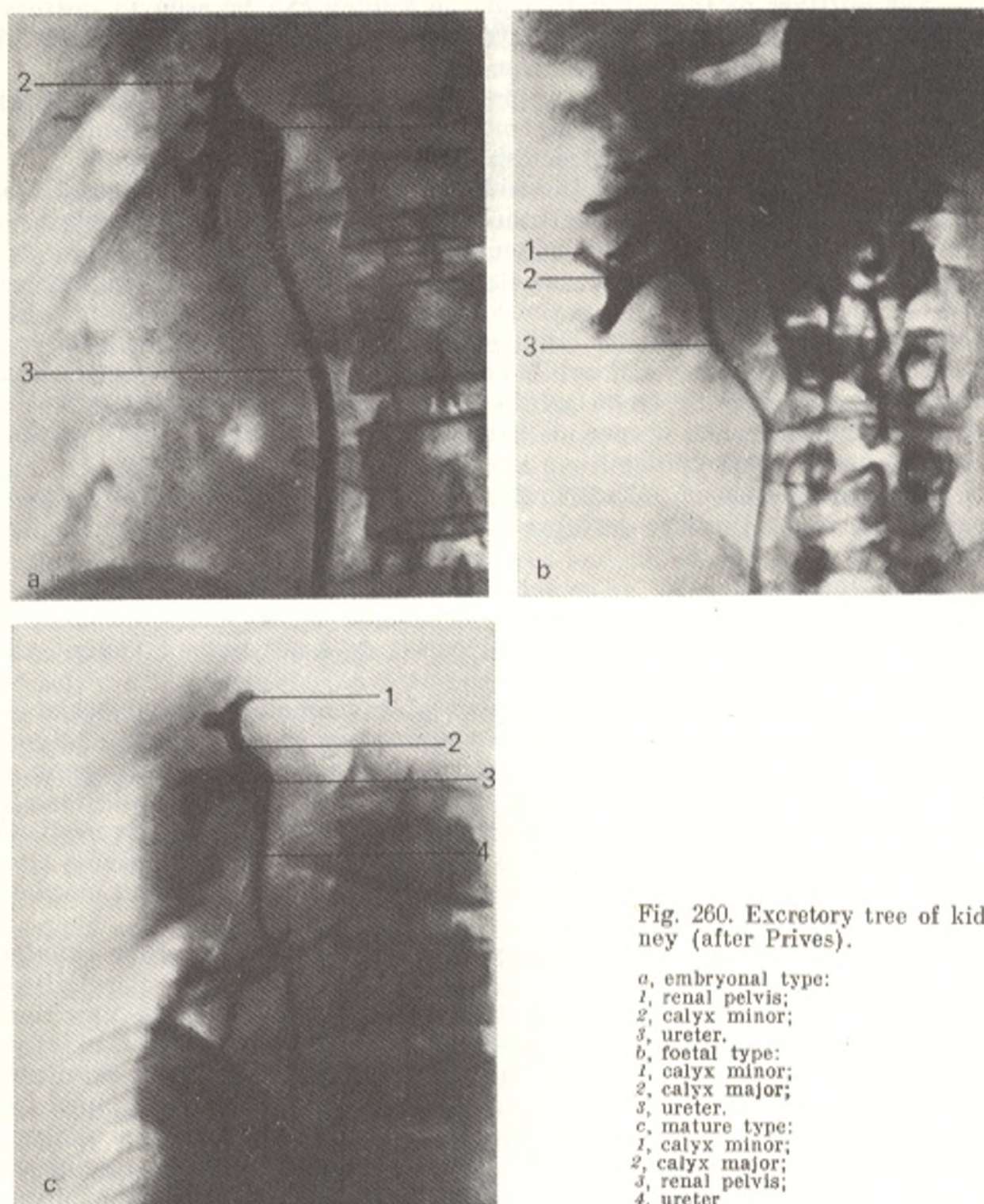


Fig. 260. Excretory tree of kidney (after Prives).

*a*, embryonic type:

1, renal pelvis;

2, calyx minor;

3, ureter.

*b*, foetal type:

1, calyx minor;

2, calyx major;

3, ureter.

*c*, mature type:

1, calyx minor;

2, calyx major;

3, renal pelvis;

4, ureter.

both anteropelvic segments are united into a single segment; in this case only four segments are distinguished.

The **ureter** is a tube about 30 cm long with a diameter of 4-7 mm. From the pelvis the ureter passes behind the peritoneum downward and medially into the true pelvis where it extends to the floor of the urinary bladder whose wall it pierces obliquely. In the ureter are distinguished an

**abdominal part** (*pars abdominalis*), from its origin to the place where it curves over *linea terminalis* to enter the true pelvis, and a **pelvic part** (*pars pelvina*) located in the true pelvis. The ureteral lumen is not uniform in width and has constrictions: (1) near the site where the renal pelvis is continuous with the ureter; (2) at the junction of the abdominal and pelvic parts; (3) along the distance of the pelvic part, and (4) near the wall of the urinary bladder. The female ureter is shorter by 2-3 cm and the relation of its inferior part to the organs differs from those of the male ureter. In the female pelvis, the ureter extends along the free border of the ovary, then at the base of the broad ligament of the uterus it lies lateral to the cervix uteri, penetrates into the space between the vagina and the bladder, and pierces the wall of the bladder in an oblique direction, like the male ureter.

**Structure.** The walls of the ureter, like the walls of the renal pelvis and the calyces, consist of three coats: an outer connective-tissue *adventitious coat* (*tunica adventitia*), an inner *mucous coat* (*tunica mucosa*) covered with transitional epithelium supplied with small mucous glands, and a middle, *muscular coat* (*tunica muscularis*). The muscular coat is formed of two layers (an inner longitudinal and an outer circular layers); these layers are not connected with the musculature of the bladder and prevent urine from flowing from the bladder back into the ureter. At the site where the ureter drains into the bladder is a third, outermost longitudinal muscular layer, which is intimately connected with the muscles of the bladder and contribute to expulsion of urine into the bladder.

The ureter of a **living subject** is demonstrated on a radiograph as a long and narrow shadow stretching from the kidney to the urinary bladder. Its outlines are clear and regular. On the way, the ureter forms curves in two planes, sagittal and frontal. The curves made by the ureter in the frontal plane, in the medial direction in the lumbar part and in the lateral direction in the pelvic part, are of practical importance. In some cases, the ureter is straightened out in the lumbar portion. The curvature of the pelvic portion is constant. In addition to the anatomical constrictions described above, there are some physiological constrictions appearing and disappearing during peristalsis. Three sections—superior, medial, and inferior—are distinguished in such instances; they are called cystoids and now contract, now dilate and thus push the urine along the ureter.

The ureter *receives blood* from several sources. The renal artery supplies branches to the walls of the renal pelvis and upper part of the ureter. Branches to the ureter are also given off by the testicular artery (or the ovarian artery) at their intersection. The middle part of the ureter is supplied with ureteral branches from the aorta, common iliac artery or internal iliac artery. The pelvic part is supplied with nutrients from the middle rectal artery and the inferior vesical arteries. *Venous blood* drains into the testicular (or ovarian) and internal iliac veins. *Lymph* is drained into the abdomino-aortic (lumbar) and iliac lymph nodes.

The *nerves* of the ureter are of sympathetic origin: they run to the upper part from the renal plexus, to the lower portion of the abdominal part from the ureteric plexus, and to the pelvic part from the inferior hypogastric plexus. In addition, the ureters are supplied with parasympathetic innervation from the pelvic splanchnic nerves.

## THE URINARY BLADDER

The **urinary bladder** (*vesica urinaria*) (Fig. 261) is a receptacle for urine, which is excreted at regular intervals through the urethra. Its capacity is 500-700 ml on the average, but may vary considerably in individual cases. The shape of the bladder and its relations to the adjoining organs greatly change depending on the extent of its filling. An empty bladder lies completely in the cavity of the true pelvis behind the pubic symphysis; posteriorly it is separated from the rectum by the seminal vesicles and the terminal parts of ductus deferens in males and by the vagina and uterus in females. When the bladder is filled with urine, its upper part changes in shape and size and rises above the pubis and, if greatly distended, reaches to the level of the umbilicus. A filled bladder is egg-shaped and the lower, wider and attached part, the **base** (*fundus vesicae*) is directed at the rectum or vagina; gradually narrowing, it is continuous with the urethra by means of a **neck** (*cervix vesicae*); the sharpened **apex** of the bladder (*apex vesicae*) is related to the inferior part of the anterior abdominal wall. The middle part between the apex and the base is known as the **body** of the bladder (*corpus vesicae*). A fibrous cord, the *median umbilical ligament* (*lig. umbilicale medianum*) stretches from the apex to the umbilicus on the posterior surface of the anterior abdominal wall to its midline.

The bladder has an anterior, posterior, and lateral surfaces. The anterior surface lies on the pubic symphysis, from which it is separated by loose are-

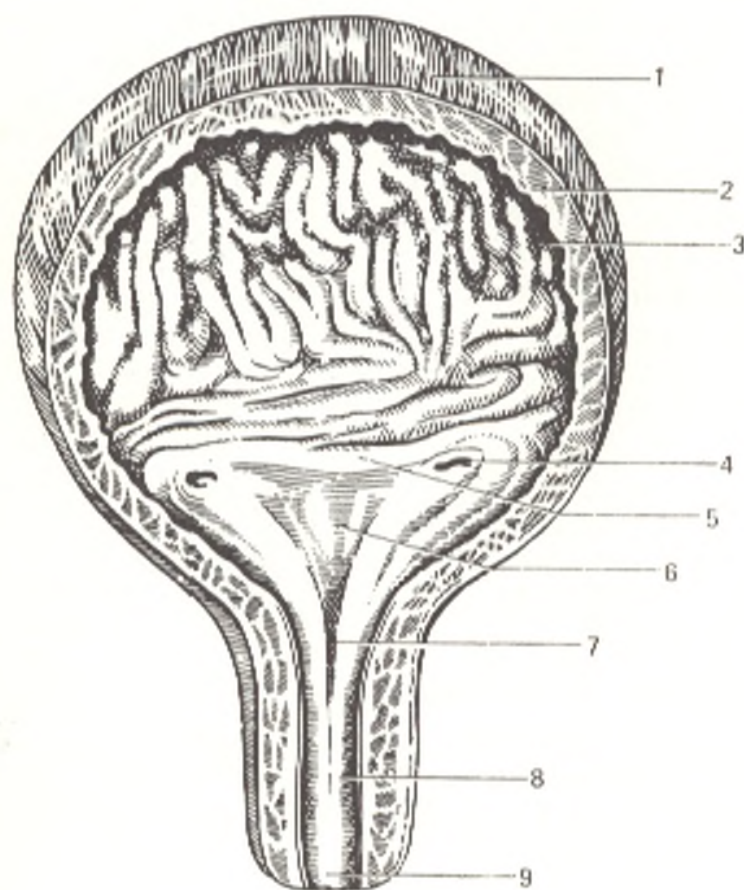


Fig. 261. Female urinary bladder and urethra (after Kiss and Szentagóthai).

- 1, tunica muscularis (stratum externum);
- 2, tunica muscularis (stratum circulare);
- 3, tunica mucosa;
- 4, ostium ureteris;
- 5, plica interureterica;
- 6, trigonum vesicae;
- 7, ostium urethrae internum;
- 8, urethra;
- 9, ostium urethrae externum



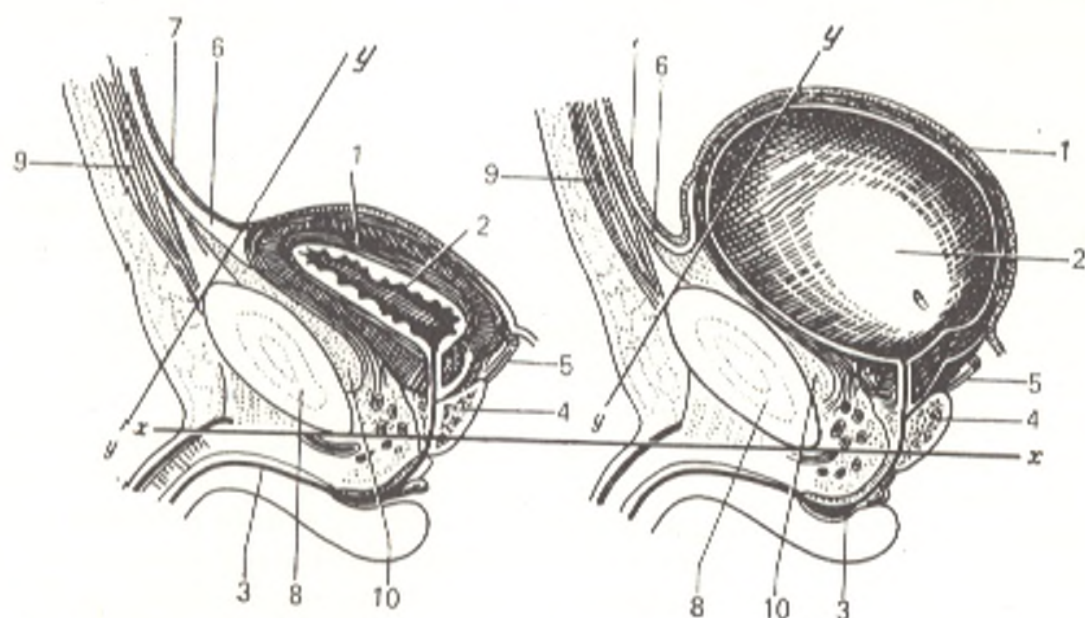


Fig. 262. Median sagittal section through an empty and full male urinary bladder.

1, tunica muscularis vesicae urinariae;  
 2, cavum;  
 3, urethra;  
 4, prostata;  
 5, ductus deferens;  
 6, lig. umbilicale medianum;  
 7, peritoneum;

8, section through symphysis pubica;  
 9, anterior abdominal wall;  
 10, prevesical (retropubic) space; x—x,  
 horizontal plane passing through inferior  
 border of symphysis pubica;  
 y—y, plane of apertura pelvis superior

olar tissue filling the prevesical, or retropubic space (spatium prevesicale s. retropubicum) (Fig. 262). The upper part of the bladder is more mobile than the lower part because the latter is attached by ligaments formed at the expense of the pelvic fascia and in males is also fused with the prostate gland. The superior surface of the bladder is related to the intestinal loops in males and to the anterior surface of the uterus in females. When the bladder is distended by urine, its upper part rises and becomes rounded and protruding above the pubis pulls upward the peritoneum reflected onto it from the anterior abdominal wall. The walls of a distended urinary bladder can, therefore, be punctured through the anterior abdominal coats without involving the peritoneum. Posteriorly, the peritoneum (as it is noted above) is reflected from the superoposterior surface of the bladder onto the anterior surface of the rectum (to form the retrovesical pouch, excavatio retrovesicalis) in males and onto the anterior surface of the uterus (to form the uterovesical pouch, excavatio vesicouterina) in females.

Besides the *serous coat* (*tunica serosa*) covering the posterior wall and apex of the bladder, the constituents of its wall are the *muscular coat* (*tunica muscularis*) formed of smooth muscle fibres, the *submucous coat* (*tela submucosa*) and the *mucous coat* (*tunica mucosa*). Three intertwining strata are distinguished in the muscular coat: (1) external (*stratum externum*) composed of longitudinal fibres; (2) middle (*stratum medium*) of circular or transverse fibres; (3) internal (*stratum internum*) formed of longitudinal and transverse fibres. These three layers of smooth muscle fibres form the common muscle

of the urinary bladder, which, on contraction, reduces the cavity of the bladder and expels the urine from it (the *pubovesical muscle*, or *m. detrusor urinae*; *L. detrudere* to push down).

The middle layer is developed most, especially in the region of the internal orifice of the urethra (*ostium urethrae internum*) where it forms the *sphincter vesicae muscle* (*m. sphincter vesicae*). Around each ureteral orifice is also a sphincter-like structure of strong circular fibres of the internal muscular stratum.

The inner surface of the bladder is lined with the mucous coat, which forms folds in an empty bladder due to the presence of a rather well developed submucous coat. These folds disappear when the bladder is distended. An opening is visible on the inner surface of the inferior part of the bladder, this is the internal orifice of the urethra. Directly behind it is a smooth triangular area called the *trigone of the bladder* (*trigonum vesicae*); its mucous coat adheres to the muscular coat and never forms folds. The apex of the trigone faces the internal urethral orifice; at the corners of the base of the trigone are the orifices of the ureters (*ostia ureteres*). The base is bounded by the *ureteric fold* (*plica interureterica*) passing between the orifices of the ureters. Behind this fold there is a depression in the cavity of the bladder, called the *fossa retroureterica*, which increases in size with the growth of the prostata. Sometimes there is an elevation directly behind the internal urethral orifice; this is the *uvula of the bladder* (*uvula vesicae*), it is mostly found in the elderly due to the strongly developed middle prostatic lobe. The mucous coat of the bladder is reddish in colour and is lined with transitional epithelium similar to the ureteral epithelium. Small mucous vesical glands (*glandulae vesicales*) and lymph follicles are embedded in the mucosa.

The bladder of the newborn occupies a much higher position than that of an adult and the internal urethral orifice is, therefore, on the level of the superior border of the symphysis pubica. After birth, the bladder gradually descends and is approximately only 1 cm above the symphysis pubica by the fourth month of life.

In *cystoscopy*, i.e. examination of the cavity of the urinary bladder in a living subject by means of a cystoscope introduced into the urethra, a pink mucous membrane is seen with many blood vessels forming networks. The mucosa gathers in folds, with the exception of the trigone, where it is smooth. The vesical sphincter has the appearance of a red crescent-shaped area while the orifices of the ureters form depressions on each side of the trigone. At regular intervals (two or three times per minute) they open and expel a thin stream of urine. Urine is discharged from the bladder into the exterior through the urethra.

Roentgenocinematography demonstrates double-phase *urodynamics*, i.e. the process of the excretion of urine along the urinary tract. In the transportation phase the urine moves along the urinary tract due to the action of the detrusor muscles; in the retention phase the given segment of the urinary tract is distended under the action of the sphincter muscles and urine accumulates in it. The whole system of the urinary tract, from the renal calyx to the urethra, is a single hollow muscular organ whose two parts

mutually alternate in function. When the excretory tree is in the transportation phase, the urinary bladder is in the phase of retention, and vice versa.

*Vessels and nerves:* the walls of the bladder receive blood from the inferior vesical artery, which is a branch of the internal iliac artery, and from the superior vesical artery, which is a branch of the umbilical artery. The middle rectal artery and other neighbouring arteries also contribute to vascularization of the bladder. The veins of the bladder drain partly into the vesical venous plexus and partly into the internal iliac vein. *Lymph* flows into the internal iliac lymph nodes.

The bladder is *innervated* from the inferior vesical plexus, which contains sympathetic nerves from the hypogastric plexus and parasympathetic nerves from the pelvic splanchnic nerves.

## THE FEMALE URETHRA

The **female urethra** (*urethra feminina*)<sup>1</sup> (Fig. 261) arises from the urinary bladder by means of an **internal orifice** (*ostium urethrae internum*). It is a tube about 3.0-3.5 cm in length convex slightly to the back and curving behind and below the inferior border of the symphysis pubica. Except during the passage of urine, its anterior and posterior walls are in contact, but they are distinguished by considerable elasticity and the urethral lumen may be distended to a diameter of 7-8 mm. The posterior urethral wall is intimately fused with the anterior wall of the vagina. On leaving the pelvis, the urethra pierces the urogenital diaphragm (see "Muscles of the Perineum") and its fasciae and is surrounded by fibres of the *sphincter urethrae muscle* (*m. sphincter urethrae*). The **external urethral orifice** (*ostium urethrae externum*) opens in front of and above the opening of the vagina and is a narrow part of the urethra. The wall of the female urethra consists of a muscular, submucous, and mucous coats. In the loose submucous coat is a vascular network, which also penetrates into the muscular coat; it lends the tissue a cavernous appearance on section. The mucous coat is arranged in longitudinal folds. Numerous small mucous glands (*glandulae urethrales*) open into the urethra, particularly in the distal portion.

The female urethra receives *arteries* from the inferior vesical and internal pudendal arteries. The *veins* drain by way of the vesical venous plexus into the internal iliac vein. *Lymphatic vessels* from the upper parts of the urethra pass to the iliac lymph nodes, those from the lower parts to the inguinal lymph nodes.

*Innervation* is supplied from the inferior hypogastric plexus, and the pelvic splanchnic and pudendal nerves.

## THE GENITAL ORGANS

**Male genital (or reproductive) organs** (*organa genitalia masculina*) and **female genital organs** (*organa genitalia feminina*) are distinguished. The genitals are laid down in the embryos of both sexes in the same manner, but later in some individuals the germs of the male sex develop, while the germs of the female sex remain rudimentary, in others the opposite occurs. The

<sup>1</sup> The male urethra conducts not only urine but also seminal fluid and is, therefore, discussed below together with the male sex system, like the act of urination itself.

essential component in individuals of both sexes are the sex (reproductive) organs (the testis in the male and the ovary in the female), which produce the sexual cells. Sometimes, characters of both, the male and female, sex develop to a greater or lesser degree in an individual. This state is called hermaphroditism; true and false hermaphroditism are distinguished. True hermaphroditism is the condition in which a single individual has the testes and the ovaries; in false hermaphroditism the individual has the gonads of one sex but the other characteristics are more or less typical of the other sex. The testes and the ovaries produce sex hormones and are, therefore, related to the group of endocrine glands.

## THE MALE GENITAL ORGANS

The male genital, or reproductive organs are: the testes together with their coverings, the ductus deferens with the seminal vesicles, the prostata, Cowper's (bulbourethral) glands, and the penis formed of cavernous bodies (Fig. 263). The male urethra, which has a mixed character of an urogenital tube, will also be described here.

### THE TESTES

The testes are a pair of oval bodies, slightly flattened on the sides. They are situated in the scrotum and measure 4 cm in length and 3 cm in thickness. Their weight ranges from 15 to 25 g. Two surfaces, medial and lateral (*facies medialis* and *facies lateralis*), two borders, anterior and posterior (*margo anterior* and *margo posterior*), and two poles, upper and lower (*extremitas superior* and *extremitas inferior*), are distinguished in the testis. In normal position of the testis in the scrotum, its upper pole is directed upward, forward, and laterally as a consequence of which the lower pole is directed not only downward but also to the back and medially. The left testis usually descends to a lower level than the right testis. The posterior border of the testis is approached by the spermatic cord (*funiculus spermaticus*) and the epididymis; the epididymis is situated on the posterior border. The epididymis is a narrow, long body in which are distinguished an upper, rather thick part, the head (*caput epididymidis*) and a lower, more pointed part, the tail (*cauda epididymidis*); the intervening part is the body (*corpus epididymidis*). In the region of the body, between the anterior concave surface of the epididymis and the testis, is a pocket, sinus of the epididymis (*sinus epididymidis*) lined with a serous membrane and opened laterally.

A small process, the appendix of the testis, is often present on the upper pole of the testis. On section it is seen to be formed of fine ductules; it is believed to be a remnant of the paramesonephric duct. The appendix of the epididymis is encountered on the head of the epididymis; it is usually attached on a pedicle and is regarded to be a remnant of the Wolffian body, or mesonephros.

**Structure of the testis** (see Fig. 266). The testis is invested by a dense fibrous whitish coat called the tunica albuginea covering directly the sub-

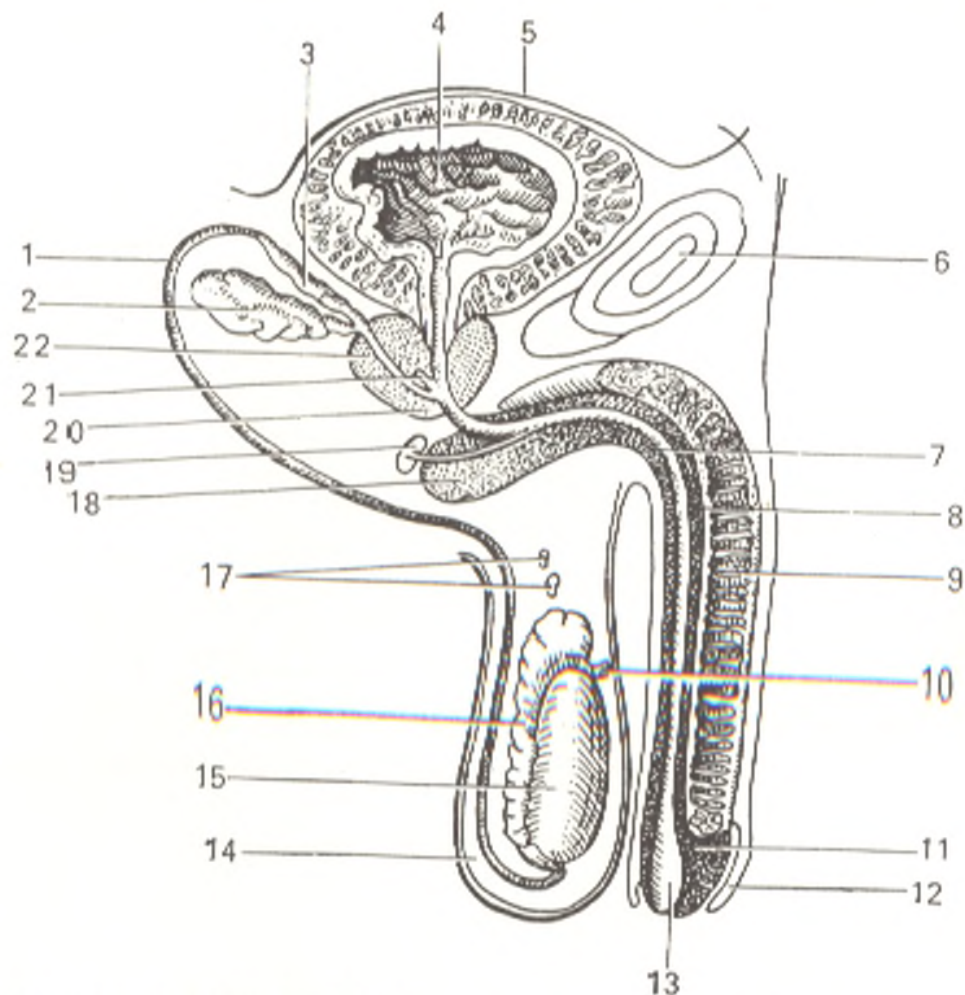


Fig. 263. Male genital (reproductive) organs (schematical representation).

- |                                     |  |
|-------------------------------------|--|
| 1, ductus deferens;                 | 13, fossa navicularis;                 |
| 2, vesicula seminalis;              | 14, scrotum;                           |
| 3, ampulla ductus deferentis;       | 15, testis;                            |
| 4, cavity of urinary bladder;       | 16, epididymis;                        |
| 5, peritoneum covering the bladder; | 17, paradidymis;                       |
| 6, symphysis pubica;                | 18, bulbus penis;                      |
| 7, urethra;                         | 19, glandula bulbourethralis (Cowper's |
| 8, corpus spongiosum penis;         | gland and its ducts);                  |
| 9, corpus cavernosum penis;         | 20, prostata;                          |
| 10, appendix testis;                | 21, utriculus prostaticus;             |
| 11, glans penis;                    | 22, ductus ejaculatorius               |
| 12, preputium;                      |  |

stance, or **parenchyma of the testis**. On the posterior border the fibrous tissue of the coat penetrates the glandular tissue of the testis for a short distance as an incomplete vertical septum or thickening; this is the **mediastinum testis** from which fibrous **septa** (*septula testis*) radiate and are attached by their outer ends to the inner surface of tunica albuginea and thus divide the whole parenchyma into **lobes** (*lobuli testis*). The total number of lobes may reach 250-300. The apices of the lobes are directed at the mediastinum, the bases at the tunica albuginea. The epididymis is also covered by tunica albuginea which, however, is thinner.

The parenchyma of the testis is composed of seminiferous tubules, in which two parts are distinguished: the convoluted seminiferous tubules (*tubuli seminiferi contorti*) and the straight seminiferous tubules (*tubuli*

seminiferi recti). Two-three and more tubules are contained in one lobule. In the lobe they are convoluted but approaching the mediastinum they unite and become narrower to form short straight seminiferous tubules directly at the mediastinum. The straight seminiferous tubules open into a network of channels, *rete testis*, in the thickness of the mediastinum. The network gives origin to 12 to 15 minute tubules, the *efferent ductules of the testis* (*ductuli efferentes testis*), passing to the head of the epididymis. On leaving the testis the efferent ductules become convoluted and form a series of conical *lobules of the epididymis* (*lobuli s. coni epididymidis*). The efferent ductules drain into a single *canal of the epididymis* (*ductus epididymidis*), which follows a very tortuous course and is continuous with the *ductus deferens*. A straightened out duct of the epididymis is 3 to 4 m long. The efferent ductules, the lobules of the epididymis, and the initial portion of the canal of the epididymis form together the head of the epididymis. *Ductuli aberrantes* are encountered on the epididymis. Immediately above the head of the epididymis, in front of the spermatic cord, is a small body, the *paradidymis*, which is a remnant of the mesonephros.

The secretion of the male reproductive organs, the semen, is produced only in the convoluted seminiferous tubules. The straight seminiferous tubules and the channels of the rete testis belong to the deferent tract.

Only a very small amount of the fluid component of the semen is produced in the testes (though it is exactly from this standpoint that they can be regarded as glands of external secretion). It is for the most part the secretion of the accessory glands of the reproductive apparatus, which open into the deferent tract.

*Arterial blood* is supplied to the testis and epididymis by the testicular artery, the artery of the ductus deferens, and partly by the cremasteric artery. *Venous blood* drains from the testis and epididymis into the pampiniform plexus and then into the testicular vein.

The *lymphatic vessels* from the testis pass as components of the spermatic cord and, by-passing the inguinal nodes, terminate in the lumbar lymph nodes. This, as well as the high position of the testicular artery and veins, is associated with the fact that the testis is laid down in the lumbar region.

The *nerves* of the testis form the sympathetic testicular and deferential plexuses around the testicular and deferential arteries.

## DUCTUS DEFERENS

The *ductus deferens* (*vas deferens*) is a direct continuation of the duct of the epididymis but its walls are much thicker. It is separated from the testis by vessels (the testicular artery and vein), ascends, and becomes a component of the spermatic cord in which it is situated behind the vessels and is easily palpated because of its firm walls. As a component of the spermatic cord it ascends vertically to the external (superficial) inguinal ring. Having passed in the inguinal canal obliquely upward and laterally, it leaves the testicular vessels (which pass into the lumbar region) and extends downward and to the back on the lateral pelvic wall where it is covered by peritoneum. On reaching the urinary bladder it curves toward its base and

reaches the prostata. The distal part of the ductus is conspicuously dilated, and this part is termed the **ampulla of the vas deferens** (*ampulla ductus deferentis*). The length of the ductus varies from 40 to 45 cm, the diameter is 2.5 mm on the average, and the width of its lumen measures only 0.2-0.5 mm. The wall of the ductus is composed of three layers: an outer *adventitious coat* of fibrous tissue (*tunica adventitia*), a middle *muscular coat* (*tunica muscularis*) and an inner *mucous coat* (*tunica mucosa*).

### THE SEMINAL VESICLES

The **seminal vesicles** (*vesiculae seminales*) (Fig. 264) are situated lateral of both ductus deferentes between the base of the bladder and the rectum. Each vesicle is about 5 cm in length and the greatest width is about 2.5-3.0 cm. Only the upper, wider and rounded part of the vesicle is covered with peritoneum. Each seminal vesicle is actually a greatly coiled tube whose length when stretched out reaches 12 cm. The lower, pointed end of the vesicle is continuous with a narrow **duct of seminal vesicle** (*ductus excretorius*), which unites with ductus deferens of the same side at a right angle to form a common **ejaculatory duct** (*ductus ejaculatorius*). The ejaculatory duct is a very slender tube, which, arising from the site of union of the ductus deferens and the excretory duct of the seminal vesicle, passes through the thickness of the prostate gland and drains into the prostatic part of the urethra by a narrow opening at the base of the seminal colliculus. The ejaculatory duct is about 2 cm in length; its lumen is about 0.8 mm wide in the initial part and 0.2 mm wide in the terminal part. The wall of the seminal vesicle is formed of coats similar to those of the ductus deferens. The seminal vesicles do not contain stores of semen; they are secretory organs, which mix the fluid they produce with the secretions of the testes.

The ductus deferens receives *arterial blood* from the artery of the vas deferens (branch of the internal iliac artery). The seminal vesicles are supplied from the inferior vesical, vas deferens, and rectal arteries. *Venous blood* flows into the vena deferentialis draining into the internal iliac vein. *Lymph* flows into the internal iliac lymph nodes.

The ductus deferens and seminal vesicles are *innervated* from the plexus of the vas deferens formed by nerves from the pelvic plexus.

### THE SPERMATIC CORD AND COATS OF THE TESTIS

The testes are situated in the scrotum as if suspended there on the spermatic cords. The **spermatic cord** (*funiculus spermaticus*) (Figs. 265 and 266) consists of the ductus deferens, the testicular arteries and veins and the arteries and veins of the vas deferens, lymphatic vessels, and nerves. At the deep ring of the inguinal canal these components separate and the spermatic cord, therefore, extends as a whole structure only between the posterior margin of the testis and the deep inguinal ring. The cord forms only after the testis descends into the scrotum from the abdominal cavity where it initially develops.

In lower mammals the testis is in the abdominal cavity. In more highly organized species, e.g. in rodents, it emerges temporarily into the exterior

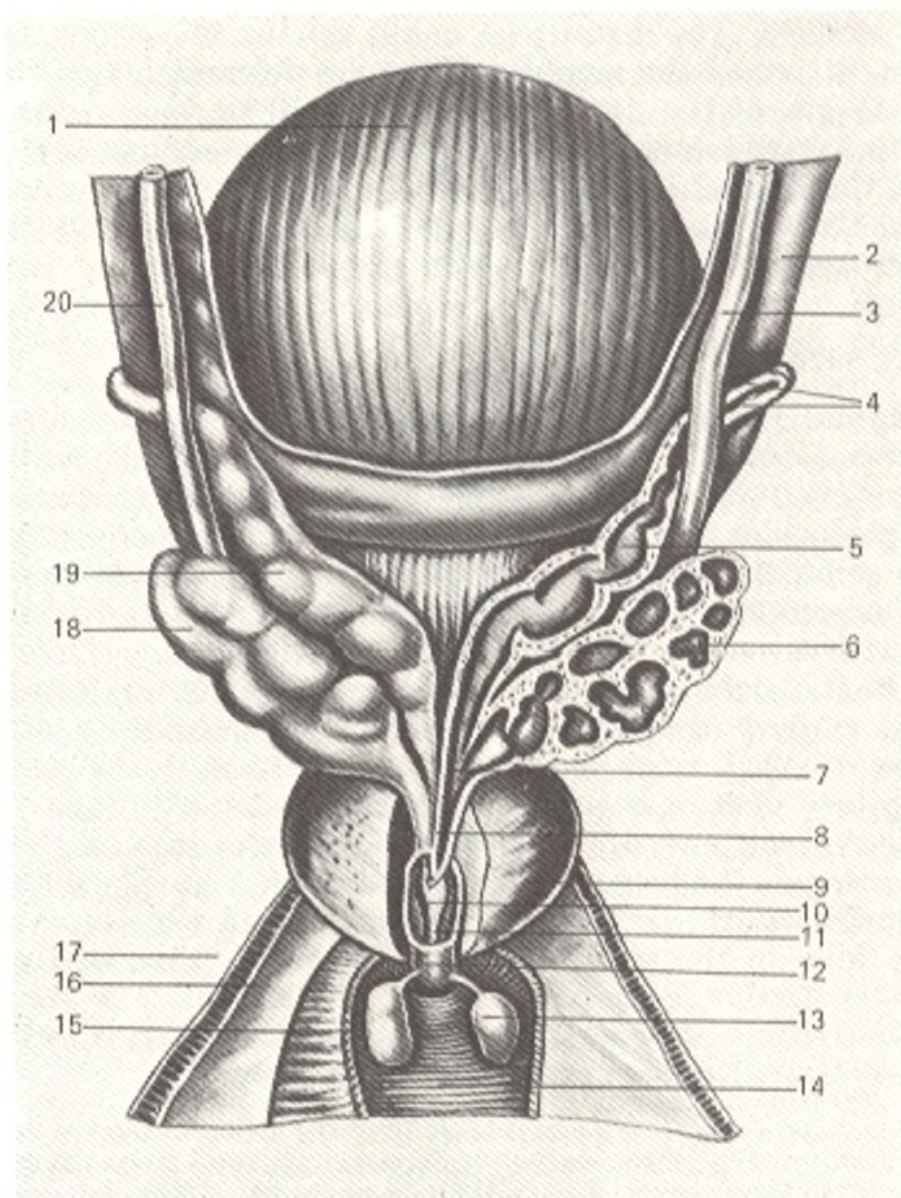


Fig. 264. Seminal vesicles and prostata.

1, vesica urinaria;  
 2, peritoneum;  
 3 and 20, ureter (dext. et sin.);  
 4, ductus deferens;  
 5 and 19, ampulla ductus deferentis (dext. et sin.);  
 6 and 18, vesicula seminalis (dext. et sin.);  
 7, ductus excretorius;  
 8, ductus ejaculatorius;  
 9, lobus dext. prostatae;

10, tunica mucosa urethrae;  
 11, pars prostatica urethrae;  
 12, pars membranacea urethrae;  
 13, glandula bulbourethralis (Cowperi);  
 14 and 15, m. transversus perinei profundus;  
 16, fascia diaphragmatis urogenitalis superior;  
 17, fascia diaphragmatis urogenitalis inferior

in the mating period. The muscle elevating the testis, the cremaster muscle, is well developed in these animals while in higher mammals and in man it is reduced because their testis comes out entirely from the abdominal cavity into the scrotum. As a reflection of this process, *descent of the testis* (*descensus testis*) takes place in man during ontogenesis. In the embryo, the testes are situated on the posterior abdominal wall at the level of the two



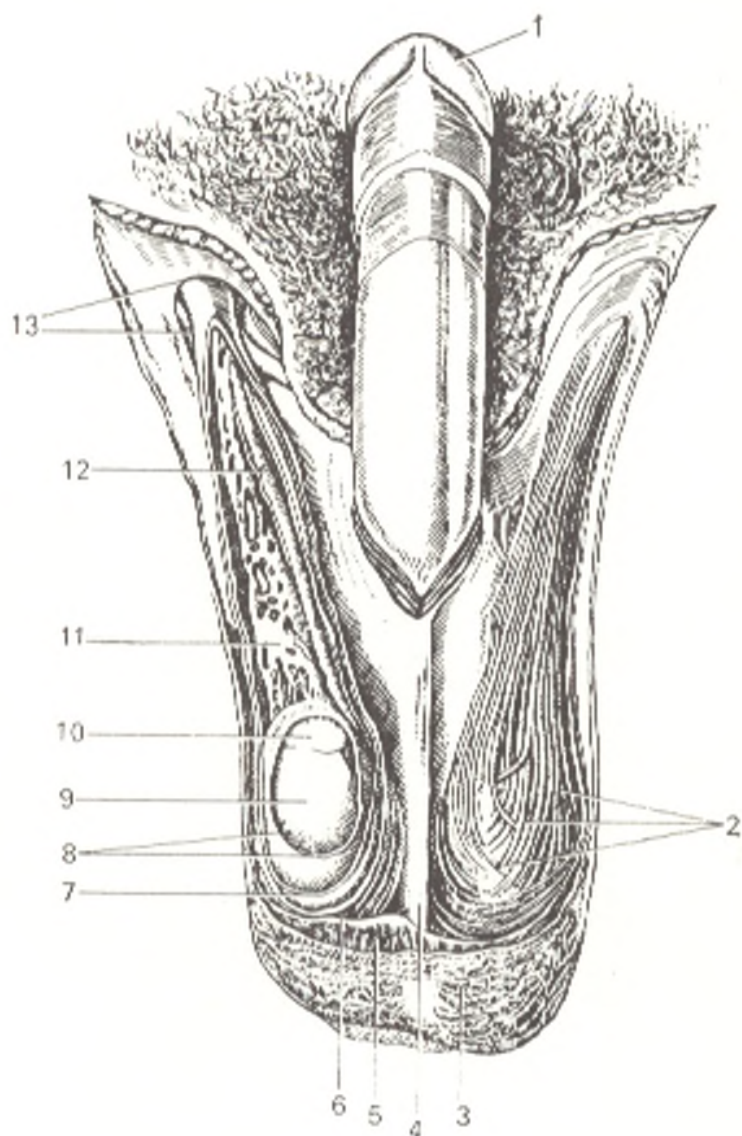


Fig. 265. Scrotum and spermatic cord, anterior aspect.

- 1, glans penis;
- 2, external fibres of m. cremaster;
- 3, skin of scrotum;
- 4, septum scroti;
- 5, tunica dartos;
- 6, m. cremaster;
- 7, fascia spermatica interna;
- 8, tunica vaginalis testis;
- 9, testis;
- 10, caput epididymidis;
- 11, plexus pampiniformis;
- 12, ductus deferens;
- 13, anulus inguinalis superficialis

upper lumbar vertebrae. The guide of the testis, gubernaculum testis, extends from its inferior extremity downward; it consists of smooth muscle fibres and fibrous tissue and its lower end is embedded in a peritoneal fold and directed into the inguinal region. With growth of the embryo, the testis gradually descends to a lower level. It lies in the iliac fossa on the third month and is situated at the deep inguinal ring by the seventh month. Long before the testis leaves the abdominal cavity, the peritoneum gives off a blind process, processus vaginalis peritonei, passing into the scrotum through the anterior abdominal wall and receiving on the way coats from all layers of the abdominal wall. Following the course of the vaginal process, the testis descends into the scrotum and occupies for the most part its final position in it before the birth of the child. The upper part of the vaginal process obliterates and the earlier existing communication between the peritoneum and the serous coat of the testis is thus discontinued. An open canal may remain if the vaginal process fails to obliterate, through which congenital hernias may form. When the testis leaves the abdominal cavity, the guber-

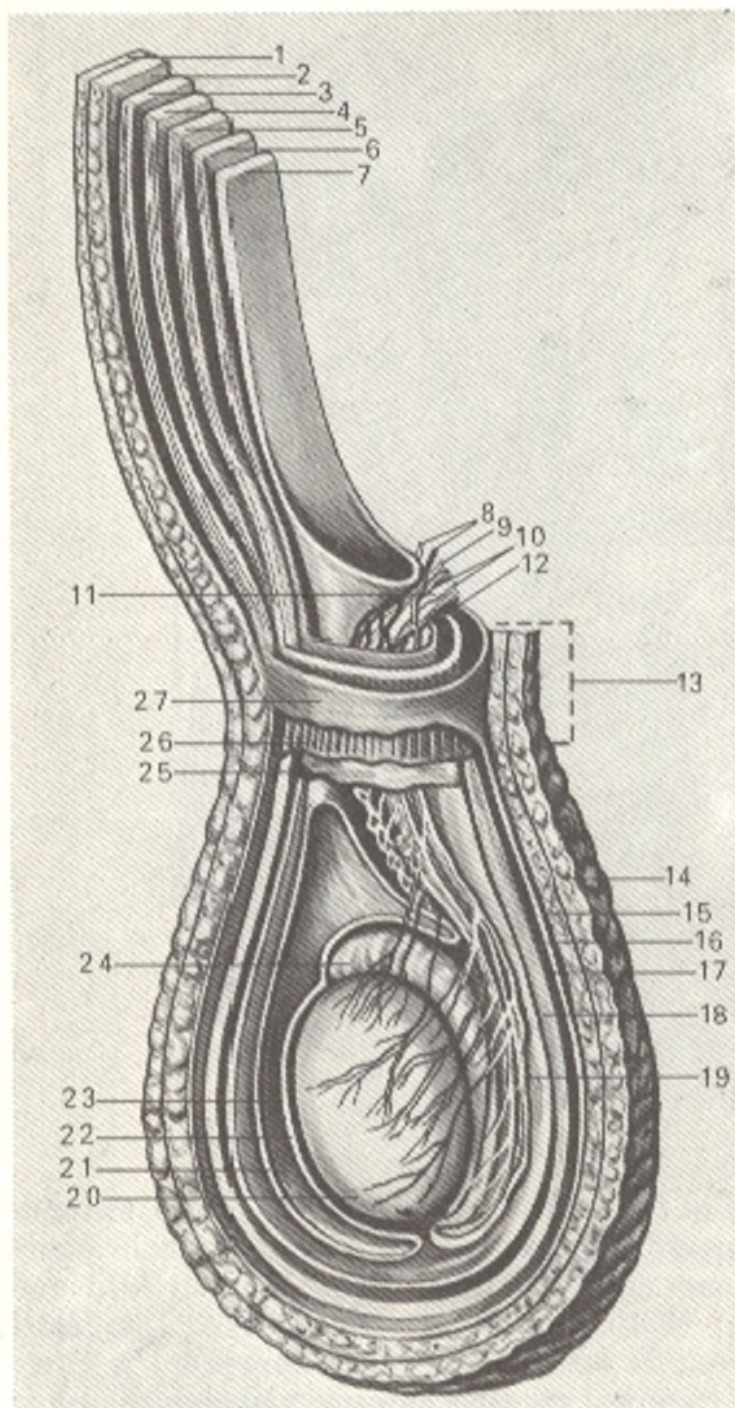


Fig. 266. Schematic representation of the coats of the testis (after Kiss and Szentagóthai).

- 1 and 14, cutis;  
 2, fascia m. obliqui ext. abdominis;  
 3, m. obliquus ext. abdominis;  
 4, m. obliquus int. abdominis;  
 5, m. transversus abdominis;  
 6, fascia transversalis;  
 7, peritoneum;  
 8, a. et v. testicularis (plexus pampiniformis);  
 9, 10, and 12, vessels and nerves of spermatic cord and testis;  
 11, ductus deferens;  
 13, funiculus spermaticus;  
 15, tunica dartos;  
 16 and 27, fascia spermatica externa;  
 17, fascia cremasterica;  
 18 and 26, m. cremaster;  
 19 and 25, fascia spermatica interna;  
 20, testis;  
 21, tunica vaginalis testis (lamina visceralis);  
 23, cavum vaginale;  
 24, epididymis

naculum testis atrophies. Some authors claim that shortening of the gubernaculum during its atrophy partly facilitates the descent of the testis. In disturbance of this process, the testis either remains in the abdominal cavity or stops in the inguinal canal, as is encountered in animals. Such abnormal position of the testis is a developmental anomaly and is called monorchidism (when one testis fails to descend into the scrotum) and cryptorchidism (when both testes fail to descend). On occupying its final position, the testis, together with the lower end of the spermatic cord, is situated in the scrotum. The raphe of the scrotum stretches on its median line from the inferior surface

of the penis to the anus. The remaining surface of the scrotum is more or less wrinkled.

The coats of the testes and spermatic cord (beginning from the exterior) are as follows: the skin, tunica dartos, external spermatic fascia, cremasteric fascia, the cremasterion muscle, internal spermatic fascia, and the tunica vaginalis testis (Fig. 262). Such a large number of testicular coats corresponds to definite layers of the anterior abdominal wall. An impression is created as if during its descent from the abdominal cavity the testis had pulled the peritoneum and the fasciae of the abdominal muscles after it and had become invested in them (see Fig. 266).

1. The skin of the scrotum is very thin and darker than that of the other parts of the body. It is supplied with numerous large sebaceous glands whose secretions have a specific odour.

2. Tunica dartos, or dartos, lies directly under the skin. It is a continuation of the inguinal and perineal connective tissue but is devoid of fat. It contains a significant number of smooth muscle fibres. The dartos forms a separate sac for each testis; the sacs are fused on the midline as a result of which a septum, septum scroti, forms which is attached on the raphe.

3. The external spermatic fascia (*fascia spermatica externa*) is a continuation of the superficial fascia of the abdomen.

4. The cremasteric fascia (*fascia cremasterica*) is a continuation of the intercrural fascia arising from the margins of the superficial inguinal ring; it covers the cremasteric muscle, hence its name.

5. The cremaster muscle (*m. cremaster*) consists of bundles of striated muscle fibres, which are a continuation of the transversus abdominis muscle (see "Myology"). Contraction of the cremaster muscle elevates the testis.

6. The internal spermatic fascia (*fascia spermatica interna*) lies directly under the cremaster muscle. It is a continuation of the transverse fascia; it invests all the components of the spermatic cord and is related to the outer surface of the testicular serous coat.

7. The tunica vaginalis testis forms from the peritoneal vaginal process and is a closed serous sac consisting of two layers, *parietal* (*lamina parietalis*) and *visceral* (*lamina visceralis*). The visceral layer is intimately fused with the tunica albuginea of the testis and extends also onto the epididymis. The visceral layer fits into a slit-like space between the lateral surface of the testis and the middle part (body) of the epididymis to form a recess, the *sinus of the epididymis*. On the posterior margin of the testis, where the vessels leave it, the visceral layer is continuous with the parietal layer. Between the opposed surfaces of the two layers is a slit-like recess, *cavum vaginale*, in which a large amount of serous fluid may accumulate in pathological conditions and produce hydrocele.

## THE PENIS

The penis together with the scrotum constitute the external male genital organs (Figs. 267 and 268). The penis is for the most part composed of cavernous, or erectile tissue formed of numerous trabeculae consisting of

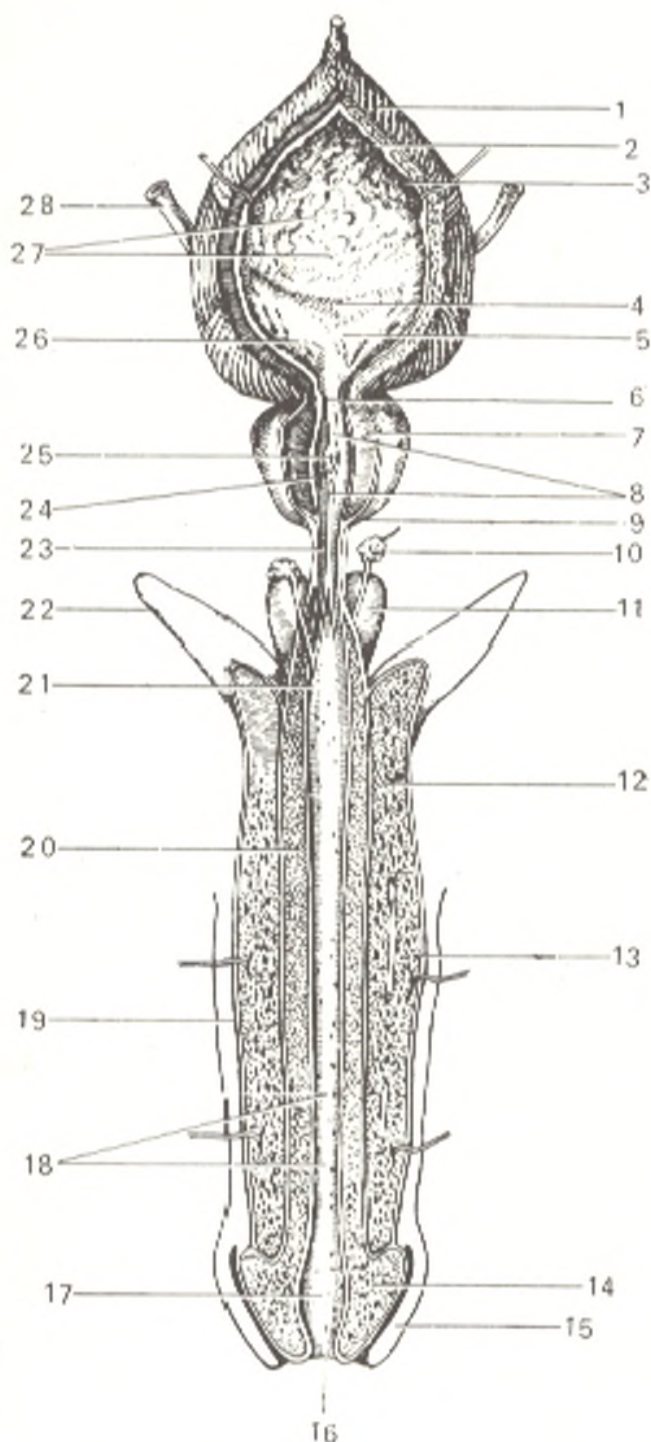


Fig. 267. Male reproductive organs (prostate and cavernous bodies) and urinary bladder (the bladder and urethra are opened).

- 1 and 2, tunica muscularis (stratum externum et stratum medium);  
 3, tela submucosa;  
 4, plica interureterica;  
 5, trigonum vesicae;  
 6, ostium urethrae internum;  
 7, substantia muscularis prostatae;  
 8, pars prostatica urethrae;  
 9, prostata;  
 10, glandula bulbo urethralis;  
 11, bulbus penis;  
 12, corpus cavernosum penis;  
 13, tunica albuginea;  
 14, glans penis;  
 15, preputium;  
 16, ostium urethrae externum;  
 17, fossa navicularis;  
 18, lacunae urethrales;  
 19, cutis;  
 20, corpus spongiosum penis;  
 21, ductus glandulae bulbourethralis (orifices);  
 22, crus penis;  
 23, pars membranacea urethrae;  
 24, ductus prostatici (orifices);  
 25, colliculus seminalis;  
 26, ostium ureteris dextrum;  
 27, plicae mucosae;  
 28, ureter dexter

fibrous-elastic strands with an admixture of smooth muscle fibres. Spaces (caverns) exist within the thick trabecular network, which are lined with endothelium and filled with blood (see Fig. 268). The cavernous tissue forms three bodies: the paired *corpus cavernosum penis* and the unpaired *corpus spongiosum penis*.

The *corpora cavernosa penis* are two long cylindrical bodies with pointed ends; the two posterior ends diverge to form the *crura penis*, which are attached to the inferior ramus of the pubis. These two bodies are covered

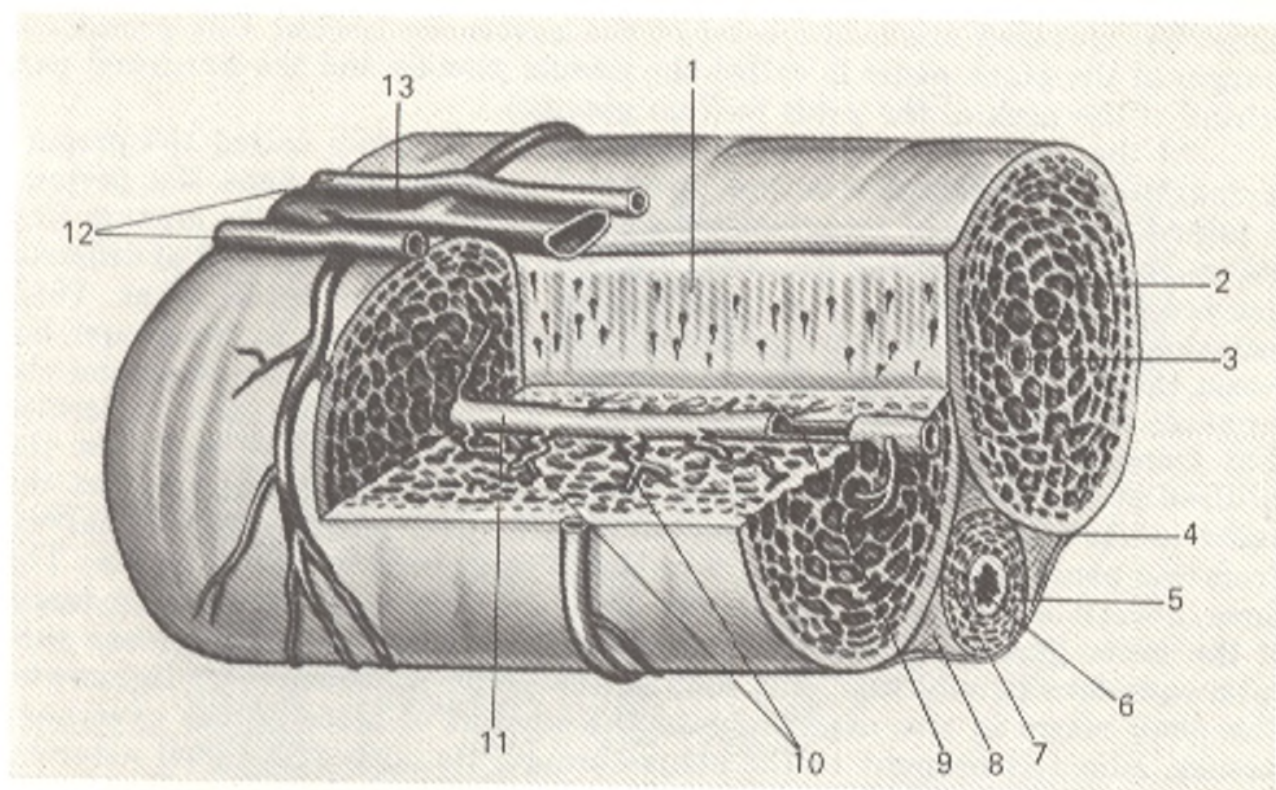


Fig. 268. Structure of the cavernous bodies (after Kiss and Szentagóthai).

- |  |   |
|--|---|
| 1, septum penis;                               | 8, tunica albuginea corporis spongiosi penis; |
| 2, corpus cavernosum penis;                    | 9, branch of a. profunda penis;               |
| 3, a. profunda penis;                          | 10, aa. helicinae;                            |
| 4, tunica albuginea corporum cavernosum penis; | 11, a. profunda penis;                        |
| 5, corpus spongiosum penis;                    | 12, aa. dorsale penis;                        |
| 6, urethra;                                    | 13, v. dorsalis penis                         |
| 7, a. urethralis;                              |   |

with a common *tunica albuginea corporum cavernosum* forming the *septum of the penis* between them. Corresponding to the septum there is a groove on the superior surface for the dorsal vein of the penis and another, on the inferior surface, for the corpus spongiosum penis.

The **corpus spongiosum penis**, covered by the *tunica albuginea corporis spongiosi*, is below the cavernous bodies and is pierced by the urethra for its whole length. The corpus spongiosum penis is smaller in diameter (1 cm) than the two cavernous bodies, but, as distinct from them, it expands on both ends to form the head, or **glans penis** anteriorly and the **bulb of the penis** (*bulbus penis*) posteriorly.

The posterior part of the penis attached to the pubic bones is **root of the penis** (*radix penis*). As it is said above, the terminal part of the penis is the glans penis. The intervening part between the glans and the root is the **body of the penis** (*corpus penis*). The superior surface of the body is wider than the inferior surface and is called the **dorsum of the penis** (*dorsum penis*). The inferior surface is in contact with the corpus spongiosum penis. The glans penis bears a vertical slit-like opening, the **external orifice of the male urethra** (*ostium urethrae externum*), and on the dorsal and ventral surfaces is

somewhat elevated above the level of the cavernous bodies; this prominent margin of the glans penis is called the **corona glandis** and the narrowed part behind it the **neck of the penis** (*collum glandis*).

At the base of the glans the skin forms a free fold called the **prepuce** (*preputium*), or **foreskin**. On the inferior surface of the glans the prepuce is joined to the skin of the glans by a fold, the *frenulum of the prepuce* (*frenulum preputii*). Sebaceous *preputial glands* (*glandulae preputiales*) of different size are situated around the corona and on the inner preputial layer. Their secretion is a component of the *smegma preputii* collecting in the groove between the glans penis and prepuce. A space is left between the glans and the prepuce; this is the cavity of the prepuce, it opens in front with an orifice that transmits the glans when the prepuce is moved to the back. On the midline of the under-surface of the penis from the frenulum stretches the *raphe* indicating the site of fusion of the two previously separate halves. From the penis it passes backward onto the scrotum and the perineum. The three bodies of the penis are united into a single structure by the **fascia of the penis** (*fascia penis*) investing them; the fascia lies under loose subcutaneous fat. In addition, the root of the penis is fastened by ligaments. The penis alters in size depending on the amount of blood in the cavernous tissues. Blood is brought to the penis through its deep and dorsal arteries. The arteries pass into the connective-tissue trabeculae and ramify here to form fine capillary branches opening directly into the cavernous spaces. Vessels carrying venous blood, the cavernous veins, begin partly in the centre of the cavernous bodies, partly closer to the periphery, and drain into the deep and dorsal veins of the penis. Due to the specific structure of the blood vessels of the penis, blood can be retained in the cavernous bodies as a result of which the bodies become hard during erection.

The *arteries* of the penis are branches of the femoral artery (the external pudendal arteries) and the internal pudendal artery. *Venous blood* is drained by the superficial and deep dorsal veins of the penis into the femoral vein and the vesical venous plexus. Lymph flows into the inguinal lymph nodes and the nodes of the true pelvis.

*Afferent innervation* is derived from the pudendal nerve, efferent sympathetic innervation from the inferior hypogastric plexus, and efferent parasympathetic innervation from the erigentes nerves.

## THE MALE URETHRA

The **male urethra** (*urethra masculina*) (Figs. 267 and 269) is a tube approximately 18 cm in length extending from the bladder to the **external urethral orifice** (*ostium urethrae externum*) on the glans penis. The urethra serves not only for the passage of urine but also for the passage of the semen entering it through the ejaculatory duct. The urethra passes through different structures according to which three parts are distinguished in it: prostatic, membranous, and spongy.

1. The **prostatic part** (*pars prostatica*) is nearest to the bladder and passes through the prostata. It is about 2.5 cm in length. This part, its middle portion in particular, is the widest and most distensible segment of the urethra. On its posterior wall it bears a small median eminence, the

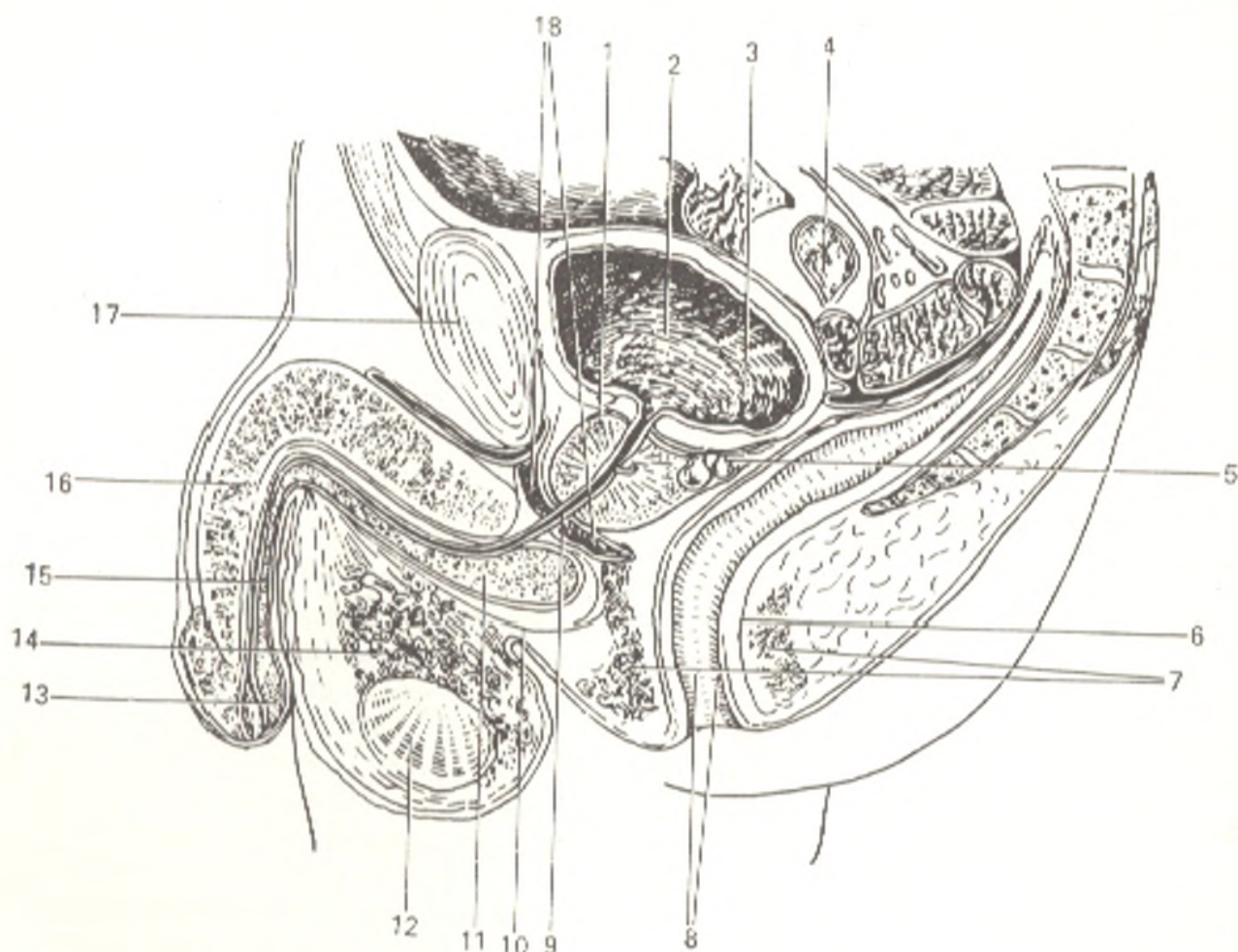


Fig. 269. Sagittal median section through male genital organs.

1, prostata;  
 2, vesica urinaria;  
 3, ostium ureteris;  
 4, intestinum tenue;  
 5, vesicula seminalis;  
 6, rectum;  
 7, m. sphincter ani externus;  
 8, anus;  
 9, urethra (pars membranacea);

10, m. bulbocavernosus;  
 11, bulbus penis;  
 12, testis;  
 13, glans penis;  
 14, plexus pampiniformis;  
 15, corpus spongiosum penis;  
 16, corpus cavernosum penis;  
 17, symphysis pubica;  
 18, diaphragma urogenitale

*seminal colliculus (colliculus seminalis)*, which is about 1.5 cm in length. On the apex of the colliculus is a small, slit-like opening leading into a small blind pouch in the substance of the prostata; it is called the *prostatic utricle (utriculus prostaticus)*, or the *male uterus (uterus masculinus)*. The last name indicates that this structure is derived from the fused lower ends of the paramesonephric (Mueller's) ducts from which the female uterus and vagina develop. On either side of the entry into the prostatic utricle are small openings of the ejaculatory ducts (one on the right and one on the left side). On both sides, lateral of the seminal colliculus, are numerous openings of the prostatic glandules. The seminal colliculus is richly supplied with blood vessels and may swell and cause constriction of the urethral lumen in strong rushes of blood.

On the circumference of the prostatic part of the urethra is a ring of smooth muscle fibres that compose part of the prostatic muscular tissue (*substantia muscularis*) and reinforce the sphincter of the bladder (*sphincter vesicae*) (smooth muscle, involuntary).

2. The **membranous part** (*pars membranacea*) is a segment of the urethra between the apex of the prostata and the bulb of the penis; it is about 1 cm in length. It is, therefore, the shortest and at the same time the narrowest of the three parts. It is situated to the back of and below the inferior pubic ligament and passes through the urogenital diaphragm and its superior and inferior fasciae, where it perforates the inferior fascia; the lower end of the membranous part is the narrowest and least dilatable segment of the urethra, which must be borne in mind so as not to rupture the urethra when introducing a catheter into it. The submucous tissue is covered on the outside by a layer of smooth muscle fibres. In addition, the membranous part is surrounded by striated muscle bundles, the voluntary sphincter urethrae muscle.

3. The **spongy part** (*pars spongiosa*), about 15 cm in length, is surrounded by the tissue of the corpus spongiosum penis. The canal is somewhat dilated in the bulbus, then for the distance to the glans it is uniform in calibre, but in the glans it is again dilated for about 1 cm to form the *fossa terminalis* (*fossa navicularis urethrae*). The external urethral orifice is a poorly dilatable part of the canal, which must be taken into account when inserting a catheter. In addition to these three anatomical parts of the urethra, two parts are distinguished in the urological clinic according to the course of inflammatory processes: the anterior urethra, i.e. the spongy part and the posterior urethra, the two remaining parts. The boundary between them is the sphincter urethrae muscle, which prevents the penetration of infection from the anterior into the posterior urethra. Numerous minute *urethral glands* (*glandulae urethrales*) or Littre's glands (hence *littreitis*, inflammation of these glands, open into the canal (urethra) along the whole mucous membrane except for the area nearest to the external opening. Recesses, the *lacunae urethrales*, are found mainly on the superior wall of the urethra, particularly in front of the bulb; their orifices are directed anteriorly and closed by valves. To the outside of the submucous tissue is a layer of smooth muscle fibres (longitudinal inside and circular outside).

The urethra describes an S-shaped course from its origin to its terminal part. When the spongy part is raised, the anterior curvature straightens out and only one curvature remains with the concavity directed at the pubic symphysis. Greater fixation of the posterior curvature is provided by the *puboprostatic ligaments* (*ligamenta puboprostatica*) passing from the symphysis to the prostata, the urogenital diaphragm (through which the membranous part of the urethra passes), and the *suspensory ligament of the penis* (*lig. suspensorium penis*) connecting the penis with the symphysis.

The calibre of the urethra is not uniform throughout. Measurement with metal casts showed the following calibres: 4.5 mm at the junction of the spongy and membranous parts; 5.7 mm at the external orifice; 11.3 mm in the middle of the prostatic part; 16.8 mm in the region of the bulbus. Before ejaculation the semen may accumulate in the dilated part of the canal corre-



sponding to the bulbus. A catheter for introduction into the urethra of an adult should have a diameter of no more than 10 mm.

The *arteries* of the urethra originate from the branches of the internal pudendal artery. The different parts of the canal are supplied from different sources: the prostatic part, from branches of the middle rectal and inferior vesical arteries; the membranous part from the inferior rectal and perineal arteries; the spongy part from the internal pudendal artery. The dorsal and deep arteries of the penis also contribute to the vascularization of the urethral walls. *Venous blood* flows into the veins of the penis and those of the urinary bladder. *Lymph* from the prostatic part drains into the prostatic lymphatic veins, lymph from the membranous and spongy parts into the inguinal nodes.

*Innervation* is accomplished from the perineal nerves and the dorsal nerve of the penis (from the pudendal nerve) and from the vegetative prostatic plexus.

The **act of urination** occurs as follows: the contraction of the detrusor urinae muscle presses the urine out of the bladder into the urethra, which opens due to relaxation of its involuntary (m. sphincter vesicae) and voluntary (m. sphincter urethrae) sphincters.

In males, the muscular part of the prostata also relaxes and acts as the third (involuntary) sphincter.

The bladder is closed by relaxation of the detrusor muscle and contraction of the sphincters indicated above.

Information has been published on the presence of a fourth sphincter below the prostata. Another opinion exists, however, according to which the bladder has no sphincter and its role is accomplished in females by the whole urethra and in males by the prostatic and membranous parts of the urethra and the elastic tissue embedded in the urethral walls.

#### THE BULBOURETHRAL GLANDS

The **bulbourethral (Cowper's) glands** (*glandulae bulbourethrales s. Cowperi*) (Figs. 263 and 270) are a pair of bodies the size of a pea lodged in the thickness of the urogenital diaphragm above the posterior end of the bulb of the penis and behind the membranous part of the urethra. The duct, about 3-4 cm in length, opens into the spongy part of the urethra in the region of the bulbus. The bulbourethral glands produce a viscous secretion, which protects the urethral walls from irritation by the urine. In old age, the glands become smaller. According to the latest data, they take part in internal secretion.

*Arteries* reach the bulbourethral glands from the internal pudendal artery. *Venous blood* flows into the veins of the bulbus and urogenital diaphragm. The *lymphatic vessels* drain into the internal iliac lymph nodes.

The glands are *innervated* from the pudendal nerve.

#### THE PROSTATE

The **prostate (prostata)** (Gk *prostates* to put in front) is, for a smaller part, a glandular and, for a greater part, a muscular organ (Figs. 264 and 267) that embraces the initial part of the male urethra. As a gland it secretes an important component of the semen, which stimulates the spermatozoa and, therefore, develops by the time of puberty. There are also indication of the gland's endocrine activity. As a muscle, it is an involuntary sphincter

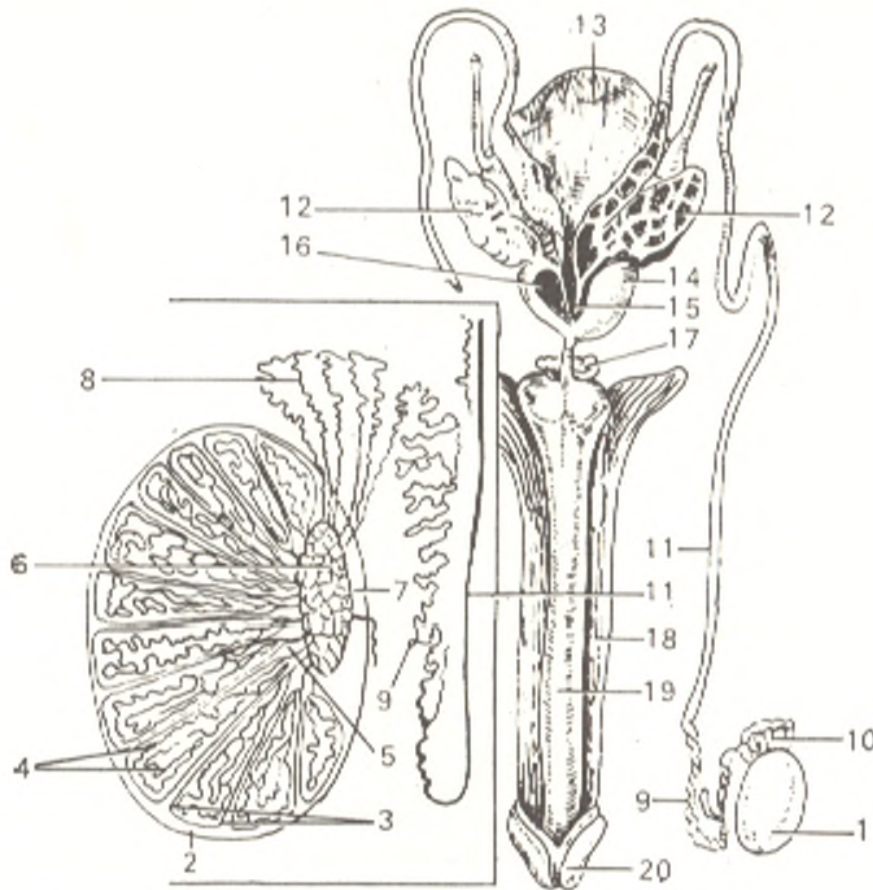


Fig. 270. Seminiferous tract, represented schematically.

- |                                |                                      |
|--------------------------------|--------------------------------------|
| 1, testis;                     | 11, ductus deferens;                 |
| 2, tunica albuginea;           | 12, vesicula seminalis;              |
| 3, septula testis;             | 13, vesica urinaria;                 |
| 4, tubuli seminiferi contorti; | 14, prostata;                        |
| 5, tubuli seminiferi recti;    | 15, orifice of ductus ejaculatorius; |
| 6, rete testis;                | 16, pars prostatica urethrae;        |
| 7, mediastinum testis;         | 17, glandula bulbourethralis;        |
| 8, ductuli efferentes testis;  | 18, corpus cavernosum penis;         |
| 9, ductus epididymidis;        | 19, corpus spongiosum penis;         |
| 10, epididymis;                | 20, glans penis                      |

of the urethra that prevents, in particular, the flow of urine during ejaculation. As a result the urine and the semen do not mix. Before puberty the prostate is exclusively a muscular organ but by the time of puberty (17 years of age) it becomes a gland. The prostate resembles a chestnut in shape and size. A **base** (*basis prostatae*) directed toward the bladder and an **apex** adjoining the urogenital diaphragm are distinguished in it. The **anterior convex surface** of the gland (*facies anterior*) faces the pubis symphysis, from which it is separated by loose fatty tissue and a venous plexus (*plexus prostaticus*) embedded in it; above the plexus are the pubovesical ligaments. The **posterior surface** (*facies posterior*) is related to the rectum, from which it is separated by only a layer of the pelvic fascia, the *retrovesical septum* (*septum retrovesicale*); that is why it can be palpated in a living subject on the anterior wall of the rectum with a finger introduced into it. The urethra passes through the prostate from the base to the apex of the gland on the midline, nearer

to the anterior than to the posterior surface. The ejaculatory ducts enter the gland through the posterior surface, run in the tissue downward, medially, and forward, and open into the prostatic part of the urethra. The wedge-shaped portion of the gland between both ejaculatory ducts and the posterior surface of the urethra is the **median lobe, or isthmus of the prostate** (*lobus medius s. isthmus prostatae*). The remaining greater part is formed by the **right and left lobes** (*lobi dexter and sinister*), which are, however, not demarcated from one another superficially. The median lobe is of considerable surgical interest because it is enlarged in hypertrophy of the prostate and may cause serious disorders of urination.

The transverse diameter of the gland (near to the base) is the largest and measures 3.5 cm on the average; the anteroposterior diameter is 2 cm, and the vertical diameter is 3 cm.

The prostate is surrounded by fascial layers, portions of the pelvic fascia, which form a sheath. In this sheath, in addition to the prostate, is fatty tissue containing a rather large prostatic venous plexus situated mainly in the anterior part under the pubovesical ligaments and on the sides of the prostate.

Inner to the fascial coat is the **prostatic capsule** (*capsula prostatica*) formed of smooth muscular and connective tissue. The tissue of the prostate is composed of glands, *glandular substance of the prostate* (*substantia glandularis*) buried mainly in muscular tissue; its lobules are formed of fine, slightly branched tubules draining into the *prostatic ducts* (*ductuli prostatici*), about 20 to 30 in number, which open on the posterior wall of the prostatic part of the urethra on the sides of the seminal colliculus. The part of the prostate in front of the urethra passing through it consists almost exclusively of muscular tissue. The totality of the smooth musculature of the prostate is called *substantia muscularis*.

The prostate is supplied with *arterial blood* from the inferior vesical and median rectal arteries. *Veins* enter the vesical and prostatic plexus draining into the inferior vesical veins; the vessels of the prostate develop fully only with the onset of puberty. The *lymphatic vessels* drain into nodes situated in the anterior parts of the pelvic cavity.

The *nerves* are derived from the inferior hypogastric plexus.

**Semen-conveying ducts indicated in the successive order** (see Fig. 270): straight seminiferous tubules, rete testis, efferent ductules of the testis, duct of the epididymis, ductus deferens, ejaculatory duct, prostatic part and the other parts of the urethra.

## THE FEMALE GENITAL ORGANS

The **female genital organs** (*organa genitalia feminina*) are as follows: (1) the internal genital organs situated in the pelvis, i.e. the ovaries, oviducts (uterine tubes), uterus, and vagina, and (2) organs visible from the exterior (pudendum femininum s. vulva), i.e. the labia majora and minora, the clitoris, and the hymen.

## THE OVARY

The **ovary** (*ovarium*), a paired organ (Fig. 271), is the female sex gland similar to the male testis. It is a flat oval body 2.5 cm in length, 1.5 cm in width, and 1.0 cm thick. Two ends are distinguished in it: the upper, rounded end directed at the uterine tube is called the **tubal end** (*extremitas tubaria*); the opposite, lower and more pointed end, the **uterine end** (*extremitas uterina*) is connected with the uterus by the **ligament of the ovary** (*ligamentum ovarii proprium*). The two surfaces, **lateral** and **medial** (*facies lateralis* and *facies medialis*), are separated one from the other by borders: the **free posterior border** (*margo liber*) is concave while the other, **anterior mesovarian border** (*margo mesovaricus*), is straight and is attached to the mesentery. This border is termed the **hilum of the ovary** (*hilus ovarii*) because vessels and nerves enter the ovary through it.

The lateral surface of the ovary lies against the lateral pelvic wall between the external iliac vessels and the psoas major muscle above, the

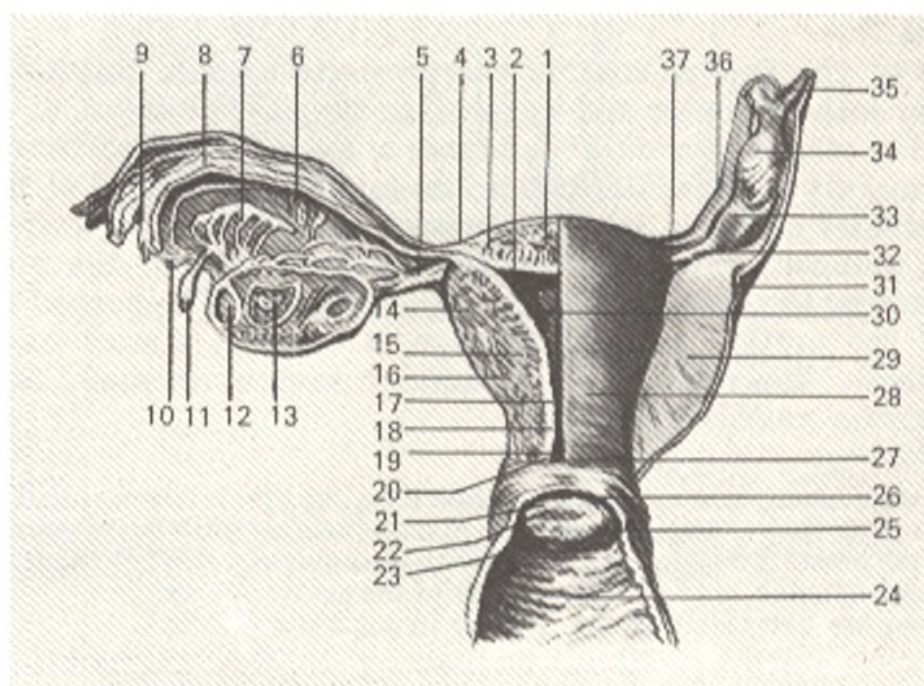


Fig. 271. Internal female genital organs (posterior aspect).

- |                                      |  |
|--------------------------------------|--|
| 1, fundus uteri;                     | 19 and 20, cervix uteri et canalis cervicis; |
| 2, ostium uterinum tubae;            | 21, labium posterius;                        |
| 3, pars uterina tubae;               | 22, ostium uteri;                            |
| 4 and 37, isthmus tubae uterinae;    | 23, labium anterius;                         |
| 5 and 32, lig. ovarii proprium;      | 24, vagina, paries anterior;                 |
| 6, mesosalpinx;                      | 25, portio vaginalis cervicis uteri;         |
| 7 and 11, epophoron;                 | 26, fornix vaginae;                          |
| 8, ampulla tubae;                    | 27, portio supravaginalis cervicis uteri;    |
| 9, infundibulum tubae uterinae;      | 28, posterior surface of uterus;             |
| 10 and 34, fimbriae tubae;           | 29, lig. latum uteri;                        |
| 12, folliculus ovaricus vesiculosus; | 30, cavum uteri;                             |
| 13, corpus luteum;                   | 31, ureter;                                  |
| 14, perimetrium;                     | 32, ovarium dextrum;                         |
| 15, myometrium;                      | 33, lig. suspensorium ovarii;                |
| 16, endometrium;                     | 34, ampulla tubae                            |
| 17 and 18, isthmus uteri;            |  |

lateral umbilical ligament in front, and the ureter behind. The long axis of the ovary is vertical. The medial surface faces the pelvic cavity but is covered for a considerable distance by the tube, which first runs upward on the mesovarian border of the ovary, then at the uterine end of the ovary turns and descends on the free border of the ovary. The ovary is connected with the uterus by the **ligament of the ovary** (*ligamentum ovarii proprium*), which is a round cord lying between the two layers of the broad ligament of the uterus. It is composed for the most part of smooth muscular fibres continuous with the uterine muscles; the ligament of the ovary stretches from the uterine end to the lateral uterine angle. The ovary has a short mesentery, called the **mesovarium**, which is a peritoneal fold by means of which its anterior border is attached to the posterior layer of the broad ligament of the uterus. To the tubal end of the ovary are attached the ovarian fimbria (*fimbria ovarica*), which is the largest of the fimbriae surrounding the abdominal end of the tube, and a triangular peritoneal fold, the **suspensory ligament of the ovary** (*lig. suspensorium ovarii*) descending to the ovary from the pelvic terminal line and containing the ovarian vessels and nerves.

The ovary is filled with small vesicles called the **vesicular ovarian (Graafian) follicles** (*folliculi ovarici vesiculosi* s. *Graafi*), which shine through the epithelium of a fresh specimen; each follicle contains a developing female sex cell, the oocyte (or egg-cell). The follicles are lodged in the stroma (*stroma ovarii*), in which the vessels and nerves pass. Depending on the developmental stage, the follicles vary in size, from microscopic to 6 mm in diameter. When the ripe follicle ruptures (ovulation) and the oocyte is discharged from it, its walls collapse and its cavity is filled with blood and yellowish cells. As a result the yellow body (*corpus luteum*) is formed. The oocyte develops into a mature cell, after ovulation, in the uterine tube. When pregnancy occurs, the corpus luteum increases in size and transforms into a large structure about 1 cm in diameter, *corpus luteum verum* s. *graviditatis*, whose traces may persist for years; if ovulation of the oocyte that has left the follicle does not occur, the corpus luteum atrophies, loses its yellow colour and is now called the *white body* (*corpus albicans*). The corpus albicans disappears completely with time. A single follicle usually ripens in 28 days. As a result of the regular rupture of the follicles (ovulation) the surface of the ovary becomes covered with wrinkles and furrows in old age (the role of the corpus luteum is discussed in the chapter "The Endocrine Glands").

The ovary is not covered with the peritoneum, which is reduced here, but is instead covered with embryonic epithelium. Due to this the oocyte is discharged from the ruptured Graafian vesicle directly onto the surface of the ovary and then into the oviduct.

**Anomalies of the ovaries.** Accessory ovaries (*ovaria accessoria*) are sometimes encountered; these are portions separated from the germ of the sex gland. The ovary may be situated at the internal inguinal ring, in the inguinal canal or in the tissues of the labia majora. The last-named anomalies result from abnormal descent of the ovary (the descent of the ovary is of the same type as the descent of the testis).

The ovary is supplied with *nutrients* from the ovarian artery and ovarian branches of the uterine artery. The ovarian *veins* correspond to the arteries; they arise from the pampiniform (vine-shaped) plexus, pass through the suspensory ligament of the ovary, and drain into the vena cava inferior (right) and left renal vein (left). The *lymphatic vessels* drain lymph into the aortic lymph nodes.

*Innervation*: the ovary is supplied with sympathetic (from the coeliac, superior mesenteric, and inferior hypogastric plexus) and parasympathetic innervation. Some authors question the existence of the parasympathetic innervation, but it cannot be flatly denied.

## THE UTERINE TUBE

The **uterine, or Fallopian tube** (*tuba uterina* [*Fallopil*] s. *salpinx*) (Fig. 271) is a paired duct (oviduct) conveying the oocytes from the surface of the ovary, onto which they are discharged during ovulation, to the cavity of the uterus. Each tube is invested in a peritoneal fold, which is the upper portion of the broad ligament of the uterus and is termed the mesentery of the tube, *mesosalpinx*. The tube is 10-12 cm in length, on the average, the right tube usually being a little longer than the left one. The part of the tube nearer to the uterus runs horizontally for a distance of 1 or 2 cm but on reaching the pelvic wall it curves around the ovary, first ascending on its anterior border and then passing to the back and downward in close contact with the medial surface of the ovary. The following parts are distinguished in the tube: (1) **uterine** (*pars uterina*), the part embedded in the wall of the uterus; (2) **isthmus**, the nearest to the uterus uniformly constricted part (inner third of the tube) with a diameter of about 2-3 mm; (3) **ampulla**, the part continuous with the isthmus and gradually increasing in diameter (the ampulla accounts for approximately half of the length of the tube); (4) **infundibulum**, a continuation of the ampulla and, in compliance with its name, is a funnel-shaped expansion of the tube with numerous irregularly shaped processes, called *fimbriae tubae*, on its margins. One of these fimbriae, the largest usually, stretches in the peritoneal fold and reaches the ovary and is termed *fimbriae ovarica*. At the apex of the infundibulum is a round opening into the abdominal cavity (**ostium abdominale tubae**), through which the oocyte discharged from the ovary enters the ampulla of the tube. In cadavers, this opening is 2-3 mm in diameter, but in uterine tubes removed during operation it is found to be physiologically closed. The opposite opening of the tube, through which it opens into the cavity of the uterus, is called the **uterine opening** (*ostium uterinum tubae*).

**Structure of the wall of the tube.** Immediately under the peritoneum, or **serous coat** (*tunica serosa*) is a connective-tissue coat (*tunica subserosa*) containing vessels and nerves. Under the last-named is a **muscular coat** (*tunica muscularis*) consisting of two layers of smooth muscle fibres, an outer longitudinal and an inner circular layer; the circular layer is especially well developed in the part close to the uterus. The **mucous coat** (*tunica mucosa*) forms numerous longitudinal folds (*plicae tubariae*) and is covered with ciliated epithelium whose cilia drive the contents of the tube in the direction of the uterus. The mucous coat is continuous with the mucous coat of the uterus on one end and on the other end is in relation with the serous

coat of the abdominal cavity through the abdominal opening. As a result the tube opens into the abdominal cavity, which in females, as distinct from that in males, is not a closed serous sac.

#### THE EPOOPHORON AND PAROOPHORON

The epoophoron and paroophoron are two rudimentary structures enclosed between the layers of the broad ligament of the uterus: the epoophoron is between the tube and the ovary and corresponds to the efferent ductules of the testis, while the paroophoron is situated medially of it and corresponds to the paradidymis in males.

#### THE UTERUS

The uterus, or womb (*Gk metra s. hystera*) (Figs. 271, 272, and 274) is an unpaired hollow muscular organ situated in the cavity of the pelvis between the urinary bladder in front and the rectum behind. The oocyte entering the uterine cavity through the uterine tubes undergoes further development here if fertilized and remains in the uterus until delivery of the mature foetus. In addition to this generative function, the uterus is also concerned with menstrual activity.

A fully developed virgin uterus is pear-shaped and flattened from front to back. A fundus, body, and neck are distinguished in it. The fundus of the uterus (*fundus uteri*) is the upper part projecting above the line joining the points of entrance of the tubes into the uterus. The body (*corpus uteri*) is triangular, gradually narrowing toward the neck. The neck (*cervix uteri*) is a continuation of the body but is rounder and narrower. The external end of the cervix projects into the upper part of the vagina and is called the vaginal part (*portio vaginalis*). The upper segment of the neck with which the body is continuous is called the supravaginal part (*portio supravaginalis*). The anterior and posterior surfaces are separated from each other by the right and left borders (*margo uteri dextra* and *margo uteri sinistra*). Due to the considerable thickness of the walls, the cavity of the uterus (*cavum uteri*) is small in comparison with the size of the organ.

On a frontal section, the uterine cavity has the shape of a triangle with the base directed at the fundus and the apex facing the neck. The tubes open into the angles of the fundus, while at the apex of the triangle the uterine cavity is continuous with the cavity, or canal of the neck (*canalis cervicis uteri*). The junction of the body with the neck is a narrowed part and is called the isthmus (*isthmus uteri*). The cervical canal communicates with the cavity of the vagina by means of the uterine opening, external os uteri (*ostium uteri*). The os uteri (Fig. 273) is round or transversely oval in nulliparas but has the appearance of a transverse slit with healed tears on the margins in women who have given birth to children. The cervical canal in nulliparas is spindle-shaped. The ostium uteri, or mouth of the womb, is bounded by two lips, anterior and posterior (*labium anterius* and *labium posterius*). The posterior lip is thinner and projects downward less than the

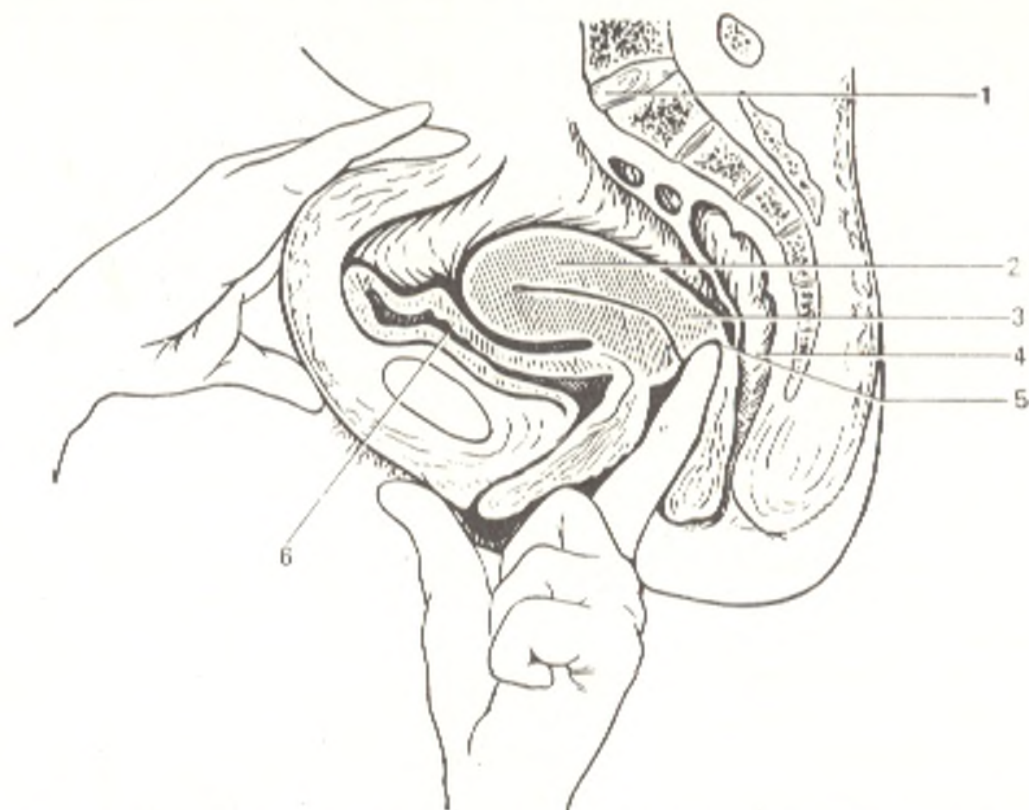


Fig. 272. Sagittal section through organs of the female pelvis in bimanual palpation of the uterus (the left index finger is introduced into the vagina).

- |                  |                    |
|------------------|--------------------|
| 1, promontorium; | 4, rectum;         |
| 2, corpus uteri; | 5, fornix vaginae; |
| 3, cervix uteri; | 6, vesica urinaria |

thicker anterior lip. It also appears longer because the vagina is attached to it at a higher level than to the anterior lip. The mucous membrane is smooth and is devoid of folds in the cavity of the uterine body but forms palmate folds, *arbor vitae* (*plicae palmatae*) in the cervical canal, which consist of an anterior and a posterior longitudinal ridges and a series of lateral rugae directed laterally and upward.

The *uterine wall* is composed of three main layers.

1. The outer layer, the *serous coat* (*tunica serosa*), or *perimetrium*, is the visceral peritoneum, which firmly adheres to the uterus. (In practice it is important to distinguish the perimetrium, i.e. the visceral peritoneum, from the parametrium, i.e. the fatty tissue on the anterior surface and along the sides of the cervix uteri, between the peritoneal layers forming the broad ligament of the uterus.)

2. The middle layer, the *muscular coat* (*tunica muscularis*), or *myometrium*, is the main part of the uterine wall. It consists of smooth muscle fibres interlacing one with another in different directions. Three layers can be distinguished in it: an inner longitudinal (corresponds to lamina muscularis mucosae), a middle circular, the thickest of the three layers (large venous plexus passes in it as a consequence of which it is called stratum vasculosum), and an outer longitudinal layer lying under the peritoneum (stratum supra-vasculosum).



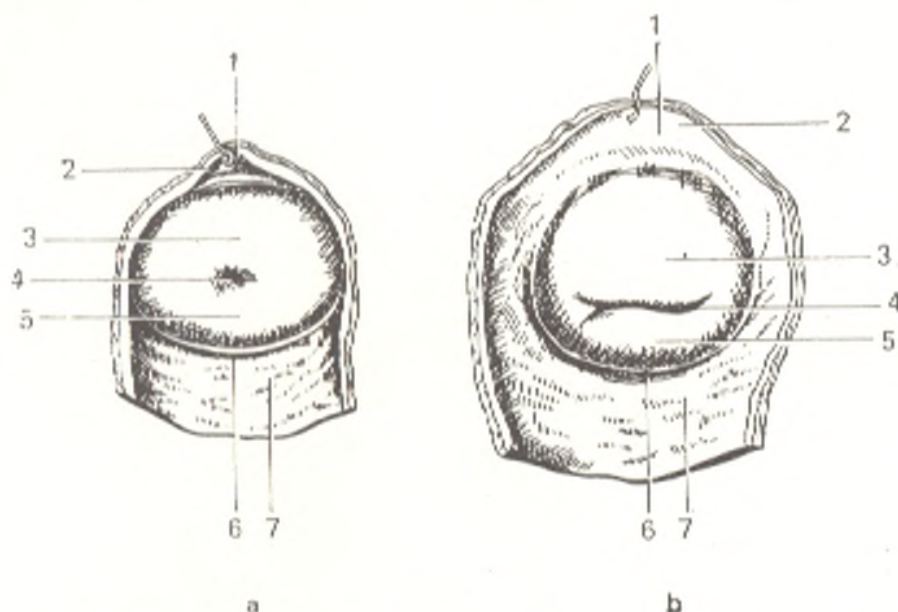


Fig. 273. Vaginal part (portio vaginalis) of uterine cervix (viewed from below).

a, in a nullipara;  
 b, in a female who has given  
 birth to children:  
 1, fornix vaginae (anterior);  
 2, paries anterior vaginae;

3, labium anterius;  
 4, ostium uteri;  
 5, labium posterius;  
 6, fornix vaginae (posterior);  
 7, paries posterior vaginae

The separation into layers is most pronounced in the neck; the amount of connective tissue with an admixture of elastic fibres is considerably greater here than in the body of the uterus, that is why the cervix is in general distinguished by greater firmness.

3. The inner layer, the *mucous coat* (*tunica mucosa*), or *endometrium*, is covered with ciliated epithelium and has no folds. It is supplied with simple tubular glands, *glandulae uterinae*, which extend to the muscular coat. In addition to the tubular glands, mucous glands, *glandulae cervicales*, are present in the thicker mucous membrane of the cervix.

The average length of a mature, non-pregnant uterus ranges from 6.0 to 7.5 cm of which about 2.5 cm are accounted for by the length of the cervix. At birth the neck is longer than the body of the uterus, but with the onset of puberty the last-named grows intensively.

The *pregnant uterus* changes rapidly in size and shape. By the eighth month it becomes 18-20 cm in length, acquires a rounded oval shape and with growth moves apart the layers of the broad ligament. Some of the muscle fibres not only multiply in number but also increase in size. After delivery the uterus gradually diminishes in size, though in quite a short time, and regains its former state but is a little larger in dimensions. The enlarged muscle fibres undergo fatty degeneration.

In old age the uterus atrophies and its tissue becomes paler in colour and harder to the touch.

**Topography of the uterus.** Possessing a considerable degree of mobility, the uterus is so positioned that its longitudinal axis is approximately parallel to the axis of the pelvis. When the bladder is empty, the fundus of the uterus

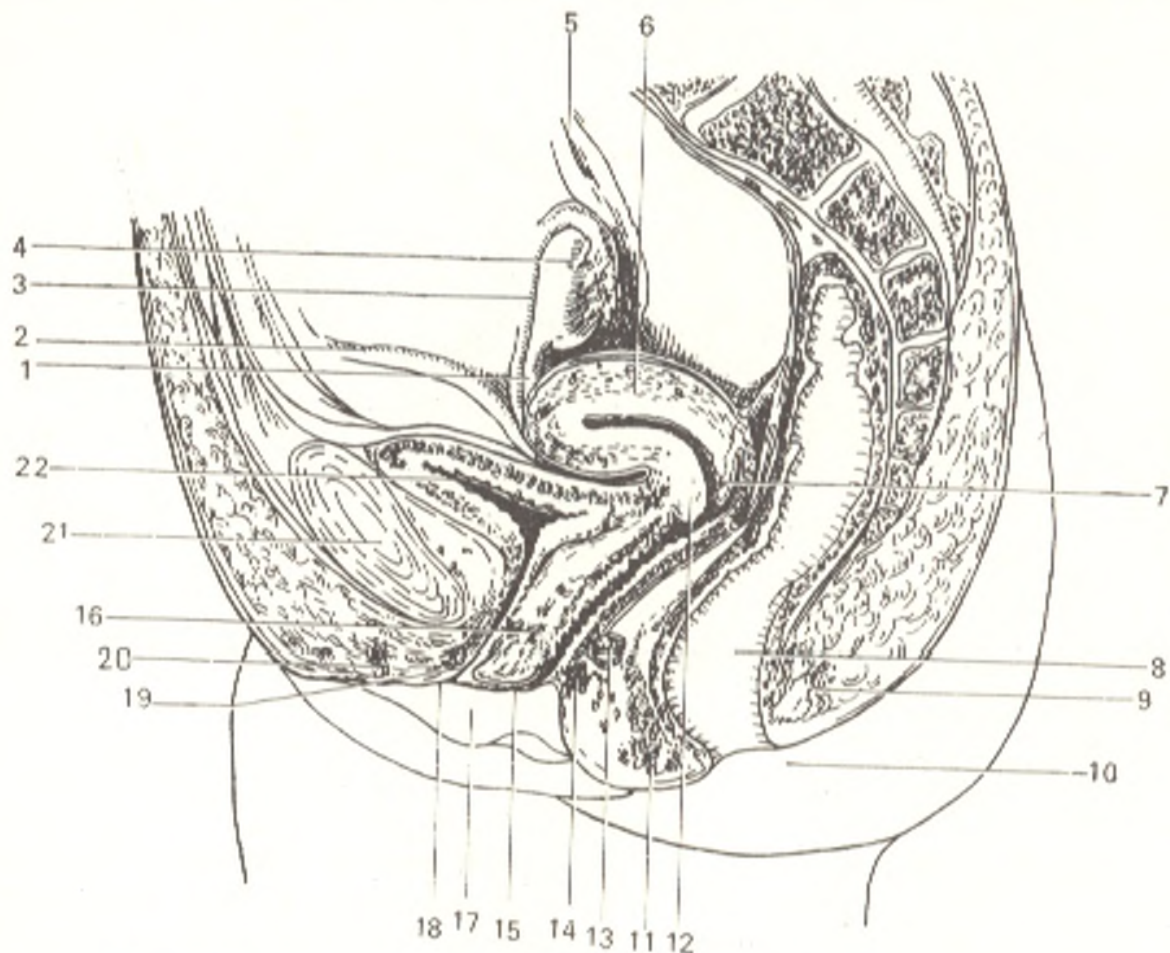


Fig. 274. Median sagittal section through female genital organs.

- |                                      |                                     |
|--------------------------------------|-------------------------------------|
| 1, lig. teres uteri;                 | 12, labium anterius uteri;          |
| 2, lig. ovarii proprium;             | 13, 14, and 16, muscles of the uro- |
| 3, tuba uterina;                     | genital diaphragm;                  |
| 4, ovarium;                          | 15, vagina;                         |
| 5, ureter;                           | 17, labium minus pudendi;           |
| 6, uterus;                           | 18, labium majus pudendi;           |
| 7, labium posterius uteri;           | 19, urethra;                        |
| 8, rectum;                           | 20, clitoris;                       |
| 9 and 11, m. sphincter ani externus; | 21, symphysis pubica;               |
| 10, anus;                            | 22, vesica urinaria                 |

is directed forward while its anterior surface faces forward and downward; this forward inclination of the uterus is known as **anteversion** (*anteversio*). In this position, the uterus being flexed forward on the cervix forms with it an angle opened forward; this is called **anteflexion** (*anteflexio*). In distention of the bladder, the uterus may be inclined backward, **retroversion** (*retroversio*) with its longitudinal axis passing downward and forward. Backward flexion of the uterus, **retroflexion** (*retroflexio*) is a pathological condition.

The peritoneum covers the uterus anteriorly to the junction of the body with the neck and is then reflected on the urinary bladder (Fig. 274). The peritoneal pouch formed as the result is called the **vesicouterine pouch** (*excavatio vesicouterina*). The anterior surface of the cervix is connected to the posterior surface of the bladder by means of loose cellular tissue. From the posterior uterine surface the peritoneum passes to the posterior wall of the

vagina, which it covers for a small distance and is then reflected on the rectum. The deep peritoneal pouch between the rectum at the back and the uterus and vagina in front is called the **rectouterine (Douglas') pouch** (*excavatio rectouterina* s. *cavum Douglasi*). The entrance into this pouch is bounded on the sides by the **rectouterine folds** (*plicae rectouterinae*) stretching from the posterior surface of the cervix to the lateral surface of the rectum. In addition to the connective tissue, bundles of smooth muscle fibres forming the **rectouterine muscles** (*mm. rectouterini*) are present in these folds.

The peritoneal layers covering the anterior and posterior surfaces of the uterus come together at its borders and extend to the lateral walls of the pelvis as the **broad ligaments of the uterus** (*ligamenta lata uteri*), which are also (below the mesosalpinx) its mesentery, the *mesometrium*. The uterus with its broad ligaments is situated transversely in the pelvis and, as it is said above, divides its cavity into two parts, the anterior, vesicouterine pouch, and the posterior, rectouterine pouch. The medial part of the broad ligament changes its position with a change in the position of the uterus. In anteversion (when the bladder is empty) it is almost horizontal and its anterior surface faces downward and the posterior surface upward. The lateral part of the ligament lies more vertically in the sagittal direction. In the free edge of the broad ligament is enclosed the uterine tube, on the anterior and posterior surfaces are two eminences formed by the **round ligament of the uterus** (*lig. teres uteri*) and the **ligament of the ovary** (*lig. ovarium proprium*). The ovary is attached to the posterior surface of the broad ligament by means of a short *mesenterium*, the *mesovarium*. The triangular area of the ligament bounded by the tube above and the ovarium below is the mesentery of the tube, *mesosalpinx*, formed of two intimately adjoining layers of the broad ligament. On the sides of the cervix and upper area of the vagina, in contrast, the layers separate and an aggregation of loose fatty tissue containing blood vessels lies between them. This cellular tissue is called the **parametrium**. The **round ligaments** (*ligamenta teres uteri*) arise one on each side, from the superior angles of the uterus and ascend anteriorly and laterally toward the deep inguinal ring. After passing through the inguinal canal the round ligament reaches the pubic symphysis where its fibres blend with the connective tissue of the *mons pubis* and the *labium majus*.

In addition to the connective-tissue fibres, the round ligament also contains muscular fibres, which are a continuation of the fibres of the uterine outer muscular layer. Like the vaginal process in males, the peritoneum together with the round ligament advances for some distance as a diverticulum into the inguinal canal in embryonic life; this peritoneal diverticulum in females is called the *processus vaginalis peritonei*; in adult females it is usually obliterated. The round ligament is analogous with the *gubernaculum testis* in males.

On a **radiograph** a normal uterine cavity filled with the contrast medium is seen as a triangle whose apex is directed downward and the base upward. The angles of the triangle correspond to the three uterine orifices. A normal uterine cavity can hold 4 to 6 ml of fluid (Fig. 275).

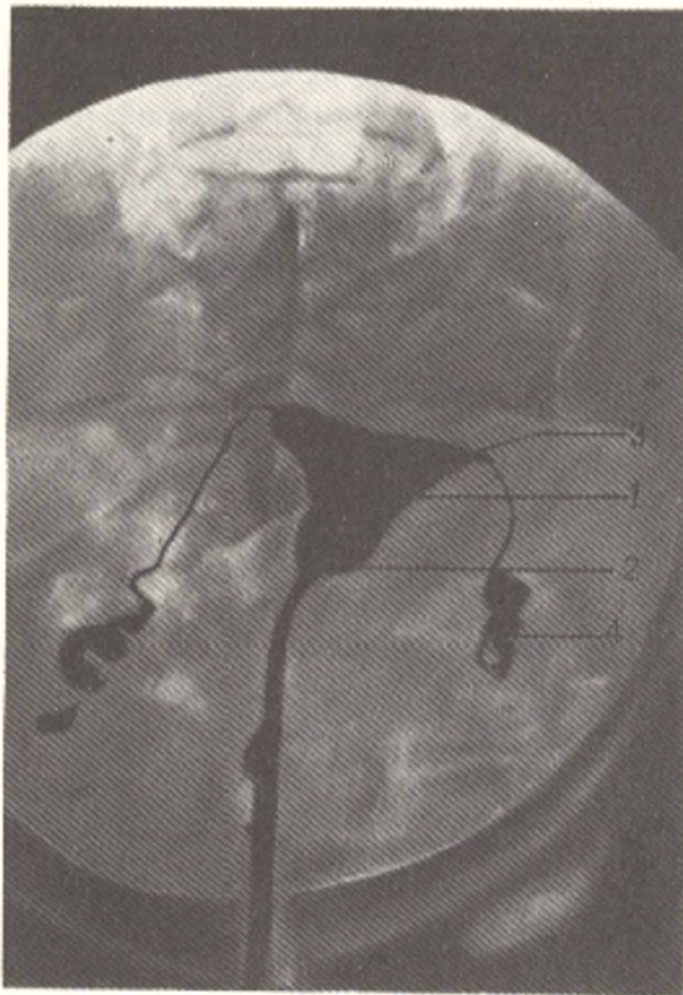


Fig. 275. Radiograph of uterus and oviducts.

- 1, body of uterus;
- 2, neck of uterus;
- 3, uterine opening of oviduct;
- 4, oviduct

The tubes produce long and narrow shadows bent in different manner. Nearer to the abdominal ends the tube becomes wider and constrictions alternate here with dilatations producing the pattern of beads. A series of radiographs demonstrates twisting movements of the tube during peristalsis. A sphincter is seen where the tube drains into the uterus.

The uterus receives *arterial blood* from the uterine artery and partly from the ovarian artery. The uterine artery supplying the uterus, the broad and round ligaments, the tube, the ovary, and the vagina passes in the base of the broad ligament downward and medially, crosses the ureter, gives off the vaginal artery to the cervix and vagina, and then turns upward and ascends to the upper uterine angle. The uterine artery lies on the lateral border of the uterus and in females who have borne children is distinguished by its tortuousness. On its way it gives off branches to the body of the uterus. On reaching the fundus, the uterine artery separates into two terminal branches, *ramus tubarius* (to the tube) and *ramus ovaricus* (to the ovary). The branches anastomose in the uterine tissue with the collateral branches and form rich networks in the muscular and mucous coats and develop particularly in pregnancy. The uterus is drained of blood by *veins* which form the uterine plexus. From this plexus the blood flows in three directions: (1) from the ovary, tube, and upper part of the uterus into the ovarian vein; (2) from the lower half of the uterine body and upper portion of the neck into the uterine vein; (3) from the lower portion of the neck and the vagina directly into the internal iliac vein. The uterine plexus anastomoses with the veins of the bladder and the rectal plexus. The *lymphatic vessels* draining the uterus pass in two directions: (1) from the uterine fundus along the tubes to the ovaries and then to the aortico-abdominal (lumbar) nodes; (2) from the body and neck of the uterus in the

thickness of the broad ligament, in attendance to the blood vessels, to the hypogastric (from the uterine neck) and the iliac (from the neck and body) nodes. Lymph from the uterus may also flow into the sacral and inguinal nodes in vessels passing on the round ligament.

The uterus is *innervated* from the inferior hypogastric plexus (sympathetic innervation) and from the pelvic splanchnic nerves (parasympathetic innervation). These nerves form the uterovaginal plexus in the region of the uterine cervix.

## THE VAGINA

The **vagina** (Gk *sheath*) is a distensible musculo-fibrous tube about 8 cm in length whose upper end embraces the uterine cervix while the lower end opens by means of ostium vaginae into the pudendal cleft. The vagina has a slight backward convexity. Its longitudinal axis forms with the uterine axis an angle of slightly more than 90 degrees open to the front. In passing from the pelvic cavity to the pudendal cleft the vagina pierces the urogenital diaphragm. The **anterior and posterior walls of the vagina** (*paries anterior and posterior*) are in contact one with the other and since the uterine cervix projects into the cavity of the vagina above, a recess forms around the cervix and is termed the **fornix vaginae**. A deeper posterior and a shallow anterior fornix are distinguished (see Fig. 273). The vagina is slightly wider in the upper than in the lower part. The upper portion of the anterior vaginal wall adjoins the fundus of the bladder from which it is separated by areolar tissue while the lower portion is connected with the urethra. The posterior wall of the vagina is covered with peritoneum in its upper fourth (the Douglas' space or pouch), lower it adjoins the rectum but gradually moves away from it in the perineum.

The vaginal orifice is closed in virgins (*virgo intacta*) by a mucosal fold, the *hymen femininus*, which leaves only a small opening. The hymen is usually circular in shape. Sometimes its edges are fringed, in which case there is *hymen fimbriatus*. In rare cases the hymen closes the entrance into the vagina completely—*hymen imperforatus*. In females who have borne children only small protuberances, fragments of the hymen, remain around the orifice; these are the *carunculae myrtiformes* (hymenales).

The vaginal walls consist of three coats. An outer coat consists of thick connective tissue. A middle, thin muscular coat consists of smooth muscle fibres intersecting in different directions in which, however, an inner circular and an outer longitudinal layer can be distinguished to a certain degree. A rather thick inner mucous coat is covered by numerous transverse ridges known as the *vaginal rugae* (*rugae vaginales*). These ridges fold to form two longitudinal *columns of the rugae* (*columnae rugarum*) one of which passes in the middle of the anterior and the other on the posterior vaginal wall. The columns are developed best in the lower part of the vagina and disappear at the top. In a child's vagina the rugae continue to the upper end.

The vaginal mucosa is covered with stratified squamous epithelium but is devoid of glands; occasional lymph nodes (*folliculi lymphatici vaginales*) are encountered here and there.

**Colposcopy** (visual examination of the vagina and neck of the uterus) shows the mucous membrane of these organs in a living woman to be uniformly red and possessing clearly detectable blood vessels. Normally there should be neither defects nor growths.

The *vessels* and *nerves* of the vagina are related intimately to those of the uterus. The *arteries* of the vagina arise from the uterine artery and partly from the inferior vesical, the middle rectal, and the internal pudendal arteries.

The *veins* form on the sides of the vagina rich venous plexuses, which anastomose with the veins of the external genital organs and the venous plexuses of the neighbouring pelvic organs. Blood from the plexus flows into the internal iliac vein.

The vagina is drained of *lymph* in three directions: from the upper part to the internal iliac nodes, from the lower part to the inguinal nodes, and from the posterior wall to the sacral nodes.

The *nerves* of the vagina are derived from the inferior hypogastric plexus (sympathetic nerves), the pelvic splanchnic nerves (parasympathetic nerves), and the pudendal nerve (to the lower part of the vagina).

### PUDENDUM FEMININUM

**Pudendum femininum** is a collective term applied to the female external genital organs, i.e. the labia majora and the structures lying between them (Fig. 276).

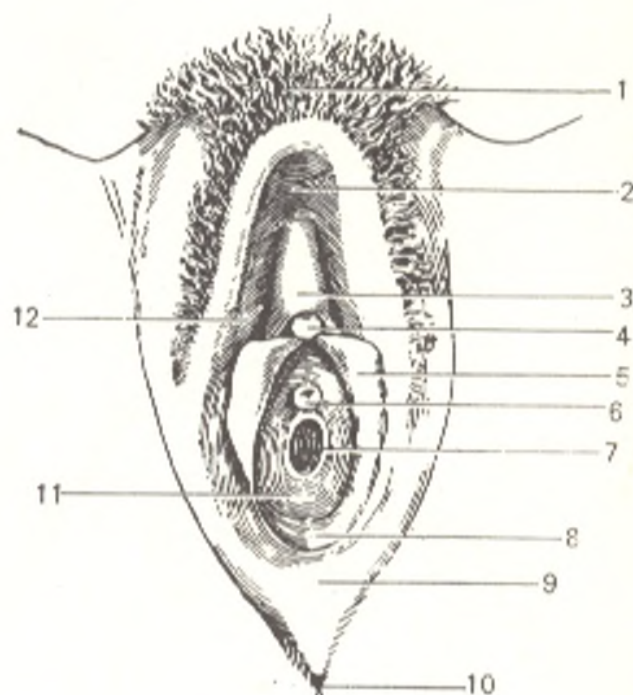
**Labia majora pudendi** are two folds of skin containing connective tissue rich in fat. They are connected to each other by skin elevations called commissures: a wider **anterior commissure** (*commissura labiorum anterior*) and a narrower **posterior commissure** (*commissura labiorum posterior*). The slit-like space bounded on the sides by the labia majora is named the **pudendal cleft** (*rima pudendi*). Upward of the labia majora, in front of the symphysis pubis, a well developed layer of fat forms the **mons pubis**. The mons and the lateral surface of the labia majora are covered with hair. The upper border of the hair is 9-10 cm below the umbilicus and is directed horizontally. The skin on the medial surface of the labia majora closer to the midline is thin and resembles the mucous membrane in its red colour and moisture.

Medial of the labia majora are the **labia minora pudendi** (nymphae), usually completely hidden in the cleft between the labia majora. Like the labia majora, labia minora are two longitudinal folds of skin resembling the mucous membrane in appearance. The labia minora bear no hair but have small sebaceous glands (*glandulae vestibulares minores*). The medial surfaces of the labia minora are in contact with each other. The anterior end of each labium divides into two limbs: the lateral limb curves around the clitoris and unites with the contralateral limb to form the **prepuce of the clitoris** (*preputium clitoridis*). The medial limbs join at an acute angle and are attached below to the glans of the clitoris and form the **frenulum of the clitoris** (*frenulum clitoridis*). The posterior ends of the labia minora unite by means of a small transverse fold called the **frenulum labiorum** (*frenulum labiorum pudendi*).

The slit-like space between the labia minora is known as the **vestibule of the vagina** (*vestibulum vaginae*). The urethra, the vagina, and the ducts of the vestibular glands open into it. The external urethral orifice (ostium

Fig. 276. External genital organs of a virgin.

- 1, mons pubis;
- 2, commissura laborium ant.;
- 3, preputium clitoridis;
- 4, glans clitoridis;
- 5, labium minus pudendi;
- 6, ostium urethrae externum;
- 7, ostium vaginae;
- 8, vestibulum vaginae;
- 9, commissura laborium posterior;
- 10, anus;
- 11, hymen;
- 12, labium majus pudendi



urethrae externum) is approximately 2 cm behind the glans of the clitoris; its margins are prominent and, therefore, easily palpated. Behind and below this opening is a much larger orifice of the vagina (ostium vaginae) closed by the hymen in virgins. On each side of the vaginal orifice in the groove between the hymen and the root of the labia minora is the opening of the duct of the **greater vestibular** or **Bartholin's gland** (*glandula vestibularis major s. Bartolini*). Bartholin's glands, one on each side, correspond to the Cowper's glands in the male and are oval structures 10-12 mm in diameter; they are situated on the posterior ends of the vestibular bulbs. In addition to these glands, there are minute sebaceous glands called the lesser vestibular glands (*glandulae vestibulares minores*) opening on the mucosal surface between the urethral and vaginal orifices.

The female genital organs contain structures equivalent of the cavernous bodies in the male; these are the bulbs of the vestibule and the clitoris.

The **bulb of the vestibule** (*bulbus vestibuli*) corresponds to the spongy body of the penis, but in females the cavernous tissue here is separated by the urethra and vagina into two symmetrical parts. Each bulb is a thick venous network resembling cavernous tissue, about 3 cm in length and 1.5 cm in width, and is situated laterally of the lower end of the vagina.

The **clitoris** (Fig. 277) corresponds to the cavernous body of the penis and consists of a glans, body, and crura. The **body** (*corpus clitoridis*) is enclosed in a dense fibrous capsule—**fascia of the clitoris** (*fascia clitoridis*) and divided by an incomplete septum into two symmetrical halves, the *corpora cavernosa of the clitoris* (*corpora cavernosa clitoridis*). The body of the clitoris tapers anteriorly and terminates as the **glans of the clitoris** (*glans clitoridis*). The prepuce and the frenulum of the clitoris, which are mentioned above, are continuous with the labia minora. Posteriorly the body of the clitoris

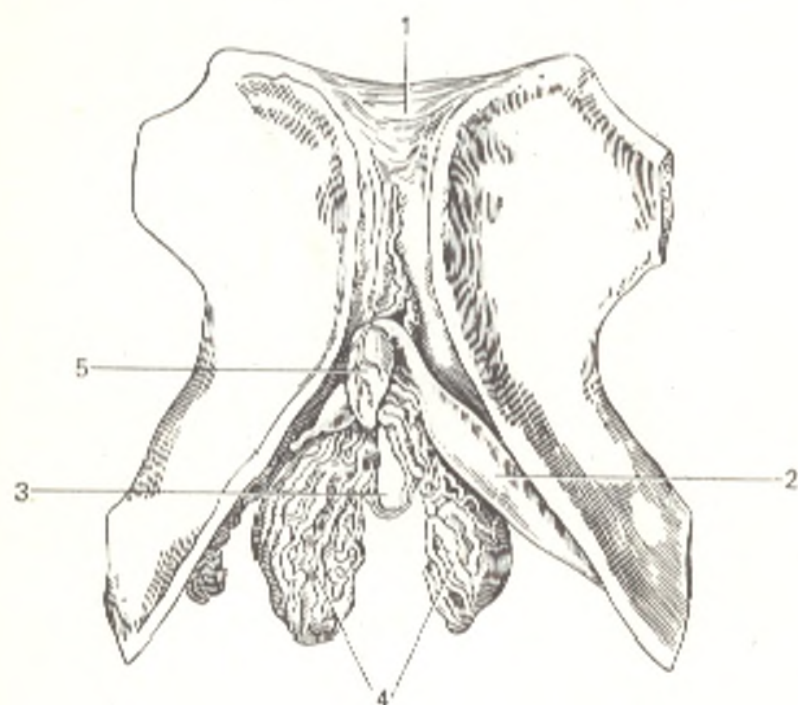


Fig. 277. Cavernous structures of female genital organs.

- 1, symphysis pubica;  
 2, corpus cavernosum clitoridis;  
 3, place where the urethra passes;  
 4, bulbos vestibuli;  
 5, clitoris

separates into two crura of the clitoris (*crura clitoridis*), which are attached to the inferior rami of the pubic bones. The body of the clitoris is fastened on the pubic symphysis by the **suspensory ligament of the clitoris** (*lig. suspensorium clitoridis*).

The pudendum receives *arterial blood* from the internal and external pudendal arteries. *Venous blood* drains into the internal and external pudendal veins and into the inferior rectal vein. *Lymph* flows into the superficial inguinal nodes.

*Innervation* is supplied from the ilioinguinal, genitofemoral, and pudendal nerves and from the sympathetic trunk.

#### DEVELOPMENT OF THE UROGENITAL ORGANS

The homology of the structure of the male and female genital organs can be understood and the anomalies and malformations sometimes encountered here can be interpreted only if the main facts of the development of the urinary and reproductive system are known. These systems are intimately related developmentally while their ducts open into a common *urogenital sinus* (*sinus urogenitalis*). The urinary system is marked by a specific feature: it does not develop from a single germ which gradually grows and becomes more and more complicated but is represented by a series of morphological structures replacing one another in succession (the pronephros, the mesonephros, and the metanephros, or permanent kidney).

The morphological structures concerned with the development of the urogenital organs are as follows (Fig. 278).

1. The *pronephros*. In man and higher vertebrates it rapidly disappears in the embryo to be replaced by the more important mesonephros.

2. The *mesonephros* (Wolffian body) and its duct called the *mesonephric* or *Wolffian duct* (*ductus mesonephricus*). The mesonephric duct is the earliest of the structures from which the urogenital organs are derived. It appears in the mesoderm on the 15th day of the embryonal life as a nephrogenic cord on the medial side of the body cavity (the coelom), and on the third week a cavity forms in it and the duct reaches the cloaca. The mesonephros consists of a number of transverse tubules arranged medially of the upper segment of the mesonephric duct, one end of the tubule opens into the duct while the other end is blind.



The mesonephros is the primary secretory organ while the mesonephric duct serves as its efferent passage (Fig. 279).

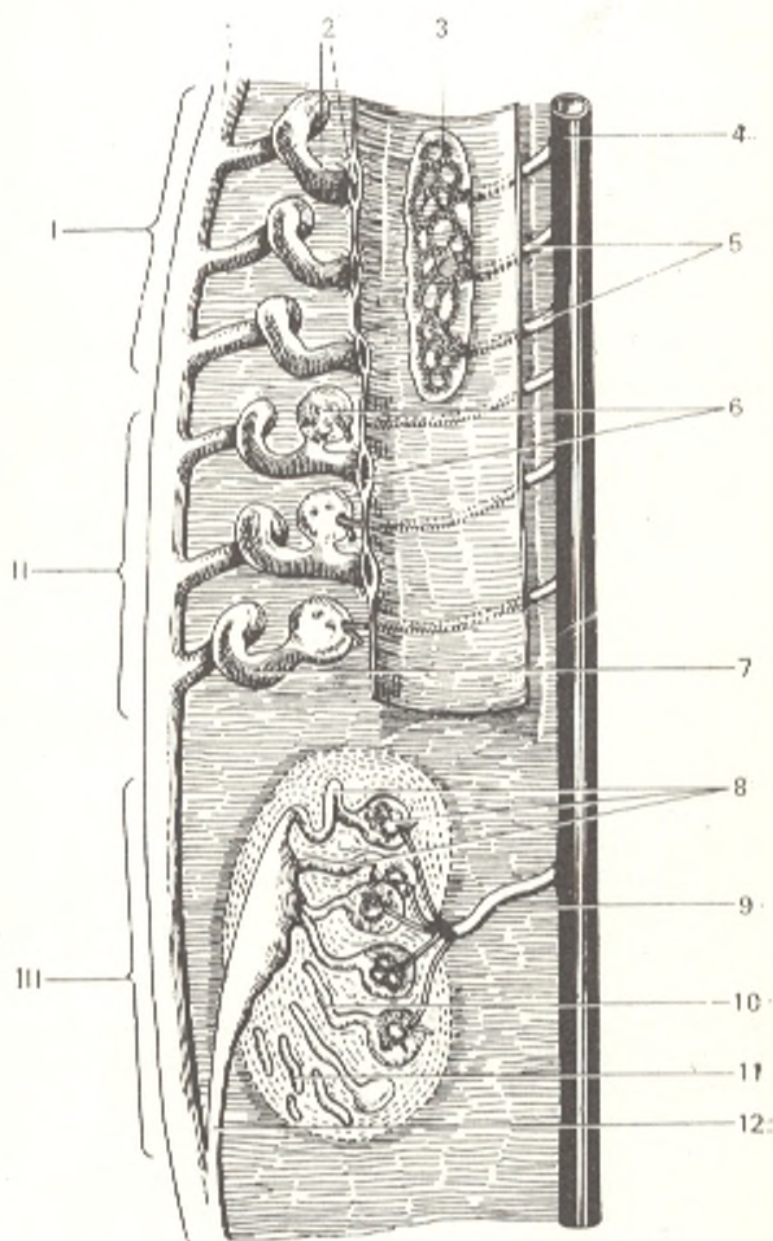
3. The *paramesonephric (Muellerian) duct (ductus paramesonephricus)*. At the end of the fourth week a longitudinal thickening of the peritoneum forms on the lateral side of each mesonephros due to the development of an epithelial cord, which transforms into a duct at the beginning of the fifth week. The cranial end of the paramesonephric duct opens into the body cavity slightly in front of the anterior end of the mesonephros. In contrast to the mesonephric ducts each opening separately, the paramesonephric ducts unite on the midline into a common duct at their caudal ends on reaching the urogenital sinus.

4. The *sex glands* develop a little later as a conglomerate of embryonic epithelium on the medial side of the mesonephros. The testicular seminiferous tubules and the ovarian follicles containing the oocytes develop from the embryonic epithelial cells. A connective-tissue cord called the gubernaculum Hunteri stretches from the lower pole of the sex gland and its lower end runs into the inguinal canal.

The final formation of the urogenital organs occurs as follows. The mesonephros is gradually replaced by the permanent kidney, the *metanephros*, developing from the same

Fig. 278. Development of the kidney, schematical representation.

- I, pronephros;
- II, mesonephros;
- III, metanephros;
- 1, ductus mesonephricus;
- 2, tubules of pronephros with the infundibulum;
- 3, glomeruli of pronephros;
- 4, aorta;
- 5, segmental arteries of pronephros glomerulus;
- 6, glomerulus and infundibulum of mesonephros;
- 7, tubules of mesonephros without infundibulum;
- 8, tubules of permanent kidney with glomeruli;
- 9, a. renalis;
- 10, tubules of permanent kidney;
- 11, nephrogenic tissue;
- 12, ureter



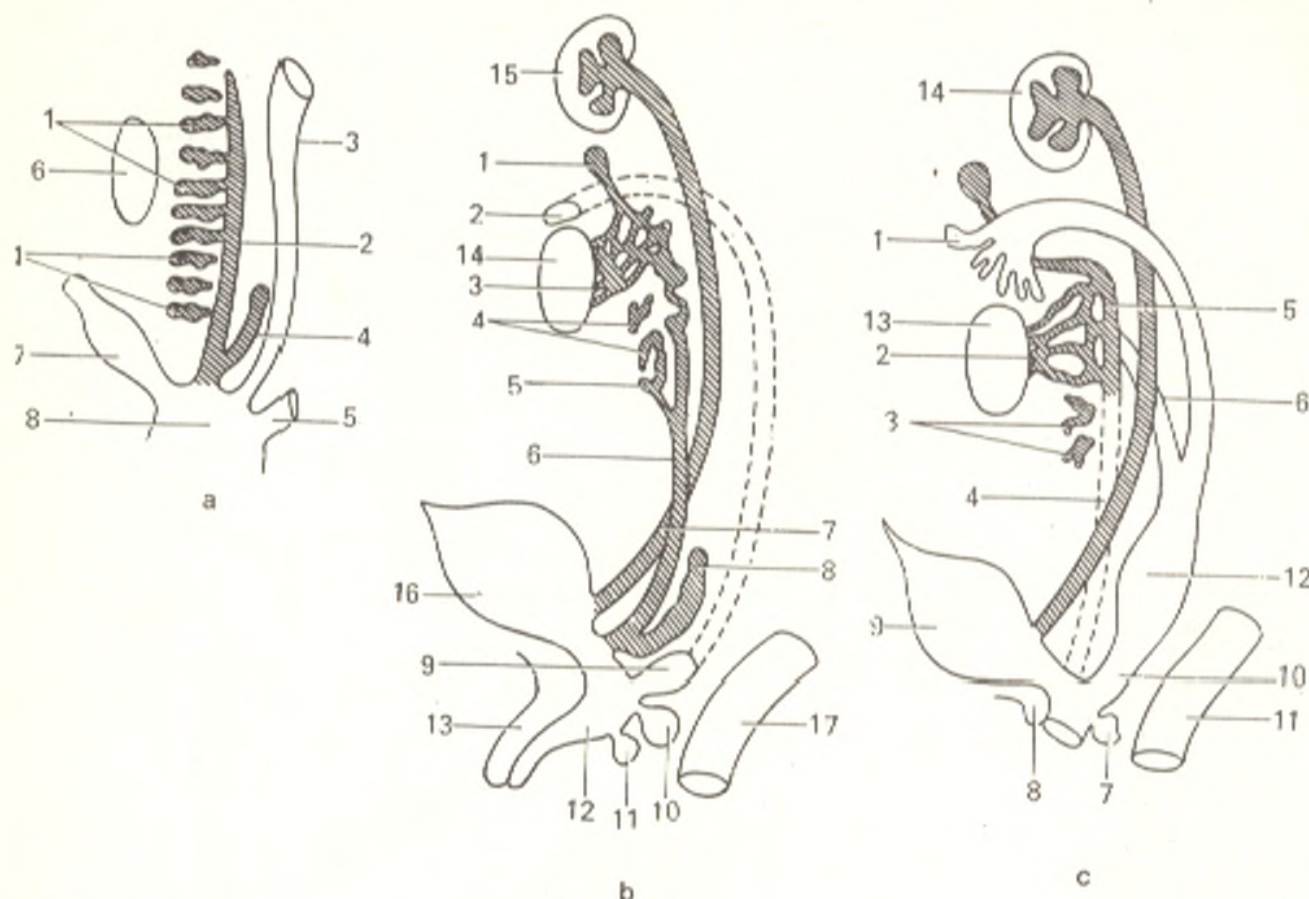


Fig. 279. Differentiation of genital organs from one indifferent type, represented schematically.

- |                                  |                                |
|----------------------------------|--------------------------------|
| a, indifferent type:             |                                |
| 1, group of mesonephros tubules; |                                |
| 2, ductus mesonephricus;         |                                |
| 3, ductus paramesonephricus;     |                                |
| 4, ureter germ;                  |                                |
| 5, hindgut;                      |                                |
| 6, gonad;                        |                                |
| 7, allantois;                    |                                |
| 8, cloaca;                       |                                |
| b, male type:                    |                                |
| 1, appendix epididymidis;        |                                |
| 2, appendix testis;              |                                |
| 3, ductuli efferentes;           |                                |
| 4, paradidymis;                  |                                |
| 5, ductus aberrans;              |                                |
| 6, vas deferens;                 |                                |
| 7, ureter;                       |                                |
| 8, seminal vesicle;              |                                |
| 9, utriculus prostaticus;        |                                |
| 10, prostata;                    |                                |
| 11, Cowper's gland;              |                                |
|                                  | 12, urethra;                   |
|                                  | 13, corpus cavernosum;         |
|                                  | 14, testis;                    |
|                                  | 15, kidney;                    |
|                                  | 16, bladder;                   |
|                                  | 17, rectum;                    |
|                                  | c, female type:                |
|                                  | 1, fimbriae;                   |
|                                  | 2, epoophoron tubules;         |
|                                  | 3, paroophoron;                |
|                                  | 4 and 5, ductus mesonephricus; |
|                                  | 6, oviduct;                    |
|                                  | 7, Bartholin's gland;          |
|                                  | 8, clitoris;                   |
|                                  | 9, bladder;                    |
|                                  | 10, vagina;                    |
|                                  | 11, rectum;                    |
|                                  | 12, uterus;                    |
|                                  | 13, ovary;                     |
|                                  | 14, kidney                     |

nephrogenic cord as the mesonephros. The nephrogenic cord gives rise to the mesenchyme proper of the permanent kidneys (the renal tubules). From the third month the permanent kidneys replace the mesonephros as the functioning excretory organs.

Since the trunk grows downward more rapidly than the urinary organs, the kidneys seem to move upward and occupy their place in the lumbar region.

The renal pelvis and the ureter develop from a diverticulum of the caudal end of the mesonephric duct at the beginning of the fourth week; the cranial end of the diverticulum reaches the nephrogenic cord and unites with the kidney. The caudal end of the

diverticulum separates from the mesonephric duct and drains into that part of the cloaca (sinus urogenitalis) from which the fundus of the urinary bladder develops; the ureters open in the fundus.

The development of the bladder is related to the transformation of the cloaca.

The cloaca is a common cavity in the human embryo into which the ducts of the urinary and reproductive systems and the hindgut open initially. It is a blind sac closed by the cloacal membrane (*membrana cloacalis*) on the outer surface. A frontal urorectal septum (*membrana urorectale*) develops later in the cloaca, which divides it into two parts, a ventral, urogenital sinus (*sinus urogenitalis*) and a dorsal part, the rectum.

After the cloacal membrane ruptures both these parts open to the exterior by means of two orifices: the urogenital sinus by an anterior orifice (the opening of the urogenital system) and the rectum by a posterior orifice (the anus).

The urogenital sac, the allantois, is connected with the urogenital sinus. In lower vertebrates it is a reservoir for the products discharged by the kidneys, whereas in man it transforms into the urinary bladder.

The allantois consists of three parts: the lowest part is a portion of the urogenital sinus from which the trigone of the bladder develops; the middle dilated part, which transforms into the rest of the bladder, and the upper narrowed part, the *urachus*, which passes from the bladder to the umbilicus. In lower vertebrates it drains the contents of the allantois, in man it obliterates by the time of birth and becomes a fibrous cord, the *median umbilical ligament* (*lig. umbilicale medianum*).

The remnants of the mesonephric tubules in males are the straight tubules, the rete testis, the efferent ductules, the aberrant ductules, and the rudimentary structure, paradidymis; in females the remnants are the rudimentary tubules of the epoophoron and paroophoron. The mesonephric duct gives rise to the epididymal duct, the vas deferens, and the ejaculatory duct in males and the rudimentary longitudinal duct of the epoophoron in females.

The paramesonephric ducts give rise to the uterine tubes, the uterus, and the vagina in females. The tubes are derived from the non-united upper parts of the paramesonephric duct while the uterus and the vagina form from the fused lower parts. In males the paramesonephric ducts undergo reduction and only the testicular appendix and the prostatic utricle remain. Thus, the paramesonephric ducts undergo reduction and transform into rudimentary structures in males, and the mesonephric ducts in females.

**Anomalies of the urinary organs.** Normally the kidneys are a paired organ. In certain cases, however, there is a third kidney situated between two kidneys or below one of them. Then a solitary kidney marked by compensative enlargement may sometimes be observed. Disease of a single kidney may be fatal. A kidney, which, during its development, fails to rise to the normal position, will be situated at a much lower level; this condition is known as dystopia.

In low position of both kidneys and fusion of their lower poles a horseshoe kidney forms; the site of their fusion, the isthmus, lies directly on the spine. The kidney of an adult, which retains a position characteristic of a child's kidney, remains on a high level and its whole anterior surface is in contact with the anterior abdominal wall (a child's position).

A case with a double-chamber bladder has been described (Robson and Ruth, 1964). When the hip bones fail to unite in the region of the pubic symphysis, the bladder may remain exposed (ectopia vesicae). In males this anomaly is often attended with abnormal opening of the urethra on the penis, the condition is called epispadias or hypospadias penis.

**Anomalies of the uterus, tubes, and vagina.** In rare cases the paramesonephric ducts retain full independency, as a result of which a double uterus and double vagina develop. Incomplete fusion of the ducts leads to the formation of a single vagina and a single uterus but with a bifid fundus. The condition is known as a bifid uterus. This developmental anomaly reflects the existence of a bifid uterus in some mammals. An inner septum or only half of it persists in the uterus and vagina in some cases. A unicorn uterus forms in complete reduction of one of the paramesonephric ducts. In some cases the vagina is absent and the uterus is a rudimentary structure.

**Development of the external genital organs.** The germs of the external genital organs become detectable around the slit-like opening, the urogenital sinus, on the eighth week of intrauterine development. At first they are alike in the male and female embryos: at

the anterior end of the external, or genital cleft is the genital tubercle, the margins of the sinus are formed by the genital folds; the genital tubercle and the genital folds are surrounded laterally by genital swellings.

These germs in a male undergo the following changes: the genital tubercle develops greatly in length and the penis forms from it. With growth of the penis the genital cleft under its inferior surface correspondingly increases and transforms into the urethra when the genital folds fuse together. The genital swelling grows intensively and becomes the scrotum as the result of fusion of both its halves on the midline.

In a female the genital tubercle grows poorly and transforms into the clitoris. The growing genital folds give rise to the labia minora but the folds do not fuse and the urogenital sinus remains open and transforms into the vaginal vestibulum. The two (right and left) halves of the genital swelling also do not fuse together but develop into the labia majora.

The female external genital organs are in general closer in structure to the initial embryologic germs than the male external genitals.

## THE PERINEUM

The perineum is an area corresponding to the pelvic outlet and is filled with striated muscles, which are invested in fasciae and form together with them two diaphragms: the **urogenital diaphragm** (*diaphragma urogenitale*) and the **pelvic diaphragm** (*diaphragma pelvis*). Both diaphragms transmit to the exterior the canals of the urogenital and digestive systems for which they form sphincters closing the external openings of these canals.

The perineum can be compared with a diamond-shaped figure whose four angles correspond with the following four points: the pubic symphysis in front, the apex of the coccyx behind, and the ischial tuberosity on the right and the left. The area is made up of two triangles, an anterior one filled by the urogenital diaphragm and a posterior triangle filled by the pelvic diaphragm. The bases of both diaphragms adjoin at approximately a straight angle, the urogenital diaphragm stands almost frontally and the pelvic diaphragm horizontally.

The urogenital diaphragm occupies the whole anterior triangular area bounded by the pubic symphysis in front (the apex of the triangle), and by the rami of the pubic and ischial bones laterally; posteriorly (the base of the triangle) it terminates as a free margin. The urogenital diaphragm transmits the urethra (*pars membranacea*) in males and the urethra and vagina in females. The pelvic diaphragm occupies the posterior triangle whose apex is formed by the coccyx and the other two angles by the ischial tuberosities. It transmits the rectum (anus) both in males and in females. The space between the anus and the external genital organs (the pudendal cleft in females) is known as the perineum in the narrow sense of the word.

## THE MUSCLES OF THE PERINEUM

Both diaphragms contain muscles arranged in two layers, deep and superficial. The urogenital diaphragm consists of muscles, which had initially surrounded the opening of the cloaca (*m. sphincter cloacae*). After the cloaca separates into the rectum and the urogenital sinus (see "Development of the

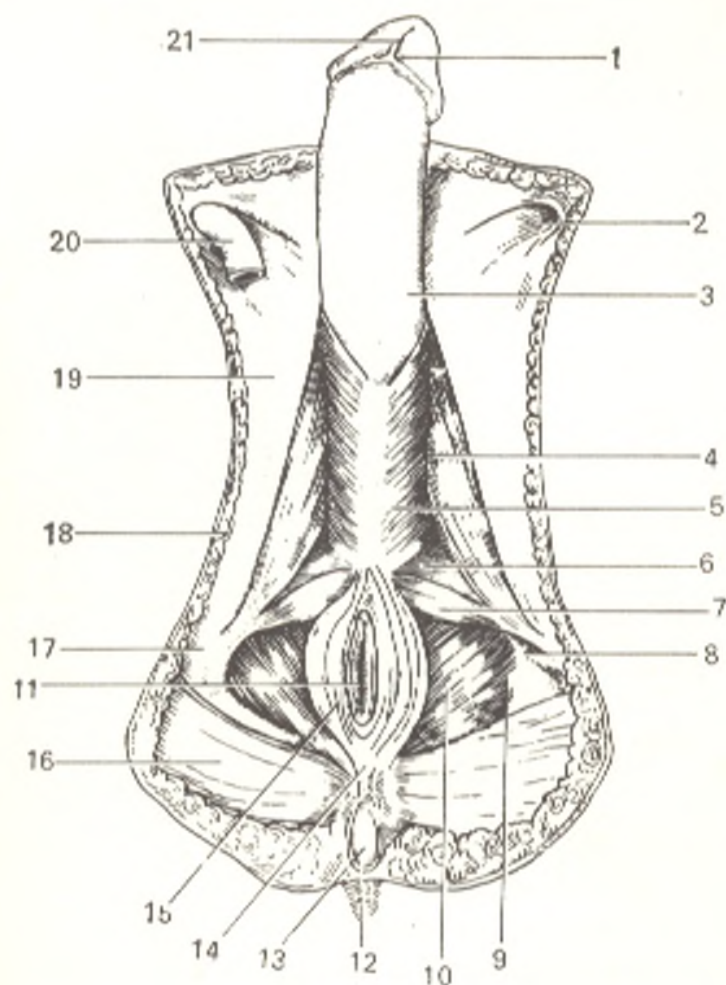


Fig. 280. Muscles of the male perineum.

- 1, glans penis;
- 2, anulus inguinalis superficialis;
- 3, fascia penis;
- 4, m. ischioavernosus;
- 5, m. bulbospongiosus;
- 6, diaphragma urogenitale;
- 7, m. transversus perinei superficialis;
- 8, fascia obturatoria;
- 9, fossa ischiorectalis;
- 10, m. levator ani;
- 11, anus;
- 12, skin in the coccygeal region;
- 13, os coccygis;
- 14, lig. anococcygeum;
- 15, m. sphincter ani externus;
- 16, m. gluteus maximus;
- 17, tuber ischii;
- 18, fatty tissue;
- 19, fascia lata;
- 20, funiculus spermaticus;
- 21, frenulum preputii (cut off)

Urogenital Organs") the sphincter muscle of the cloaca also separates into two parts: a posterior part surrounds the anus and becomes the sphincter and externus muscle (a component of the pelvic diaphragm); an anterior part encloses the urogenital sinus and transforms into the urogenital diaphragm. The different differentiation of the urogenital sinus in the male and female determines the different development of the muscles of the urogenital diaphragm in them (see Figs. 280, 281, 282 and 283).

The **urogenital diaphragm** (*diaphragma urogenitale*) (see Figs. 280, 281 and 282) has the following *deep muscles*.

1. The *deep transverse perineal muscle* (*m. transversus perinei profundus*) is a flat muscle enclosing the membranous part of the urethra. It arises from the ischial tuberosities and the adjoining parts of the rami of the ischial bones, runs medially and slightly to the front and is inserted into the *central perineal tendon* (*centrum perineale*), which is the site of insertion of many perineal muscles. The main action of the muscle consists in reinforcing the urogenital diaphragm and the urethra together with it.

At the site where the urogenital diaphragm transmits the urethra some of the fibres of the deep transverse perineal muscle change from a transverse to a circular course and surround the urethra and form its sphincter muscle (*m. sphincter urethrae*).

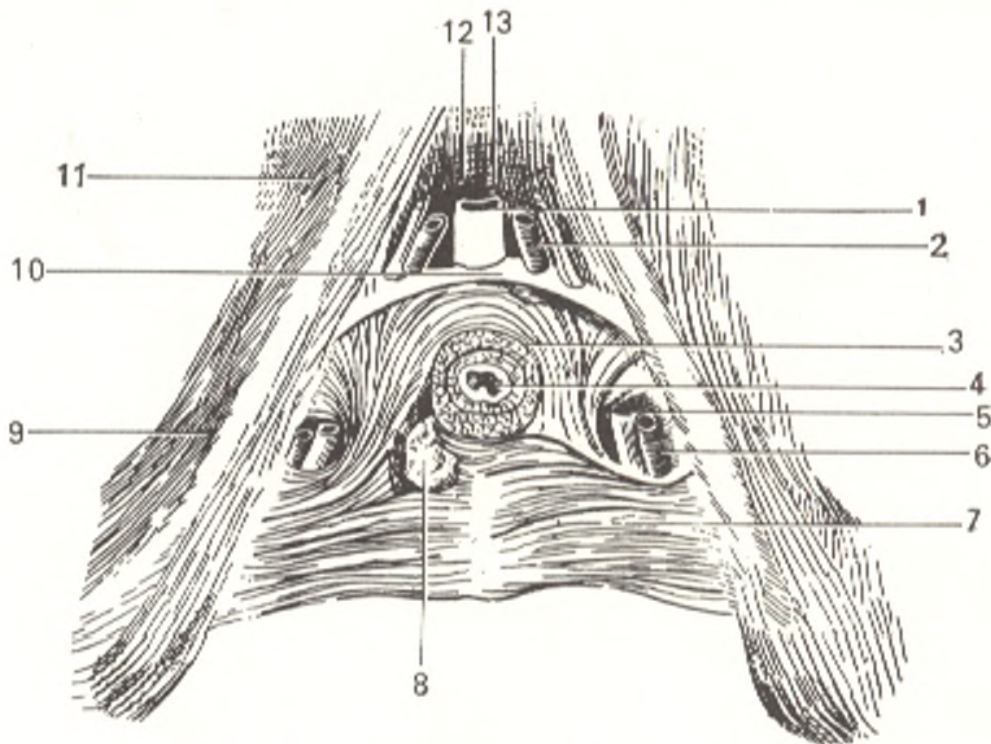


Fig. 281. Muscles of the male urogenital triangle.

- |                                      |                                 |
|--------------------------------------|---------------------------------|
| 1, v. dorsalis penis;                | 8, glandula bulbourethralis;    |
| 2, a. dorsalis penis;                | 9, ramus ossis ischii;          |
| 3, m. sphincter urethrae;            | 10, lig. transversum perinei;   |
| 4, urethra;                          | 11, ramus inferior ossis pubis; |
| 5, v. profunda penis;                | 12, symphysis pubica;           |
| 6, a. profunda penis;                | 13, lig. arcuatum pubis         |
| 7, m. transversus perinei profundus; |                                 |

2. The *sphincter urethrae muscle* (*m. sphincter urethrae*) surrounds the membranous part of the urethra like a ring and constricts it on contraction.

The muscular layer of the urogenital diaphragm in females is formed by the poorly developed deep transversus perinei muscle and circular slips of muscle fibres, analogues of the sphincter urethrae muscle in males. These fibres enclose together with the urethra also the vagina and cause their constriction by contracting.

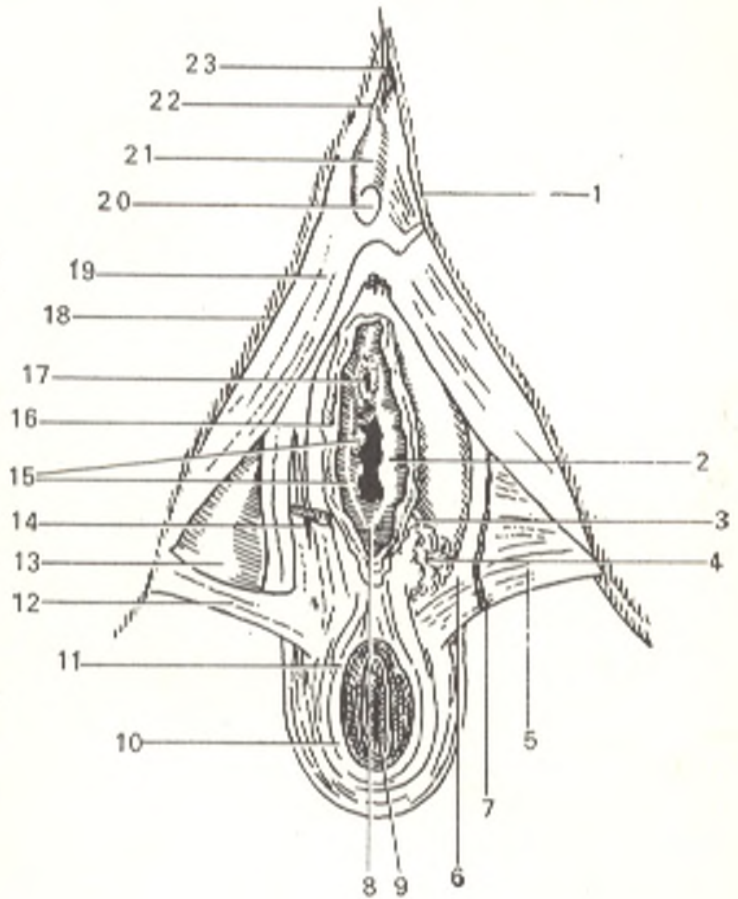
The *superficial muscles of the urogenital diaphragm* are as follows.

1. The *bulbospongiosus muscle* of males differs from that of females. In the male it surrounds the inferolateral surface of the bulbus and the adjoining part of the spongy body of the penis and fuses on the midline with its fellow by means of a narrow tendinous raphe running longitudinally. By compressing the urethra on contraction the bulbospongiosus muscle contributes to the ejaculation of the semen and the excretion of the urine (*m. ejaculator seminis* and *accelerator urinae*). In females the muscle separates into two symmetric halves surrounding the vaginal orifice. On contraction it narrows the opening of the vagina (*m. constrictor cunni*) (see Fig. 282).

2. *M. ischiocavernosus* arises on either side from the ischial tuberosity and is inserted into the cavernous body. It contributes to the erection of the penis or clitoris by compressing the veins.

Fig. 282. Muscles of the female perineum, bulb of vestibule, and urogenital triangle.

- 1, ramus inferior ossis pubis;
- 2, vestibulum vaginae;
- 3, ductus excretorius glandulae vestibularis majoris;
- 4, glandula vestibularis major;
- 5, m. transversus perinei profundus;
- 6, fascia diaphragmatis urogenitalis inferior;
- 7 and 12, m. transversus perinei superficialis;
- 8, columna rugarum;
- 9, anus;
- 10 and 11, m. sphincter ani externus;
- 13, trigonum urogenitale;
- 14 and 19, m. bulbospongiosus (the superficial bundles are cut off);
- 15, carunculae hymenales;
- 16, labium minus pudendi (cut off);
- 17, ostium urethrae externum;
- 18, m. ischioavernosus;
- 20, glans clitoridis;
- 21, corpus clitoridis;
- 22, lig. fundiforme clitoridis (cut off);
- 23, lig. suspensorium clitoridis



3. The *superficial transversus perinei muscle* (*m. transversus perinei superficialis*) is a thin muscular slip stretching transversely from the ischial tuberosity toward the collateral muscle and is inserted on the midline into the central tendon of the perineum. On contraction it holds steady this centre. In females this muscle is poorly developed.

The superficial transversus perinei muscle lies on a line coinciding with the bases of the anterior and posterior triangles adjacent one to the other (see p. 576) and forms a kind of boundary between both diaphragms.

The **pelvic diaphragm** (*diaphragma pelvis*) forms the floor of the pelvic cavity.

The *deep muscles* of the pelvic diaphragm are as follows.

1. *M. levator ani* is a flat triangular muscle forming together with the contralateral muscle a sort of an overturned dome. It arises on the pelvic wall anteriorly from the descending ramus of the pubic bone lateral of the pubic symphysis, then from the fascia of the internal obturator muscle, and posteriorly from the pelvic surface of the ischial spine. The line of the initial fixation in the space between its extreme points forms a *tendinous arch of the levator ani muscle* (*arcus tendineus m. levatoris ani*). From this place, some of the muscular bundles pass backward and medially, curve around the rectum posteriorly, unite with the contralateral bundles, thus encircling the rectum and fusing with its muscular coat. The other part of the levator ani muscle bypasses the rectum and runs on the lateral side of the prostata and

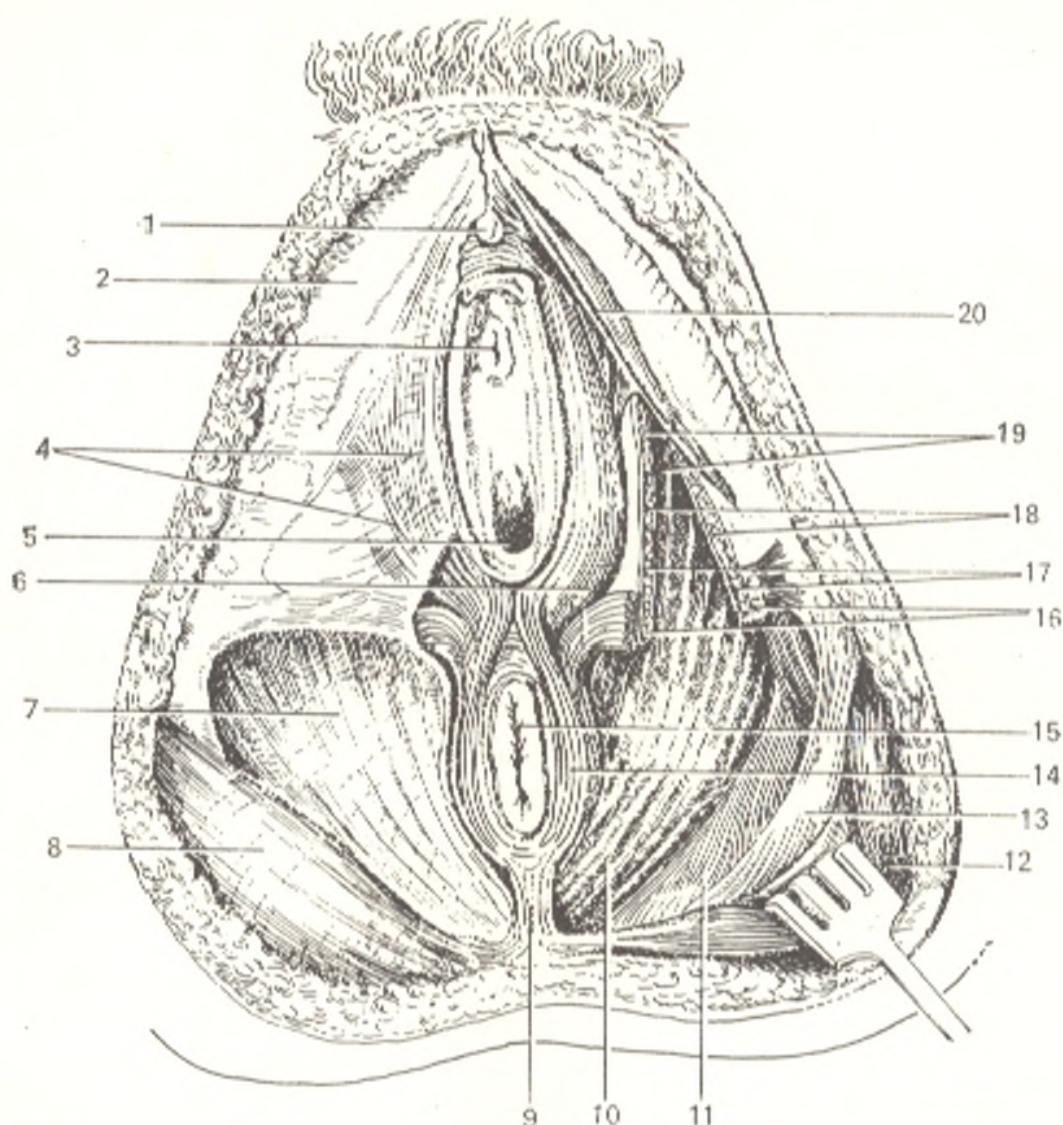


Fig. 283. Muscles and fasciae of the female perineum, viewed from below (on the right, the fasciae are removed).

- |  |   |
|--|---|
| 1, glans clitoridis;                     | 12, m. gluteus maximus;                         |
| 2, fascia lata;                          | 13, lig. sacrotuberale;                         |
| 3, ostium urethrae externum;             | 14, m. sphincter ani externus;                  |
| 4, fascia superficialis perinei;         | 15, anus;                                       |
| 5, ostium vaginae;                       | 16, m. transversus perinei superficialis;       |
| 6, m. bulbospongiosus;                   | 17, m. transversus perinei profundus;           |
| 7, fascia diaphragmatis pelvis inferior; | 18, fascia diaphragmatis urogenitalis inferior; |
| 8, fascia glutea;                        | 19, fascia diaphragmatis urogenitalis superior; |
| 9, lig. anococcygeum;                    | 20, m. ischiocavernosus                         |
| 10, m. levator ani;                      |   |
| 11, lig. sacrospinale;                   |   |

bladder and in females also the vagina; it is intimately related to these organs and blends with the muscles of the vagina and bladder: it then passes to the coccyx into whose apex it is inserted by means of the anococcygeal body. Besides elevating the anus, the levator ani muscle reinforces the pelvic floor and in females also compresses the vagina.

2. *M. coccygeus* is a part of the muscular layer of the posterior portion of the pelvic diaphragm. It arises from the ischial spine and the pelvic sur-



face of the sacrospinous ligament, passes medially expanding fan-like, and is inserted into the lateral border of the coccyx and the apex of the sacrum.

The external (voluntary) sphincter of the anus, *m. sphincter ani externus*, is the only *superficial muscle* of the pelvic floor. It lies under the skin around the anus on the outside of the internal smooth-muscle sphincter (*m. sphincter ani internus*) formed by the muscular coat of the rectum (see Fig. 280).

## FASCIAE OF THE PERINEUM

1. The **pelvic fascia** (*fascia pelvis*) is a continuation of the iliac fascia in the true pelvis (Fig. 283). Two parts, parietal and visceral, are distinguished in it. The *parietal pelvic fascia* (*fascia pelvis parietalis*) lines the walls of the true pelvis (the internal obturator and the piriform muscles) and is then reflected on the superior surface of the pelvic diaphragm to cover the levator ani muscle. This part of the parietal pelvic fascia is also termed the *superior fascia of the pelvic diaphragm* (*fascia diaphragmatis pelvis superior*) which, having covered the diaphragm, is reflected on the pelvic organs passing through the floor of the pelvis and invests them as the *visceral pelvic fascia* (*fascia pelvis visceralis*). Spaces filled with loose connective tissue form between the pelvic fascia and the peritoneum lining the pelvis on the inside. One of these, the *retropubic space* (*spatium retropubicum*), is behind the pubic symphysis and in front of the bladder, extending to the bladder to form the *perivesical space* (*spatium perivesicale*). Another space, the *retrorectal space* (*spatium retrorectale*), is situated in front of the sacrum and behind the rectum.

The inferior (external) surface of the pelvic diaphragm is covered by the *inferior fascia of the pelvic diaphragm* (*fascia diaphragmatis pelvis inferior*). As a result, the muscles of the pelvic floor are contained between two fasciae, the superior and inferior fasciae of the pelvic diaphragm, together with which they form the pelvic diaphragm. In view of the fact that the action of the diaphragm consists in supporting the viscera these fasciae are distinguished by a great strength.

Since the pelvic diaphragm slightly protrudes downward like a dome, below, between it and the ischial tuberosities, on either side of the rectum forms a paired *ischiorectal fossa* (*fossa ischiorectalis*) filled with fatty tissue, *paraproctium* (hence *paraproctitis*, inflammation of this tissue).

2. The **superior and inferior fasciae of the urogenital diaphragm** (*fasciae diaphragmatis urogenitalis superior and inferior*) cover the deep transversus perinei and sphincter urethrae muscles in front (the inferior fascia) and behind (the superior fascia) and form together with them the urogenital diaphragm. Anteriorly, where the deep transversus perinei muscle does not reach the pubic symphysis, both fasciae fuse to form the fibrous portion of the urogenital diaphragm, which is called the *transverse perineal ligament* (*lig. transversum perinei*). The dorsal vein of the penis (or of the clitoris) passes in front of this ligament, between it and the *arcuate pubic ligament* (*lig. arcuatum pubis*) (see Fig. 283).

The fasciae also unite posteriorly on the posterior border of the deep transversus perinei muscle. Laterally, the superior fascia having covered the prostata is continuous with the pelvic fascia, whereas the inferior fascia fuses with the bulb of the penis on the midline, covers the bulbourethral glands, and separates the deep muscles of the urogenital diaphragm from the superficial muscles.

In females both fasciae of the urogenital diaphragm join the vagina and fuse with the bulb of its vestibule.

3. The **superficial fascia of the perineum** (*fascia perinei superficialis*) is a continuation of the subcutaneous fascia of the body to the perineum. It covers the superficial muscles of the urogenital diaphragm (mm. bulbospongiosus, ischiocavernosus and transversus perinei superficialis) and together with the inferior fascia of the urogenital diaphragm forms a sheath for the spongy bodies of the penis. In females this fascia is divided into two halves by the vestibule of the vagina (see Fig. 283).

The perineal region is supplied with *arterial blood* from the internal pudendal artery. On leaving the ischioanal fossa this artery gives off one to three inferior rectal arteries, which pass to the muscles and the skin of the anus. At the inferior border of the urogenital diaphragm the internal pudendal artery separates into two terminal branches, the profunda penis and the dorsal penis arteries. The *veins* pass in attendance to the arteries. The perineum is drained of *lymph* into the superficial inguinal lymph nodes. The skin of the perineum is *innervated* from the pudendal nerve, which, in addition, gives off the inferior rectal, perineal, and posterior scrotal nerves, as well as from the coccygeal plexus.

# THE SCIENCE OF THE ORGANS OF INTERNAL SECRETION

## THE ENDOCRINE GLANDS (GLANDULAE ENDOCRINAE)

As the result of metabolism taking place under the effect of the nervous system chemical compounds form in the body. Possessing high physiological activity, they regulate the normal performance of the functions of the body and participate in the process of its growth and development. This is *chemical regulation*.

In the protozoan unicellular organisms devoid of a nervous system, the functions of the body and its connection with the external environment are regulated only by chemical substances contained in the body fluids; this is chemical or *humoral regulation*. In this case the physiologically active substances circulate by diffusion in plasma in the unicellular organisms and along a system of special tubes, the vessels, in the multicellular organisms. With the appearance of the nervous system *neuro-humoral* regulation gradually develops, in which the chemically active substances and the nerve elements become intimately related.

The active chemical substances produced during metabolism under the effect of the nervous system become at the same time the stimulators of this system and are termed mediators, i.e. transmitters of the nerve stimulation (e.g. sympathin, acetylcholine, histamine, etc.). They act far from the site of their production (distant activators) and spread rapidly in the blood vascular and lymphatic systems. These distant activators are produced in specially developing organs called the *endocrine glands* (Gk *endon* within, *krinein* to secrete). These are glands, which have no duct (glandulae sine ductibus) and which discharge their secretions directly into the vascular system, in contrast to the exocrine glands whose secretions or excretions are discharged onto the surface of the skin (the sweat and sebaceous glands) or the mucous membrane (the salivary glands, the liver, etc.).

**Common anatomo-physiological properties of the endocrine glands.** Despite the difference in their shape, size, and position, the endocrine glands have anatomo-physiological properties in common. First, they are devoid of ducts. Since their secretions are discharged into the blood vascular system, the endocrine glands possess an expansively developed network of blood vessels. These blood vessels pierce the gland in different directions and play a role similar to that of the ducts of the endocrine glands. Glandular cells discharging their secretion into the blood are arranged around the vessels.

In addition to the richness in blood vessels, specific features of the capillary network of these glands can be pointed out. It may consist of very dilated irregular capillaries termed sinusoids whose endothelial wall comes

in direct contact with the epithelial cells of the gland without an intervening connective tissue. Besides, the wall of the sinusoids is even interrupted in places and the epithelial cells project directly into the vascular lumen. In relatively wide sinusoids the blood flows slower, which provides a more lasting and intimate contact between the cells of the gland and blood flowing through its vessels. In comparison to their significance in the body, the size of the endocrine glands is relatively small. For instance, the largest gland, the thyroid, weighs only about 35 g on the average; the parathyroid glands, whose extirpation leads to tetanic spasms and death, are only approximately 6 mm in length.

The products of the secretory activity of the endocrine glands are known as *incretions* or *hormones* (*Gk hormon* to stir up). The secreted substance may possess a specific action in relation to some organ or tissue. The *incretion* of the thyroid, for instance, has a direct effect on metabolism and its disappearance from the body causes disorders in nutrition. Other substances secreted by the endocrine glands cause an effect on the growth and development of the organism. Despite the fact that hormones enter the blood in small amounts, they are marked by a strong physiological action.

The *connection of the endocrine glands with the nervous system* is of two kinds. First, the glands are richly supplied with innervation from the vegetative nervous system, i.e. from that part of the nervous system, which innervates the viscera; the tissue of the thyroid, suprarenals, and testis is pierced by numerous nerve fibres. Second, the *incretions* of the glands cause an effect, in turn, on the nerve centres through the blood. In addition, the neurons of one of the glands (the hypophysis) contribute to the production of mediators, which reach the vasoneural synapses along the axons of these neurons and enter the blood through the synapses. This phenomenon of the production of hormonal substances by the nerve cells is termed *neurosecretion*. The intimate relation between the endocrine glands and the nervous system is also due to the fact that the development of many of them is linked with the nervous system. For instance, the posterior hypophysial lobe and the epiphysis cerebri are projections of the brain, whereas the medulla of the suprarenal gland develops in association with the sympathetic ganglia (part of the vegetative nervous system; see section on the nervous system). This determines the effect of its hormones on the sympathetic system, which is intimately connected with the chromaffin organs.

*Development.* Embryologically the endocrine glands differ in origin. In this respect even separate parts of one and the same gland may be distinguished, for instance, the medulla and cortex of the suprarenal gland. The ectoderm gives rise to the hypophysis, epiphysis cerebri, the medulla of the suprarenal glands, and the chromaffin organs. The thyroid, parathyroids, the thymus, and the insular apparatus of the pancreas develop from the entoderm. The cortex of the suprarenal glands and the endocrine organs of the sex glands are derived from the mesoderm.

Five groups of endocrine glands can, therefore, be distinguished according to the site of their development (Fig. 284).

1. Entodermal glands arising from the pharynx and branchial pouches

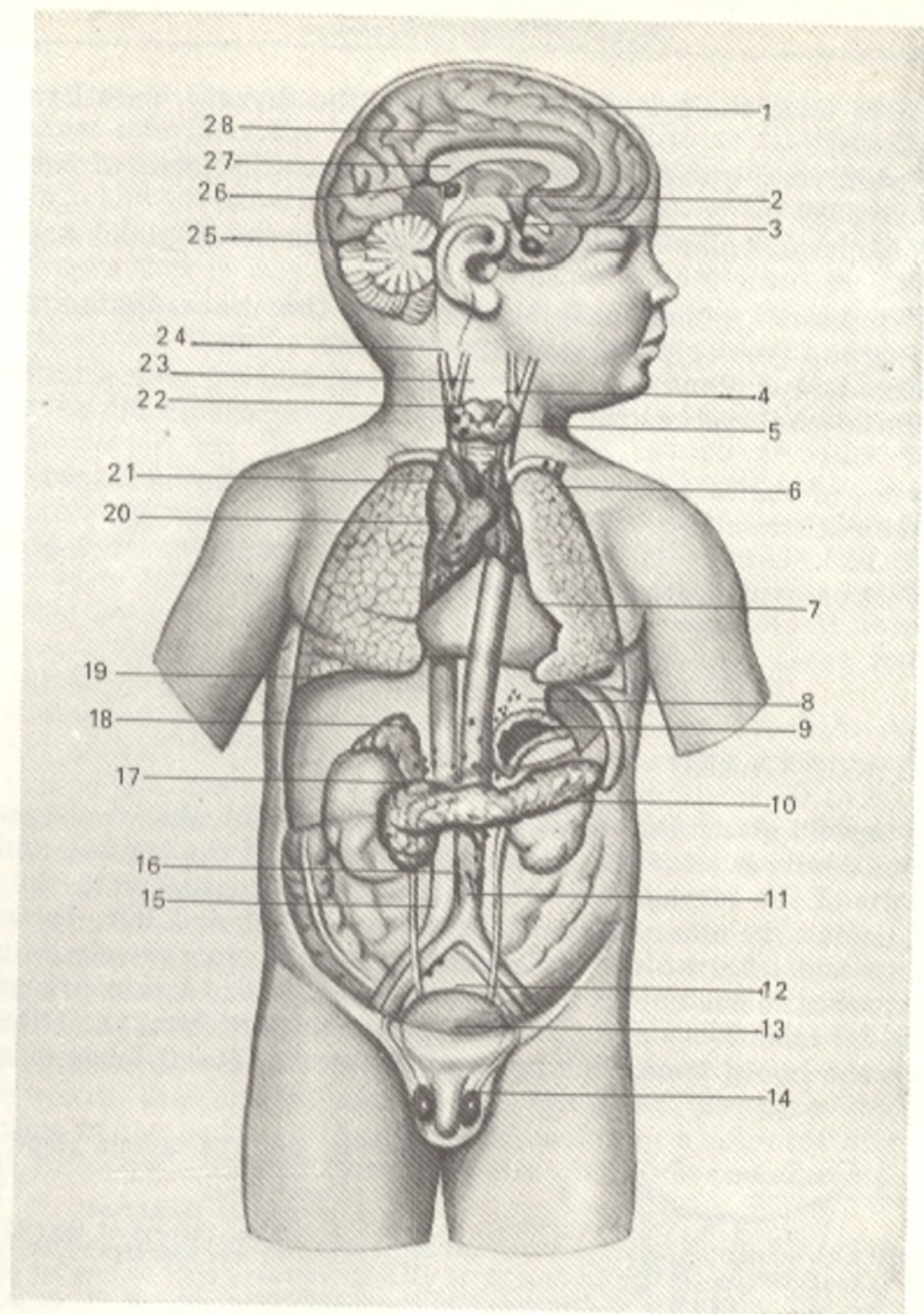


Fig. 284. Localization of endocrine glands, represented schematically (after Sinelnikov).

- 1, hemispherium cerebri;
- 2, infundibulum;
- 3, hypophysis cerebri;
- 4, glandula thyroidea;
- 5, trachea;
- 6, pulmo;
- 7, pericardium;
- 8, medulla glandulae suprarenalis;
- 9, cortex glandulae suprarenalis;
- 10, ren;
- 11, aorta;
- 12, vesica urinaria;
- 13, glomus coccygeum;
- 14, testis;
- 15, v. cava inferior;

- 16, corpora paraaortica (paraganglion aorticum);
- 17, pancreas;
- 18, glandula suprarenalis;
- 19, hepar;
- 20, paraganglion supracardiale;
- 21, thymus;
- 22, glandulae parathyroideae;
- 23, larynx;
- 24, glomus caroticum;
- 25, cerebellum;
- 26, tectum mesencephali;
- 27, corpus pineale;
- 28, corpus callosum

of the embryo form the branchiogenic group (the thyroid, parathyroid, and thymus glands).

2. Entodermal glands of the intestinal tube (the islets of Langerhans in the pancreas).

3. Mesodermal glands (the cortex of the suprarenal gland and the sex glands).

4. Ectodermal glands originating from the diencephalon form the neurogenic group (the epiphysis and hypophysis).

5. Ectodermal glands arising from the sympathetic elements form the group of the adrenal system (the medulla of the suprarenals and the chromaffin bodies).

In view of the fact that the endocrine glands differ in origin, development, and structure and are united only according to their function (internal secretion), it is correct to consider that they compose an apparatus, the endocrine apparatus, rather than a system.

## THE BRANCHIOGENIC GROUP

### THE THYROID GLAND

The **thyroid gland** (*glandula thyroidea*) (Fig. 285), the largest endocrine gland in an adult, is situated on the neck in front of the trachea and on the lateral walls of the larynx; part of the gland is in contact with the thyroid cartilage, hence its name. It consists of two, **right and left, lateral lobes** (*lobus dexter* and *lobus sinister*) and an **isthmus** lying transversely and joining the lateral lobes to each other near to their lower ends. A thin process called the **pyramidal lobe** (*lobus pyramidalis*) extends upward from the isthmus and may reach the hyoid bone. The upper parts of the lateral lobes overlap the

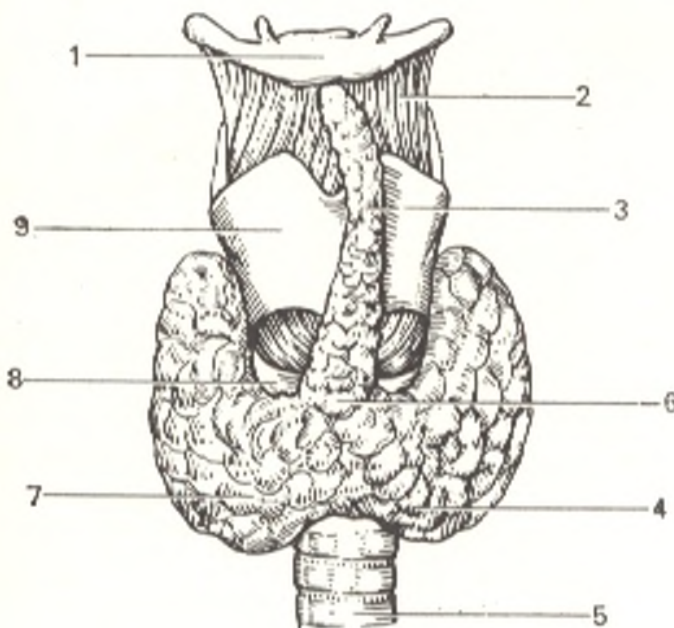


Fig. 285. The thyroid gland.

- 1, hyoid bone;
- 2, thyrohyoid membrane;
- 3, pyramidal process of thyroid gland;
- 4 and 7, left and right lobe;
- 5, trachea;
- 6, isthmus;
- 8, cricoid cartilage;
- 9, thyroid cartilage

external surface of the thyroid cartilage and cover its inferior horn and the adjacent area; inferiorly the lobes extend to the fifth or sixth tracheal ring; the posterior surface of the isthmus is in contact with the second and third tracheal rings and the superior margin sometimes reaches the cricoid cartilage. Posteriorly the lateral lobes are intimately related to the walls of the pharynx and oesophagus that is why in goitre (abnormal enlargement of the thyroid) disorders of swallowing may occur due to compression of the oesophagus. Laterally the lobes slightly extend over the anterior surfaces of the common carotid arteries. The outer surface of the thyroid is convex, the inner surface facing the trachea and larynx is concave. In front the thyroid is covered with skin, subcutaneous fat, the fascia of the neck, which provides the gland with an external fibrous capsule (*capsula fibrosa*), and with muscles (the sternohyoid, sternothyroid, and omohyoid). Thickenings of the external capsule form the ligamentous apparatus joining the gland with the trachea and larynx as a result of which it moves together with these organs. The capsule gives off processes into the tissue of the gland, which separate it into lobules consisting of vesicles containing colloid (its component is an iodine containing substance, thyroïdin).

The thyroid gland measures about 50-60 mm in breadth, its antero-posterior dimension is 18-20 mm in the region of the lateral lobes and 6-8 mm at the level of the isthmus. Its weight ranges from about 30 to 40 g and is slightly more in females than in males and sometimes increases regularly (during menstruation). The thyroid gland is relatively larger in the foetus and in the infant than in the adult.

*Function.* The gland plays a very important role in the organism. Its congenital underdevelopment causes myxoedema and cretinism. The hormone of the gland determines proper development of the tissues, the bone tissue in particular, metabolism, functioning of the nervous system, etc. Disorders of thyroid function lead to the development of endemic goitre in some localities. Thyroxin, the hormone produced by the gland, promotes the processes of oxidation in the body. In thyroid hypersecretion a complex of symptoms known as Basedow's disease (exophthalmic goitre) is encountered.

*Development.* The gland develops from the first branchial pouch behind the unpaired germ of the tongue so that embryologically it is part of the alimentary canal. The foramen caecum on the tongue marks the point of outgrowth of the gland. The epithelial cord growing out of this point receives a lumen (the thyroglossal duct) in its upper portion before dividing into two lobes. At the end of the fourth week it usually atrophies and disappears leaving only the foramen caecum on the tongue. The pyramidal lobe mentioned above is a remnant of the thyroglossal duct. Accessory thyroid glands may also occur.

The thyroid receives two superior thyroid arteries (from the external carotid artery), two inferior thyroid arteries (from the thyrocervical trunk arising from the subclavian artery) and a fifth unpaired (inconstant) artery, a. ima, which may arise from the brachiocephalic trunk, the subclavian artery or even from the arch of the aorta. The veins form plexuses, which lie under the external capsule; these plexuses drain into three veins on either side: the superior, middle, and inferior thyroid veins (the first two drain into the internal jugular vein, while the inferior vein drains into the left brachiocephalic vein).

The lymphatic vessels are numerous and form a rich plexus; they conduct the colloid, pass in attendance to the arteries and drain into the tracheal, deep cervical, and mediastinal lymph nodes.

The *nerves* arise from the sympathetic trunk (mainly from the middle cervical ganglion and partly from the superior and inferior ganglia), from the vagus nerve (by way of the superior and inferior laryngeal nerves) and, possibly, from the glossopharyngeal nerve.

## THE PARATHYROID GLANDS

The **parathyroid glands** (*glandulae parathyroideae*) (epithelial bodies), usually four in number (two superior and two inferior), are small bodies situated on the posterior surface of the lateral thyroid lobes (Fig. 286). Their average dimensions are 6 mm in length, 4 mm in breadth, and 2 mm in thickness. They are pink in young subjects but acquire a yellowish or brown colour with age. On examination with the naked eye the parathyroids can sometimes be mistaken for fatty lobules, accessory thyroid glands or pieces separated from the thymus.

*Function.* The parathyroid glands regulate calcium and phosphorus metabolism in the body. Their extirpation results in death preceded by tetany.

It is now considered that the parathyroids cause an effect on the blood calcium level not only humorally through the parathyroid hormone but also by the neurohumoral paths.

*Development and variants.* The parathyroid glands develop from the third and fourth branchial pouches and are, therefore, developmentally related to the alimentary canal like the thyroid gland. Their number may vary, it is rarely less than four and relatively more frequently it is increased (five to twelve). In some cases they are almost completely embedded in the tissue of the thyroid gland.

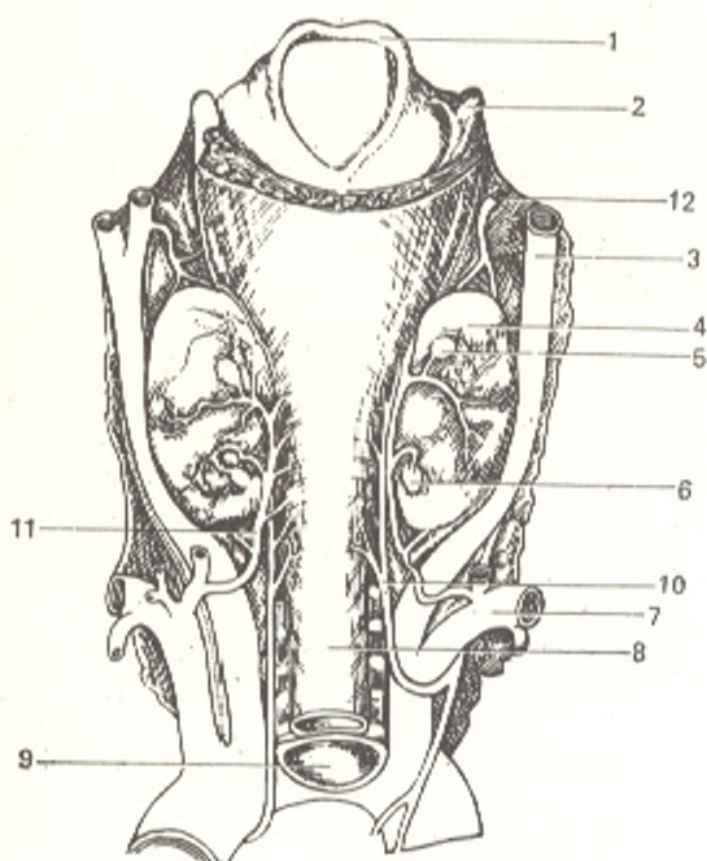


Fig. 286. The parathyroid glands.

- 1, epiglottis;
- 2, cornu superius cartilaginis thyroideae;
- 3, a. carotis communis;
- 4, lobus dexter glandula thyroideae;
- 5, glandula parathyroidea superior dextra;
- 6, glandula parathyroidea inferior dextra;
- 7, a. subclavia dextra;
- 8, esophagus;
- 9, trachea;
- 10, n. laryngeus inferior;
- 11, a. thyroidea inferior;
- 12, a. thyroidea superior



The parathyroids are supplied with *arterial blood* from branches of the inferior and superior thyroid arteries and in some cases from branches of the oesophageal and tracheal arteries. Wide sinusoid capillaries are inserted between the arteries and veins. The *sources of innervation* are the same as in the thyroid gland, the nerve branches are numerous.

## THE THYMUS

The thymus (Fig. 287) is both an endocrine gland and an organ of immunological reactions. That is why its structure is described in volume II in *Organs of Haemopoiesis and Immunological Reactions*.

## THE NEUROGENIC GROUP

### HYPOPHYSIS CEREBRI

The *hypophysis cerebri*, or *pituitary gland* (*glandula pituitaria*) (Figs. 288 and 104 in Volume II) is a small spherical or oval gland, reddish in colour, which is connected with the brain, with the tuber cinereum and tuber in-

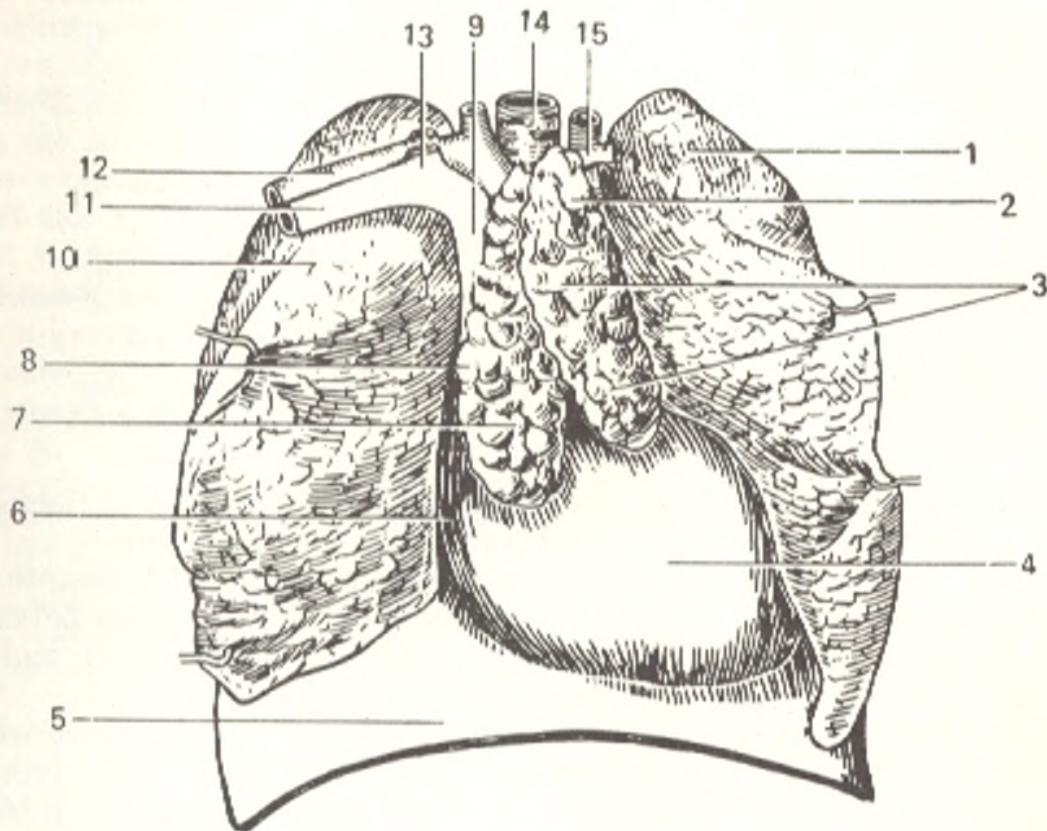


Fig. 287. Organs of the anterior mediastinum of a child. The thymus.

- |  |                                |
|--|--------------------------------|
| 1, left lung, medial surface;                        | 7, thymus (right lobe);        |
| 2, lobule of thymus;                                 | 9, v. cava superior;           |
| 3, thymus (left lobe);                               | 10, right lung;                |
| 4, pericardium;                                      | 11 and 13, subclavian vein;    |
| 5, diaphragm;  | 12, subclavian artery;         |
| 6 and 8, line of incision of the mediastinal pleura; | 14, trachea;                   |
|  | 15, left common carotid artery |

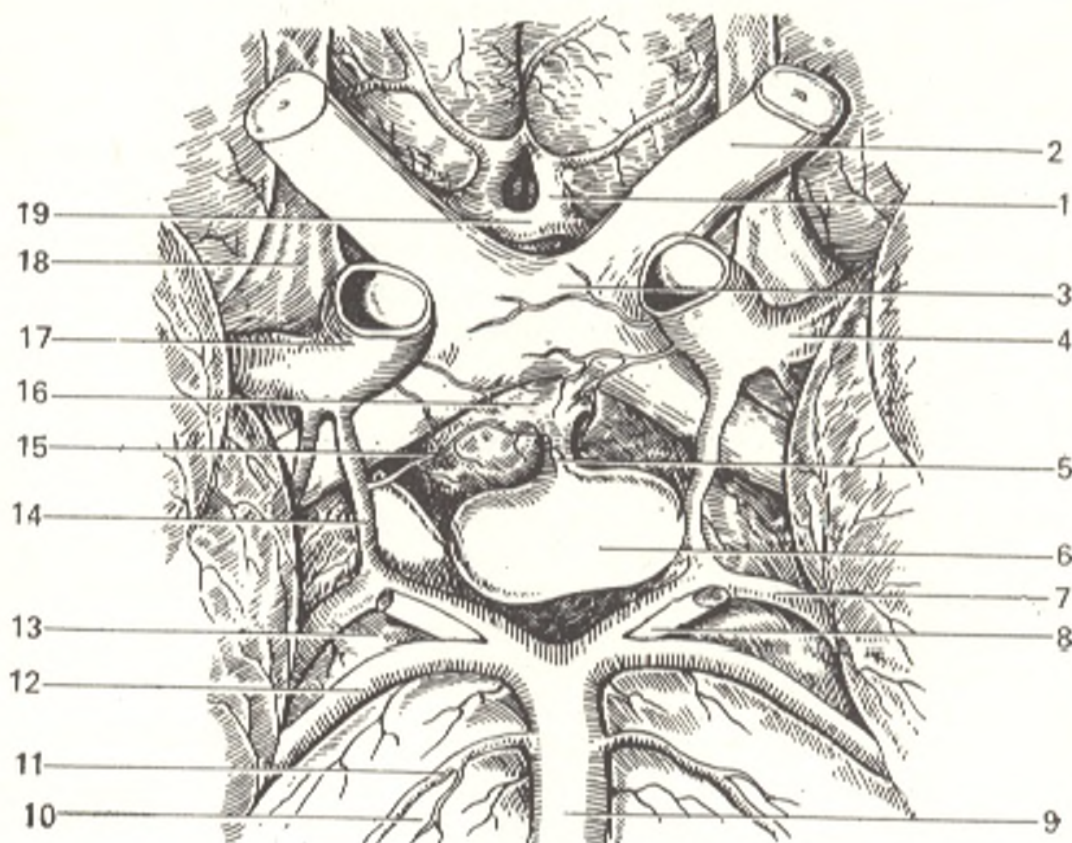


Fig. 288. Hypophysis, viewed from below (after Sinelnikov).

- |                          |                               |
|--------------------------|-------------------------------|
| 1, a. cerebri anterior;  | 11, a. labyrinthi;            |
| 2, n. opticus;           | 12, a. cerebelli sup.;        |
| 3, chiasma opticum;      | 13, pedunculus cerebri;       |
| 4, a. cerebri media;     | 14, a. communicans posterior; |
| 5, infundibulum;         | 15, a. hypophyseae;           |
| 6, hypophysis cerebri;   | 16, tuber cinereum;           |
| 7, a. cerebri posterior; | 17, a. carotis interna;       |
| 8, n. oculomotorius;     | 18, tractus olfactorius;      |
| 9, a. basilaris;         | 19, a. communicans anterior   |
| 10, pons;                |                               |

fundibulum, by means of the hypophysial stalk. The gland is lodged in the sella turcica and is attached there by the diaphragma sellae.

The dimensions of the hypophysis are small: 8-10 mm in length, 12-15 mm in width, and 5-6 mm in height. Its weight ranges between 0.35 and 0.65 g. The gland is considerably enlarged in pregnancy and fails to regain its initial size after delivery.

Two lobes differing in structure, function, and development are distinguished in the hypophysis: **anterior** and **posterior lobes**. The superior part of the anterior lobe, which adjoins the tuber cinereum, is distinguished as the *tuberal part* (*pars tuberalis*). The posterior part of the anterior lobe situated as a border between this lobe and the posterior lobe is termed the *intermediate part* (*pars intermedia*).

The anterior lobe with the tuberal and intermediate parts develops from the ectoderm of the oral pit by the formation of a diverticulum of the pharyngeal (hypophyseal) pouch. It first occurs as an exocrine gland but its duct soon reduces and it becomes an endocrine gland with a maintained glandular structure (adenohypophysis). Remnants of the

former duct may sometimes be found as the craniopharyngeal canal stretching from the floor of the sella turcica into the pharynx.

The posterior lobe is laid down later than the anterior lobe as a diverticulum of the floor of the third ventricle. The upper part of the diverticulum, which remains hollow, gives rise to the tuber cinereum and the tuber infundibulum, the lower part develops into the posterior hypophysial lobe and the hypophyseal stalk, which are, therefore, a projection of the infundibulum and contain elements of the nervous system (neurohypophysis).

*Function.* The different structure and development of the two lobes determines the different function.

The anterior lobe affects the growth and development of the whole body (the somatotrophic hormone). In tumours of this lobe, intensified growth of the fingers, nose, and lips occurs (acromegaly). The anterior lobe also stimulates the activity of the other endocrine glands, namely the thyroid (thyrotrophic hormone), the adrenal cortex (the adrenocorticotrophic hormone), and the sex glands (the gonadotrophic hormone).

The posterior lobe augments the work of the smooth muscles of the vessels by raising blood pressure (vasopressin) and the muscles of the uterus (oxytocin) and also exerts an influence on reabsorption of water in the kidneys (the antidiuretic hormone). Damage to the posterior hypophyseal lobe causes diabetes insipidus.

*Neurosecretion.* The posterior lobe takes part in neurosecretion, i.e. the production of specific neurosecretory substances by the hypothalamic neurons, chemomediators. Chemomediators spread along the axons of these neurons through the hypophysial stalk into the neurohypophysis and pass there into the vessels through the vasoneural synapses. This is explained by the common origin of the hypothalamus and the hypophysis and their constructive connections through the hypophysial stalk.

The hypophysis is considered the centre of the endocrine apparatus because it produces hormones, which stimulate the development and function of the other endocrine glands.

A specific feature of the *blood supply* to the hypophysis is the existence of a portal system in its anterior lobe: numerous (10-25) small branches of the circle of Willis soon ramify in the hypophysial stalk into capillaries, which drain into the portal veins entering the hypophysial hilus and again ramifying into capillaries, sinusoids, in the tissue of the gland. These give rise to the veins draining the hypophysis. The posterior lobe receives branches from the internal carotid artery. Both lobes are supplied separately with arterial blood but their vessels anastomose with one another.

The arterial anastomoses and the joining of the capillary bed of the two parts of the hypophysis can be regarded as potential collateral channels of the blood supply to the organ. They provide the possibility for the redistribution of blood in changed intensity of hypophysial activity as well as during neuro-numoral correlations of the functionally different components of this organ. *Venous blood* drains into plexus situated at the base of the brain and then into the cerebri magna vein. The *lymphatic vessels* drain into the subarachnoid space, into which some hormones enter. The *nerves* (sympathetic) arrive from the pia mater plexus.

## THE PINEAL BODY

The **pineal body**, or **gland** (*corpus pineale* s. *epiphysis cerebri*) (see Figs. 108 and 111 in Volume II) is situated above the anterior quadrigeminal bodies and is connected with the thalamus by means of the habenulae. It is

a small oval, reddish body whose narrower end is directed downward and to the back. (It measures 7-10 mm in length and 5-7 mm in width.) Its cells are grouped in the form of strands and possess secretory properties. The pineal body is larger in infants (it is also larger in females than in males) but signs of involution are detected even before the onset of puberty as early as the seventh year of life.

*Function.* The function of the pineal body is still not clear to the end. Extirpation of the gland results in rapid growth of the skeleton in animals and premature and abnormally intensive development of the sex glands and secondary sexual characters. This suggests that the gland has an inhibiting effect on these functions.

*Development.* The pineal body develops as an initially hollow pouch-like outgrowth from the superior wall of the diencephalon (the future third ventricle).

*Vessels and nerves.* The pineal body receives some branches from the posterior choroid artery (a branch of the posterior cerebral artery), and the superior cerebellar and middle cerebral arteries. The sympathetic fibres entering the pineal body are evidently intended for innervation of the blood vessels.

## THE ADRENAL SYSTEM GROUP

### THE SUPRARENAL GLAND

The suprarenal, or adrenal gland (*glandula suprarenalis s. adrenalis*) is a paired organ situated in the retroperitoneal fat above the superior end of the corresponding kidney (Fig. 289). The adrenal gland (right) weighs about 4 g; no significant enlargement of the gland is encountered with age. The dimensions are as follows: vertical 30-60 mm; transverse about 30 mm; anteroposterior 4-6 mm. On the outer surface the gland is yellowish or brownish in colour. The lower, tapering end of the right suprarenal gland embraces the superior pole of the kidney, whereas the left gland is in intimate relation with the medial border of the kidney closest to its pole rather than with the pole itself.

One or more clefts are seen on the anterior surface of the glands; these are the hilum through which the suprarenal vein leaves the gland and the arteries enter it. The posterior surfaces of both suprarenal glands lie against the diaphragm.

*Structure.* The suprarenal gland is covered with a fibrous capsule, which gives off trabeculae into the tissue of the gland. It can be seen on section that the suprarenal gland consists of two layers, a yellowish cortex and a medulla, which is softer and of a darker brownish colour. They differ sharply from each other in development, structure, and function.

The cortex is formed of three zones, which produce different hormones. The medulla consists of cells secreting adrenaline and noradrenaline. They also contain very many non-medullated and ganglionic (sympathetic) nerve cells.

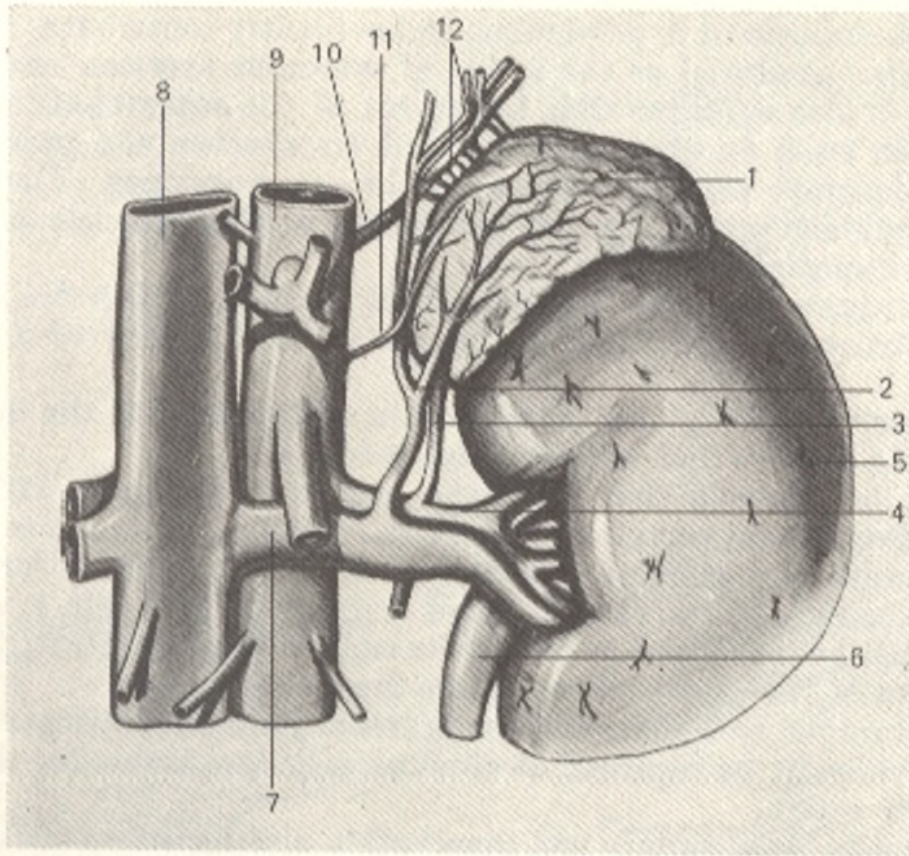


Fig. 289. Left suprarenal gland, anterior aspect (after Sinelnikov).

1, glandula suprarenalis;  
2, v. suprarenalis sin.;  
3, a. suprarenalis inferior;  
4, a. renalis;  
5, ren;  
6, ureter;

7, v. renalis;  
8, v. cava inferior;  
9, aorta;  
10, a. phrenica inferior;  
11, a. suprarenalis media;  
12, aa. suprarenalis superior

*Development and variants.* The cortex is related to the interrenal system arising from the mesoderm between the two primary kidneys (hence the name of the system). The medulla, in contrast, originates from the ectoderm, from the sympathetic elements (which separate later into the sympathetic nerve cells and the chromaffin cells). This is the adrenal, or chromaffin system. The interrenal and chromaffin systems are independent of each other in the lower vertebrates, but are united into a single anatomical organ, the suprarenal gland, in higher mammals and man.

Remnants of both systems, which formerly, in embryonic life, stretched for a considerable distance, may also be encountered in higher mammals besides the main organ (the suprarenal gland). The remnants of the interrenal system are known as the *accessory suprarenal glands*; they have been found in the suprarenal gland itself, in the kidney, in the connective tissue of the retroperitoneal space, and in the sex glands, both male and female (see "Paraganglia" below). In rare cases one, or still less frequently, both suprarenal glands may be absent.

*Function.* In accordance with the different structure of the two constituents, the cortex and the medulla, the suprarenal gland as if combines the function of two glands. The medulla secretes into the blood adrenaline, which maintains the tonus of the sympathetic nervous system and possesses vasoconstrictive properties. The cortex is the main site of lipid production

(lecithin and cholesterol in particular) and evidently contributes to neutralization of toxins produced as the result of muscular exertion and fatigue.

There is also evidence that the cortex of the suprarenals secretes hormones, which exert an effect on water-salt metabolism and produce specific hormones identical with or related to the sex hormones. The suprarenal cortex is capable of producing such a diversity of hormones because its different zones are specialized.

The intimate union of the cortex and medulla, which are so different in origin, structure, and function, suggests the existence of a definite reciprocity.

Both parts of the gland contribute in cooperation to the development of the body's defence and adaptational reactions.

It can be assumed that when the body's condition is within normal bounds the suprarenal cortex and medulla function more or less separately. However, under any extreme circumstances causing sharp disorders in the state of the body (e.g. starvation, blood loss, severe pain, etc.), when all its resources must be mobilized to restore its equilibrium, cooperated activation of both parts of the gland comes to the forefront.

The joining of both parts of the suprarenal gland into a single anatomical organ can evidently be regarded as circumstance favourable for the synchronism of their action.

A common blood supply and innervation also facilitate the cooperative activity of the two parts of the suprarenal gland. For instance, relaxation of sphincters present in the suprarenal veins leads to simultaneous liberation of medullary and cortical hormones into the blood.

The adrenals receive three pairs of *arterial* branches: superior suprarenal arteries (from the inferior phrenic artery), middle (from the abdominal aorta), and inferior suprarenal arteries (from the renal artery). They all anastomose with one another to form a network in the capsule of the glands. *Venous blood* passes through the wide venous capillaries (sinusoids) and usually drains along a single vessel, the suprarenal (central) vein, which leaves the gland through the hilum and drains into the vena cava inferior (the right vessel) and into the left renal vein (the left, longer vessel). The *lymphatic vessels* run to the lymph nodes situated at the aorta and vena cava inferior.

The *nerves* pass from the major splanchnic nerve (through the coeliac and renal plexus).

## THE CHROMAFFIN BODIES

The **chromaffin bodies**, free remnants of the *adrenaline*, or *chromaffin system*, are known under the term *paraganglia*, or accessory sympathetic organs because they are intimately related to the sympathetic nervous system being situated medially or dorsally of the sympathetic trunk ganglia (Fig. 290). Like the medulla of the suprarenal gland, they contain chromaffin cells. The following structures belong to the group of paraganglia: the **para-aortic bodies** (*corpora para-aortica*) situated on the sides of the abdominal aorta above its bifurcation; the **carotid body** (*glomus caroticum*) (Fig. 291) situated in the angle formed by the bifurcation of the common carotid artery;

Fig. 290. Position of temporary and permanent chromaffin paraganglia in the human body, represented schematically.

- 1 and 15, intercarotid paraganglia;
- 2 and 4, inconstant paraganglia in oesophageal nerve plexus;
- 3, supracardiac paraganglia;
- 5, paraganglia in coeliac plexus;
- 6 and 13, suprarenal paraganglia (suprarenal medulla);
- 7, inconstant paraganglia in renal plexus;
- 8, inconstant paraganglia in superior mesenteric plexus;
- 9 and 12, lumbar-aortic paraganglia (in infancy);
- 10, inconstant paraganglion in testis;
- 11, inconstant paraganglia in hypogastric plexus;
- 14, inconstant paraganglia in stellate ganglion

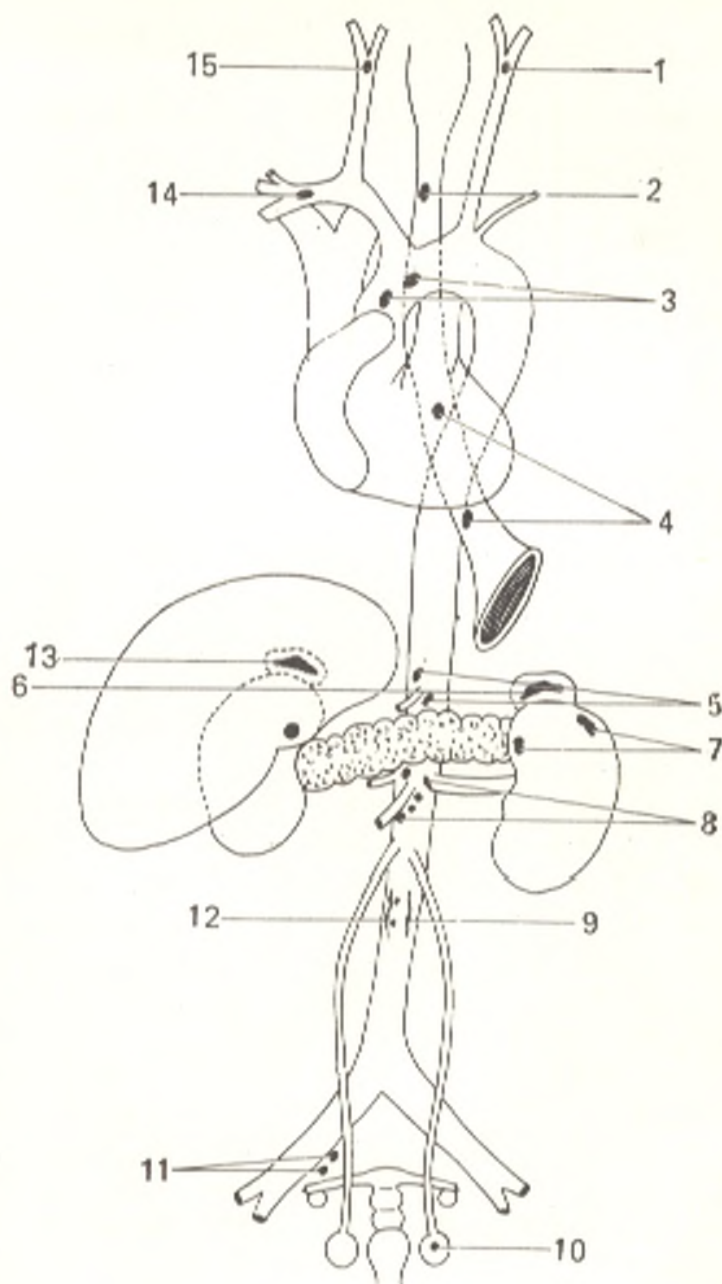
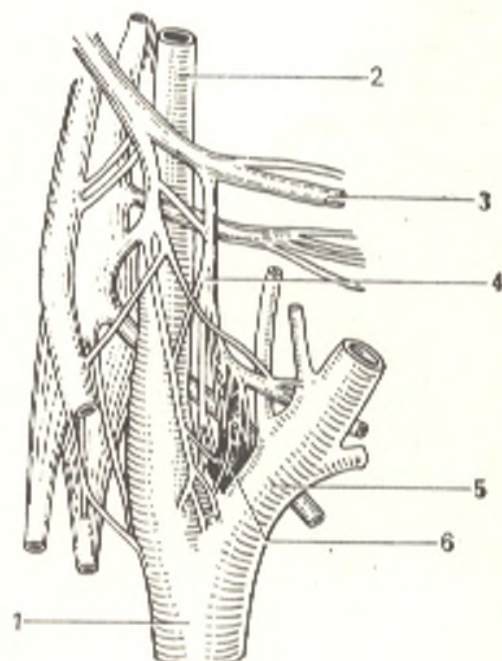


Fig. 291. Intercarotid paraganglion (glomus intercaroticum) of a newborn (after Smirnov).

- 1, common carotid artery;
- 2, internal carotid artery;
- 3, glossopharyngeal nerve;
- 4, sinus nerve;
- 5, external carotid artery;
- 6, intercarotid paraganglion



the **coccygeal body** (*glomus coccygeum*) situated on the end of the median sacral artery.

The activity of the chromaffin bodies is identical with that of the suprarenal medulla.

## THE MESODERMAL GLANDS

### ENDOCRINE ORGANS OF THE SEX GLANDS

1. Polygonal interstitial cells (Leydig's cells) are embedded in the testis in the connective tissue between the seminiferous tubules. These are the **interstitial glands** of internal secretion (they secrete the hormone testosterone and the androgen hormones). Some authors attribute only a trophic role to them, however, and relate the secretion of the sex hormone to the sex (seminal) cells.

2. The production of the specific hormone in the ovary is associated with the secretion of the follicles themselves. To this hormone, called folliculin, is attributed the exertion of a trophic effect on the sex apparatus, the regulation of menstruations, the exertion of an effect on the secondary sex characters, and lending the nervous system eroticism.

Besides, another endocrine organ, the yellow body (the corpus luteum) appears regularly in the ovary. Two categories of this corpus exist: the true yellow body or the yellow body of pregnancy (corpus luteum verum s. graviditatis) and the false yellow body (corpus luteum spurium s. menstruatium [periodicum]). Both are similar in origin; they develop from a ruptured follicle, which has liberated the oocyst, but the true body exists in a woman nine months and grows to a relatively large size, while the false body appears periodically and exists one month. In involution of the corpus luteum the process of regressive metamorphosis consists in gradual reduction of the number of cell elements and their replacement by the proliferating connective tissue; the corpus luteum disappears finally without leaving a trace and blends with the ovarian stroma.

The corpora lutea contribute to the regulation of the female sex cycle. This activity is linked with the production of two hormones united under the concept female sex hormones (1) the oestrogenic hormone, or oestrogen and (2) the hormone of the yellow body, or progesterone.

Removal of the corpus luteum in the early stages of pregnancy and deprivation of the body of progesterone disturb implantation of the oocyst and result in abortion.

From the general biological standpoint, the principal function of oestrogen consists in preparation of the female reproductive apparatus for fertilization of the oocyst, which leaves the follicle after ovulation; progesterone provides for the implantation and normal development of the fertilized oocyst.



The cortex of the suprarenal gland (the interrenal system) related developmentally to this group of glands is described above together with the medulla in the adrenal system group for the convenience of the description of the organ as a single whole.

## ENTODERMAL GLANDS OF THE INTESTINAL TUBE

### INSULAR PART OF THE PANCREAS

Islets of Langerhans (*insulae pancreaticae Langerhansi*) are inserted among the glandular parts of the pancreas; their number is greatest in the tail of the gland. These structures are related to the endocrine glands.

*Function.* The islets secrete their hormones insulin and glucagon into the blood and thus regulate carbohydrate metabolism. The connection of lesions of the pancreas with diabetes is generally known. Insulin now plays an important role in the treatment of this disease.